

**NEUTROPHIL CYTOPLASMIC ANTIBODIES :
THEIR CLINICAL ASSOCIATIONS AND AN
IMPROVED METHOD FOR THEIR DETECTION**

by

June Duursma

**Submitted in partial fulfilment of the requirements for the degree
of
Master of Medical Science in the Department of Medicine
University of Natal**

1993

For my friend Prakash Naidoo ("DP")

CONTENTS

	<u>PAGE</u>	
ABSTRACT	v	
PREFACE	vii	
ACKNOWLEDGEMENTS	x	
ABBREVIATIONS	xii	
PLATES, FIGURES AND TABLES	xvi	
INTRODUCTION	xix	
CHAPTER 1		
THE INDIRECT IMMUNOFLUORESCENT TEST FOR THE DETECTION OF ANTINEUTROPHIL CYTOPLASMIC ANTIBODIES		
1.1	INTRODUCTION	1
	1.1.1 C-ANCA	3
	1.1.2 P-ANCA	6
	1.1.3 X-ANCA	9
	1.1.4 GS-ANA	13
1.2	BUFFY COAT SMEAR NEUTROPHIL SUBSTRATE	16
	1.2.1 Preparation : Materials and Methods	16
	1.2.2 I I F : Materials and Methods	17
1.3	DEVELOPMENT OF A NEW I I F METHOD	
	16 WELL CHAMBER SLIDE	20
	1.3.1 Introduction	20
	1.3.2 Background	22
	1.3.3 Preparation : Materials and Methods	26
	1.3.4 I I F : Materials and Methods	31

1.3.5	Storage	34
1.4	PREPARATION OF A MYELOPEROXIDASE DEFICIENT NEUTROPHIL SUBSTRATE	36
1.4.1	Introduction	36
1.4.2	Materials and Methods	38
CHAPTER 2		
ANCA AND DISEASE		
2.1	SYSTEMIC VASCULITIS	39
2.1.1	Introduction	39
2.1.2	Study population	40
2.1.3	Methods	40
2.1.4	Results	42
2.1.5	Discussion	46
2.2	INFLAMMATORY BOWEL DISEASE	48
2.2.1	Introduction	48
2.2.2	Study population	51
2.2.3	Methods	52
2.2.4	Results	52
2.2.5	Discussion	54
2.3	SYMPTOMATIC HIV DISEASE	57
2.3.1	Introduction	57
2.3.2	Study population	58
2.3.3	Methods	59

2.3.4	Results	60
2.3.5	Discussion	63
2.4	INVASIVE AMOEBIASIS	65
2.4.1	Introduction	65
2.4.2	Study population	65
2.4.3	Methods	66
2.4.4	Results	69
2.4.5	Discussion	75
2.5	CLINICAL STUDIES	77
2.6	CONTROLS	84
	CONCLUSION	87
	REFERENCES	89
	SELECTED BIBLIOGRAPHY	100

ABSTRACT

The test for antineutrophil cytoplasmic antibodies (ANCA) was introduced into the author's laboratory in 1987. An improved indirect immunofluorescent method was developed, using a system which allows 16 instead of one serum sample to be screened on each microscope slide.

The known disease associations of ANCA that have been explored include systemic vasculitis, renal limited vasculitis, chronic inflammatory bowel disease and HIV disease. In general the findings are similar to those which are emerging from other centres and confirm the value not only of the positivity but also the relevance of the intracellular disposition of the neutrophil cytoplasmic fluorescence in diagnosis.

In this study 85% of patients with Wegener's granulomatosis were found to have C-ANCA. C, P and X-ANCA staining patterns were found in 57% of patients with ulcerative colitis. Forty one per cent of patients with symptomatic HIV have ANCA.

Certain histological features such as neutrophil and vascular damage in invasive amoebiasis, and the established lytic effect of amoebae on neutrophils prompted the investigation of the possibility that ANCA may be generated in this disease. Seventy eight amoebiasis sera were screened and 98,7% gave a positive ANCA test with a pattern of fluorescence resembling that found in Wegener's granulomatosis. An ELISA test for specificity confirmed that, as in Wegener's granulomatosis, this amoebiasis-associated ANCA had proteinase 3

specificity. Of practical clinical importance is the fact that both HIV and amoebiasis are associated with a high level of ANCA positivity. These findings will need to be considered when ANCA tests are used in clinical decision making in an area where HIV disease and amoebiasis are endemic.

A large number of normal volunteer blood donors have been tested and the false positivity rate of 0,5% confirms the specificity of the test.

PREFACE

The experimental work described in this thesis was carried out in the Department of Medicine, University of Natal Medical School, Durban, under the supervision of Professor Dennis Pudifin.

These studies represent original work by the author and have not been submitted to any other university.

The following are publications and presentations arising from this study to date.

PUBLICATIONS

Pudifin DJ, Naicker S, Patton MS, Naicker IP, Nathoo BC, Mody GM, Duursma J, Parag KB. Circulating auto-antibodies to neutrophil cytoplasmic antigens in vasculitis. A report of 3 cases. *S Afr Med J* 1989; **78**: 73-75.

Duursma J, Pudifin DJ. A rapid indirect immunofluorescent screening test for the detection of anti-neutrophil cytoplasmic antibodies. (Letter) *S Afr Med J* 1993; **83(11)**: 865-866.

Published in journal in abstract form.

Pudifin DJ, Duursma J, Gathiram V, Jackson TFHG. Serum from patients with invasive amoebiasis has anti-neutrophil cytoplasmic activity. *Clin Exp Immunol* 1993; **93 Suppl 1**: 33.

ORAL PRESENTATIONS.

Pudifin DJ, Duursma J. Antibody to neutrophil cytoplasmic antigens in vasculitis.

SA Renal Society meeting, Durban 1988.

Duursma J, Pudifin DJ. A rapid indirect immunofluorescent screening test for the detection of anti-neutrophil cytoplasmic antibodies.

1. Dept of Medicine, University of Natal, ICI 10th annual Clinical Research Day. 7th October 1992. *This paper shared the award for the best junior researcher.*

2. 15th Congress of the SA Transplantation Society and the 2nd interim congress of the SA Immunology Society 9-13 th May 1993.

Goagoseb A, Randeree IGH, Duursma J, Pudifin DJ. Antineutrophil cytoplasmic antibody testing.

Dept of Medicine, University of Natal, ICI 10th annual Clinical Research Day.

7 th October 1992.

Pudifin DJ, Duursma J, Gathiram V, Jackson TFHG. Serum from patients with invasive amoebiasis has anti-neutrophil cytoplasmic activity.

1. 5th International ANCA workshop St John's College, University of Cambridge UK, September 1993. *This paper was awarded the Friederich Wegener award for the best oral presentation at the conference.*

2. Dept of Medicine, University of Natal, ZENECA 11th Annual Research Day, 6th October 1993. *This paper was awarded the senior researcher's prize*

POSTER PRESENTATION

Randeree IGH, Duursma J, Goagoseb A, Pudifin DJ. Antineutrophil cytoplasmic antibody (ANCA) testing in Natal.

XIIth International Congress of Nephrology. Jerusalem Israel 13th-18th June 1993.

ACKNOWLEDGEMENTS

I would like to thank the many people whose help and advice contributed to this thesis.

Professor Dennis Pudifin, my supervisor, for the many hours of discussion, guidance and editing of this manuscript. I'd also like to thank him for the innumerable venepunctures he endured, to provide the standard neutrophil substrate and serum control for this entire thesis.

Professor Peter Brain who many years ago inspired me to do research work and to have fun while doing it.

Dr Dereck Tait whose challenge it was that initiated this thesis.

Professor Y K Seedat Head of the Department of Medicine, University of Natal Medical School for giving me the opportunity to carry out this work.

The many consultants and registrars in the Department of Medicine who were always so helpful with patient blood samples and clinical details.

Dr Sarala Naicker and the staff of the Renal Unit at Addington Hospital, Dr Ismail Randeree and Dr Augustine Goagaseb for their clinical contribution to the section on vasculitis.

Professor Ahmed Simjee, Dr Bob Moolla, Dr Keith Pettengell, Dr Allan Eathorne and Dr Ian Macleod for access to their patients with inflammatory bowel disease.

Dr Terry Jackson of the Medical Research Council and Dr Vinodh Gathiram for the serum samples, advice and clinical assessment of patients with amoebiasis.

Dr Vinodh Gathiram and Dr Nirupa Shah for allowing me to test their HIV positive patients.

The Natal Blood Transfusion Service for access to their blood donor samples that constituted the majority of the control population studied.

The Department of Chemical Pathology for the use of their tissue culture facilities.

My dear friend Mr G H Haffajee for the many hours he spent checking all my references, and the staff in the Medical library who were always so incredibly helpful.

My friends and colleagues in the Immunology laboratory, Margaret Stretton, Hilary Dinnematin and Nerina Gerber.

Mr Tinus Fick the myeloperoxidase negative volunteer who donated his blood whenever it was needed, and the haematology laboratory of the Durdoc laboratory who found him for me.

Mr Victor van der Walt for his patience and help with computer programmes used in this work.

My father, Professor Isidor Gordon for his continual encouragement and for proof reading this thesis.

My late mother, Jean Gordon for all her love and support.

My husband Rienk, for his tolerance and for buying me a computer when he feared that I'd use too many trees before completing this thesis.

ABBREVIATIONS

ACA	-	anticardiolipin antibody
AIDS	-	acquired immunodeficiency syndrome
ALA	-	amoebic liver abscess
ANCA	-	antineutrophil cytoplasmic antibody
A-ANCA	-	atypical antineutrophil cytoplasmic antibody
ANA	-	antinuclear antibody
ANF	-	antinuclear factor
ARC	-	aids related complex
AZT	-	azidothymidine
CD4	-	Helper T lymphocyte
CG	-	cathepsin G
CSS	-	Churg-Strauss syndrome
C-ANCA	-	cytoplasmic antineutrophil cytoplasmic antibody
DNA	-	deoxyribonucleic acid
ds-DNA	-	double stranded deoxyribonucleic acid
EDTA	-	ethylene-diamine-tetra- acetic acid
ELISA	-	enzyme linked immunosorbent assay
ENA	-	extractable nuclear antigen
ESR	-	erythrocyte sedimentation rate
FCS	-	foetal calf serum
FITC	-	fluorescein isothiocynate conjugate
FITC-GAM	-	fluorescein isothiocynate conjugated antihuman Ig G, A and M.
g	-	gravity
GS-ANA	-	granulocyte specific antinuclear antibody
ON-ANA	-	organ nonspecific
HBSS	-	Hank's balanced salt solution

HEp-2	-	human epithelial cell line
HIV	-	human immunodeficiency virus
HLE	-	human leucocyte elastase
IgA	-	immunoglobulin A
IgG	-	immunoglobulin G
IgM	-	immunoglobulin M
iu	-	international units
IIF	-	indirect immunofluorescence
kDa	-	Kilo-Dalton
Lf	-	lactoferrin
Lz	-	lysozyme
mag	-	magnification
MEM	-	minimal essential medium
min	-	minute
ml	-	millilitre
mM	-	millimole
μl	-	microlitre
MPO	-	myeloperoxidase
LUC	-	large unstained cell
P-ANCA	-	perinuclear antineutrophil cytoplasmic antibody
PAN	-	polyarteritis nodosa
cPAN	-	classical polyarteritis nodosa
mPAN	-	microscopic polyarteritis nodosa
PBS	-	phosphate-buffered saline
PCAB	-	parietal cell antibody
PR3	-	proteinase 3
RIA	-	radio-immuno-assay
RNP	-	ribonuclear protein
SMAB	-	smooth muscle antibody

Sm	-	Smith antibody
SS-a	-	Sjögren's syndrome associated antibody a
SS-b	-	Sjögren's syndrome associated antibody b
TNF- α	-	Tumour necrosis factor- α
U/ml	-	units per millitre
WG	-	Wegener's granulomatosis
X-ANCA	-	atypical antineutrophil cytoplasmic antibody

DAKO (Code No 520020.

Dakopatts pen for histochemistry.

Dakopatts A/S, Produktionvej 42, Postbox 1359, DK-2600,
Glostrup, Denmark.

Fetal Bovine Serum (FCS) (Cat. No. 200-6140 PG).

Gibco Laboratories, Grand Island NY, 14072, USA.

Fluoromount (Cat. No. 36098)

Gurr. BDH Laboratory Supplies, Broom Road, Poole, England.

Fluorescent Anti-Human Immunoglobulin (Wellcome MF 01)

Murex Diagnostics Limited, Central Road, Temple Hill, Dartford,
England, DA 5 LR.

Heparin (Pularin)

Glaxo (Pty) Ltd, Manchester Road, Wadeville, Transvaal, RSA.

Histopaque-1119 and Histopaque-1077.

Sigma Diagnostics, P O Box 14508, St Louis, MO 63178, USA.

Koki (Marking pen).

Yoken Mark II No 10, Japan.

Lab-Tek Chamber slide and Coverglass (178599 and 171080).

Nunc Inc, 2000 North Aurora Road, Naperville, IL 60566, USA.

Minimum Essential Medium (Eagle M4767)

Sigma, P O Box 14508, St Louis, MO 63178, USA.

Phosphate Buffered Saline (Dulbecco "A" Code BR14a)

Oxoid, Unipath Ltd, Basingstoke, Hampshire, England.

T.C.Hanks Solution

Difco Laboratories, Detroit, Michigan, USA.

PLATES

1. Photomicrograph C-ANCA	3
2. Photomicrograph P-ANCA	6
3. Photomicrograph X-ANCA	9
4. Photomicrograph X-ANCA (i)	10
5. Photomicrograph X-ANCA (ii)	11
6. Photomicrograph X-ANCA (iii)	12
7. Photomicrograph GS-ANA	13
8. 16 Well chamber slide (A-E)	24
9. Comparison of 16 well chamber slide to standard single slides	25
10. Photomicrograph C-ANCA 1 month/3 months	34
11. Photomicrograph P-ANCA 1 month/3 months	35
12. Photomicrograph depicting neutrophil granule spill	53
13. Photomicrograph Amoebic-associated C-ANCA	70
14. Photomicrograph Amoebae	71
15. Proteinase 3 ELISA test plate	74
16. Photomicrograph nuclear staining in a control	85

FIGURES

1.	Indirect Immunofluorescence Test (IIF)	2
2.	Absolute alcohol fixation of neutrophils and IIF	7
3.	Double density gradient, neutrophil separation	28
4.	Technicon H2 scattergram, normal differential	37
5.	Technicon H2 scattergram, MPO deficient	37
6.	Study population of patients with systemic vasculitis	40
7.	Demographic details of vasculitis-associated ANCA positive patients	42
8.	Patient characteristics of vasculitis-associated C and P ANCA positive patients	43
9.	Distribution of disease in C-ANCA positive patients	44
10.	Distribution of disease in P-ANCA positive patients	44
11.	P-ANCA in 10 patients with systemic vasculitis	45
12.	Disease spectrum in patients with ANCA	46
13.	ELISA proteinase 3 scattergram	73

TABLES

1. ANCA in ulcerative colitis. Summary of findings at the 5th International workshop on ANCA	50
2. Demographic details of 44 patients with ulcerative colitis	51
3. ANCA in 44 patients with ulcerative colitis	54
4. Demographic details of 49 Black HIV positive patients	59
5. Autoantibody and CD4 counts in 21 patients with ANCA	61
6. Comparison of helper cell counts and autoantibody findings in ANCA positive and ANCA negative HIV infected patients	62
7. Serial observations in patient S27	70
8. Absorption studies	72
9. Demographic details of 199 normal controls	84

INTRODUCTION

Friedrich Wegener first described the pathology of a granulomatous vasculitic disease in 1936. The following excerpt is from the last manuscript of the pioneer work that he presented at a symposium to honor his 83rd birthday. The symposium on Wegener's granulomatosis (WG) and related vasculitic syndromes was held in Zweibrücken in 1990 and the manuscript was translated by H. Lehman and N Rasmussen (Lehmann 1990).

In 1936 I (Friedrich Wegener) gave the first brief report, based on three post mortem examinations performed by myself, of a "new" and peculiar disease, which had not been recognized before. In 1939 I described this disease in detail and called it "rhinogenic granulomatosis". This paper is now considered a "classic". Since the fifties this "novel" disease is, in its generalized stage, clinically and anatomically characterized by a so called triad:

- 1. A granulomatous-necrotizing and ulcerative inflammatory process of the respiratory tract and internal organs.*
- 2. A necrotizing-granulomatous general vasculitis.*
- 3. A usually focal, necrotizing glomerulonephritis.*

Shortly after this presentation Dr Friedrich Wegener died with the knowledge of the discovery of an antibody associated with the disease he described 50 years earlier and that had been given his name.

Wegener's granulomatosis is often a diagnostic problem and until 10 years ago no specific laboratory test was available to assist in its diagnosis. In

1982, using an indirect immunofluorescent test Davies and co-workers reported autoantibodies directed against neutrophil cytoplasmic components in patients with necrotizing glomerulonephritis (Davies 1982). The impact of this observation became apparent only in 1985 when Van der Woude and colleagues noted that this autoantibody was present in 93% of patients they tested with a diagnosis of Wegener's granulomatosis. The initial report by Van der Woude was soon followed by extensive confirmatory studies by other workers (Gross 1986, Lüdemann 1987, Parleviet 1988). This new antibody was named ANCA, antineutrophil cytoplasmic antibody. In 1988 Falk demonstrated a different immunofluorescent ANCA staining pattern that was later to be called P-ANCA. The association of this perinuclear staining antibody was with patients with necrotizing glomerulonephritis and microscopic polyarteritis (Jennette 1991, Geffriaud-Ricouard 1993). P-ANCA has also been reported in 5% to 50% of patients with Churg Strauss syndrome (CSS) and in about 5% of patients with WG (Hoffman 1992). A year later yet another ANCA variation was described, this time in patients with inflammatory bowel disease, and this antibody was called X-ANCA (Targan 1989). ANCA's have proved to be of great value in the diagnosis and management of patients within the large spectrum of systemic vasculitis (Specks 1989 (1), Cohen-Tervaert 1990 (2), Savage 1990, Pettersson 1992).

The indirect immunofluorescence assay (IIF) was the first method used to detect ANCA and although there are many new techniques for antibody identification such as enzyme linked immunosorbent assay (ELISA), radioimmunoassay (RIA) and immunoblotting, the IIF method remains the accepted international gold standard. Five international workshops have been held since 1988 and consensus attained on both the categorisation and

the nomenclature of the various ANCA's. Using IIF on alcohol-fixed human neutrophils three different staining patterns can be identified: i the granular cytoplasmic pattern (C-ANCA) seen in Wegener's granulomatosis; ii the perinuclear pattern (P-ANCA) which is associated with necrotizing and crescentic glomerulonephritis and microscopic polyarteritis (mPAN) (Falk 1988). iii The third and unusual immunofluorescent staining pattern is a mixture of C and P-ANCA exhibiting a "snow storm" pattern and is called X-ANCA. The clinical association of this antibody is with a subgroup of patients with chronic inflammatory bowel disease and chronic active hepatitis (Targan 1989, Rump 1990, Cohen Tervaert 1992).

The target antigens for many of these ANCA's have been identified. The C-ANCA antigen is predominantly proteinase 3 (PR3), a serine protease found in the primary granules of the neutrophil (Goldschmeding 1989(1), Niles 1989). Recent molecular studies have indicated that several epitopes within the PR3 molecule are recognised and these differences may correlate with varied disease expression (Lockwood 1993). The major P-ANCA target specificity is myeloperoxidase (MPO), also a primary granule constituent, but other proteins such as human leucocyte elastase (HLE), lactoferrin (Lf), lysozyme (Lz) and cathepsin G (CG) have been implicated. X-ANCA associated antigens are as yet unknown.

Different immunoglobulin isotypes have been reported in the ANCA associated diseases. The majority of ANCA's in WG and mPAN are of the IgG isotype (Van der Woude 1989) however Jayne in 1989 reported three patients with pulmonary renal syndrome whose initial sera had IgM ANCA activity alone. All three of these patients later switched from IgM to IgG in keeping with the normal immune response. Patients who have simultaneous IgG and IgM have a marked predilection for pulmonary

haemorrhage (Esnault 1993). Adult Henoch-Schönlein purpura has been associated with the presence of IgA ANCA (Shaw 1992, Saulsbury 1991). Both the ANCA isotype and the antibody specificity seem to be important determinants of disease expression.

There has been speculation but no definitive proof as yet of the pathogenetic role of ANCA. The fact that disease recrudescence and remission go hand in hand with the presence and absence respectively of ANCA lends support to the fact that this autoantibody in the setting of systemic vasculitis is not an epiphenomenon (Van der Woude 1985, Van der Woude 1989, Kallenberg 1991, Hagen 1992). The pathogenesis of WG remains unclear but respiratory infection where large amounts of degranulating neutrophils are found, is thought to precipitate disease activity. *"In vitro"* studies have suggested different theories for the roll of ANCA in the pathogenesis and the histological findings in the systemic vasculitides. One theory is that cytokine, tumour necrosis factor- α (TNF- α) activated neutrophils causes translocation of proteases to the cell membrane, thus making them accessible to ANCA. The ANCA-neutrophil binding results in a neutrophil respiratory burst and degranulation, causing direct damage to the cytokine activated endothelial cells. Another suggestion is that endothelial cells express proteases on their membranes that lead to direct binding of ANCA with concomitant destruction of the blood vessel (Gross 1993(2)).

The introduction of the ANCA test in the Department of Medicine at the University of Natal medical school was stimulated by the advent of a severe multi-system disease in a colleague in 1987. The key publication by Van der Woude had appeared in the *Lancet* and a simplified version of the ANCA test was performed on this patient using a peripheral blood film as

substrate. The strong neutrophil cytoplasmic fluorescence facilitated a diagnosis and therapy was started which resulted in a lasting remission.

Interest in and usage of ANCA increased dramatically and samples in excess of 2000 have been processed in the author's laboratory. With such a new test the opportunity arose to join the exploration into disease associations of ANCA in the large teaching hospital, King Edward VIII, and the surrounding medical environment of Durban.

It soon became clear that the technique of the test should be modified and streamlined to overcome the cumbersome process of utilising one microscope slide loaded with substrate for each test and control sample. This led to the successful introduction of the 16 well chamber slide technique which has greatly simplified the screening process.

CHAPTER 1

THE INDIRECT IMMUNOFLUORESCENT ASSAY FOR THE DETECTION OF ANTINEUTROPHIL CYTOPLASMIC ANTIBODIES

1.1 INTRODUCTION:

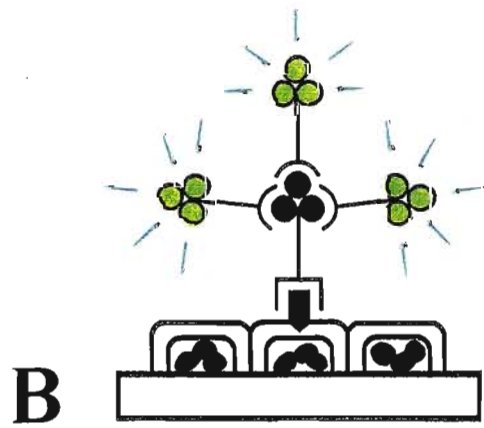
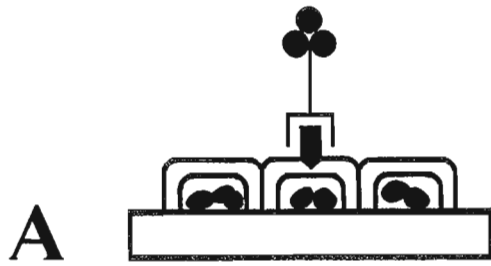
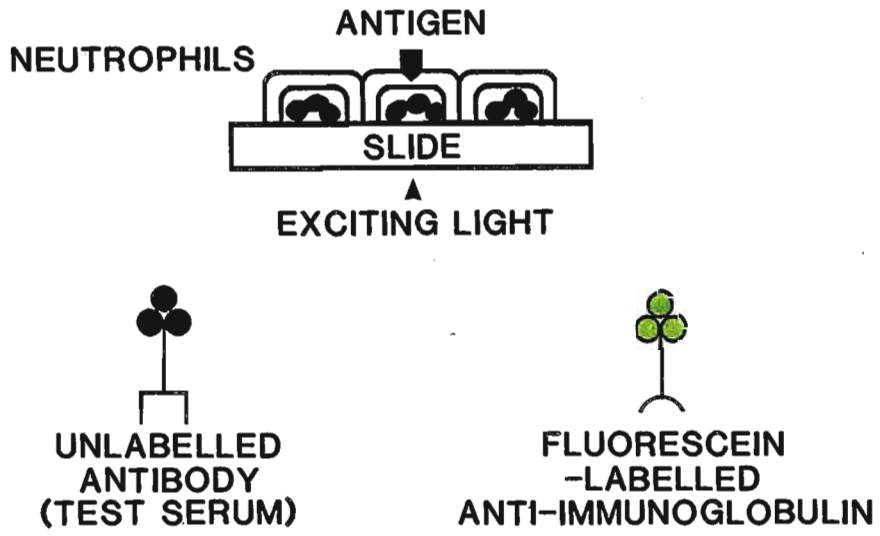
THE INDIRECT IMMUNOFLUORESCENT (IIF) TECHNIQUE

The coupling of fluorescent dyes like fluorescein to antibodies does not destroy their specificity. These antibody conjugates then combine with their corresponding antigens and can be visualised with a fluorescence microscope. In the indirect immunofluorescent test, a double layer technique, the unlabelled, unknown antibody is applied to the tissue section or cell substrate, (Fig 1 A), and then visualised by means of a fluorochrome conjugated anti-human globulin (Fig 1 B).

Using this technique with ethanol fixed human neutrophils as the substrate, four different immunofluorescent staining patterns can be identified from positive test samples ;

- 1.1.1 C-ANCA cytoplasmic antineutrophil cytoplasmic antibody
- 1.1.2 P-ANCA perinuclear antineutrophil cytoplasmic antibody
- 1.1.3 X-ANCA atypical antineutrophil cytoplasmic antibody
- 1.1.4 GS-ANA granulocyte specific antinuclear antibody

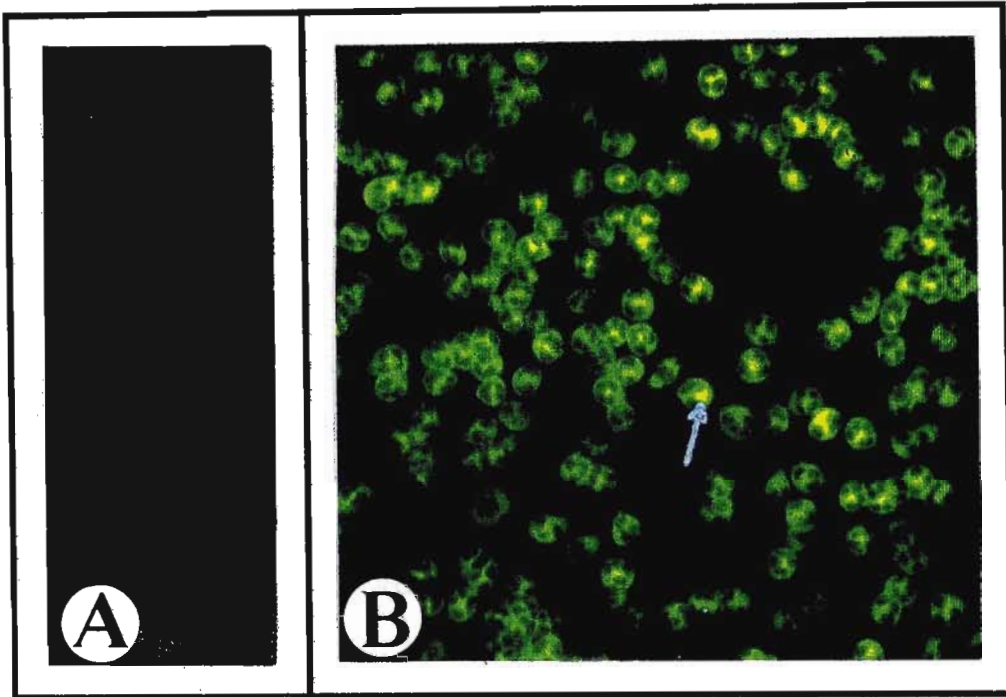
Fig 1 INDIRECT IMMUNOFLUORESCENT TEST (IIF)



1.1.1 C-ANCA

Photomicrograph of the C-ANCA, granular cytoplasmic immunofluorescent staining pattern showing perinuclear emphasis, on ethanol fixed neutrophils.

Plate 1



A: Normal serum negative. B: C-ANCA positive serum. (Mag. x 300)
→ perinuclear emphasis.

Following the description of the classical granular cytoplasmic staining of ANCA and its association with Wegener's granulomatosis (Van der Woude 1985) various workers investigated the specificity of this new antibody. Initially the autoantigen was thought to be alkaline phosphatase (Lockwood 1987) however this was disproved by three different groups (Rasmussen 1987, Gross 1987, Goldschmeding 1987).

In 1989 a novel myeloid serine protease, Proteinase 3 (PR3) located in the primary azurophilic granules of the neutrophil was identified as the C-ANCA target antigen by two different groups (Goldschmeding 1989 (2), Goldschmeding 1989 (3), Niles 1989). Confirmation by other workers followed shortly afterwards (Lüdemann 1990, Jennette 1990, Bini 1992). This 29 kDa multifunctional protein PR3 was sequenced and renamed, "Wegener's autoantigen" by Jenne (Jenne 1990).

The strong association of C-ANCA with Wegener's granulomatosis has been extensively documented (Van der Woude 1985, Cohen-Tervaert 1989, Gross 1986, Harrison 1989, Nölle 1989, Parlevliet 1988, Specks 1989 (2)).

In various studies the specificity of C-ANCA for biopsy proven Wegener's granulomatosis was shown to be around 90%. Depending on the extent and the activity of the disease phase, the sensitivity varied from 50% in patients with early disease, and close to 100% in patients with active, generalised systemic disease. In most patients on treatment or in complete remission, ANCA is either absent or the antibody titre is reduced (Van der Woude 1985, Nolle 1989, Cohen-Tervaert 1990 (1)). However in some patients titres do not correlate with disease activity (Hoffman 1992, Kerr 1993).

Although the majority of patients with C-ANCA have Wegener's granulomatosis the antibody has been found in small numbers of patients with closely related vasculitic disorders such as microscopic polyarteritis (mPAN), Churg-Strauss Syndrome (CSS) and classic polyarteritis nodosa (cPAN) (Cohen-Tervaert 1989, Falk 1990, Bleil 1991).

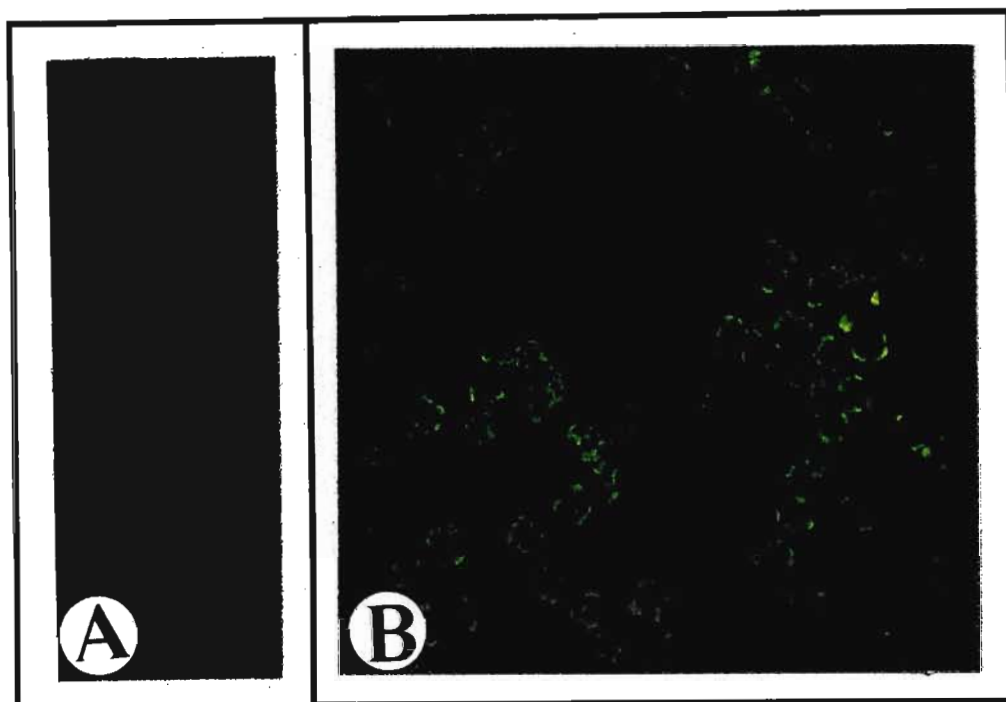
"False positive" C-ANCA's have been reported in infections such as symptomatic human immunodeficiency virus (HIV) infection (Koderisch 1990, Davenport 1991, Klaasen 1990, Klaasen 1992), in pneumonia and infections in cystic fibrosis (Efthimiou 1991).

A new C-ANCA (Proteinase 3 specific) association is documented in this thesis in patients with invasive amoebiasis (Chapter 2.4).

1.1.2 P-ANCA

Photomicrograph of the P-ANCA, perinuclear immunofluorescent staining pattern on ethanol fixed neutrophils.

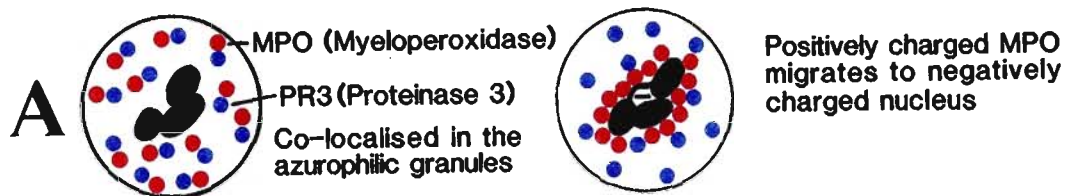
Plate 2



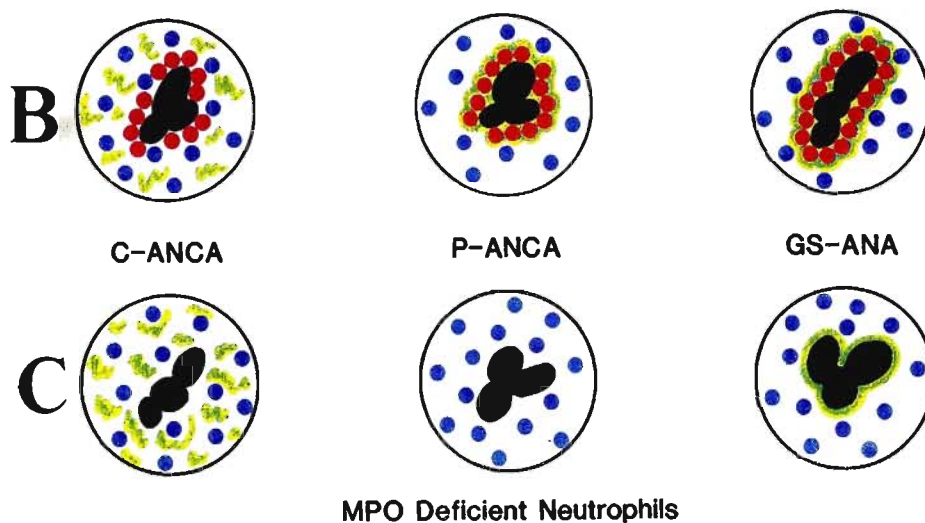
A: Normal serum negative. B: P-ANCA positive serum.(Mag. x 300)

The P-ANCA staining pattern illustrated above is the fortuitous result of a fixation artefact. When neutrophils are dried on slides, both the cell and granule membranes become permeable. During subsequent alcohol fixation, soluble positively-charged neutrophil granule constituents such as myeloperoxidase, elastase, cathepsin G and lactoferrin translocate and bind to the negatively charged neutrophil nucleus (Falk 1988), (Fig 2 A).

Fig 2 A,B&C

ABSOLUTE ALCOHOL FIXATION OF NEUTROPHILS AND IIF.

INDIRECT IMMUNOFLUORESCENCE



Falk in 1988 first showed that the P-ANCA staining pattern was associated with autoantibodies directed against myeloperoxidase (Fig 2 B). To confirm the specificity of MPO P-ANCA the serum sample is tested on a myeloperoxidase deficient neutrophil substrate. An MPO specific P-ANCA

will be negative on this substrate (Fig 2 C). Although most P-ANCA's are specific for MPO (Jennette 1990), HLE, CG, Lf, beta-glucuronidase and Lz have also been shown to be P-ANCA target antigens (Lesavre 1991, Halbwachs-Mecarelli 1992, Mårtensson 1992, Lesavre 1993). Further antigen specificities are still to be defined as some P-ANCA positive sera are non reactive using ELISA's and immunoblots for all the currently known P-ANCA target autoantigens, hence the list of P-ANCA specificities is likely to grow.

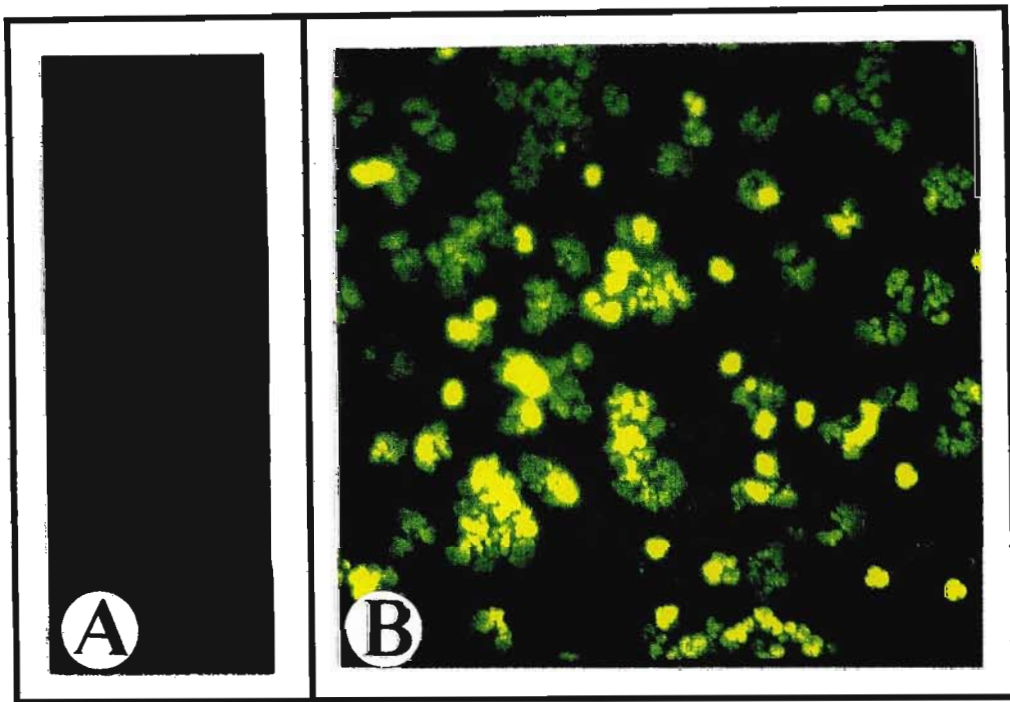
P-ANCA is found in many vasculitides, including segmental necrotising glomerulonephritis, mPAN, CSS in a small number of patients with PAN and WG (Jennette 1989, Chapter 2.5 page 78). P-ANCA has also been reported in patients with chronic inflammatory rheumatic disorders ie; rheumatoid arthritis, Still's and Felty's syndromes, systemic lupus erythematosus (SLE), mixed connective tissue disease, Sjögren's syndrome and in inflammatory bowel diseases (Gross 1991, Juby 1992, Savige 1991, Saxon 1990, Duerr 1991 (1), Duerr 1991 (2)).

Myeloperoxidase and HLE specific P-ANCA's have been detected in patients with infections such as post streptococcal glomerulonephritis, Legionnaires' disease and atypical pneumonia (Gallicchio 1991). Cornely in 1993 reported the presence of P-ANCA by immunofluorescence in thirty eight of sixty four HIV infected patients with symptomatic disease. Drug induced P-ANCA has been documented, the drugs responsible being hydralazine, clozapine and L-tryptophan (Nässberger 1990, Ålmroth 1992, Jaunkalns 1992, Cilursu 1991).

1.1.3 X-ANCA

Photomicrograph of the X-ANCA immunofluorescent staining pattern on ethanol fixed neutrophils.

Plate 3



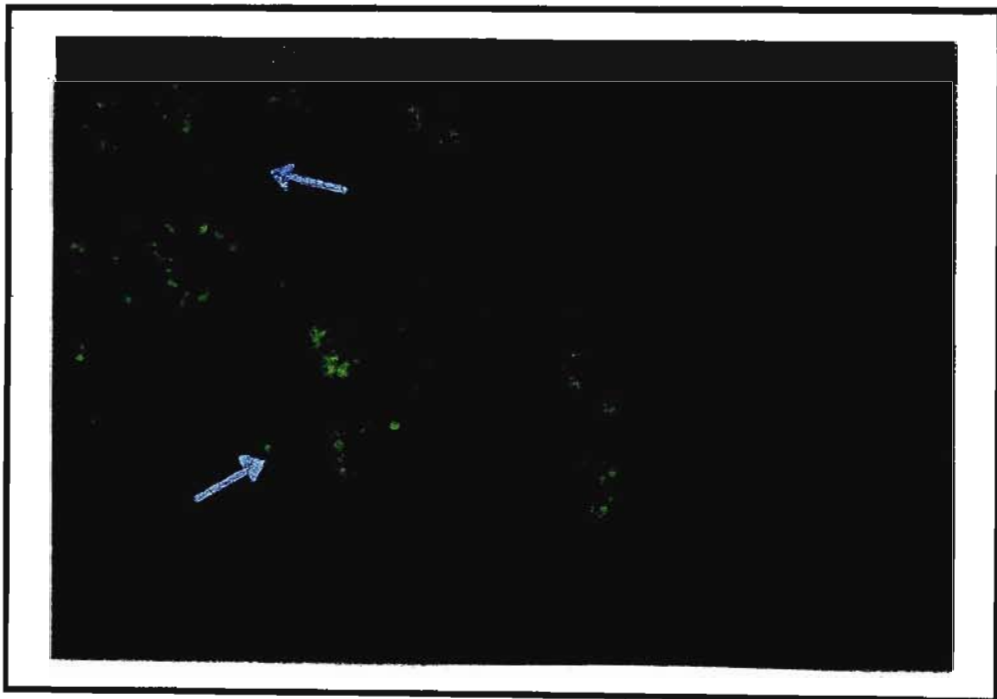
A: Normal serum negative. B: X-ANCA positive serum.(Mag. x 300)

X-ANCA, also called A-ANCA, (atypical ANCA) has the appearance of a combination of C and P-ANCA resulting in a "snow storm" pattern on indirect immunofluorescence was first documented by Rump in 1990. He called it a new type of P-ANCA but X or A-ANCA has been more recently accepted as the nomenclature of choice (Gross 1993 (1)). When the author first encountered this antibody in 1991 it was named M-ANCA, mixed ANCA, a mixture of C and P-ANCA.

The clinical associations of this antibody are subgroups of patients with chronic inflammatory bowel disease, primary sclerosing cholangitis and patients with autoimmune hepatitis (Rump 1990, Cohen-Tervaert 1992). The target antigen involved with this staining pattern is not yet known.

The following photomicrographs show some unusual, atypical X-ANCA staining patterns encountered by the author that do not conform to the "snow storm" mixed C and P-ANCA pattern described in the literature. No doubt new specificities will soon emerge and new disease associations will be made.

Plate 4

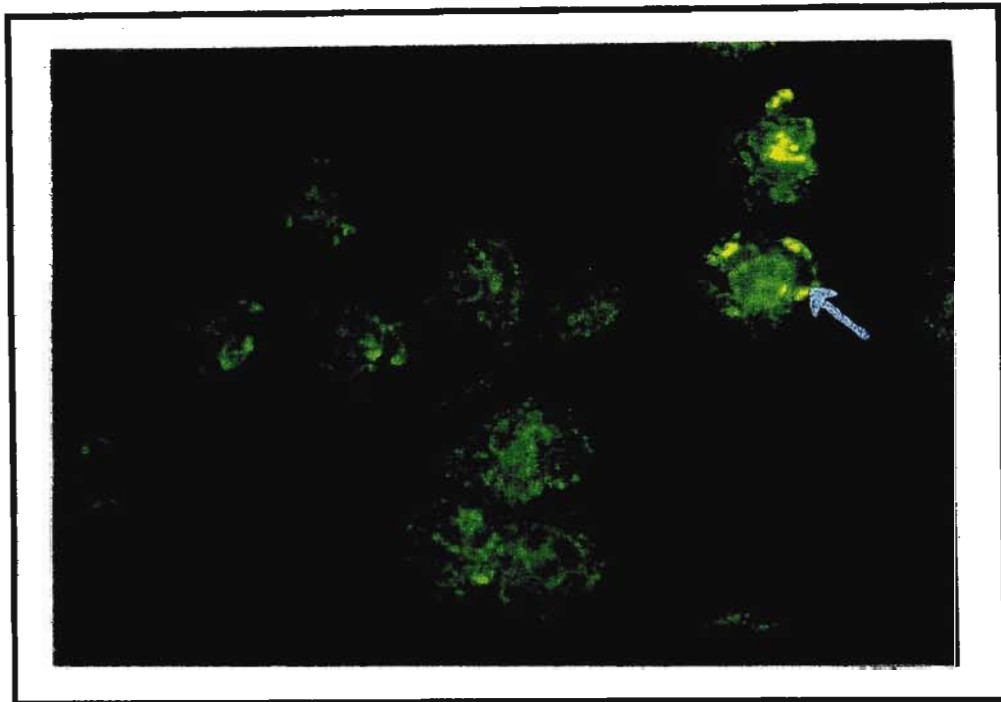


X-ANCA → granule "spill" (Mag. x 800)

X-ANCA found in a 69 year old woman who presented with Sjögren's syndrome. The ANA was described as homogeneous with a ground glass

appearance. Tests for antibodies specific for double stranded DNA (ds-DNA), Sjögren's syndrome associated antibody a (SSa), Sjögren's syndrome associated antibody b (SSb), Smith (Sm) and ribonuclear protein (RNP) were negative. Both nuclear and granular cytoplasmic staining is apparent with membrane disruption of all the neutrophils resulting in fluorescent staining granule "spill".

Plate 5

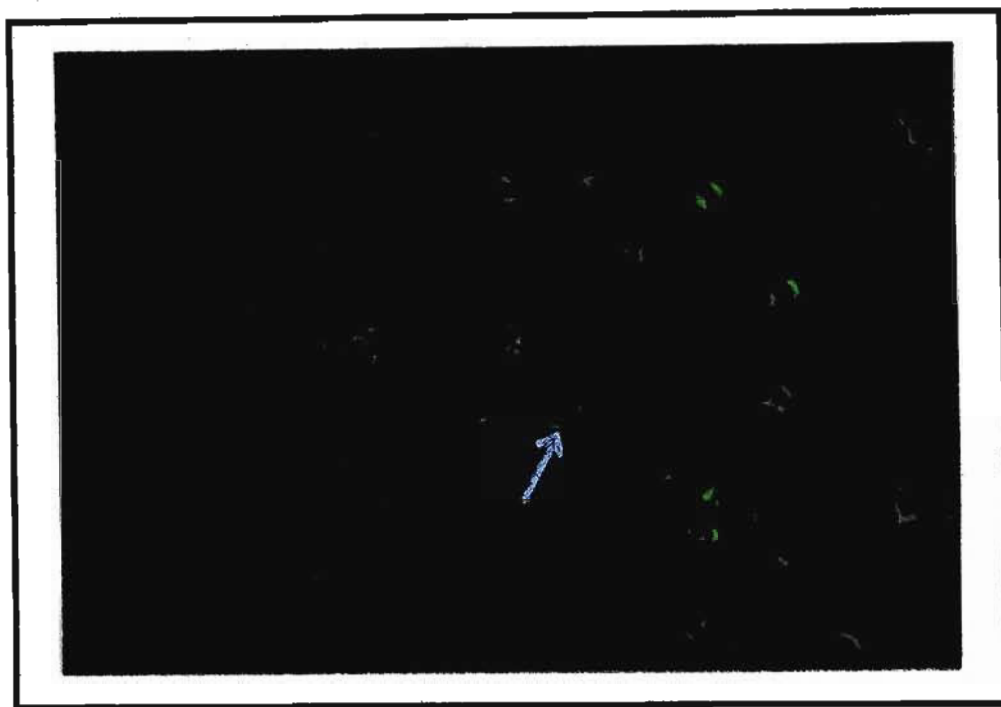


X-ANCA → irregular patches of intense fluorescent staining (Mag. x 800)

X-ANCA found in a 26 year old woman with a diagnosis of SLE. Screening for antinuclear antibody (ANA) on a composite block tissue section and a human epithelial cell line (HEp-2) was negative. Ribosomal cytoplasmic staining was noted on the HEp-2 cell substrate. Tests for antibodies reacting

with ds-DNA, SSb, Sm and RNP were negative, however using an ELISA assay, antibodies specific for SSa were found. Definite perinuclear fluorescence is present as well as granular cytoplasmic staining. In many neutrophils irregular patches of intense fluorescent staining can be seen.

Plate 6



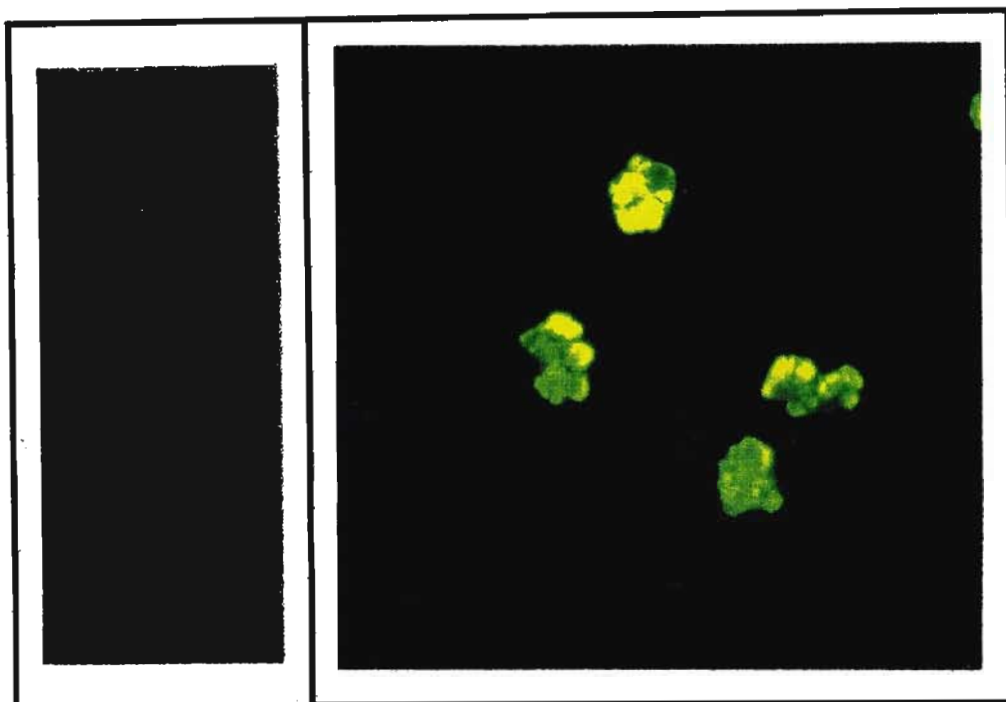
X-ANCA → non uniform perinuclear staining (Mag. x 800)

X-ANCA found in a 10 year old black female (Clinical studies Case 13, Chapter 2.6). The differential diagnosis in this child was; hyper-eosinophilic syndrome or PAN with hepatitis B antigenaemia. All tests for ANA were negative. Areas of perinuclear fluorescent staining are evident however there is no uniformity of the perinuclear staining as found in the typical P-ANCA staining pattern.

1.1.4 GS-ANA

Photomicrograph of the granulocyte specific antinuclear antibody (GS-ANA), immunofluorescent staining pattern on ethanol fixed neutrophils.

Plate 7



A: Normal serum negative. B: GS-ANA positive serum.(Mag. x 800)

In 1959 Calabresi reported on fluorescent antibody studies in leucopenic patients . He described this antibody as one with affinity for nucleoproteins of neutrophils alone. The staining patterns in the photomicrographs reproduced in his article 34 years ago are identical to those which are currently called GS-ANA or P-ANCA. The serum samples were from one patient with systemic lupus erythematosus and one with Felty's syndrome. In 1964 this antibody was again reported in a patient with Felty's syndrome (Faber1964). Granulocyte

specific antinuclear antibodies were thoroughly investigated by Wiik in patients with rheumatoid arthritis (Wiik 1980).

Using alcohol fixed neutrophils the immunofluorescent staining pattern of P-ANCA and GS-ANA look identical. Various methods are used to distinguish between the two. When tested on formalin fixed neutrophils, P-ANCA exhibits a cytoplasmic immunofluorescent staining pattern as the granule constituents remain *in situ* with this method of fixation whereas GS-ANA still shows nuclear fluorescence. (Cross linking fixation is thought by some workers to damage nuclear proteins and formalin is not recommended as a standard fixative for an ANCA substrate). Workers have also demonstrated that in patients with ulcerative colitis, autoimmune liver diseases and rheumatoid arthritis, (Savige 1991, Kallenberg 1992, Mulder 1993) the perinuclear pattern seen on ethanol-fixed neutrophils turns into a cytoplasmic pattern when neutrophils are fixed with paraformaldehyde. Using an MPO deficient neutrophil substrate a worker is able to distinguish between MPO specific P-ANCA and GS-ANA but not between the other P-ANCA specificities such as Lf, HLE and CG. Myeloperoxidase specific P-ANCA will show no immunofluorescent staining on this substrate while the GS-ANA and the other P-ANCA specificities still exhibit nuclear fluorescence (Figure 2 B,C).

The clinical association of this antibody overlaps with that of P-ANCA and X-ANCA and is reported in autoimmune chronic active hepatitis. (Cohen-Tervaert 1992) There are numerous reports of P-ANCA/GS-ANA association in patients with rheumatoid arthritis and Felty's syndrome (Wiik 1980, Juby 1992, Mulder 1993).

The exact specificity of GS-ANA remains controversial. Unlike ANA which is an organ non specific nuclear antibody (ON-ANA), GS-ANA is said to be specific for the nuclei of neutrophils alone (Wiik 1980). In contrast however since 1989, several groups have demonstrated that most if not all, GS-ANA are in fact recognising cytoplasmic antigens (Kallenberg 1992).

1.2. BUFFY COAT SMEAR NEUTROPHIL SUBSTRATE

1.2.1 PREPARATION

MATERIALS

1. 10 ml of ethylene-diamine-tetra-acetic acid (EDTA) anticoagulated blood from a healthy group O positive volunteer.
2. Alcohol-cleaned standard glass microscope slides.
3. Foetal Calf Serum (FCS) (Gibco)
4. Preservative-free heparin (Pularin Glaxo) diluted in distilled water to a concentration of 200 iu/ml
5. Absolute alcohol pre-cooled at -20°C in a standard domestic freezer.

METHOD

1. Avoiding bubbles pipette ethylene-diamine-tetra-acetic acid (EDTA) blood into Westergren ESR tubes.
2. Centrifuge the tubes at $1400 \times g$ for 30 minutes.
3. Pipette off and discard the plasma.
4. Gently remove the buffy coat at the red cell interface with a plastic pasteur pipette.

5. Suspend the leucocytes in 1ml of FCS with 20 μ l of heparin to prevent clumping of the white cells.
6. Adjust the cells to a count of 45×10^6 /ml in the FCS/heparin diluent.
7. Make thin smears on the prepared microscope slides.
8. Air dry the slides for 2 hours at room temperature.
9. Fix the smears for five minutes in absolute alcohol pre-cooled at -20°C
10. Allow the slides to dry and store them in slide boxes at -20°C .

1.2.2 INDIRECT IMMUNOFLUORESCENT ASSAY

MATERIALS

1. Buffy coat preparations of human leucocytes on glass microscope slides.
2. Glass coverslips.
3. Dako marking pen.
4. Black koki glass marking pen
5. Phosphate buffered saline (PBS) 0,05M phosphate-0,1 NaCl pH 7,2.

6. Sera: test and controls; C and P-ANCA positive and normal serum.
7. Fluorescein-conjugated sheep polyvalent anti-human globulin (anti-IgG, IgA and IgM, (FITC-GAM). Wellcome MF01 (Murex).
8. Fluoromount (Gurr).
9. Moist chamber.
10. Stainless steel container with a magnetic stirrer.

METHOD

1. Remove the buffy coat prepared slides from the deepfreeze and dry them under a fan for 3 minutes.
2. Mark the test area with a Dako pen (a circle of about 1,5cm diameter). This forms a "well" to prevent the serum sample from running across the slide.
3. Dilute the test and control serum samples 1 in 10 in PBS (50 μ l serum +450 μ l PBS).
4. Mix the diluted serum using a pipette and gently cover the marked area on the slide with approximately 200 μ l of each sample. (All test and control samples are tested in duplicate).

5. Incubate the slides in a moist chamber for 30 mins at room temperature.
6. Very gently wash off the serum from each slide with PBS delivered from a wash bottle with a nozzle tube, then wash the slides in PBS in a stainless steel container gently stirring with a magnetic stirrer.
7. Prepare a 1 in 20 dilution of the FITC-GAM in PBS.
8. Shake each slide to remove the excess buffer and add 200 μ l of the conjugate to cover the marked area on each slide.
9. Incubate in a moist chamber for 30 minutes at room temperature.
10. Wash the slide as in step 6.
11. Shake off the excess buffer and mount with the mountant, (Fluoromount), and the appropriate sized coverslip.
12. Outline the test area from underneath the slide with a black koki marker to facilitate finding the test area when examining the slides.
13. Examine the neutrophils under a UV microscope at 200x and 400x magnification.

IMPORTANT NOTE. *Avoid complete drying of the slides during any step of the staining procedure.*

1.3 DEVELOPMENT OF A NEW INDIRECT IMMUNOFLUORESCENT METHOD. 16 WELL CHAMBER SLIDE

1.3.1 INTRODUCTION

The first method used to detect ANCA was the indirect immunofluorescence assay, originally applied for the detection of GS-ANA (Wiik 1980) and it is still used in the same way today.

There have been five international workshops on ANCA to standardise the interpretation and the application of the various techniques used for the identification of these antibodies. At present the indirect immunofluorescent technique with alcohol fixed intact neutrophils as the substrate is the most widely used and is accepted as the "gold standard" (Wiik 1989, Gross 1993 (1)). At the first workshop in Copenhagen in 1988 Wiik proposed a standard procedure for the IIF detection of these antibodies. The procedure is summarised below.

Cell source Human donor peripheral blood with leucocyte preparation carried out immediately.

Cell substrate Whole leucocyte population including a small proportion of contaminating red cells.

Anticoagulant Heparin with differential centrifugation to eliminate platelets, or defibrination.

Sedimentation agent Methyl cellulose with hypaque.

Washing medium Phosphate buffered saline pH 7,4 containing 1% human serum albumin. Two washes.

Leucocyte deposition on slides Cyto centrifugation or smearing techniques.

Fixation 96-99% ethanol at 4°C for 5 minutes with quick drying.

Patients serum Dilute 1 in 20 in phosphate buffered saline.

Conjugate Rabbit IgG specific for human gamma chains diluted 1 in 25 to 1 in 50 in PBS.

Microscope Epi-illumination with a relatively narrow band FITC primary interference filter.

At the following four workshops the IIF assay was still favoured and has remained the gold standard for screening for the presence of ANCA. (Gross 1993 (1))

1.3.2 BACKGROUND

In the author's laboratory between 1987 and 1991 buffy coat leucocyte smears (Chapter 1.2) were used as the source of the neutrophil substrate for the indirect immunofluorescent assay. Unfortunately access to a cytocentrifuge was not possible so this had to be the method of choice.

The buffy coat smear method had many disadvantages. It necessitated one slide per test; hence to test 5 patients and three controls in duplicate 16 slides were required. As the routine requests for this test increased it became unmanageable. The technical steps were difficult and the washing procedures long and unsatisfactory. Although the same source of blood was used for the substrate throughout the first four years there were qualitative differences from batch to batch and even differences between slides within the same batch of smears.

Chamber slide culture vessels have been used extensively in tissue culture laboratories for *in situ* culture analysis. A new 16 well chamber slide was introduced by NUNC in 1992 designed for use with standard eight channel dispensers and aspirators for quick filling and replenishment of media for tissue cultures (Plate 8). It was decided to experiment with these chamber slides as an alternative to the buffy coat smears. A chamber slide 16 IIF method was successfully developed using pure neutrophils as the substrate. (Chapter 1.3.3).

Many advantages of this new technique were found.

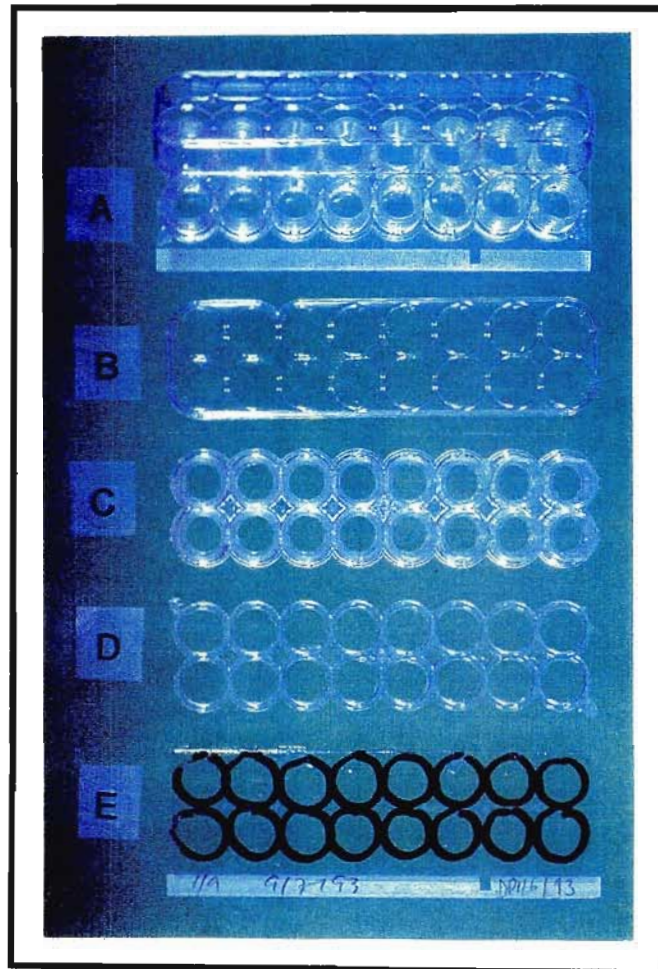
1. Cell morphology of the attached neutrophils is well maintained and the various staining patterns are easily identified.

2. Reading of the results is expedited by having 16 tests on a single slide, allowing easy reference to the controls (Plate 9).
3. The technical steps are much simpler and faster.
4. Titration of antibody activity is easily accomplished.
5. Relatively small numbers of substrate cells are needed, 20ml of blood provides neutrophils for 10 chamber slides or 160 tests.

Before introducing this method into the laboratory for use as the routine substrate for the IIF ANCA assay, 96 stored samples of known positive sera and negative controls were tested in parallel with the buffy coat smear substrate. The results with the two methods were in complete agreement. The morphology of the neutrophils in the chamber slides was far superior to that of the buffy coat, facilitating the reading and identification of the different fluorescent staining patterns.

The majority of the tests carried out in this study were performed using the 16 well chamber slide neutrophil preparations.

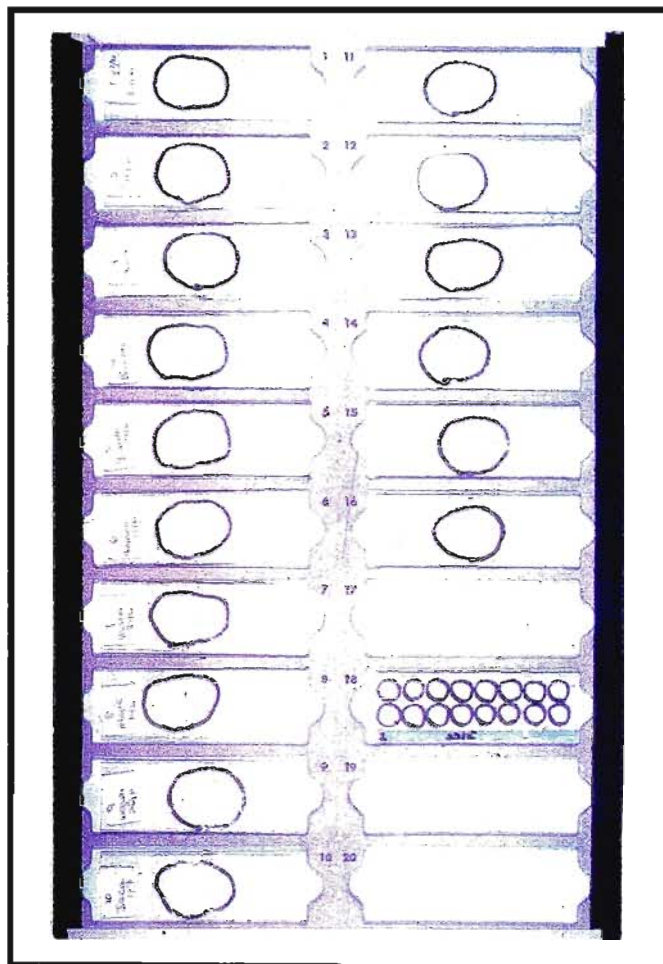
Plate 8



16 Well Chamber Slide (A-E)

- A. Composite 16 well chamber slide
- B. Lid
- C. Detachable plastic wells
- D. Rubber sealing gasket
- E. Glass slide

Plate 9



Comparison of 16 well chamber slide to standard single slides.

1.3 PREPARATION

MATERIALS

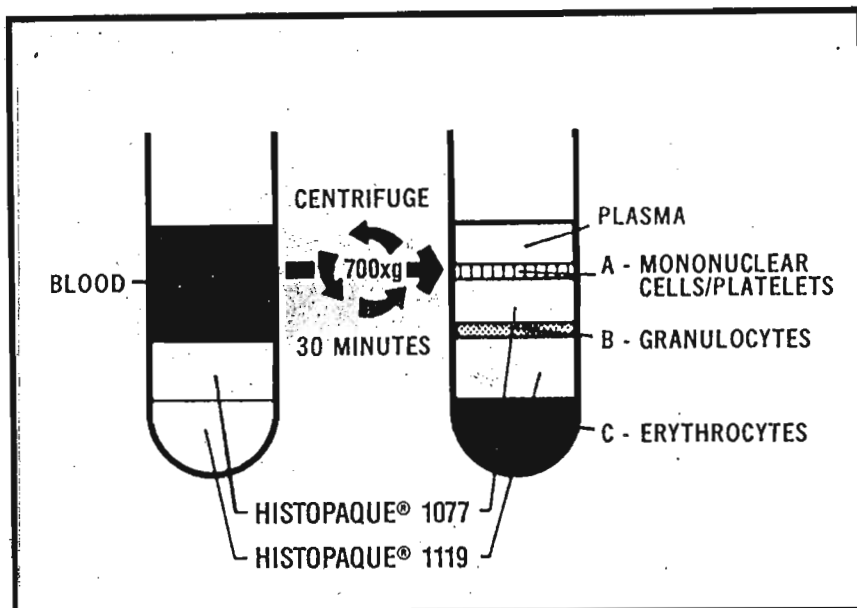
1. 20ml of venous blood was drawn from a healthy group O positive volunteer, into preservative free heparin (Pularin Glaxo) 20 iu heparin/ml blood.
2. Lab Tek 16 well chamber slide 178599.
3. Hank's balanced salt solution (HBBS) (Oxoid).
4. Eagles minimum essential medium (MEM) (Sigma).
5. Foetal calf serum (FCS) (Gibco).
6. Histopaque-1119 and Histopaque-1077 (Sigma).
7. 15ml plastic tissue culture tubes (NUNC).
8. Repeating Eppendorf or multichannel pipette.
9. Humidified 37°C incubator with 5% carbon dioxide in air.
10. 20ml syringe with a 21 guage needle.
11. Absolute alcohol pre-cooled at -20°C in a standard domestic freezer.

12. Storage container with a firm sealing lid (Tupperware).
13. Dessicant.

METHOD (Böyum 1968 (1), Böyum 1968 (2))

1. Dilute the heparinised blood 1+1 in HBSS.
2. Add 3,5ml of Histopaque-1119 to each of the tissue culture tubes. (Six tubes are needed for 20ml of blood).
3. Carefully layer 3,5ml of Histopaque-1077 onto the Histopaque-1119. Hold all the tubes to the light to check that the gradient line is clearly visible.
4. Carefully layer 6ml of the diluted heparinised blood onto the upper solution in the tissue culture tube.
5. Centrifuge the tubes at 700 x g for 30 minutes at room temperature.
6. Carefully remove the tubes from the centrifuge. One distinct layer at the upper 1077 interface can be seen. This is the mononuclear cell interface. The layer at the second, 1119 interface is indiscernable and blurred, contrary to the information provided on the Histopaque manufacturers package insert (Fig 3). Remove the cells from and into the second (1119) interface with a plastic pasteur pipette.

Fig 3



Double density gradient, neutrophil separation.

NOTE. *The author's experience with this technique has shown that without exception there has never been a clear neutrophil layer at the 1119 interface. Initially all the cell preparations were checked for neutrophil purity by smearing and staining the harvested cells, identifying and counting them under light microscopy. Neutrophil purity ranged from 95% to 98% in these preparations.*

7. Wash the harvested cells once in Eagles MEM at 350 x g for 7 minutes.
8. Very gently resuspend the cell button in Eagles MEM with 10% FCS.
9. Adjust the cell count to $0,5 \times 10^6$ /ml with Eagles MEM with 10% FCS.

NOTE. *Various concentrations of neutrophils were added to the chamber wells ranging from $2,0 \times 10^6/\text{ml}$ to $0,25 \times 10^6/\text{ml}$. $0,5 \times 10^6/\text{ml}$ was found to be the most suitable, with an even spread of cells and approximately 100 cells per microscope field at 200 x magnification.*

10. Add 200 μl of the cell suspension to each chamber well, mixing the suspension regularly to ensure cell number uniformity. Cover the chambers with the matching chamber lid. ($1,0 \times 10^5$ cells /well).
11. Incubate the chambers at 37°C for one hour under optimal tissue culture conditions i.e. humidified incubator with 5% CO₂ in air.
12. After one hour examine the wells using an inverted phase contrast microscope to check the attachment of the neutrophils to the surface of the slide.
13. Carefully remove the supernatant from each well with a syringe and a 21 gauge needle.

NOTE. *Different methods for removing the supernatant were compared, (a) simply throwing off the supernatant, (b) sucking the supernatant off with an ELISA plate washer and (c) the syringe and needle method. The syringe and needle method was the method of choice as this caused the least disturbance to the neutrophil "carpet".*

14. Invert the chamber slide and gently pat dry on a tissue.

15. Air dry the neutrophils for 2 hours at room temperature.
16. Fix the neutrophils with pre-cooled ice cold absolute alcohol for 5 minutes (200 μ l/well).
17. As soon as the cells have dried store the chambers at -20°C in a sealed container with a dessicant.

20ml of blood yields neutrophil substrate for 10 chambers, 160 tests.

1.3.4 INDIRECT IMMUNOFLUORESCENT ASSAY. 16 WELL CHAMBER SLIDE

MATERIALS

1. Pure neutrophil preparations in the multiwell chamber 16 slide.
2. Glass coverslips 22x74mm (Lab Tek 171080).
3. Black koki glass marking pen.
4. PBS.
5. Sera: test and controls; C and P-ANCA positive and normal serum.
6. FITC-GAM.
7. Fluoromount.
8. Moist chamber.
9. Repeating Ependorff or any standard eight channel dispensing and aspirating pipette.

METHOD

1. Remove the chamber slide from storage in the sealed container at -20°C.
2. Dry the chamber slide under a fan at room temperature for 3 minutes.
3. Dilute the test serum samples and the appropriate controls 1 in 10 in PBS (50µl serum + 450µl PBS).
4. Mix the diluted serum with a pipette and place 200µl in each well. (All test and control samples are tested in duplicate).
5. Cover the chambers with the matching lid and incubate them in a moist chamber for 30 minutes at room temperature.
6. Invert the chamber slide, throwing off the test samples and flick to remove the excess fluid.
7. Wash the chambers with 250µl of PBS/well throwing off the PBS and flicking the chamber between each of the five washes.
8. Prepare a 1 in 40 dilution of the FITC-GAM in PBS.

NOTE. *In the author's laboratory the fluorescein labelled anti-human globulin has always been used at 1 in 20 dilution in PBS. In an attempt to trim expenditure in this assay a 1 in 40 dilution of the FITC-GAM was compared with the 1 in 20 dilution. Sixty four samples including controls*

were tested in parallel with the two dilutions of the conjugate. No difference in either the presence, staining pattern or intensity of the fluorescence in the positive samples was noted, nor was there any difference in the background "glow" of the negative samples.

9. Add 200 μ l of the FITC-GAM to each well.
10. Cover and incubate the chamber in a moist container for 30 minutes at room temperature.
11. Repeat steps 6 and 7.
12. Mark the circles of the 16 wells on the underside of the slide with a black koki pen. This facilitates finding the wells when examining the slides.
13. Remove the partitioned chambers and sealing gasket (Plate 5 B andC).
14. Pipette one drop of mountant on to each marked well of the slide and cover with the matching long coverslip.
15. Examine under a UV microscope at 200x and 400x magnification.


IMPORTANT NOTE. *Avoid the complete drying of the chamber wells during any step of the staining procedure.*

1.3.5 STORAGE

The recommended storage time at -20°C of the different neutrophil substrates for the indirect immunofluorescent test varies from four to eight weeks. (Wiik 1989 and Venning 1990). The multiwell chamber slides have been stored for as long as three months with no deterioration in either the neutrophil morphology or the intensity of the fluorescent signal.

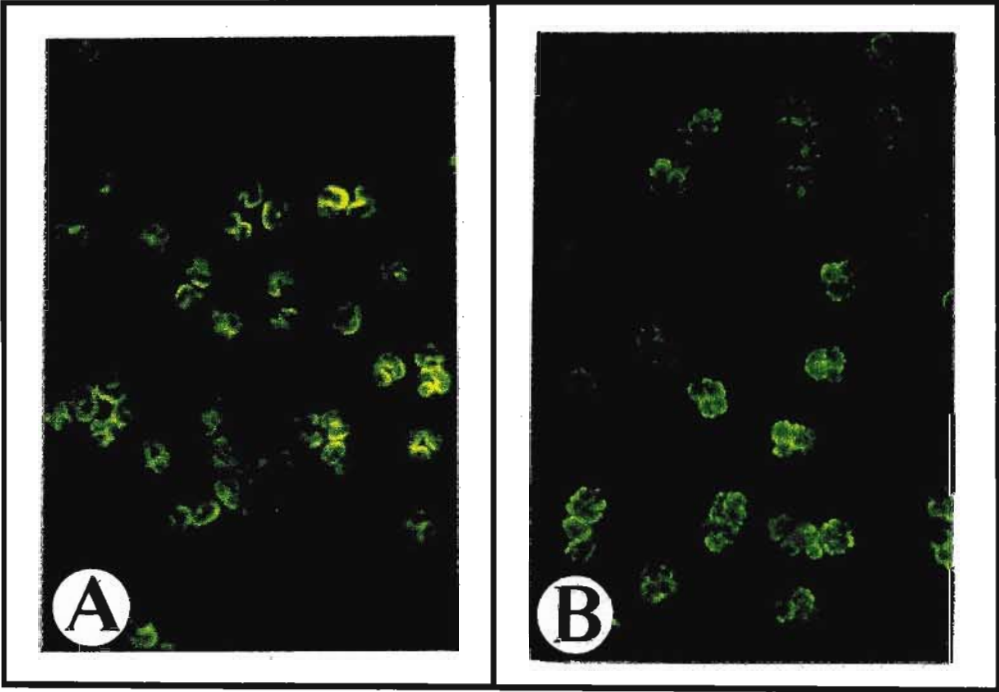
The following photomicrographs show the C and P-ANCA fluorescent patterns on two substrates, stored for one month and three months, testing the same serum samples on the same day (Plate 10 and Plate 11).

Plate 10



A: C-ANCA (01/06/93) B: C-ANCA (17/08/93) (Mag. x 300)

Plate 11



A: P-ANCA (01/06/93) B: P-ANCA (17/08/93) (Mag. x 300)

1.4 PREPARATION OF A MYELOPEROXIDASE DEFICIENT NEUTROPHIL SUBSTRATE

1.4.1 INTRODUCTION

Homozygous hereditary myeloperoxidase deficiency, probably an autosomal recessive disorder occurs in approximately 1 in 3000 individuals (Nauseef 1988).

A private pathology laboratory in Durban uses the Technikon H2 for automatic full blood counting using flow cytochemistry. In this system neutrophil peroxidase in the presence of hydrogen peroxide and an appropriate electron receptor chromogen, develops a darkly-coloured material which precipitates in the cells. With the use of electronic thresholds to separate the cell types passing through the flow cell, a scattergram is generated and cell differentiation accomplished (Fig 4). The neutrophils of a myeloperoxidase deficient individual will therefore not appear in the neutrophil area of the scattergram, (Fig 5), and are counted as large unstained cells (LUC) . A manual differential count is then done on a stained blood smear and the neutrophils are easily identified and enumerated.

Fig 4

TECHNIKON H2 SCATTERGRAM OF NORMAL NEUTROPHILS

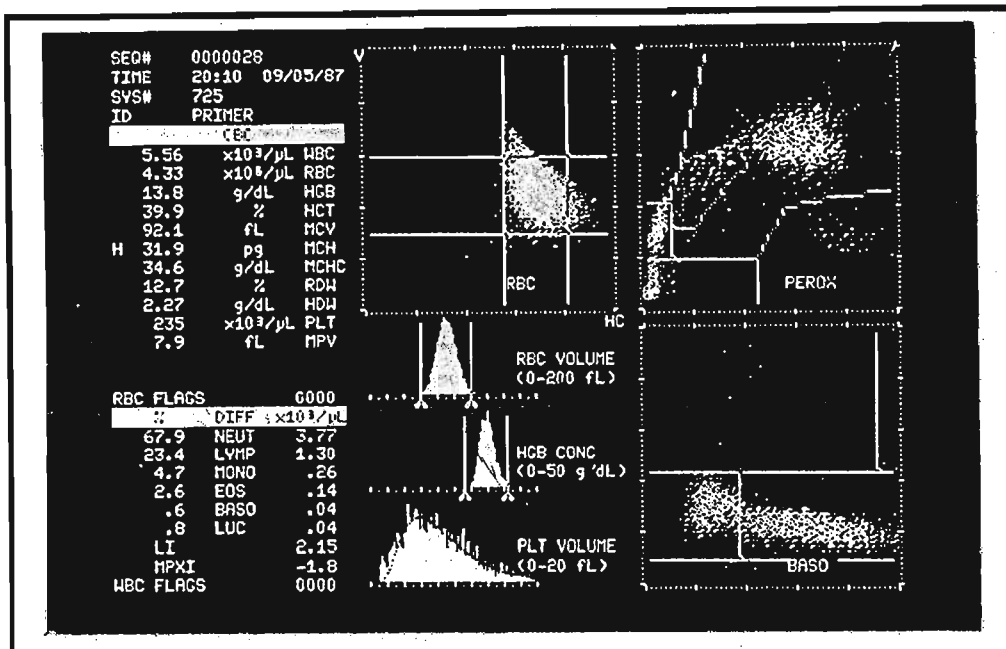
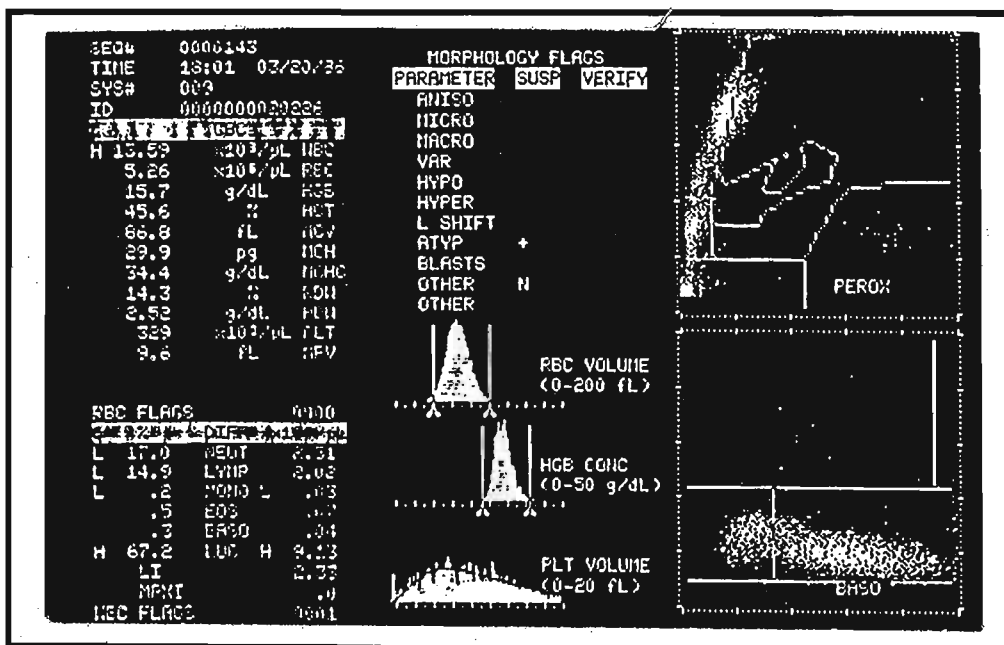


Fig 5

TECHNIKON H2 SCATTERGRAM OF MYELOPEROXIDASE DEFICIENT NEUTROPHILS



Throughout this study Mr T.F, a myeloperoxidase deficient, healthy young man kindly donated 20 mls of his blood whenever it was required.

1.4.2 MATERIALS AND METHODS

The myeloperoxidase deficient neutrophil substrate was prepared by the 16 well chamber slide technique (Chapter 1.3.3 and 1.3.4) and stored at -20°C.

All P and X-ANCA positive serum samples were tested on the MPO deficient substrate.

CHAPTER 2

ANCA AND DISEASE

2.1 SYSTEMIC VASCULITIS

2.1.1 INTRODUCTION

The systemic vasculitides are inflammatory diseases of the blood vessels which may rapidly lead to end organ failure and death. They were first classified by Fauci in 1978. The diverse presenting features of these illnesses often lead to clinical and diagnostic problems and until recently the diagnosis was based on clinical features and tissue biopsy, the latter at times being inconclusive or difficult to interpret and resulting in delays. With the development of the ANCA test, a specific serological marker is now available that is of real value in establishing a diagnosis before respiratory or renal failure becomes irreversible.

In 1982 Davies first documented the finding of ANCA in 8 patients with segmental necrotizing glomerulonephritis (Davies 1982). Van der Woude initially reported the presence of this antibody in twenty five of twenty seven (93%) patients he tested with active Wegener's Granulomatosis, and more recently Kerr reported C-ANCA in forty four of fifty (88%) patients with W.G. (Van der Woude 1985, Kerr 1993).

In 1988, Falk and Jennette reported two distinct immunostaining patterns of ANCA when using ethanol fixed neutrophils; C-ANCA, the classical granular cytoplasmic staining pattern primarily associated with Wegener's

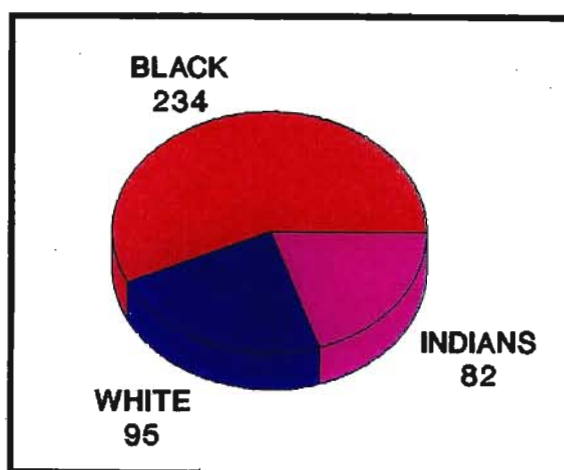
Granulomatosis and microscopic polyarteritis; and P-ANCA, the perinuclear staining pattern associated with the renal limited vasculitides (Falk 1988).

2.1.2 STUDY POPULATION

Four hundred and eleven blood samples from patients suspected of having systemic or renal limited vasculitis were received in the laboratory for routine ANCA testing over a period of four years (1988-1992). Two hundred and thirty four were from Black, ninety five from Indian and eighty two from White patients (Fig 6).

Fig 6

STUDY POPULATION (411 PATIENTS)



2.1.3 METHODS

Patients' serum samples were divided into two tubes and stored at -20°C until assayed. Samples were thawed once for testing, re-freezing and thawing of sera was avoided.

The samples received from 1988 to June 1992 when the new method was developed were tested for ANCA using an indirect immunofluorescent assay with buffy coat smears as the source of the neutrophil substrate (Chapter 1.2.2). The remainder were tested by indirect immunofluorescence using the chamber 16 slide method, (Chapter 1.3.4). All samples were tested in duplicate. From 1990 onwards all samples that were found to be P-ANCA positive on the standard normal neutrophil substrate were tested for ANCA on a myeloperoxidase deficient substrate.

The patients having a positive ANCA test were classified by defined criteria laid down by Fauci in 1978.

Wegener's Granulomatosis (WG) : destruction of upper and/or lower respiratory tract with glomerulonephritis in most cases. This diagnosis was accepted if the biopsy revealed a small vessel vasculitis or a necrotizing/crescentic glomerulonephritis.

Syndrome of Systemic Vasculitis : a non-specific clinical syndrome with at least two of the following features : anorexia, anaemia, arthralgia, fever, malaise, myalgia and weight loss in the absence of infections, malignancy or metabolic abnormalities.

Classical Polyarteritis nodosa : illness with features of systemic vasculitis and damage to at least two major organs . Confirmation of the diagnosis was dependent on the biopsy showing vasculitis of medium sized vessels without granuloma formation. The final diagnosis was obtained using these criteria after reviewing the hospital charts.

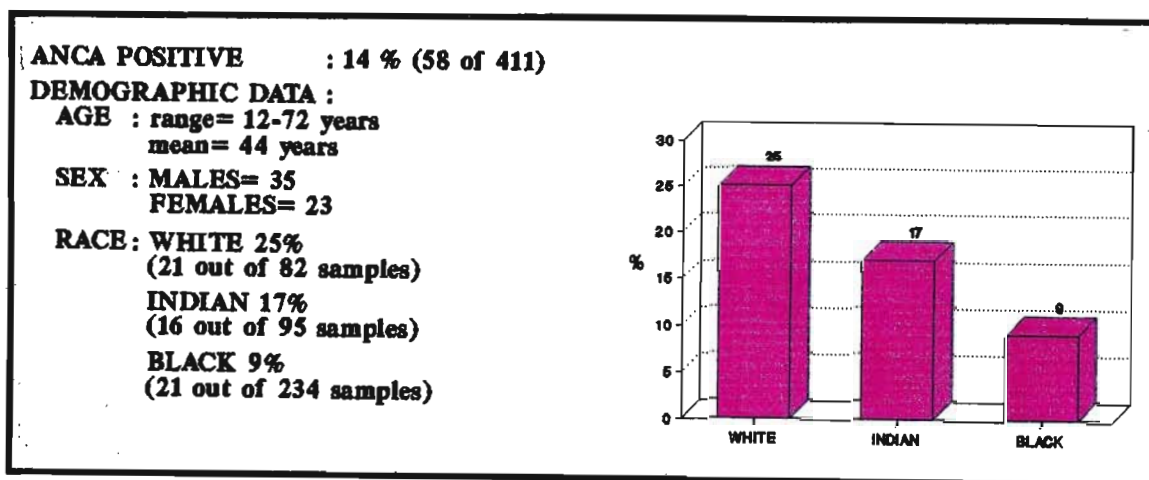
2.1.4 RESULTS

Fifty eight (14%) of the 411 patients suspected of having systemic vasculitis tested positive for ANCA. The group consisted of 35 males and 23 females, with an age range from 12 to 72 years and a mean age of 44.

Of the total, 234 were from Black patients of which 21 were positive, 82 from White patients with 21 positive and 95 from Indian patients, 16 of whom were positive (Fig 7).

Fig 7

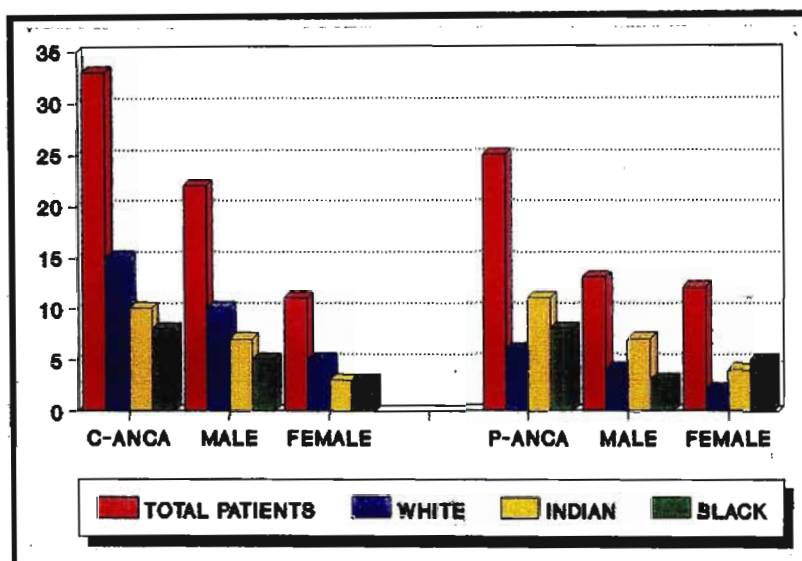
DEMOGRAPHIC DATA OF ANCA POSITIVE PATIENTS



Two patterns of ANCA positivity were identified in these 58 patients, 33 having C-ANCA and 25 P-ANCA as shown in Fig 8.

Fig 8

C AND P-ANCA IN 58 PATIENTS WITH SYSTEMIC VASCULITIS



Wegener's granulomatosis was diagnosed in 23 (70%), the majority of the patients with C-ANCA. The P-ANCA associations were much more diverse with a diagnosis of Wegener's in 4 (16%) and systemic vasculitis in 10 (40%) of these patients (Fig 9 and Fig 10).

Fig 9

DISTRIBUTION OF DISEASE IN C-ANCA POSITIVE PATIENTS

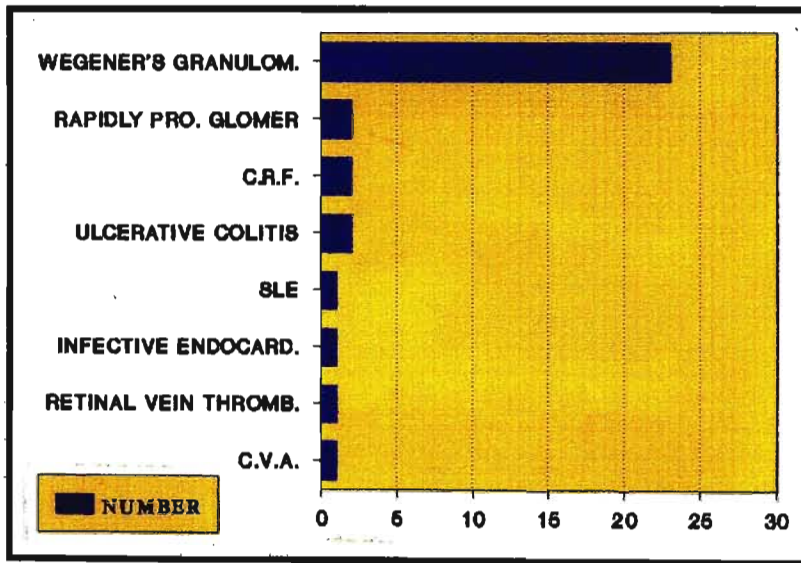
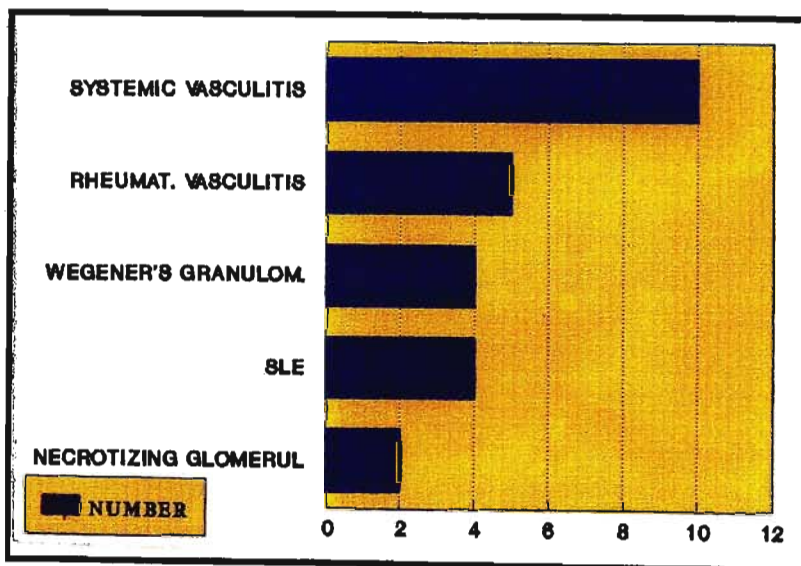


Fig 10

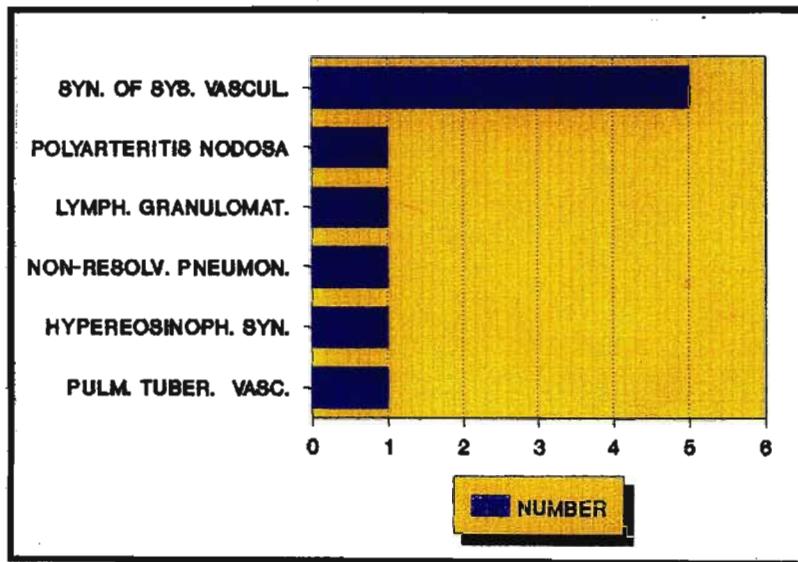
DISTRIBUTION OF DISEASE IN P-ANCA POSITIVE PATIENTS



A further breakdown of the 10 patients with P-ANCA and systemic vasculitis is shown in Fig 11.

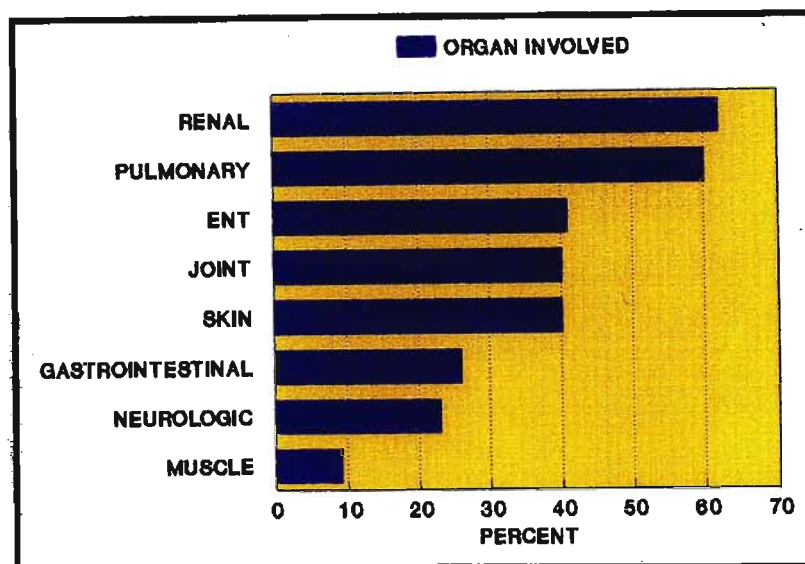
Fig 11

P-ANCA IN 10 PATIENTS WITH SYSTEMIC VASCULITIS



The organ involvement data (Fig 12) and the representative case reports (Chapter 2.6) illustrate the diversity of the presenting symptoms, with renal and pulmonary features predominating, as described in previous reports.

Fig 12

SPECTRUM OF DISEASE IN ANCA POSITIVE PATIENTS

2.1.5 DISCUSSION.

The clinical presentation of these patients ranged from limited renal disease to varying degrees of systemic involvement (Chapter 2.6). This resulted in patients presenting to ear nose and throat surgeons, pulmonologists, rheumatologists, ophthalmologists and general physicians. Requests for the ANCA test were often delayed. Many of the ANCA associated diseases are rapidly progressive, leading to irreversible organ damage and early immunosuppressive therapy is of great importance.

The sex distribution of ANCA positive patients in this study showed a male predominance in keeping with the findings reported in other studies (Adu 1987). ANCA was found more often in White patients, (25% of samples tested) than in Black patients, (9% of samples tested). This is in agreement

with the report of Falk in 1991, and could be attributed to the higher incidence of Wegener's granulomatosis amongst the White subjects.

C-ANCA has a reported specificity of almost 90% for Wegener's granulomatosis and microscopic polyarteritis, (Nölle 1989, Specks 1989 (1)) and in our study C-ANCA was identified in 85% of all cases of WG. P-ANCA is found in patients with a wider range of disorders and has been extensively associated with necrotizing and crescentic glomerulonephritis (Wathen 1987, Jennette 1989). Our patients with P-ANCA also fell into this category. (Fig 10 and Fig 11).

It is well recognised that some biopsies may be hazardous and technically difficult in these patients and that the histology is often inconclusive (D'Cruz 1989, Case 1, Chapter 2.6). The finding of ANCA in these patients is extremely useful in making a definitive diagnosis enabling prompt treatment to be started. Although there is contradictory evidence in the literature the serial monitoring of ANCA in these patients helps in their clinical assessment while on treatment and also helps in the differentiation of infection and relapse (Specks 1989 (2), Egner 1990, Pettersson 1992, Kerr 1993).

2.2 INFLAMMATORY BOWEL DISEASE

2.2.1 INTRODUCTION

At the third international workshop on ANCA in Washington DC in 1990 three different working groups reported the presence of ANCA in patients with inflammatory bowel disease. They found that the prevalence of the antineutrophil cytoplasmic antibody in ulcerative colitis was 53%, 64% and 23% respectively and the predominant staining pattern was P-ANCA (Cambridge 1991, Rump 1991, Jørgensen 1991). In patients with Crohn's disease the antibody frequency reported was much lower at 10%, 11% and 11% and the staining pattern was also P-ANCA. These P-ANCA's were not myeloperoxidase specific and other target antigens such as lactoferrin were suggested.

Using an intact neutrophil enzyme linked immunsorbent assay (ELISA) Saxon and co-workers undertook a blind study and found that twenty one of twenty five patients with ulcerative colitis and five of twenty five patients with Crohn's disease had antibodies to neutrophil cytoplasmic components (Saxon 1990). Duerr in 1991 confirmed a high prevalence of ANCA of 85% in ulcerative colitis and a prevalence of 78% in patients with ulcerative colitis who had undergone colectomy. Duerr also used a fixed neutrophil ELISA, and ELISA assays for specific antigens such as MPO, HLE and CG (Duerr 1991). He concluded that these ulcerative colitis associated ANCA's were not directed against any of the known cytoplasmic antigens. In 1992 Halbwachs-Mecarelli and co-workers found that in their study there was a strong association between ulcerative colitis, primary sclerosing cholangitis and ANCA specific

for CG (Halbwachs-Mecarelli 1992). In a recent study by Oudkerk Pool, P-ANCA was reported in 79% of patients with ulcerative colitis, in 13% of patients with Crohn's disease and the antibody was also present in all four of the patients he tested who had primary sclerosing cholangitis (Oudkerk Pool 1993). He found no correlation between disease activity and the presence of ANCA. The specific antigen testing proved that the antibodies were neither MPO, HLE nor proteinase 3 specific.

More recently at the 5th international workshop on ANCA in Cambridge, September 1993, a number of groups presented their data on ANCA in bowel diseases and their findings in ulcerative colitis are summarised in Table 1.

Table 1.

ANCA IN ULCERATIVE COLITIS. SUMMARY OF FINDINGS AT THE
FIFTH INTERNATIONAL ANCA WORKSHOP

GROUP	NO	POS	%	IIF PATTERN	SPECIFICITY
Patel Birmingham	101	71	70	P	26% Lf
Hauschild Lubeck	33	17	51	9/17 P 8/17 X	55% HLE 22% Lz
Oudkerk Pool * Amsterdam	51	37	73	P	
Mann Bristol / Leicester	S Asian 18	14	78	10/14 P 3/14 C 1/14 X	0% CG
	Eur. 35	30	86	29/35 P 1/35 C	24% CG

* Combined European study, Amsterdam results.

Lf Lactoferrin

CG Cathepsin G

HLE Human Leucocyte Elastase

Lz Lysozyme

It is evident from this new data that no single ANCA specificity is associated with ulcerative colitis. Hauschild's group found that the percentage of ANCA positive patients was similar in patients with low (52%), moderate (50%) and severe (50%) disease activity. Mann and co workers concluded from their study that there was a significantly higher rate of P-ANCA positivity with Cathepsin G specificity in European compared to South Asian patients. They

also report that in a recent study it has been suggested that there is a clinical difference between these two groups of patients and that these differences warrant further investigation (Patel 1993, Hauschild 1993, Oudkerk Pool 1993, Mann 1993).

2.2.2 STUDY POPULATION

Fifty eight patients were recruited from the Gastrointestinal unit at King Edward VIII hospital and from local private physicians. Forty four patients had ulcerative colitis alone, three patients had ulcerative colitis together with sclerosing cholangitis, one patient had sclerosing cholangitis alone, four patients had Crohn's disease, five had irritable bowel syndrome and one patient had colonic schistosomiasis. The diagnosis of inflammatory bowel disease was made on clinical, endoscopic, radiographic and histological grounds. None of the patients with inflammatory bowel disease had severe colitis, and all were being treated as outpatients. Three of the patients with ulcerative colitis had undergone colectomy. The demographic details of the forty four patients with ulcerative colitis can be seen in Table 2.

Table 2

DEMOGRAPHIC DETAILS OF FORTY FOUR PATIENTS WITH ULCERATIVE COLITIS

DISTRUBITION	MEAN AGE	AGE RANGE	NUMBER
Black female	48	38-60	3
White female	40	20-60	11
White male	39	18-61	8
Indian female	41	19-71	15
Indian male	33	21-58	6
Col.female	37		1

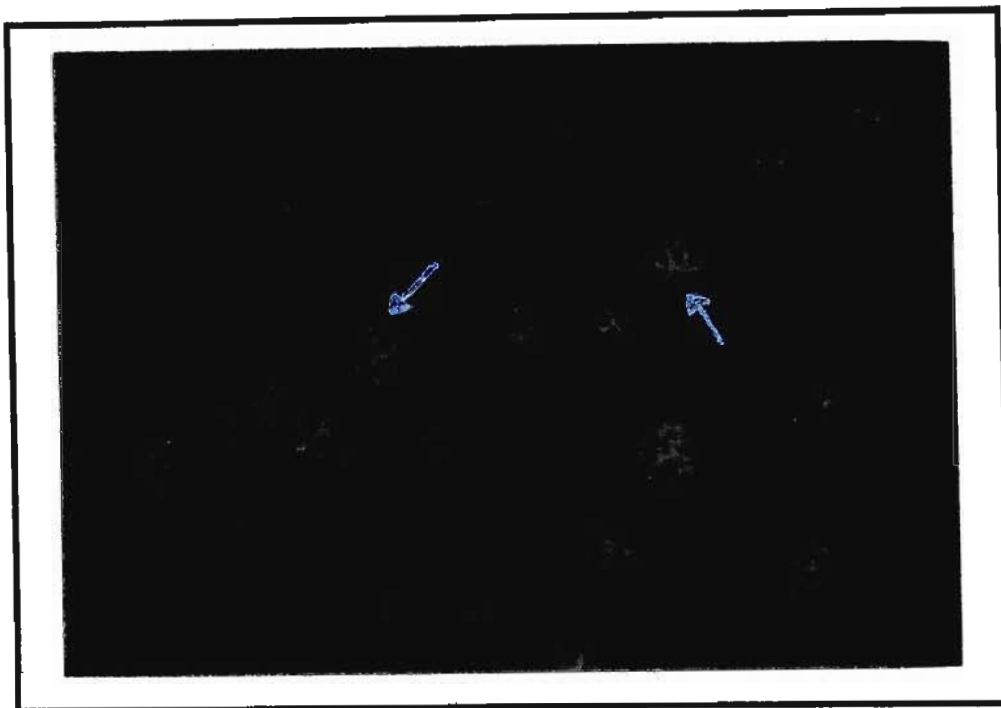
2.2.3 METHODS

Patients' serum samples were divided into four tubes and stored at -20°C until assayed. Samples were thawed once for testing, re-freezing and thawing of sera was avoided. An indirect immunofluorescent assay was done using the chamber 16 slide method (Chapter 1.3.4). All samples were tested in duplicate. Samples found positive on the standard normal neutrophil substrate were tested on the MPO deficient substrate and they were also tested for antinuclear antibody by indirect immunofluorescence. Two screening substrates were used: (i) composite block of mouse kidney, liver and stomach tissue and (ii) HEP-2 cell line.

2.2.4 RESULTS

ANCA was not found in the five patients with irritable bowel syndrome or in the patient with schistosomiasis. Two of the four patients with Crohn's disease had atypical X-ANCA while two of the three patients who had ulcerative colitis with sclerosing cholangitis were found to have P-ANCA and C-ANCA respectively. The single patient with sclerosing cholangitis alone had P-ANCA. The antibodies found in the two patients with Crohn's disease were very similar, both exhibiting cell membrane disruption and granule "spill" (Plate 9). This same staining peculiarity was observed on the myeloperoxidase deficient substrate. One of these patients had a positive antinuclear antibody of homogenous pattern with a titre of 1:200 while the other showed a cytoplasmic lysosomal pattern on the composite block mouse tissue section.

Plate 9



ANCA in Crohn's disease → neutrophil granule "spill". (Mag. x 300)

Of the forty four patients with ulcerative colitis twenty five were found to have antineutrophil cytoplasmic autoantibodies (57%). Twelve (48%) of these were of P-ANCA specificity, ten (40%) showed an atypical staining pattern, X-ANCA and the remaining three (12%) had the classical granular cytoplasmic staining pattern. Of the three patients who had a colectomy one was C-ANCA positive. Details of the ANCA distribution in this group of patients can be seen in Table 3. All 22 P and X-ANCA positive samples were tested on the myeloperoxidase deficient substrate and showed positive fluorescent staining, i.e. they were not myeloperoxidase specific. Other autoantibodies were identified in this group of patients, one black female with P-ANCA had an antinuclear antibody (homogeneous pattern) at a titre of 1:200 and tested

for antibodies to ds-DNA and extractable nuclear antigens. One white female, also P-ANCA positive was found to have cytoplasmic lysosomal antibodies on the composite block, similar to those seen in the patient with Crohn's disease. Two patients had smooth muscle antibodies and a third patient had antibodies specific for parietal cells.

Table 3

ANCA IN FORTY FOUR PATIENTS
WITH ULCERATIVE COLITIS.

	P-ANCA	X-ANCA	C-ANCA	Total Positive	Number	%tage Positive
B.F	2			2	3	67%
W.F	4	2		6	11	55%
W.M	2		1*	3	8	36%
I.F	3	6	1	10	15	67%
I.M	1	1	1	3	8	38%
C.F		1		1	1	100%
	12	10	3	25	44	57%

* Post colectomy

2.3.5 DISCUSSION

The spectrum of inflammatory bowel disease has been associated for many years with autoimmune phenomena. Autoantibodies reactive with colonic epithelial cells and lymphocytes were reported in 1959 and 1975 respectively (Broberger 1959, Korsmeyer 1975). In an editorial in 1991 "Vasculitis and the gut: unwitting partners or strange bedfellows", Prof J T Lie of the Mayo Clinic reviewed the involvement of the gut in various vasculitic diseases such as

Takayasu's arteritis, Churg Strauss syndrome and Wegener's granulomatosis. He concluded " The association of vasculitis and inflammatory bowel disease cannot be dismissed as an epiphenomenon and it merits our continual attention" (Lie 1991). The recent discovery of ANCA in patients with inflammatory bowel disease supports the suggestions that Prof Lie made.

The presence of ANCA has been demonstrated in a group of local Durban patients with ulcerative colitis. Fifty seven per cent of the patients were ANCA positive correlating well with other reports (Saxon 1990, Duerr 1991, Halbwachs-Mecarelli 1992). The antibody specificity of the twenty five patients is unclear. All the P-ANCA positive patients were also positive on the myeloperoxidase deficient substrate therefore excluding MPO specificity as has been reported by others. As yet specific antibody tests for other antigens such as Lf, HLE and CG are locally unavailable. None of the ANCA positive patients had severe colitis, so the antibody presence was probably unrelated to disease activity as documented in three separate studies (Saxon 1990, Duerr 1991, Hauschild 1993). Unlike the recently reported study of Mann in 1993, in this study population the frequency of P-ANCA does not differ between White and Indian patients. However 7/13 (54%) Indian patients have X-ANCA whereas only 2/9 (22%) White patients have the atypical X-ANCA. Although these numbers are too small for statistical evaluation it is of interest that the overall ANCA prevalence varies both between the race groups and the sexes. Fifty five per cent of White and 67% of Indian females have ANCA compared with 36% White and 38% Indian males. In this study the number of patients with Crohn's disease and sclerosing cholangitis was so small that it is difficult to comment upon, or to evaluate the results.

The pathogenetic importance of ANCA in inflammatory bowel disease is not yet known. Some feel that it is unlikely that it is involved in the pathogenesis of chronic inflammatory bowel disease, (Gross 1993) while others postulate that ANCA may be a manifestation of altered immune regulation in ulcerative colitis (Duerr 1991). There is consensus however that ANCA may be a useful marker and a helpful test to distinguish between ulcerative colitis and Crohn's disease.

2.3 SYMPTOMATIC HIV DISEASE

2.3.1 INTRODUCTION

Since 1985 autoimmune phenomena have been reported in patients with HIV infection. Among the autoantibodies documented in HIV infected patients are antinuclear factor, rheumatoid factor and anticardiolipin antibodies. In 1990 ANCA was first described in HIV infection by Koderisch and co-workers. Using the indirect immunofluorescent assay they reported a faint homogeneous cytoplasmic staining in thirty one sera from twenty four patients and they interpreted this as being non-specific Fc-receptor binding of IgG. Fifteen of their patients were hypergammaglobulinaemic and all fifteen showed this staining pattern. Definite C-ANCA staining however was found in four serum samples from three patients. These authors found no correlation between the stage of the disease and the presence of ANCA and cautioned clinicians to be aware of "false positive" reactions in HIV infections. In contrast however Klaasen and co-workers in 1992 reported the presence of ANCA (IIF testing method), in eleven of thirty five patients with symptomatic HIV infection. In their study they found that this antibody was not related to the degree of hypergammaglobulinaemia nor to any specific patient symptomatology. They reported both C and P-ANCA staining patterns, and of great interest was the negative reaction with these serum samples when they were tested for PR3, MPO and elastase specificity by sandwich ELISA's, immunoprecipitation and immuno-blotting. This suggested a possible new specificity for the target antigen in HIV associated ANCA. Davenport in 1992 published four case reports of "false positive" ANCA in patients with Hodgkins, Tuberculosis, haemorrhagic cerebral infarct and HIV disease. Cornely in 1993 reported P-

ANCA positivity in 65/103 (63.1%) HIV infected patients. Of these 65 patients 57 had CD4 counts of $<200/\mu\text{l}$ and 8 had CD4 counts $>200/\mu\text{l}$. He reported no association with hypergammaglobulinaemia or the presence of other autoantibodies. Immuno-blotting of these P-ANCA's was associated with at least four different target proteins of 45kDa, 55kDa, 60kDa and 75kDa respectively.

HIV incidence in the Durban area has increased rapidly over the last five years to an incidence of about 10% in the Black population (Personal communication Prof J Moodley ante natal clinic survey). HIV related disease is assuming progressively increasing prominence in the medical wards at King Edward VIII hospital and Wentworth hospital.

ANCA is used routinely for the diagnosis of systemic vasculitis at this hospital. The positive predictive value of the test will undoubtedly be influenced by the rising HIV prevalence, and it was therefore decided to test a cohort of local patients with symptomatic HIV disease for the presence of autoimmune phenomena.

2.3.2 STUDY POPULATION

Forty five consecutive patients were recruited from the HIV out patient clinic at King Edward VIII hospital and six "in" patients at Wentworth hospital. The patients from the clinic all had symptomatic disease varying from generalised lymphadenopathy to Aids related complex (ARC) and AIDS. None of these patients was being treated with AZT, but some were receiving treatment for related conditions such as tuberculosis and candidiasis.

The patients from Wentworth Hospital were from the neurology wards and had been admitted for investigation of various neurological symptoms, including paraparesis and cerebro vascular accidents.

The 51 patients included 22 Black males, 27 Black females and 2 Indian males. The demographic details of the Black patients can be seen in Table 4.

Table 4

DEMOGRAPHIC DETAILS OF FORTY NINE BLACK HIV
POSITIVE PATIENTS

	MALE	FEMALE
NUMBER	22	27
MEAN AGE	36	30
AGE RANGE	20-60	17-52

2.3.3 METHODS

Serum samples were divided and frozen at -20°C until tested. Samples were thawed once for testing, re-freezing and thawing of sera was avoided. ANCA tests were performed in duplicate using the indirect immunofluorescent technique in the 16 well chamber slide (Chapter 1.3.4).

CD4, helper cell counts were enumerated on a Coulter flow cell cytometer, EPICS PROFILE II using cytoStat Coulter clone T4-RDYT8-FITC 2222E223 as the detecting antibody. These counts are expressed as the number of cells per microlitre.

Indirect immunofluorescent screening for antinuclear factor was done on a composite block of mouse tissue: liver, kidney and stomach. Positive sera on this substrate were retested on a HEp-2 cell line for antinuclear factor confirmation, *Crithidia luciliae* for antibodies to ds-DNA and ELISA assays for specific antibodies to four extractable nuclear antigens, RNP, Sm, SSa and SSb.

IgG antiphospholipid antibodies were sought using an "in house" ELISA assay with bovine heart cardiolipin extract as the substrate. An index of positivity is calculated by dividing the mean of the optical density of the patient's sample by 1,5 x the mean optical density of the standard negative serum control. An index of 1,1-2,5 is considered a low range positive, 2,6-3,5 a medium range positive and >3,6 a high range positive.

2.3.4 RESULTS

ANCA was found in in twenty one (41%) of the fifty one patients. Fifteen had C-ANCA, three P-ANCA and three an atypical X-ANCA staining pattern. Table 5 shows the helper cell counts and the autoantibody findings in the twenty one ANCA positive patients. Four of twenty one patients (19%) had ANA that was not specific for ds-DNA or the extractable nuclear antigens SSa, SSb Sm and RNP. Thirteen of twenty one (62%) had antibodies to smooth muscle. Sixteen of twenty one (76%) patients had antiphospholipid antibodies.

Table 5

AUTOANTIBODY AND CD4 COUNTS IN 21 PATIENTS WITH ANCA.

Pat. no.	ANCA	CD4 / μ l	ANF /Auto abs	ACA Index
390	C	N/D	SMAB	4,1
400	C	N/D	SMAB	3,6
5	C	196	Sp.1/50 wk SMAB	1,1
10	C	756	SMAB	1,5
12	P	73	Neg	1,1
13	X	308	wk nuc dots 1/50	2,1
34	C	584	SMAB	5,6
35	C	260	PCAB	2,0
36	C	188	Sp. 1/50 wk SMAB	2,2
38	C	627	Hom. 1/50	5,4
42	X	412	SMAB	1,7
43	C	206	SMAB	3,5
44	C	155	SMAB	3,0
45	P	354	Hom. 1/50	0,3
46	C	399	SMAB	1,9
47	P	594	SMAB	2,4
49	C	626	Neg	0,5
53	C	205	wk nuc.dots 1/50	1,9
54	C	725	SMAB	1,6
55	X	120	SMAB	2,3
56	C	N/D	Neg	1,1

SMAB Smooth muscle antibody

PCAB Parietal cell antibody

Hom Homogeneous antinuclear staining pattern

Sp Speckled antinuclear staining pattern

1/50 antibody titre

N/D not done

Table 6 illustrates the comparison between the autoantibody results and the CD4 counts of the ANCA positive and the ANCA negative patients.

Table 6

COMPARISON OF HELPER CELL COUNTS AND AUTOANTIBODY FINDINGS IN ANCA POSITIVE AND ANCA NEGATIVE HIV INFECTED PATIENTS.

	ANCA Positive	ANCA Negative
Number	21	30
CD4 <200	5/19 (26%)	6/26 (23%)
CD4 201-400	7/19 (37%)	8/26 (54%)
CD4 401-800	7/19 (37%)	10/26 (38,4%)
CD4 >800	0/19	2/26 (7,6%)
ANF	4/21 (19%)	3/30 (10%)
SMAB	13/21 (62%)	11/30 (37%)
ACA	16/21 (76%)	21/30 (70%)

- CD4 Helper cell count expressed as number per microlitre
 ANF Antinuclear factor
 SMAB Smooth muscle antibody
 ACA Anticardiolipin antibody

Of the twenty one ANCA positive and thirty ANCA negative patients, CD4 counts were available on nineteen and twenty six respectively. There was no difference between the CD4 counts in the two groups. Antinuclear antibodies

were detected in 19% of the ANCA positive patients and in 10% of the ANCA negative group. A high proportion, 76% and 70% of these patients were found to have anticardiolipin antibodies. This is in agreement with the findings of other workers in this field (Maclean 1990). Smooth muscle antibodies were found more frequently, (62%) in ANCA positive patients than in the ANCA negative patients (37%).

2.3.5 DISCUSSION

Concurring with the reports of others (Koderisch 1990, Klaasen 1992, Cornely 1993) a high prevalence of ANCA (41%) was found in the HIV infected patients with symptomatic disease at King Edward VIII and Wentworth hospitals. Other than a higher prevalence of smooth muscle antibodies in the ANCA positive patients compared to the ANCA negative patients, there were no differences between the two groups of patients relating to the helper cell counts, antinuclear antibodies and anticardiolipin antibodies. Smooth muscle antibodies once thought to be specific for chronic active hepatitis are found in about 80% of patients with viral infections and non specific liver damage so the non specific nature of the test may explain the high prevalence of this antibody in this group of patients (Chapel H and Haeney M. Essentials of Clinical Immunology, 3rd edition 1993).

ANCA in HIV infected patients does not appear to be associated with any clinical symptoms of vasculitis. HIV associated ANCA is probably an epiphenomenon related to the breakdown and degranulation of neutrophils concomitant with a viral infection, or the response to a retroviral antigen, or the result of immune dysregulation in HIV infection

All three patterns of ANCA were found in our patients, the majority, 71% being C-ANCA but the specificities are still ill defined. Clinical manifestations of HIV disease and Wegener's granulomatosis may have features in common, therefore the finding of C-ANCA in our local patients should be followed by an HIV test when the clinical or histological investigations are inconclusive.

2.4 INVASIVE AMOEBIASIS

2.4.1 INTRODUCTION

Invasion of the body by *Entamoebae histolytica* commonly manifests with ulcerative colitis or amoebic liver abscess (ALA). Interaction between the protozoa and polymorphonuclear leucocytes is thought to contribute to the pathogenesis of these lesions. It has been shown that contact between virulent strains of *E. histolytica* and neutrophils *in vitro* is followed by spontaneous degranulation and subsequent lysis of neutrophils (Guerrant 1981). The liberation of proteolytic enzymes during this process participates in producing the hepatic necrosis characteristic of amoebic liver abscess.

Features of the pathology of amoebiasis include disruption of neutrophils, damage to blood vessels and areas of ischaemic necrosis, particularly in the colon (Luvuno 1985). It was therefore postulated that in the setting of invasive amoebiasis, components of the damaged neutrophils may in addition generate an immune response and that this response could be implicated in the vascular pathology of this condition. Accordingly a study of serum samples from patients with invasive amoebiasis was initiated.

2.4.2 STUDY POPULATION

Eighty two encoded samples from 77 Black adult patients with clinically proven ALA were tested. Included was a sequence of sera from one patient at the time of diagnosis and at 1, 3 and 8 months of convalescence. Two serial samples from each of two additional patients were also examined. Because other investigations were used in this amoebiasis study, controls included reference C and P-ANCA positive sera from patients with histologically

confirmed vasculitis and sera from volunteer adult blood donors. These were included as appropriate with each of the methods.

2.4.3 METHODS

The serum samples from these patients had been lyophilized and stored at -20°C .

Prior to testing they were reconstituted with 200 μl of distilled water. ANCA was sought using the indirect immunofluorescent technique on the 16 well chamber slides (Chapter 1.3.4). Because of the large numbers, **these samples were not tested in duplicate**. The tests were read in a blinded fashion by a minimum of two observers and the degree of fluorescence graded from negative to +++++. Where there was a discrepancy between the observers (n = 4) the test was repeated in duplicate.

Tests to demonstrate cross-reacting antibody.

Indirect immunofluorescence (IIF) on *E. histolytica* substrate.

Whole amoebae were washed once in Ringer's solution and adjusted to a count of $0,25 \times 10^6/\text{ml}$. 200 μl of this suspension was pipetted into the wells of the 16-chamber slides and allowed to settle for one hour at 37°C in an atmosphere of 5% CO_2 in air. The supernatant was gently syringed off, the wells dried at room temperature for two hours and then the amoebae were fixed for 5 mins in cold absolute alcohol. A standard IIF was performed with serum from eight patients with amoebiasis, four with vasculitis associated ANCA (3 C-ANCA, 1 P-ANCA) and one normal control.

Amoebic gel diffusion test (AGDT)

The amoebic gel diffusion test was performed as previously described (Jackson 1983). If no precipitins developed within 40 hours the test was read as negative. When precipitins developed within 20 hours the AGDT was regarded as strongly positive. The test was done on serum from 87 patients with amoebic liver abscess, 6 patients with vasculitis associated ANCA, (5 C-ANCA and 1 P-ANCA) and 107 normal controls.

Absorption studies.

Pure neutrophil suspensions were prepared as detailed (Chapter 1.3.3). Whole amoebae were washed once for five minutes at 350 x g in Ringers solution. The neutrophils were resuspended in Hank's balanced salt solution and adjusted to a cell count of $7,5 \times 10^6/\text{ml}$. The amoebae were suspended in Ringers solution and adjusted to a count of $5,4 \times 10^6/\text{ml}$. 110 μl of a proteinase inhibitor, iodoacetamide was added to one millilitre of each cell suspension to achieve an end concentration of 10mM. The neutrophils were sonicated for two minutes at 100 watts and the amoebae for four minutes at 100 watts. These sonicates were then centrifuged for thirty minutes at 1900 x g. The supernatants were removed and the cell debris resuspended in 500 μl of PBS. These two preparations of the neutrophils and the amoebae were termed "sediment and supernatant". The amoebic antigen used in the amoebic gel diffusion test was also used as an absorbent. The seven absorbents are listed below.

1. Phosphate buffered saline. PBS
2. Whole neutrophils $2 \times 10^6/\text{ml}$.
3. Neutrophil sediment.

4. Neutrophil supernatant.
5. Amoebic sediment.
6. Amoebic supernatant.
7. Amoebic antigen as used in the AGDT.

These seven absorbents were each incubated with an equal volume of six ANCA amoebic sera, 4 vasculitis associated ANCA (3 C-ANCA and 1 P-ANCA) and one normal control. The incubation time was for one hour at RT, with gentle shaking every ten minutes. The preparations were then centrifuged for 10 mins at 1900 x g and the supernatants removed for testing. These serum supernatants were then diluted 1 in 5 with PBS to achieve the end dilution of 1 in 10 used for the ANCA screening technique.

Ouchterlony gel diffusion tests.

The gel diffusion technique described by Ouchterlony (1962) was used.

100µl of the two antigens, neutrophil sediment and neutrophil supernatant were placed in the central well of each of two agarose Ouchterlony plates. 45µl of positive sera, (3 C-ANCA, 1 P-ANCA, 3 Amoebic-ANCA) and a normal serum control were placed in the eight small surrounding wells. The plates were incubated in a moist chamber for 48 hours and then examined for precipitation lines using a magnifying glass against a dark background.

Anti-Proteinase 3 (PR3) ELISA

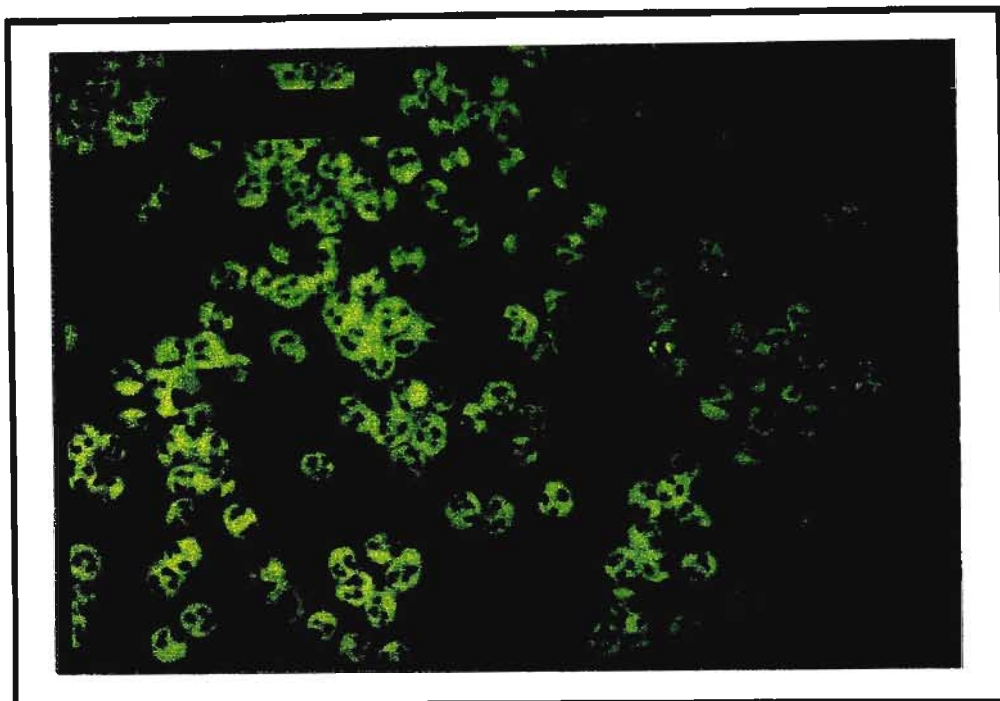
Specific anti-proteinase 3 activity was measured using an ELISA test kit supplied by Immunobiological Laboratories, Hamburg, according to the manufacturer's instructions. A cut off value of 10U/ml was used to separate seropositive from seronegative results. Sera of 28 ANCA positive amoebic

patients, six vasculitis-associated ANCA patients (3C and 3 P-ANCA) and 10 volunteer blood donors were tested.

2.4.4 RESULTS

Seventy six (98,7%) sera from patients with invasive amoebiasis produced unequivocal fluorescence of the neutrophil cytoplasm indicating the presence of ANCA. The pattern of staining resembled C-ANCA but was considered to be more homogeneous than granular, and lacked any perinuclear emphasis (Plate13). In the case for whom serial observations were available the ANCA became less intense at one month and negative at three months after successful treatment (Table 7). One confirmed ALA patient with a negative AGDT and one AGDT positive ALA patient were ANCA negative. In the patients for whom there were two serial samples the ANCA became weaker with the second sample.

Plate 13



Amoebiasis-associated C-ANCA (Mag x 300)

Table 7

SERIAL OBSERVATIONS IN PATIENT S27

DATE	MONTHS	ANCA	AGDT
18/03/91	0	3 C HOM	POS 20 HR
12/04/91	1	2 C HOM	POS 20 HR
20/06/91	3	NEG	POS 20 HR
28/11/91	8	NEG	POS 40 HR

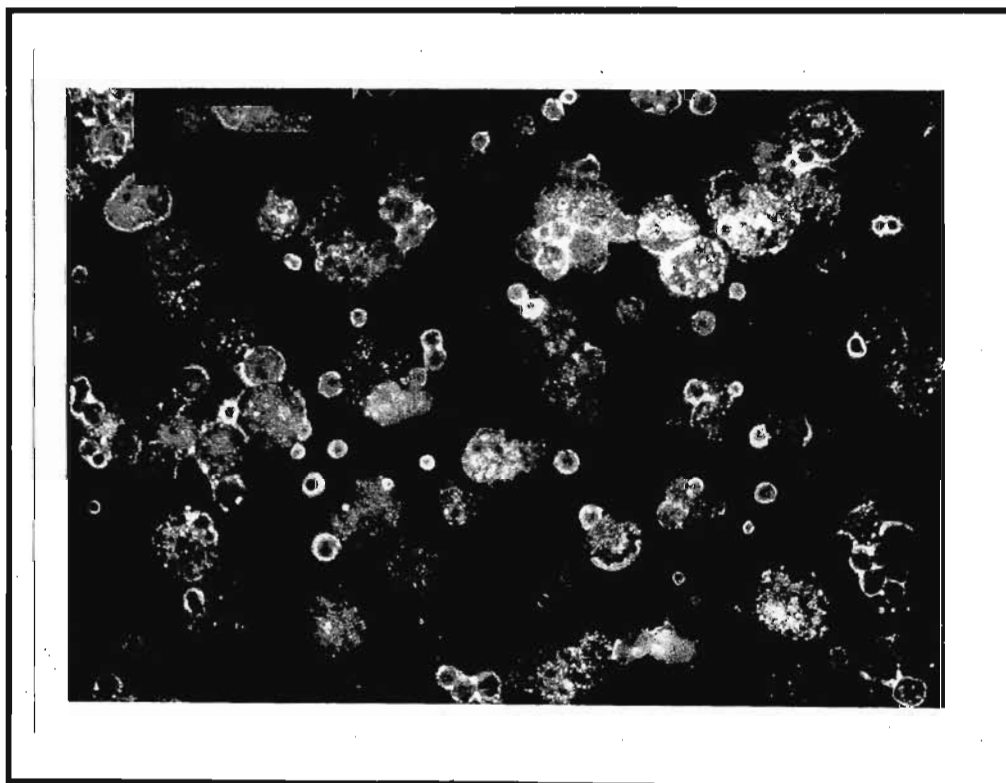
3/2 Grading of fluorescence, negative to 4 (++++)

C cytoplasmic fluorescence

HOM homogeneous staining.

In the IIF *E. histolytica* assay all the samples from patients with amoebiasis gave definite fluorescence of the amoebae (Plate 14). Serum from the patients with vasculitis-associated C and P-ANCA and normal controls gave negative results.

Plate 14



IIF Amoebae (Mag. x 400)

Six samples from patients with vasculitis-associated ANCA gave negative AGDT results with no precipitins observed after 40 hours. Of the 107 control samples tested 105 were negative, one was strongly positive at 20 hours and another positive at 40 hours.

Attempts to absorb ANCA from amoebic and vasculitis-associated serum with any of the preparations used for this purpose were unsuccessful (Table 8).

Table 8

ABSORPTION STUDIES

Absorbent	N. serum	Weg C-ANCA	Amoeb C-ANCA
PBS	-	+	+
Intact neutrophil	-	+	+
Neutrophil sediment	-	+	+
Neutrophil supernatant	-	+	+
Amoebic sediment	-	+	+
Amoebic supernatant	-	+	+
Amoebic antigen (AGDT)	-	+	+

NOTE. *A possible explanation for the failure to absorb neutrophil antibody activity from both vasculitis-associated C-ANCA and amoebiasis-associated C-ANCA is that there was antibody excess in the mixtures. Recent reports have suggested that absorption of this group of antibodies using neutrophil derived antigens is difficult, and recommend that serum should be diluted at least 1 in 50 to ensure antigen excess.*

Two of the four Wegener's sera (3 C-ANCA and 1 P-ANCA) formed lines of precipitation in the Ouchterlony gel diffusion test with the neutrophil sonicate sediment. No reaction occurred with any of the amoebic sera. There was no reaction in the plate where the neutrophil sonicate supernatant was used as the detecting antigen.

As can be seen in Fig 13, 75% (21/28) ANCA positive sera from patients with amoebiasis have specific anti-PR3 activity. All 10 controls and the 3 P-ANCA sera had values of <10U/ml, and the 4 C-ANCA patients levels of >80U/ml. Plate 15 shows one of the PR3 ELISA test plates.

Fig 13

IMMUNOBIOLOGICAL LABORATORIES HAMBURG PR3 ELISA

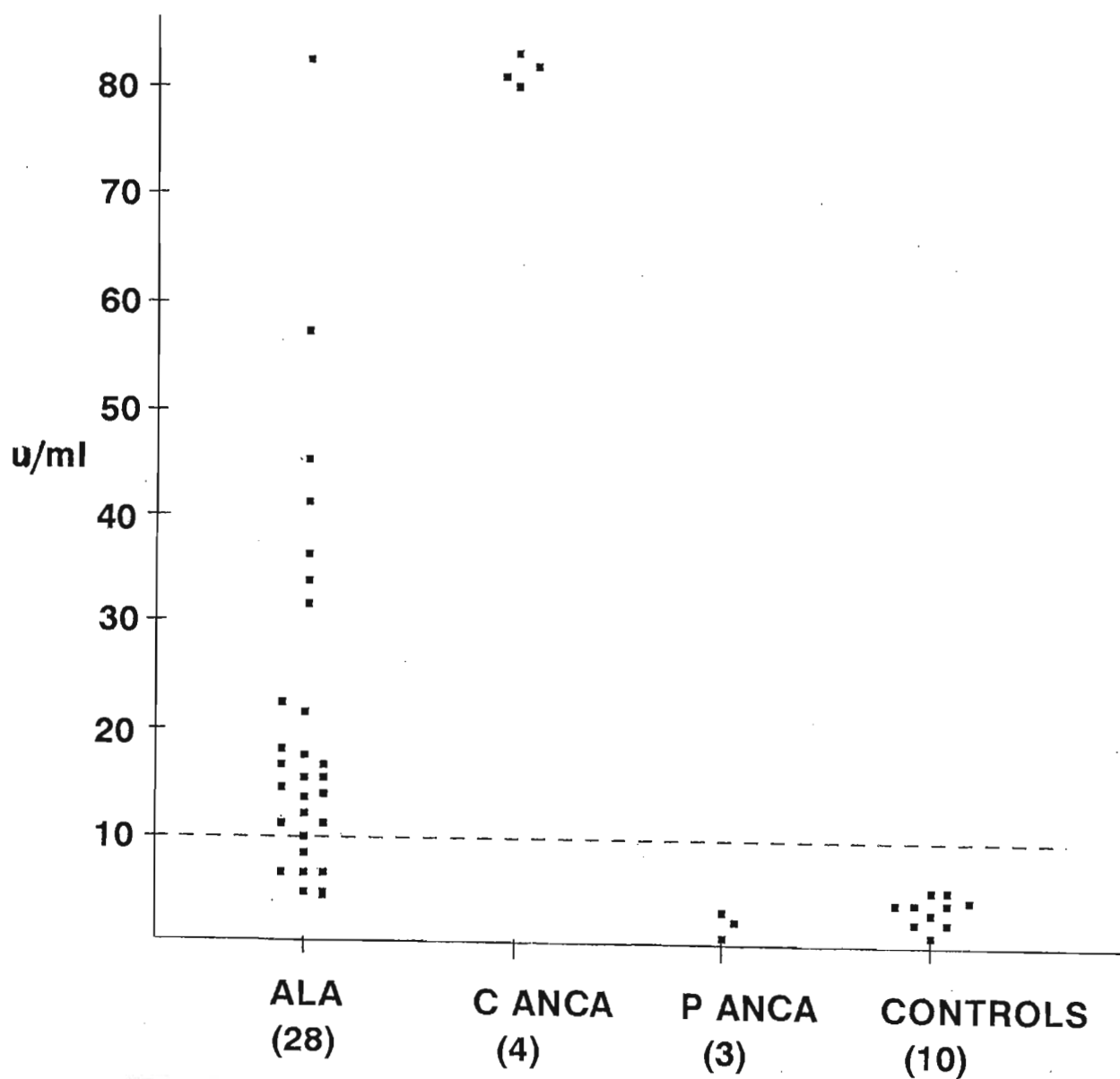
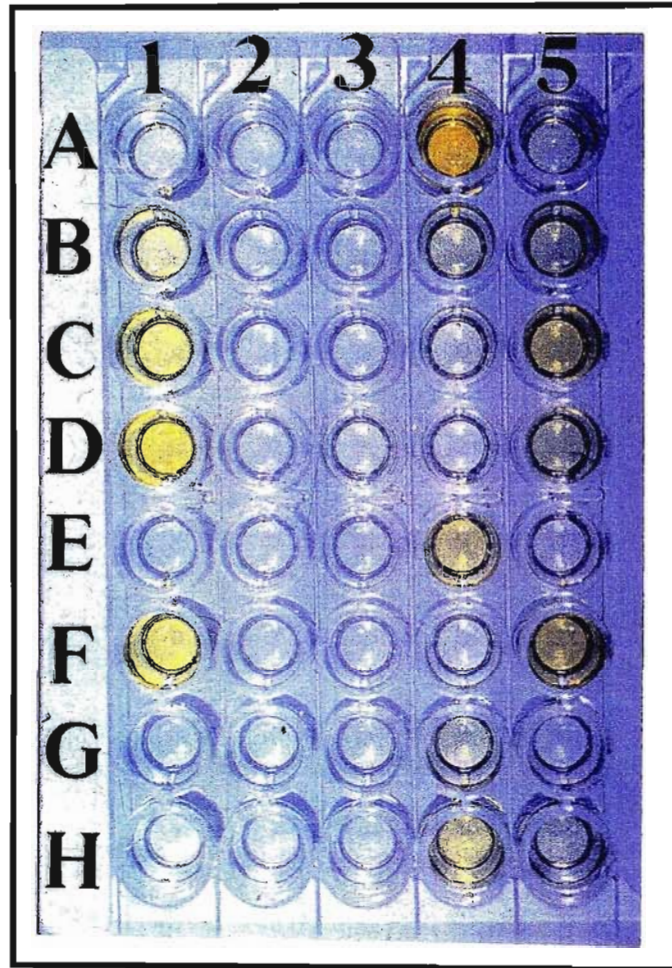


Plate 15

PR3 ELISA PLATE



- | | |
|----------------|----------------------------------|
| 1 A-D | Standard curve |
| 1 E | Negative control |
| 1 F | Positive control |
| 1 G-H, 2&3 A-H | Blood donors |
| 4&5 A-H | Amoebic C-ANCA positive patients |

2.4.5 DISCUSSION

The two observations that clearly emerge from this study are that 98,7% of patients tested with invasive amoebiasis have ANCA, with a pattern of staining that suggests PR3 specificity and that the anti-PR3 assay confirms at least a degree of PR3 specificity in 75% of these. It was noted that the staining pattern is homogeneous rather than granular, that there is no central emphasis and that the reaction in both IIF and ELISA is less intense suggesting that besides the recognition of a PR3 epitope other specificities may be implicated. The first possible explanation for the presence of this antibody in amoebiasis is that the disruptive effect of *E. histolytica* on neutrophils may expose and/or alter proteins, rendering them antigenic and resulting in the production of an antibody with specificity for an epitope of proteinase 3. The second possibility is that the antibody is produced in response to an amoebic antigen and that it cross reacts with neutrophil cytoplasmic components such as proteinase 3. Attempts to demonstrate cross reactivity were inconclusive and more detailed immunochemical studies are required to explore this possibility.

It is postulated that the binding of ANCA to proteinases on neutrophil membranes activates the neutrophil and this may result in degranulation with resulting tissue damage (Gross 1993). The demonstration of ANCA in virtually all cases of invasive amoebiasis raises the interesting possibility that such neutrophil activation may contribute to hepatic necrosis and colonic vasculitis observed in this condition. It is also thought that ANCA binding to proteinase ligands on endothelial cells may contribute to the vasculitis seen in Wegener's granulomatosis (Savage 1993). A similar direct effect may operate in invasive amoebiasis. Effective eradication of *E. histolytica* trophozoites with metronidazole and inactivation of proteinases by endogenous inhibitors,

would effectively stop this sequence of events resulting in rapid conversion to seronegativity observed in the one patient from whom serial samples were obtained.

Of practical clinical importance is the fact that amoebiasis is associated with a high level of C-ANCA positivity. This finding will need to be considered when ANCA test results are used in clinical decision making in an area where invasive amoebiasis is endemic.

2.6 CLINICAL STUDIES

Serial observations are available on fourteen patients with ANCA associated disease and their brief case histories serve to illustrate the clinical applications of the ANCA test.

1. A 36 year old Indian man had recurrent otitis media, tonsillitis and nasal ulceration for 3 years. Serial biopsies had not yielded a diagnosis. He then became acutely ill in 1987 with fever, arthralgia, right middle lobe consolidation and progressive renal failure.

The ANCA test revealed strong C-ANCA. A similar result was obtained with a serum sample that had been taken one year earlier and stored at -20°C.

Treatment was started with prednisolone and cyclophosphamide and temporary haemodialysis was required.

Response was good and remission has persisted for 6 years.

ANCA was not detected within a few weeks of starting treatment and has remained negative (Pudifin 1989).

This was the first ANCA test in our laboratory. It was diagnostic, and has been a valuable adjunct to monitoring remission.

2. A 55 year old White man presented with polyarthralgia, haemoptysis and renal failure. Right upper lobe consolidation was present on X-ray examination. Renal biopsy revealed focal necrotising vasculitis with interstitial inflammation.

The ANCA test was positive - cytoplasmic pattern.

Treatment included prednisone, cyclophosphamide and haemodialysis.

The constitutional and pulmonary features resolved rapidly, but haemodialysis has been needed for irreversible renal failure.

The ANCA test has remained positive despite long term immunosuppressive therapy.

This patient showed an exception to the general finding that ANCA parallels disease activity.

3. A 51 year old White man had chronic sinusitis for 5 years, tinnitus and unilateral hearing loss for 3 years, associated with malaise, weight loss, intermittent fever and arthralgia. There was no impairment of renal function.

An ENT surgeon referred the patient when dramatic hearing improvement occurred during a short course of prednisone. ANCA test was positive - perinuclear staining pattern.

The patient was treated with prednisone and cyclophosphamide and has remained well for 2 years. Apart from a spell of weak ANCA positivity for 6 months in the first year, the serial ANCA tests have been negative on treatment.

An incidental finding in this patient in 1988 was mild myelofibrosis on bone marrow biopsy.

This test proved useful in diagnosis and monitoring.

4. A 64 year old White male presented with 3 weeks of pyrexia with severe malaise and arthralgia. An X-ray of the chest was clear. Urine contained protein and granular casts. The ANCA test produced a strong P-ANCA pattern and was myeloperoxidase specific.

Treatment with cyclophosphamide and prednisone produced rapid remission which has been maintained for 3 years.

The ANCA test has remained positive throughout this period.

ANCA may persist despite clinical remission.

5. A 31 year old White man presented with maxillary sinusitis and conjunctival injection. A mucosal biopsy showed non-specific chronic inflammation. The urine was clear.

The ANCA test was positive - cytoplasmic pattern.

Standard treatment produced resolution and the ANCA test became, and has remained negative.

The ANCA test aided early diagnosis.

6. A 36 year old Indian man presented with a 6 week illness characterised by arthralgia, nasal granulomas, segmental pulmonary consolidation, a vasculitic rash, encephalopathy with a seizure and acute renal failure.

The ANCA test was positive - cytoplasmic pattern.

The illness ran a fulminant course and the patient died of a gastrointestinal haemorrhage one month later despite therapy with immunosuppression and plasma exchange.

The ANCA positivity was not affected by the treatment.

7. A 40 year old Indian woman, admitted with an avascular necrosis of the femoral head, was found to be in renal failure with small kidneys.

Unexplained fever and a markedly elevated ESR prompted a request for the ANCA test which was positive, perinuclear pattern, myeloperoxidase specific.

The patient was treated with cyclophosphamide and is maintained on chronic ambulatory peritoneal dialysis.

Under treatment the ANCA test became negative. However, ANCA positivity returned with a reduction in the cyclophosphamide dose, and has remained positive since discontinuation after 2 years of therapy. There has been no recrudescence of vasculitis.

P-ANCA in renal limited disease.

8. A 60 year old Indian woman presented with severe mononeuritis multiplex, weight loss and arthralgia with an ESR of 141mm/hour.

ANCA test was positive - perinuclear pattern.

Gradual recovery of the neurological features occurred on treatment with cyclophosphamide and prednisone.

ANCA became negative and has remained so after cessation of continuous therapy for 2 years.

ANCA aided in diagnosis and management.

9. A 46 year old Indian female who was on treatment with prednisone for a multi-system disease, thought to be systemic lupus erythematosus developed severe destructive pneumonia leading to a lobectomy in Cape Town. Histology revealed Wegener's granulomatosis. Treatment with cyclophosphamide and prednisone was initiated. At this time, on treatment, the ANCA test was negative.

After withdrawal of treatment 4 years later, the test became positive, C-ANCA pattern. Maintenance treatment with cyclophosphamide has been resumed and the test is again negative. The patient remains well.

ANCA test was useful in treatment decisions.

10. A 60 year old White male with chronic sinusitis presented after a *grand mal* seizure. Investigation revealed sinus disease and a mass involving the base of the skull. Histology of tissue obtained by a trans-sphenoidal biopsy showed the presence of a necrotising granuloma. ANCA test was positive, C-ANCA pattern.

Treatment with cyclophosphamide produced resolution of the granuloma and the ANCA test became and remained negative until his death.

Bone marrow failure, possibly therapy-related (cyclophosphamide and phenytoin) complicated the course and resulted in death 18 months later.

ANCA assisted in the diagnosis.

11. A 31 year old Indian female died of acute hepatic failure after a 9 month multisystem illness for which a clear diagnosis was never established.

Thirteen years earlier, splenectomy had been done for chronic immune thrombocytopenia.

Features of the terminal illness included pulmonary infiltrates, focal segmental glomerulonephritis with vasculitis of interlobular arteries, paraparesis and arthralgia.

Several ANCA tests carried out during the late stages of her illness were positive with a strange pattern that we described as M-ANCA "mixed C and P". This would now be recognised as X-ANCA.

The first X-ANCA seen in the author's laboratory.

12. A 27 year old White man presented with arthralgia, epistaxis, haemoptysis, dyspnoea and rapidly progressive renal failure.

ANCA was positive - cytoplasmic pattern.

Renal biopsy supported the diagnosis of Wegener's granulomatosis.

All constitutional features resolved on treatment with cyclophosphamide and prednisone and the ANCA test became and has remained negative.

The patient remains well on maintenance dialysis without immunosuppressive therapy.

Classical association with Wegener's granulomatosis.

13. A 10 year old Black girl had generalised lymphadenopathy, hepatosplenomegaly and profound eosinophilia ($37 \times 10^9/l$). ESR was 129 mm/hr and hepatitis B antigen was present in the serum.

Various biopsies show eosinophil infiltration - "hypereosinophilic syndrome".

On two occasions, one year apart ANCA was strongly positive, X pattern.

An enigmatic association.

14. A 36 year old Black female was treated for tuberculosis suggested by cavitating disease of the right upper lobe and bilateral basal bronchiectasis. There was no improvement.

Further developments included encephalopathy with seizures, cardiomyopathy, proteinuria and renal insufficiency.

Renal biopsy showed neutrophil infiltration of glomeruli but no granuloma or vasculitis.

ANCA test was strongly positive - cytoplasmic pattern.

Treatment with cyclophosphamide and prednisone resulted in a marked overall improvement.

ANCA was of diagnostic value in this case.

This series of 14 cases illustrate the diverse presentation and varied clinical course of the ANCA associated diseases. We have observed both C and P-ANCA associated Wegener's granulomatosis, immediate and permanent clearing of antibody with immunosuppressive therapy and persisting antibody in patients in complete remission. In all these cases ANCA was a most useful adjunct to the successful diagnosis and treatment of these patients.

2.6 CONTROLS

Many workers have tested control populations in their environs. Falk and co-workers in 1988 were unable to demonstrate ANCA in the fifty normal controls that they tested. In a comprehensive study of the role of autoantibodies in the diagnosis of systemic vasculitis, Bleil's group in 1991 were unable to detect ANCA in 164 normal controls. The largest control group recorded in the literature comprised 319 normal volunteers and 714 patients with diseases other than of renal, autoimmune or infectious origin (Nölle 1989). Using the IIF method of screening all 1033 were ANCA negative.

Durban has a heterogenous population so it was important to test the local, normal population for the presence of ANCA. A total of one hundred and ninety nine controls were tested, forty by the original buffy coat smear indirect immunofluorescent technique (Chapter 1.2.2) and the remaining one hundred and fifty nine by the 16 well chamber slide method (Chapter 1.3.4). The 199 controls comprised 92 Blacks, 49 Whites and 58 Indians. All but 34 Black females were blood donors. These women were used as a control population in a separate study and they were all in their third trimester of pregnancy. The demographic details of these controls can be seen in Table 9.

Table 9

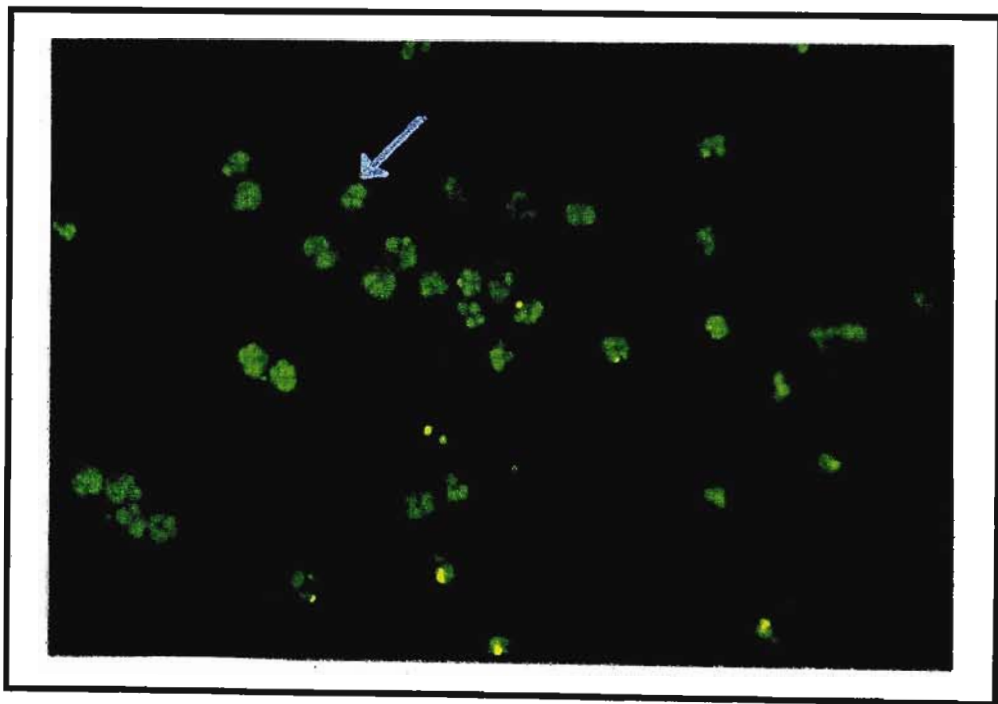
DEMOGRAPHIC DETAILS OF ONE HUNDRED AND NINETY NINE NORMAL CONTROLS.

	Male	Mean age	Female	Mean age
Black	36	29	56	27
White	38	45	11	37
Indian	48	31	10	29

All samples were tested singly and read independently by two workers. If there was any disagreement or if a positive result was found, the sample was retested in duplicate.

ANCA was not found in any of the Black control population. Three blood donors, two White males and one Indian male were found to have weak P-ANCA with definite nuclear staining (Plate 16). These three samples when tested for ANA were found to be positive on the HEp-2 substrate. The antibodies were weak and tests of specificity for ds-DNA and ENA's were negative. Of interest was the ages of these three donors 54, 56 and 44, as it is well documented that the incidence of antinuclear factor in the normal population increases with age.

Plate 16



→ Nuclear staining in a control. (Mag. x 300)

One White female 47 years old had P-ANCA and a negative test for antinuclear antibody. In a recent publication Stroncek (1993) showed that neutrophil alloantibodies formed in response to pregnancy or blood transfusion react with cytoplasmic antigens causing a false-positive ANCA test. It is therefore of interest that the ANCA positive control in this series is a female. Because of the anonymity of the controls, further details of this woman are unavailable. Kallenberg and co-workers in 1992 reported P-ANCA in 12 of 252 (5%) blood donors they tested, a much higher prevalence than in this control series.

In conclusion one of the 199 controls tested was P-ANCA positive, a prevalence of 0,5% in the local population. This low false positivity rate is important when interpreting ANCA results in this area.

CONCLUSION

In 1985 van der Woude published the new and exciting observation that the majority of patients with Wegener's granulomatosis have antibodies to a cytoplasmic component of neutrophils. The target antigen for this antibody was found to be Proteinase 3, a serine protease located in the primary granules of the neutrophil. Over the next few years several other neutrophil cytoplasmic antibodies were identified in various clinical situations but none of these antibodies has the high degree of specificity that Proteinase 3, C-ANCA has for Wegener's granulomatosis.

The first ANCA test was done in the author's laboratory in July 1987 and this thesis is based on six years of personal experience with the method and its interpretation.

The initial technique was cumbersome and time consuming, with one test sample processed on each slide, so an improved indirect immunofluorescent assay was developed for the rapid detection of antineutrophil cytoplasmic antibody activity. Sixteen serum samples can now be inexpensively processed on one slide, enabling negative, positive C and P-ANCA controls and duplicate patient testing to be done simultaneously. The easy washing and handling procedure of the 16 well chamber slide technique facilitates a testing time of two hours. When warranted, an urgent assay is of great value and can be provided, as prompt diagnosis and treatment of patients with systemic vasculitis is often critical to the successful management and outcome of the condition. Histological diagnosis although always desirable is at times, for

various reasons unobtainable. The ANCA test has been of life saving use in extremely enigmatic clinical situations.

As in most of the immunofluorescent techniques the performance and interpretation of this test requires a dedicated and experienced operator.

A new and interesting observation has been made of a disease association of ANCA in patients with amoebic liver abscess. Invasive amoebiasis is endemic to this region and the finding of C-ANCA in 98,7% of these patients, 75% of whom had Proteinase 3 specificity is of great interest. Internationally a high prevalence of Proteinase 3 specific C-ANCA has been reported only in patients with Wegener's granulomatosis. There is growing evidence of the pathogenic role ANCA plays in systemic vasculitis, but the implications of this finding for both the pathogenesis and the clinical relevance of ANCA in invasive amoebiasis are still to be elucidated.

This study has confirmed the value of the finding of this autoantibody in the settings of vasculitis, renal disease and inflammatory bowel disease. It also confirms the emerging evidence of "false positive" ANCA's in the major disease of immune-dysregulation, HIV infection. The finding of the varied ANCA specificities in the local population of Durban compares well with the reports in the literature by numerous workers in this field.

Although the "false positive" rate of ANCA in the normal volunteer blood donor population is low (0,5%), the fact that both HIV infection and invasive amoebiasis are endemic in this area must of necessity be kept in the mind of clinicians interpreting ANCA tests in this environment.

REFERENCES

- Adu D, Howie AJ, Scott DGI, Bacon PA, McGonigle RJS, Michael J. Polyarteritis and the kidney. *Q J Med* 1987; **62**: 221-237.
- Ålmroth G, Eneström S, Hed J, Samuelsson I, Sjöström P. Autoantibodies to leucocyte antigens in hydralazine-associated nephritis. *J Intern Med* 1992; **231**: 37-42.
- Bini P, Gabay JE, Teitel A, Melchior M, Zhou JL, Elkon KB. Antineutrophil autoantibodies in Wegener's granulomatosis recognize a conformational epitope(s) on proteinase 3. *J Immunol* 1992; **149**: 1409-1415.
- Bleil L, Manger B, Winkler H *et al.* The role of antineutrophil cytoplasm antibodies, anticardiolipin antibodies, and von Willebrand factor antigen, and fibronectin for the diagnosis of systemic vasculitis. *J Rheumatol* 1991; **18**: 1199-1206.
- Böyum A. Separation of leucocytes from blood and bone marrow. Paper I. Isolation of leucocytes from human blood. *Scan J Clin Lab Invest* 1968; **21 Suppl 97**: 9-29.
- Böyum A. Separation of leucocytes from blood and bone marrow. Paper IV. Isolation of mononuclear cells and granulocytes from human blood. *Scan J Clin Lab Invest* 1968; **21 Suppl 97**: 77-89.
- Broberger O, Perlmann P. Autoantibodies in human ulcerative colitis. *J Exp Med* 1959; **110**: 657-674.
- Calabresi P, Edwards EA, Schilling RF. Fluorescent antiglobulin studies in leukopenic and related disorders. *J Clin Invest* 1959; **38**: 2091-2100.
- Cambridge G, Rampton D, Leaker B. Anti-neutrophil antibodies in sera from patients with inflammatory bowel disease. *Am J Kidney Dis* 1991; **18**: 214.

- Chapel H, Haeney M. *Essentials of Clinical Immunology*. 3rd ed. Chapter 12 Gastrointestinal and liver diseases. 248. Blackwell Scientific publications. Oxford 1993.
- Cilursu AM, Goeken J, Olsen RR. Detection of antineutrophil cytoplasmic antibody in a patient with L-tryptophan induced eosinophilia-myalgia syndrome. *Ann Rheum Dis* 1991; **50**: 817-819.
- Cohen Tervaert JW, van der Woude FJ, Fauci AS *et al*. Association between active Wegener's granulomatosis and anticytoplasmic antibodies. *Arch Intern Med* 1989; **149**: 2461-2465.
- Cohen Tervaert JW, Goldschmeding R, Elema JD *et al*. Autoantibodies against myeloid lysosomal enzymes in crescentic glomerulonephritis. *Kidney Int* 1990; **37**: 799-806. (1)
- Cohen Tervaert JW, Goldschmeding R, Elema JD *et al*. Association of autoantibodies to myeloperoxidase with different forms of vasculitis. *Arthritis Rheum* 1990; **33**: 1264-1272. (2)
- Cohen Tervaert JW, Mulder AHL, Horst G, Haagsma EB, Kleibeuker JH, Kallenberg CGM. Antineutrophil cytoplasmic antibodies in autoimmune liver disease. (Letter) *Gastroenterology* 1992; **102**: 1090.
- Cornely O, Wiese C, Wiedemann M *et al*. P-ANCA in HIV infection-associations with CD4+ cell count, target proteins and Kaposi's sarcoma. *Clin Exp Immunol* 1993; **93 Suppl 1**: abstract 61.
- Davenport A. "False positive" perinuclear and cytoplasmic anti-neutrophil cytoplasmic antibody results leading to misdiagnosis of Wegener's granulomatosis and/or microscopic polyarteritis. *Clin Nephrol* 1992; **37**: 124-130.
- Davies DJ, Moran JE, Niall JF. Segmental necrotizing glomerulonephritis with antineutrophil antibody: possible arbovirus aetiology? *Brit Med J* 1982; **285**: 606.
- D'Cruz D, Hughes G. Systemic vasculitis: New tests, new treatments. *Brit Med J* 1992; **304**: 269-270.

- Duerr RH, Targan SR, Landers CJ *et al.* Neutrophil cytoplasmic antibodies: A link between primary sclerosing cholangitis and ulcerative colitis. *Gastroenterology* 1991; **100**: 1385-1391.(1)
- Duerr RH, Targan SR, Landers CJ, Sutherland LR, Shanahan F. Anti-neutrophil cytoplasmic antibodies in ulcerative colitis. *Gastroenterology* 1991; **100**: 1590-1596. (2)
- Efthimiou J, Spickett G, Lane D, Thompson A. Antineutrophil cytoplasmic antibodies, cystic fibrosis, and infection. (Letter) *Lancet* 1991; **337**: 1037-1038.
- Egner W, Chapel HM. Titration of antibodies against neutrophil cytoplasmic antigens is useful in monitoring disease activity in systemic vasculitides. *Clin Exp Immunol* 1990; **82**: 244-249.
- Esnault VLM, Ronda N, Jayne DRW, Lockwood CM. Association of ANCA isotype and affinity with disease expression. *J Autoimmun* 1993; **6**: 197-205.
- Faber V, Elling P, Norup G, Mansa B, Nissen NI. An antinuclear factor specific for leucocytes. *Lancet* 1964; **2**: 344-345.
- Falk RJ, Jennette JC. Anti-neutrophil cytoplasmic autoantibodies with specificity for myeloperoxidase in patients with systemic vasculitis and idiopathic necrotizing and crescentic glomerulonephritis. *N Eng J Med* 1988; **318**: 1651-1657.
- Falk RJ. ANCA-associated renal disease. *Kidney Int* 1990; **38**: 998-1010.
- Falk RJ and Jennette JC. Wegener's granulomatosis, systemic vasculitis, and antineutrophil cytoplasmic autoantibodies. *Annu Rev Med* 1991; **42**: 459-460. (1)
- Fauci AS (Moderator), Haynes BF, Katz P. The spectrum of Vasculitis. Clinical, pathologic, immunologic and therapeutic considerations. *Ann Intern Med* 1978; **89**: 660-676.

- Gallicchio MC, Savige JA. Detection of anti-myeloperoxidase and anti-elastase antibodies in vasculitides and infections. *Clin Exp Immunol* 1991; **84**: 232-237.
- Geffriaud-Ricouard C, Noël LH, Chaveau D, Houhou S, Grünfeld JP, Lesavre P. Clinical spectrum associated with ANCA of defined antigen specificities in 98 selected patients. *Clin Nephrol* 1993; **39**: 125-136.
- Goldschmeding R, Tetteroo PAT, Kr von dem Borne AEG, Kallenberg CGM. Anti-neutrophil cytoplasm antibodies in Wegener's granulomatosis are not directed against alkaline phosphatase. (Letter) *Lancet* 1987; **1**: 1489.
- Goldschmeding R, van der Schoot CE, van der Snoek MA, Kr von dem Borne AEG. A monoclonal antibody against the 29kD ANCA-antigen: Application as catching antibody in a sandwich-ELISA for ANCA detection. *APMIS Suppl 6* 1989; **97**: 47. (1)
- Goldschmeding R, van der Schoot CE, ten Bokkel Huinink D *et al.* Wegener's granulomatosis autoantibodies identify a novel diisopropylfluorophosphate binding protein in the lysosomes of normal human neutrophils. *J Clin Invest* 1989; **84**: 1577-1587. (2)
- Goldschmeding R, ten Bokkel Huinink D, Faber N *et al.* Identification of the "ANCA-antigen" as a novel myeloid lysosomal serine protease. *APMIS Suppl 6* 1989; **46** : 46. (3)
- Gross WL, Lüdemann G, Kiefer G, Lehmann H. Anticytoplasmic antibodies in Wegener's granulomatosis. (Letter) *Lancet* 1986; **1**: 806.
- Gross WL, Lüdemann J, Schroder JM. Anti-neutrophil cytoplasm antibodies in Wegener's granulomatosis are not directed against alkaline phosphatase. (Letter) *Lancet* 1987; **1**: 1488-1489.
- Gross WL, Schmitt WH, Csernok E. Antineutrophil cytoplasmic autoantibody-associated diseases: A rheumatologist's perspective. *Am J Kidney Dis* 1991; **18**: 175-179.
- Gross WL, Schmitt WH, Csernok E. Anca and associated diseases: immunodiagnostic and pathogenetic aspects. *Clin Exp Immunol* 1993; **91**: 1-12.(1)

- Gross WL, Csernok E, Flesch K. "Classic" anti-neutrophil cytoplasmic auto-antibodies (c-ANCA), "Wegener's autoantigen" and their immunopathogenic role in Wegener's granulomatosis. *J Autoimmun* 1993; **6**: 171-184. (2)
- Guerrant RL, Brush J, Ravdin JJ, Sullivan A, Mandell GL. Interaction between *Entamoeba histolytica* and human polymorphonuclear neutrophils. *J Infect Dis* 1981; **143**: 83-93.
- Hagen EC, Ballieux BEPB, Daha MR, van Es LA, van der Woude FJ. Fundamental clinical aspects of antineutrophil cytoplasmic antibodies (ANCA). *Autoimmunity* 1992; **11**: 199-207.
- Halbwachs-Mecarelli L, Nusbaum P, Noël LH *et al.* Antineutrophil cytoplasmic antibodies (ANCA) directed against cathepsin G in ulcerative colitis, Crohn's disease and primary sclerosing cholangitis. *Clin Exp Immunol* 1992; **90**: 79-84.
- Harrison DJ, Simpson R, Kharbanda R, Abernethy VE, Nimmo G. Antibodies to neutrophil cytoplasmic antigens in Wegener's granulomatosis and other conditions. *Thorax* 1989; **44**: 373-377.
- Hauschild S, Schwarting K, Czernok E *et al.* ANCA-finespecificities and disease activity in IBD. *Clin Exp Immunol* 1993; **93 Suppl 1**: Abstract 118. 46.
- Hoffman GS, Kerr GS, Leavitt RY *et al.* Wegener granulomatosis: An analysis of 158 patients. *Ann Intern Med* 1992; **116**: 488-498.
- Jackson TFHG, Duursma J, Simjee AE, Pudifin DJ. Application of the leucocyte adherence inhibition test to the assessment of cell mediated immunity in invasive amoebiasis. *Trans Roy Soc Trop Med Hyg* 1983; **77**: 121-125.
- Jaunkalns R, Shear NH, Sokoluk B, Gardner D, Claas F, Uetrecht JP. Anti-myeloperoxidase antibodies and adverse reactions to clozapine. (Letter) *Lancet* 1992; **339**: 1611-1612.

- Jayne DRW, Jones SJ, Severn A, Shaunak S, Murphy J, Lockwood CM. Severe pulmonary hemorrhage and systemic vasculitis in association with circulating antineutrophil cytoplasm antibodies of IgM class only. *Clin Nephrol* 1989; **32**: 101-106.
- Jennette JC, Wilkman AS, Falk RJ. Anti-neutrophil cytoplasmic autoantibody-associated glomerulonephritis and vasculitis. *Am J Pathol* 1989; **135**: 921-930.
- Jennette CJ, Falk RJ. Antineutrophil cytoplasmic autoantibodies and associated diseases: A review. *Am J Kidney Dis* 1990; **15**: 517-529. (1)
- Jennette JC, Hoidal JR, Falk RJ. Specificity of anti-neutrophil cytoplasmic autoantibodies for proteinase 3. (Letter) *Blood* 1990; **75 (11)**: 2263-2264. (2)
- Jennette JC, Falk RJ. Diagnostic classification of antineutrophil cytoplasmic autoantibody-associated vasculitides. *Am J Kidney Dis* 1991; **18**: 184-187.
- Jenne DE, Tschopp J, Lüdemann J, Utecht B, Gross WL. Wegener's autoantigen decoded. *Nature* 1990; **346**: 520.
- Jørgensen BB, Wiik A, Høier-Madsen M, Rasmussen N, Haagen Nielsen O. Serum antibodies to neutrophils in patients with chronic inflammatory bowel disease (CIBD). *Am J Kid Dis* 1991; **18(2)**: 214-215.
- Juby A, Johnston C, Davis P, Russell AS. Antinuclear and antineutrophil cytoplasmic antibodies (ANCA) in the sera of patients with Felty's syndrome. *Br J Rheumatol* 1992; **31**: 185-188.
- Kallenberg CGM, Cohen Tervaert JW, Van der Woude FJ, Goldschmeding R, Kr von dem Borne AEG, Weening JJ. Autoimmunity to lysosomal enzyme: New clues to vasculitis and glomerulonephritis? *Immunol Today* 1991; **12**: 61-64.
- Kallenberg CGM, Mulder AHL, Cohen Tervaert JW. Antineutrophil cytoplasmic antibodies: A still growing class of autoantibodies in inflammatory disorders. *Am J Med* 1992; **93**: 675-682.

- Kerr GS, Fleisher TA, Hallahan CW, Leavitt RY, Fauci AS, Hoffman GS. Limited prognostic value of changes in antineutrophil cytoplasmic antibody titer in patients with Wegener's granulomatosis. *Arthritis Rheum* 1993; **36**: 365-371.
- Klaassen RJL, Mulder JW, Vlekke ABJ *et al.* Autoantibodies against peripheral blood cells appear early in HIV infection and their prevalence increases with disease progression. *Clin Exp Immunol* 1990; **81**: 11-17.
- Klaassen RJL, Goldschmeding R, Dolman KM *et al.* Anti-neutrophil cytoplasmic autoantibodies in patients with symptomatic HIV infection. *Clin Exp Immunol* 1992; **87**: 24-30.
- Koderisch J, Andrassy K, Rasmussen N, Hartmann M, Tilgen W. "False positive" anti-neutrophil cytoplasmic antibodies in HIV infection. (Letter) *Lancet* 1990; **335**: 1227-1228.
- Korsmeyer SJ, Williams Jr RC, Wilson ID, Strickland RC. Lymphocytotoxic antibody in inflammatory bowel disease. A family study. *N Eng J Med* 1975; **293**: 1117-1120.
- Lehmann H, Rasmussen N. The histopathological definition of Wegener's granulomatosis. Translation from F Wegener's manuscript. *APMIS Suppl* 1990; **98**: 13-14.
- Lesavre P. Antineutrophil cytoplasmic autoantibodies antigen specificity. *Am J Kidney Dis* 1991; **18**: 159-163.
- Lesavre P, Noël LH, Gayno S *et al.* Atypical autoantigen targets of perinuclear antineutrophil cytoplasm antibodies (P-ANCA): specificity and clinical associations. *J Autoimmun* 1993; **6**: 185-195.
- Lie JT. Vasculitis and the gut: unwitting partners or strange bedfellows. (Editorial) *J Rheumatol* 1991; **18**: 647-649.
- Lockwood CM, Jones S, Moss DW, Bakes D, Whitaker KB, Savage COS. Association of alkaline phosphatase with an autoantigen recognised by circulating anti-neutrophil antibodies in systemic vasculitis. *Lancet* 1987; **1**: 716-720.(1)

- Lockwood CM, Thiru S, Isaacs JD, Hale G and Waldmann H. Long-term remission of intractable vasculitis with monoclonal antibody therapy. *Lancet* 1993; **341**: 1620-1622.
- Lüdemann GL, Gross WL. Autoantibodies against structures of neutrophil granulocytes in Wegener's granulomatosis. *Clin Exp Immunol* 1987; **69**: 350-357.
- Lüdemann GL, Utecht B, Gross WL. Anti-neutrophil cytoplasm antibodies in Wegener's granulomatosis recognize an elastinolytic enzyme. *J Exp Med* 1990; **171**: 357-362.
- Luvuno FM, Mtshali Z, Baker LW. Vascular occlusion in the pathogenesis of complicated amoebic colitis: evidence for an hypothesis. *Br J Surg* 1985; **72**: 123-127.
- Maclean C, Flegg PJ, Kilpatrick DC. Anti-cardiolipin antibodies and HIV infection. *Clin Exp Immunol* 1990; **81**: 263-266.
- Mann RJ, Probert CSJ, Tizard EJ, Mountford RA, Mayberry JF, Lock RJ. Prevalence of pANCA in South Asians and Europeans with ulcerative colitis. *Clin Exp Immunol* 1993; **93 Suppl 1**: Abstract 119: 47.
- Mårtensson U, Nässberger L. Circulating autoantibodies directed against beta-glucuronidase. *Autoimmunity* 1992; **11**: 213-214.
- Mulder AHL, Horst G, van Leeuwen MA, Limburg PC, Kallenberg CGM. Antineutrophil cytoplasmic antibodies in rheumatoid arthritis. Characterization and clinical correlations. *Arthritis Rheum* 1993; **36**: 1054-1060.
- Nässberger L, Sjöholm AG, Jonsson, Sturfelt G, Åkesson A. Autoantibodies against neutrophil cytoplasm components in systemic lupus erythematosus and in hydralazine-induced lupus. *Clin Exp Immunol* 1990; **81**: 380-383.
- Nauseef WM. Myeloperoxidase deficiency. *Hematol Oncol Clin North Am* 1988; **2**: 135-158.

- Niles JL, McCluskey T, Ahmad MF, Arnaout MA. Wegener's granulomatosis auto-antigen is a novel serine proteinase. *Blood* 1989; **74**: 1888-1893.
- Nölle B, Specks U, Lüdemann J, Rohrbach MS, DeRemee RA, Gross WL. Anticytoplasmic autoantibodies: their immunodiagnostic value in Wegener granulomatosis. *Ann Intern Med* 1989; **111**: 28-40.
- Ouchterlony O. Diffusion-in-gel methods for immunological analysis II. *Progress in Allergy* 1962; **6**: 30-154
- Oudkerk Pool M, Ellerbroek PM, Ridwan BU *et al*. Serum antineutrophil cytoplasmic auto-antibodies in inflammatory bowel disease are mainly associated with ulcerative colitis. A correlation study between perinuclear autoantibodies and clinical parameters, medical, and surgical treatment. *Gut* 1993; **34**: 46-50.
- Oudkerk Pool M, Remaux D, Pena AS *et al*. Differences in the prevalence of anti-neutrophil autoantibodies in European patients with inflammatory bowel disease. *Clin Exp Immunol* 1993; **93 Suppl 1**: Abstract 120: 47.
- Parlevliet KJ, Henzen-Logmans C, Oe PL, Bronsveld W, Balm AJM, Donker AJM. Antibodies to components of neutrophil cytoplasm: a new diagnostic tool in patients with Wegener's granulomatosis and systemic vasculitis. *QJ Med* 1988; **66**: 55-63.
- Patel RT, Varaganam M, Youngs D, Keighley MRB. Antineutrophil cytoplasmic antibodies with specificity for lactoferrin in ulcerative colitis. *Clin Exp Immunol* 1993; **93 Suppl 1**: Abstract 59: 31.
- Pettersson E, Heigl Z. Antineutrophil cytoplasmic antibody (cANCA and pANCA) titers in relation to disease activity in patients with necrotizing vasculitis : a longitudinal study. *Clin Nephrol* 1992; **37** : 219-228.
- Pudifin DJ, Naicker S, Patton MS *et al*. Circulating auto-antibodies to neutrophil cytoplasmic antigens in vasculitis. A report of 3 cases. *S A Med J* 1989; **75**: 73-75.

- Rasmussen N, Borregaard N, Wiik A. Anti-neutrophil-cytoplasm antibodies in Wegener's granulomatosis are not directed against alkaline phosphatase. *Lancet* 1987; **1**: 1488
- Rump JA, Schölmerich J, Gross V *et al.* A new type of perinuclear anti-neutrophil cytoplasmic antibody (p-ANCA) in active ulcerative colitis but not in Crohn's disease. *Immunobiology* 1990; **181**: 406-413.
- Rump JA, Schölmerich J, Roth M *et al.* A new type of p-ANCA in active ulcerative colitis. *Am J Kid Dis* 1991; **18**: 214.
- Saulsbury FT, Kirkpatrick PR, Bolton WK. IgA antineutrophil cytoplasmic antibody in Henoch-Schönlein purpura. *Am J Nephrol* 1991; **11**: 295-300.
- Savage COS, Lockwood CM. Autoantibodies in primary systemic vasculitis. *Adv Intern Med* 1990; **35**: 73-92.
- Savage COS, Cooke SP. The role of the endothelium in systemic vasculitis. *J Autoimmun* 1993; **6**: 237-249.
- Savigne JA, Gallicchio MC, Stockman A *et al.* Anti-neutrophil cytoplasm antibodies in rheumatoid arthritis. *Clin Exp Immunol* 1991; **86**: 92-98.
- Saxon A, Shanahan F, Landers C, Ganz TG, Targan S. A distinct subset of antineutrophil cytoplasmic antibodies is associated with inflammatory bowel disease. *J Allergy Clin Immunol* 1990; **86**: 202-210.
- Shaw G, Ronda N, Bevan JS, Esnault V, Griffiths DF, Rees A. Antineutrophil cytoplasmic antibodies (ANCA) of IgA class correlate with disease activity in adult Henoch-Schönlein purpura. *Nephrol Dial Transplant* 1992; **7** : 1238-1241.
- Specks U, DeRemee RA. Significance of antibodies to cytoplasmic components of neutrophils. (Editorial) *Thorax* 1989; **44**: 369-370. (1)

- Specks U, Wheatley CL, McDonald TJ, Rohrbach MS, DeRemee RA. Anticytoplasmic autoantibodies in the diagnosis and follow-up of Wegener's granulomatosis. *Mayo Clin Proc* 1989; **64**: 28-36. (2)
- Stroncek DF, Egging MS, Eiber GA, Clay ME. Neutrophil alloantibodies react with cytoplasmic antigens: a possible cause of false-positive indirect immunofluorescence assays for autoantibodies to neutrophil cytoplasmic antigens. *Am J Kidney Dis* 1993; **21**: 368-373.
- Targan SR, Saxon A, Landers C, Landers C, Ganz T, Shanahan F. Serum antineutrophil cytoplasmic autoantibodies distinguish between ulcerative colitis from Crohn's disease patients. *Gastroenterology* 1989; **96**: A 505 (Abstract).
- Van der Woude FJ, Rasmussen N, Lobatto S *et al.* Autoantibodies against neutrophils and monocytes: tool for the diagnosis and marker of disease activity in Wegener's granulomatosis. *Lancet* 1985; **1**: 425-429.
- Van der Woude FJ, Daha MR, Van Es LA. The current status of neutrophil cytoplasmic antibodies. *Clin Exp Immunol* 1989; **78**: 143-148.
- Venning MC, Quinn A, Broomhead V, Bird AG. Antibodies directed against neutrophils (C-ANCA and P-ANCA) are of distinct diagnostic value in systemic vasculitis. *Q J Med* 1990; **77**: 1287-1296.
- Wathen CW, Harrison DJ. Circulating anti-neutrophil antibodies in systemic vasculitis. *Lancet* 1987; **1**: 1037.
- Wiik A. Granulocyte specific antinuclear antibodies. Possible significance for the pathogenesis, clinical features and diagnosis of rheumatoid arthritis. *Allergy* 1980; **35**: 263-289.
- Wiik A. Delineation of a standard procedure for indirect immunofluorescence detection of ANCA. *APMIS Suppl 6* 1989; **97**: 12-13.

SELECTED BIBLIOGRAPHY

- Addis BJ. Wegener's granulomatosis, ANCA, and microscopic polyarteritis. (Editorial) *J Pathol* 1991; **164**: 189-190.
- Adu D, Howie AJ, Scott DGI, Bacon PA, McGonigle RJS, Michael J. Polyarteritis and the kidney. *Q J Med* 1987; **62**: 221-237.
- Ålmroth G, Eneström S, Hed J, Samuelsson I, Sjöström P. Autoantibodies to leucocyte antigens in hydralazine-associated nephritis. *J Intern Med* 1992; **231**: 37-42.
- Andrassy K, van der Woude FJ. Detection of ANCA by immunofluorescence techniques. *Neth J Med* 1990; **36**: 128-131.
- Andrassy K, Erb A, Koderisch J, Waldherr R, Ritz E. Wegener's granulomatosis with renal involvement: patient survival and correlations between initial renal function, renal histology, therapy and renal outcome. *Clin Nephrol* 1991; **35**: 139-147.
- Andrassy K, Waldherr R, Erb A, Ritz E. De novo glomerulonephritis in patients during remission from Wegener's granulomatosis. *Clin Nephrol* 1992; **38**: 295-298.
- Beer DJ. ANCAs aweigh. (Editorial) *Am Rev Respir Dis* 1992; **146**: 1128-1130.
- Bindi P, Mougenot B, Mentre F *et al.* Necrotizing crescentic glomerulonephritis without significant immune deposits: a clinical and serological study. *Q J Med* 1993; **86**: 55-68.
- Bini P, Gabay JE, Teitel A, Melchior M, Zhou JL, Elkou KB. Antineutrophil cytoplasmic autoantibodies in Wegener's granulomatosis recognize a conformational epitope(s) on proteinase 3. *J Immunol* 1992; **149**: 1409-1415.

- Blann AD, Scott DGI. Activated, cytotoxic lymphocytes in systemic vasculitis. *Rheumatol Int* 1991; **11**: 69-72.
- Bleil L, Manger B, Winkler H *et al*. The role of antineutrophil cytoplasm antibodies, anticardiolipin antibodies, and von Willebrand factor antigen, and fibronectin for the diagnosis of systemic vasculitis. *J Rheumatol* 1991; **18**: 1199-1206.
- Bosch X, Font J, Mirapeix E, Revert L, Ingelmo M, Urbano-Marquez A. Antimyeloperoxidase autoantibody-associated necrotizing alveolar capillaritis. *Am Rev Respir Dis* 1992; **146**: 1326-1329.
- Bosch X, Asherson RA. The antigenic significance and methods of detection of the anti-neutrophil cytoplasmic autoantibodies (ANCA). *Postgrad Med J* 1992; **68**: 707-713.
- Bosch X, Mirapeix E, Font J *et al*. Anti-myeloperoxidase autoantibodies in patients with necrotizing glomerular and alveolar capillaritis. *Am J Kidney Dis* 1992; **20**: 231-239.
- Böttinger EP, Niles JL, Collins AB, McCluskey RT, Arnaout MA. Antineutrophil cytoplasmic autoantibody-associated vasculitis presenting as Sjogren's syndrome. *Arthritis Rheum* 1992; **35**: 1373-1376.
- Böyum A. Separation of leucocytes from blood and bone marrow. Paper I. Isolation of leucocytes from human blood. *Scan J Clin Lab Invest* 1968; **21 Suppl 97**: 9-29.
- Böyum A. Separation of leucocytes from blood and bone marrow. Paper IV. Isolation of mononuclear cells and granulocytes from human blood. *Scan J Clin Lab Invest* 1968; **21 Suppl 97**: 77-89.
- Brasile L, Kremer JM, Clarke JL, Cerilli J. Identification of an autoantibody to vascular endothelial cell-specific antigens in patients with systemic vasculitis. *Am J Med* 1989; **87**: 74-80.

- Braun MG, Csernok E, Gross WL, Müller-Hermelink HK. Proteinase 3, the target antigen of anticytoplasmic antibodies circulating in Wegener's granulomatosis. Immunolocalization in normal and pathologic tissues. *Am J Pathol* 1991; **139**: 831-838.
- Broberger O, Perlmann P. Autoantibodies in human ulcerative colitis. *J Exp Med* 1959; **110**: 657-674.
- Bygren P, Rasmussen N, Isaksson B, Wieslander J. Anti-neutrophil cytoplasm antibodies, anti-GBM antibodies and anti ds-DNA antibodies in glomerulonephritis. *Eur J Clin Invest* 1992; **22**: 783-792.
- Calabresi P, Edwards EA, Schilling RF. Fluorescent antiglobulin studies in leukopenic and related disorders. *J Clin Invest* 1959; **38**: 2091-2100.
- Cambridge G, Rampton D, Leaker B. Anti-neutrophil antibodies in sera from patients with inflammatory bowel disease. *Am J Kidney Dis* 1991; **18**: 214.
- Cameron JS. Advances in secondary glomerulonephritis of childhood. (Abstract) *Pediatr Nephrol* 1992; **6 (5)**: C29-C30.
- Chapel H, Haeney M. *Essentials of Clinical Immunology*. 3rd ed. Chapter 12 Gastrointestinal and liver diseases. 248. Blackwell Scientific publications. Oxford 1993.
- Charles LA, Falk RJ, Jennette JC. Reactivity of anti-neutrophil cytoplasmic autoantibodies with HL-60 cells. *Clin Immunol Immunopathol* 1989; **53**: 243-253.
- Chevallier A, Noel LH, Renier G *et al*. Determination of anti-neutrophil cytoplasm antibodies (ANCA) specificity by immunofluorescence on chronic myelocytic leukemia cells. *J Immunol Methods* 1992; **147**: 101-109.
- Churg J. Nomenclature of vasculitic syndromes: a historical perspective. *Am J Kidney Dis* 1991; **18**: 148-153.

- Cilursu AM, Goeken J, Olsen RR. Detection of antineutrophil cytoplasmic antibody in a patient with L-tryptophan induced eosinophilia-myalgia syndrome. *Ann Rheum Dis* 1991; **50**: 817-819.
- Cohen Tervaert JW, van der Woude FJ, Fauci AS *et al.* Association between active Wegener's granulomatosis and anticytoplasmic antibodies. *Arch Intern Med* 1989; **149**: 2461-2465.
- Cohen Tervaert JW, Goldschmeding R, Elema JD *et al.* Autoantibodies against myeloid lysosomal enzymes in crescentic glomerulonephritis. *Kidney Int* 1990; **37**: 799-806.
- Cohen Tervaert JW, Goldschmeding R, Elema JD *et al.* Association of autoantibodies to myeloperoxidase with different forms of vasculitis. *Arthritis Rheum* 1990; **33**: 1264-1272.
- Cohen Tervaert JW, Huitema MG, Hené RJ *et al.* Prevention of relapses in Wegener's granulomatosis by treatment based on antineutrophil cytoplasmic antibody titre. *Lancet* 1990; **336**: 709-711.
- Cohen Tervaert JW, Limburg PC, Elema JD *et al.* Detection of autoantibodies against myeloid lysosomal enzymes: a useful adjunct to classification of patients with biopsy-proven necrotizing arteritis. *Am J Med* 1991; **91**: 59-66.
- Cohen Tervaert JW, Mulder AHL, Horst G, Haagsma EB, Kleibeuker JH, Kallenberg CGM. Antineutrophil cytoplasmic antibodies in autoimmune liver disease. (Letter) *Gastroenterology* 1992; **102**: 1090.
- Cotran RS. Pathogenesis of vasculitis: an update. *Adv Pathol* 1990; **3**: 301-310.
- Cornely O, Wiese C, Wiedemann M *et al.* P-ANCA in HIV infection-associations with CD4+ cell count, target proteins and Kaposi's sarcoma. *Clin Exp Immunol* 1993; **93 Suppl 1**: abstract 61.
- Cross CE, Lillington GA. Serodiagnosis of Wegener's granulomatosis : pathobiologic and clinical implications. (Editorial) *Mayo Clin Proc* 1989; **64**: 119-122.

- Csernok E, Lüdemann J, Gross WL, Bainton DF. Ultrastructural localization of proteinase 3, the target antigen of anti-cytoplasmic antibodies circulating in Wegener's granulomatosis. *Am J Pathol* 1990; **137**: 1113-1120.
- Davenport A. "False positive" perinuclear and cytoplasmic anti-neutrophil cytoplasmic antibody results leading to misdiagnosis of Wegener's granulomatosis and/or microscopic polyarteritis. *Clin Nephrol* 1992; **37**: 124-130.
- Davies DJ, Moran JE, Niall JF. Segmental necrotizing glomerulonephritis with antineutrophil antibody: possible arbovirus aetiology? *Brit Med J* 1982; **285**: 606.
- D'Cruz D, Hughes G. Systemic vasculitis: New tests, new treatments. *Brit Med J* 1992; **304**: 269-270.
- Del Papa N, Meroni PL, Barcellini W *et al.* Antibodies to endothelial cells in primary vasculitides mediate *in vitro* endothelial cytotoxicity in the presence of normal peripheral blood mononuclear cells. *Clin Immunol Immunopathol* 1992; **63**: 267-274.
- De Meester F, Shaw E, Scholz H, Solarsky T, Mirelman D. Specific labelling of cysteine proteinases in pathogenic and nonpathogenic *Entamoeba histolytica*. *Infect Immun* 1990; **58**: 1396-1401.
- De Remeé RA. Antineutrophil cytoplasmic autoantibody-associated diseases: A pulmonologist's perspective. *Am J Kidney Dis* 1991; **18**: 180-183.
- Dolman KM, Goldschmeding R, Sonnenberg A, von dem Borne AEGK. ANCA related antigens. *APMIS* 1990; **98 Suppl 19**: 28.
- Dreisin RB. New perspectives in Wegener's granulomatosis. *Thorax* 1993; **48**: 97-99.
- Duerr RH, Targan SR, Landers CJ *et al.* Neutrophil cytoplasmic antibodies: A link between primary sclerosing cholangitis and ulcerative colitis. *Gastroenterology* 1991; **100**: 1385-1391.

- Duerr RH, Targan SR, Landers CJ, Sutherland LR, Shanahan F. Anti-neutrophil cytoplasmic antibodies in ulcerative colitis. *Gastroenterology* 1991; **100**: 1590-1596.
- Edgar JDM, Rooney DP, McNamee P, McNeill TA. An association between ANCA positive renal disease and malignancy. *Clin Nephrol* 1993; **40**: 22-25.
- Efthimiou J, Spickett G, Lane D, Thompson A. Antineutrophil cytoplasmic antibodies, cystic fibrosis, and infection. (Letter) *Lancet* 1991; **337**: 1037-1038.
- Egner W, Chapel HM. Titration of antibodies against neutrophil cytoplasmic antigens is useful in monitoring disease activity in systemic vasculitides. *Clin Exp Immunol* 1990; **82**: 244-249.
- Ehrenstein MR, Leaker B, Isenberg D, Cambridge G. Production of human monoclonal antibodies to myeloperoxidase. *Immunology* 1992; **77**: 617-620.
- Esnault VLM, Jayne DRW, Weetman AP, Lockwood CM. IgG subclass distribution and relative functional affinity of anti-myeloperoxidase antibodies in systemic vasculitis at presentation and during follow-up. *Immunology* 1991; **74**: 714-718.
- Esnault VLM, Ronda N, Jayne DRW, Lockwood CM. Association of ANCA isotype and affinity with disease expression. *J Autoimmun* 1993; **6**: 197-205.
- Ewert BH, Jennette JC, Falk RJ. The pathogenic role of antineutrophil cytoplasmic autoantibodies. *Am J Kidney Dis* 1991; **18**: 188-195.
- Faber V, Elling P, Norup G, Mansa B, Nissen NI. An antinuclear factor specific for leucocytes. *Lancet* 1964; **2**: 344-345.
- Falk RJ, Jennette JC. Anti-neutrophil cytoplasmic autoantibodies with specificity for myeloperoxidase in patients with systemic vasculitis and idiopathic necrotizing and crescentic glomerulonephritis. *N Eng J Med* 1988; **318**: 1651-1657.

- Falk RJ, Terrell RS, Charles LA, Jennette JC. Anti-neutrophil cytoplasmic autoantibodies induce neutrophils to degranulate and produce oxygen radicals *in vitro*. *Proc Natl Acad Sci USA* 1990; **87**: 4115-4119.
- Falk RJ, Hogan S, Carey TS, Jennette JC. Clinical course of anti-neutrophil cytoplasmic autoantibody-associated glomerulonephritis and systemic vasculitis. *Ann Intern Med* 1990; **113**: 656-663.
- Falk RJ. ANCA-associated renal disease. *Kidney Int* 1990; **38**: 998-1010.
- Falk RJ and Jennette JC. Wegener's granulomatosis, systemic vasculitis, and antineutrophil cytoplasmic autoantibodies. *Annu Rev Med* 1991; **42**: 459-469.
- Falk RJ, Jennette JC. The third international workshop on antineutrophil cytoplasmic autoantibodies. (Introduction) *Am J Kidney Dis* 1991; **18**: 145-147.
- Falk RJ, Becker M, Terrell R, and Jennette JC. Anti-myeloperoxidase autoantibodies react with native but not denatured myeloperoxidase. *Clin Exp Immunol* 1992; **89**: 274-278.
- Fauci AS (Moderator), Haynes BF, Katz P. The spectrum of Vasculitis. Clinical, pathologic, immunologic and therapeutic considerations. *Ann Intern Med* 1978; **89**: 660-676.
- Field M. Antineutrophil cytoplasmic antibodies (ANCA): their role in diagnosis and pathogenesis of vasculitis. *Br J Rheumatol* 1991; **30**: 229-231.
- Frampton G, Jayne DRW, Perry GJ, Lockwood CM, Cameron JS. Autoantibodies to endothelial cells and neutrophil cytoplasmic antigens in systemic vasculitis. *Clin Exp Immunol* 1990; **82**: 227-232.
- François A, Dhib M, Dubois D, Fillastre, Hemet J. Thrombotic microangiopathy (TMA) as the first manifestation of HIV infection. *Clin Nephrol* 1993; **39**: 352-354.

- Fries JF, Hunder GG, Bloch DA et al. The American College of Rheumatology 1990 criteria for the classification of vasculitis. *Arthritis Rheum* 1990; **33**: 1135-1136.
- Gabay JE, Almeida RP. Antibiotic peptides and serine protease homologs in human polymorphonuclear leukocytes: defensins and azurocidin. *Curr Opin Immunol* 1993; **5**: 97-102.
- Gall EP. Immunotesting for diagnosis in rheumatic diseases. (Editorial) *Arch Intern Med* 1989; **149**: 2401-2402.
- Gallicchio MC, Savige JA. Detection of anti-myeloperoxidase and anti-elastase antibodies in vasculitides and infections. *Clin Exp Immunol* 1991; **84**: 232-237.
- Gans R, De Vries N, Donker AJM, Goldschmeding R, Hoorntje SJ. Circulating anti-neutrophil cytoplasmic autoantibodies in subglottic stenosis: a useful aid in diagnosing vasculitis in this condition? *Q J Med* 1991; **291**: 565-574.
- Garrett PJ, Dewhurst AG, Morgan LS, Mason JC, Dathan JR. Renal disease associated with circulating antineutrophil cytoplasmic activity. *Q J Med* 85 1992; **306**: 731-749.
- Gaskin G, Savage COS. Immune markers in vasculitis. *Br J Hosp Med* 1991; **46**: 104-106.
- Geffriaud-Ricouard C, Noël LH, Chaveau D, Houhou S, Grünfeld JP, Lesavre P. Clinical spectrum associated with ANCA of defined antigen specificities in 98 selected patients. *Clin Nephrol* 1993; **39**: 125-136.
- Geiger WJ, Garrison KL, Losh DP. Wegener's granulomatosis. *Am Fam Physician* 1992; **45**: 191-196.
- Goeken JA. Antineutrophil cytoplasmic antibody - A useful serological marker for vasculitis. *J Clin Immunol* 1991; **11**: 161-174.

- Goldschmeding R, Tetteroo PAT, Kr von dem Borne AEG, Kallenberg CGM. Anti-neutrophil cytoplasm antibodies in Wegener's granulomatosis are not directed against alkaline phosphatase. (Letter) *Lancet* 1987; **1**: 1489.
- Goldschmeding R, van der Schoot CE, van der Snoek MA, Kr von dem Borne AEG. A monoclonal antibody against the 29kD ANCA-antigen: Application as catching antibody in a sandwich-ELISA for ANCA detection. *APMIS Suppl 6* 1989; **97**: 47.
- Goldschmeding R, CohenTervaert JW, van der Schoot CE, van der Veen C, Kallenberg CGM, Kr von dem Borne AEG. ANCA, anti-myeloperoxidase, and anti-elastase: Three members of a novel class of autoantibodies against myeloid lysosomal enzymes. *APMIS Suppl 6* 1989; **97**: 48-49.
- Goldschmeding R, van der Schoot CE, ten Bokkel Huinink D *et al.* Wegener's granulomatosis autoantibodies identify a novel diisopropylfluorophosphate binding protein in the lysosomes of normal human neutrophils. *J Clin Invest* 1989; **84**: 1577-1587.
- Goldschmeding R, ten Bokkel Huinink D, Faber N *et al.* Identification of the "ANCA-antigen" as a novel myeloid lysosomal serine protease. *APMIS Suppl 6* 1989; **46** : 46.
- Goldschmeding R, Dolman KM, van den Ende ME, van der Meer-Gerritsen CH, Sonnenberg A, von dem Borne AEG. The relation of 29kD C-ANCA antigen to proteinase 3. *APMIS Suppl. 19*, 1990; **98**: 26-27.
- Gross WL, Lüdemann G, Kiefer G, Lehmann H. Anticytoplasmic antibodies in Wegener's granulomatosis. (Letter) *Lancet* 1986; **1**: 806.
- Gross WL, Lüdemann J, Schröder JM. Anti-neutrophil cytoplasm antibodies in Wegener's granulomatosis are not directed against alkaline phosphatase. (Letter) *Lancet* 1987; **1**: 1488-1489.
- Gross WL, Schmitt WH, Csernok E. Antineutrophil cytoplasmic autoantibody-associated diseases: A rheumatologist's perspective. *Am J Kidney Dis* 1991; **18**: 175-179.

- Gross WL, Schmitt WH, Csernok E. Anca and associated diseases: immunodiagnostic and pathogenetic aspects. *Clin Exp Immunol* 1993; **91**: 1-12.
- Gross WL, Csernok E, Flesch K. "Classic" anti-neutrophil cytoplasmic autoantibodies (c-ANCA), "Wegener's autoantigen" and their immunopathogenic role in Wegener's granulomatosis. *J Autoimmun* 1993; **6**: 171-184.
- Grotz W, Wanner C, Keller E *et al.* Crescentic glomerulonephritis in Wegener's granulomatosis: morphology, therapy, outcome. *Clin Nephrol* 1991; **35**: 243-251.
- Guerrant RL, Brush J, Ravdin JI, Sullivan A, Mandell GL. Interaction between *Entamoeba histolytica* and human polymorphonuclear neutrophils. *J Infect Dis* 1981; **143**: 83-93.
- Guillevin L, Visser H, Oksman F, Pourrat J. Antineutrophil cytoplasmic antibodies in polyarteritis nodosa related to hepatitis B virus. (Letter) *Arthritis Rheum* 1990 ; **33**: 1871-1872.
- Hagen EC, Ballieux BEPB, Daha MR, van Es LA, van der Woude FJ. Fundamental clinical aspects of antineutrophil cytoplasmic antibodies (ANCA). *Autoimmunity* 1992; **11**: 199-207.
- Hagen E C, Ballieux BEPB, van Es LA, Daha MR, van der Woude FJ. Antineutrophil cytoplasmic autoantibodies: a review of the antigens involved, the assays, and the clinical and possible pathogenetic consequences. *Blood* 1993; **81**: 1996-2002.
- Halbwachs-Mecarelli L, Nusbaum P, Noël LH *et al.* Antineutrophil cytoplasmic antibodies (ANCA) directed against cathepsin G in ulcerative colitis, Crohn's disease and primary sclerosing cholangitis. *Clin Exp Immunol* 1992; **90**: 79-84.
- Harrison DJ, Simpson R, Kharbanda R, Abernethy VE, Nimmo G. Antibodies to neutrophil cytoplasmic antigens in Wegener's granulomatosis and other conditions. *Thorax* 1989; **44**: 373-377.

- Hauschild S, Schwarting K, Czernok E *et al.* ANCA-finespecificities and disease activity in IBD. *Clin Exp Immunol* 1993; **93 Suppl 1**: Abstract 118: 46.
- Herrero-Beaumont G, Armas JB, Amorim R, Shenstone B, Bhalla A, Maddison PJ. Limited forms of Wegener's granulomatosis presenting as polymyalgia rheumatica. *Br J Rheumatol* 1991; **30**: 382-384.
- Hoffman GS, Kerr GS, Leavitt RY *et al.* Wegener granulomatosis: An analysis of 158 patients. *Ann Intern Med* 1992; **116**: 488-498.
- Hunder GG, Arend WP, Bloch DA *et al.* The American College of Rheumatology 1990 criteria for the classification of vasculitis. *Arthritis Rheum* 1990; **33**: 1065-1067.
- Jackson TFHG, Duursma J, Simjee AE, Pudifin DJ. Application of the leucocyte adherence inhibition test to the assessment of cell mediated immunity in invasive amoebiasis. *Trans Roy Soc Trop Med Hyg* 1983; **77**: 121-125.
- Jarumilinta R, Kradolfer F. The toxic effect of *Entamoeba histolytica* on leucocytes. *Ann Trop Med Parasitol* 1964; **58**: 375-381.
- Jaunkalns R, Shear NH, Sokoluk B, Gardner D, Claas F, Uetrecht JP. Anti-myeloperoxidase antibodies and adverse reactions to clozapine. (Letter) *Lancet* 1992; **339**: 1611-1612.
- Jayne DRW, Jones SJ, Severn A, Shaunak S, Murphy J, Lockwood CM. Severe pulmonary hemorrhage and systemic vasculitis in association with circulating antineutrophil cytoplasm antibodies of IgM class only. *Clin Nephrol* 1989; **32**: 101-106.
- Jayne DRW, Marshall PD, Jones SJ, Lockwood CM. Autoantibodies to GBM and neutrophil cytoplasm in rapidly progressive glomerulonephritis. *Kidney Int* 1990; **37**: 965-970.

- Jayne DRW, Esnault VLM, Lockwood CM. Anti-idiotypic antibodies to anti-myeloperoxidase autoantibodies in patients with systemic vasculitis. *J Autoimmun* 1993; **6**: 221-226.
- Jayne DRW, Esnault VLM, Lockwood CM. ANCA anti-idiotypic antibodies and the treatment of systemic vasculitis with intravenous immunoglobulin. *J Autoimmun* 1993; **6**: 207-219.
- Jennette JC, Falk RJ. Anti-neutrophil cytoplasmic autoantibodies. (Letter) *N Engl J Med* 1988; **319**: 1417.
- Jennette JC, Wilkman AS, Falk RJ. Anti-neutrophil cytoplasmic autoantibody-associated glomerulonephritis and vasculitis. *Am J Pathol* 1989; **135**: 921-930.
- Jennette CJ, Falk RJ. Antineutrophil cytoplasmic autoantibodies and associated diseases: A review. *Am J Kidney Dis* 1990; **15**: 517-529.
- Jennette JC, Hoidal JR, Falk RJ. Specificity of anti-neutrophil cytoplasmic autoantibodies for proteinase 3. (Letter) *Blood* 1990; **75**: 2263-2264.
- Jennette JC. Antineutrophil cytoplasmic autoantibody-associated diseases: A pathologist's perspective. *Am J Kidney Dis* 1991; **18**: 164-170.
- Jennette JC, Falk RJ. Diagnostic classification of antineutrophil cytoplasmic autoantibody-associated vasculitides. *Am J Kidney Dis* 1991; **18**: 184-187.
- Jenne DE, Tschopp J, Lüdemann J, Utecht B, Gross WL. Wegener's autoantigen decoded. *Nature* 1990; **346**: 520.
- Jørgensen BB, Wiik A, Høier-Madsen M, Rasmussen N, Haagen Nielsen O. Serum antibodies to neutrophils in patients with chronic inflammatory bowel disease (CIBD). *Am J Kidney Dis* 1991; **18**: 214-215.
- Juby A, Johnston C, Davis P, Russell AS. Antinuclear and antineutrophil cytoplasmic antibodies (ANCA) in the sera of patients with Felty's syndrome. *Br J Rheumatol* 1992; **31**: 185-188.

- Kallenberg CGM, Rasmussen N. Solid phase assays for ANCA. *Neth J Med* 1990; **36**: 132-136.
- Kallenberg CGM, Cohen Tervaert JW, van der Woude FJ, Goldschmeding R, Kr von dem Borne AEG, Weening JJ. Autoimmunity to lysosomal enzyme: New clues to vasculitis and glomerulonephritis ? *Immunol Today* 1991; **12**: 61-64.
- Kallenberg CGM, Mulder AHL, Cohen Tervaert JW. Antineutrophil cytoplasmic antibodies: A still growing class of autoantibodies in inflammatory disorders. *Am J Med* 1992; **93**: 675-682.
- Keogan MT, Esnault VLM, Green AJ, Lockwood CM, Brown DL. Activation of normal neutrophils by anti-neutrophil cytoplasm antibodies. *Clin Exp Immunol* 1992; **90**: 228-234.
- Kerr GS, Fleisher TA, Hallahan CW, Leavitt RY, Fauci AS, Hoffman GS. Limited prognostic value of changes in antineutrophil cytoplasmic antibody titer in patients with Wegener's granulomatosis. *Arthritis Rheum* 1993; **36**: 365-371.
- Klaassen RJL, Mulder JW, Vlekke ABJ *et al.* Autoantibodies against peripheral blood cells appear early in HIV infection and their prevalence increases with disease progression. *Clin Exp Immunol* 1990; **81**: 11-17.
- Klaassen RJL, Goldschmeding R, Dolman KM *et al.* Anti-neutrophil cytoplasmic autoantibodies in patients with symptomatic HIV infection. *Clin Exp Immunol* 1992; **87**: 24-30.
- Koderisch J, Andrassy K, Rasmussen N, Hartmann M, Tilgen W. "False positive" anti-neutrophil cytoplasmic antibodies in HIV infection. (Letter) *Lancet* 1990; **335**: 1227-1228.
- Korsmeyer SJ, Williams Jr RC, Wilson ID, Strickland RC. Lymphocytotoxic antibody in inflammatory bowel disease. A family study. *N Eng J Med* 1975; **293**: 1117-1120.

- Lai KN, Jayne DRW, Brownlee A, Lockwood CM. The specificity of antineutrophil cytoplasm antibodies in systemic vasculitis. *Clin Exp Immunol* 1990; **82**: 233-237.
- Leaker B, Cambridge G. Anti-neutrophil cytoplasmic antibodies and vasculitis. *Postgrad Med J* 1990; **66**: 77-79.
- Leavitt RY, Fauci AS, Bloch DA *et al.* The American College of Rheumatology 1990 criteria for the classification of Wegener's granulomatosis. *Arthritis Rheum* 1990; **33**: 1101-1107.
- Lee SS, Adu D, Thompson RA. Anti-myeloperoxidase antibodies in systemic vasculitis. *Clin Exp Immunol* 1990; **79**: 41-46.
- Lehmann H, Kieffer B. Clinical manifestations of Wegener's granulomatosis. *APMIS Suppl 19* 1990; **98**: 19-20.
- Lehmann H, Rasmussen N. The histopathological definition of Wegener's granulomatosis. Translation from F Wegener's manuscript. *APMIS Suppl 19* 1990; **98**: 13-14.
- Lesavre P. Antineutrophil cytoplasmic autoantibodies antigen specificity. *Am J Kidney Dis* 1991; **18**: 159-163.
- Lesavre P, Noël LH, Gayno S *et al.* Atypical autoantigen targets of perinuclear antineutrophil cytoplasm antibodies (P-ANCA): specificity and clinical associations. *J Autoimmun* 1993; **6**: 185-195.
- Lie JT. Vasculitis and the gut: unwitting partners or strange bedfellows. (Editorial) *J Rheumatol* 1991; **18** : 647-649.
- Lightfoot, Jr. RW, Michel BA, Bloch DA *et al.* The American College of Rheumatology 1990 criteria for the classification of polyarteritis nodosa. *Arthritis Rheum* 1990; **33**: 1088-1093.
- Lo SK, Fleming KA, Chapman RW. Prevalence of anti-neutrophil antibody in primary sclerosing cholangitis and ulcerative colitis using an alkaline phosphatase technique. *Gut* 1992; **33**: 1370-1375.

- Lo SK, Chapman RWG, Cheeseman P *et al.* Antineutrophil antibody: a test for autoimmune primary sclerosing cholangitis in childhood? *Gut* 1993; **34**: 199-202.
- Lockwood CM, Jones S, Moss DW, Bakes D, Whitaker KB, Savage COS. Association of alkaline phosphatase with an autoantigen recognised by circulating anti-neutrophil antibodies in systemic vasculitis. *Lancet* 1987; **1**: 716-720.
- Lockwood CM. Anti-neutrophil-cytoplasm antibodies in Wegener's Granulomatosis are not directed against alkaline phosphatase. (Letter) *Lancet* 1987; **1**: 1489-1490.
- Lockwood CM. Antineutrophil cytoplasmic autoantibodies: the nephrologist's perspective. *Am J Kidney Dis* 1991; **18**: 171-174.
- Lockwood CM, Thiru S, Isaacs JD, Hale G and Waldmann H. Long-term remission of intractable vasculitis with monoclonal antibody therapy. *Lancet* 1993; **341**: 1620-1622.
- Lockwood CM. Specificity and pathogenicity of antineutrophil cytoplasm antibodies. *Exp Nephrol* 1993; **1**: 13-18.
- Lüdemann GL, Gross WL. Autoantibodies against structures of neutrophil granulocytes in Wegener's granulomatosis. *Clin Exp Immunol* 1987; **69**: 350-357.
- Lüdemann J, Utecht B, Gross WL. Anti-neutrophil cytoplasm antibodies in Wegener's granulomatosis recognize an elastinolytic enzyme. *J Exp Med* 1990; **171**: 357-362.
- Luvuno FM, Mtshali Z, Baker LW. Vascular occlusion in the pathogenesis of complicated amoebic colitis: evidence for an hypothesis. *Br J Surg* 1985; **72**: 123-127.
- Maclean C, Flegg PJ, Kilpatrick DC. Anti-cardiolipin antibodies and HIV infection. *Clin Exp Immunol* 1990; **81**: 263-266.

- Malech HL, Gallin JI. Current concepts: Immunology. Neutrophils in human diseases. *N Eng J Med* 1987; **317**: 687-694.
- Mann RJ, Probert CSJ, Tizard EJ, Mountford RA, Mayberry JF, Lock RJ. Prevalence of pANCA in South Asians and Europeans with ulcerative colitis. *Clin Exp Immunol* 1993; **93 Suppl 1**: Abstract 119: 47.
- Mårtensson U, Nässberger L. Circulating autoantibodies directed against beta-glucuronidase. *Autoimmunity* 1992; **11**: 213-214.
- Masi AT, Hunder GG, Lie JT *et al*. The American College of Rheumatology 1990 criteria for the classification of Churg-Strauss syndrome (allergic granulomatous and angiitis). *Arthritis Rheum* 1990; **33**: 1094-1100.
- Mathieson PW, Cobbold SP, Hale G *et al*. Monoclonal-antibody therapy in systemic vasculitis. *N Eng J Med* 1990; **323**: 250-254.
- Mathiesson PW. Overview on systemic vasculitides other than Wegener's granulomatosis. *APMIS Suppl 19* 1990; **98**: 21-23.
- Mathieson PW, Lockwood CM, Oliviera DBG. T and B cell responses to neutrophil cytoplasmic antigens in systemic vasculitis. *Clin Immunol Immunopathol* 1992; **63**: 135-141.
- Mathieson PW, Qasim FJ, Esnault VLM, Oliveira DBG. Animal models of sytemic vasculitis. *J Autoimmun* 1993; **6**: 251-264.
- Matthews JNS, Altman DG, Campbell MJ, Royston P. Analysis of serial measurements in medical research. *Br Med J* 1990; **300**: 230-235.
- Mulder AHL, Horst G, van Leeuwen MA, Limburg PC, Kallenberg CGM. Antineutrophil cytoplasmic antibodies in rheumatoid arthritis. Characterization and clinical correlations. *Arthritis Rheum* 1993; **36**: 1054-1060.
- Nässberger L Sjöholm AG, Jonsson, Sturfelt G, Åkesson A. Autoantibodies against neutrophil cytoplasm components in systemic lupus erythematosus and in hydralazine-induced lupus. *Clin Exp Immunol* 1990; **81**: 380-383.

- Nauseef WM. Myeloperoxidase deficiency. *Hematol Oncol Clin North Am* 1988; **2**: 135-158.
- Nielsen H, Wiik A, Elmgreen J. Granulocyte specific antinuclear antibodies in ulcerative colitis. Aid in differential diagnosis of inflammatory bowel disease. *APMIS* 1983; **91**: 23-26.
- Niles JL, McCluskey T, Ahmad MF, Arnaout MA. Wegener's granulomatosis auto-antigen is a novel serine proteinase. *Blood* 1989; **74**: 1888-1893.
- Nishino H, DeRemee RA, Rubino FA, Parisi JE. Wegener's granulomatosis associated with vasculitis of the temporal artery: report of five cases. *Mayo Clin Proc* 1993; **68**: 115-121.
- Nishino H, Rubino FA, DeRemee RA, Swanson JW, Parisi JE. Neurological involvement in Wegener's granulomatosis: an analysis of 324 consecutive patients at the Mayo clinic. *Ann Neurol* 1993; **33**: 4-9.
- Nölle B, Specks U, Lüdemann J, Rohrbach MS, DeRemee RA, Gross WL. Anticytoplasmic autoantibodies: their immunodiagnostic value in Wegener granulomatosis. *Ann Intern Med* 1989; **111**: 28-40.
- Ouchterlony O. Diffusion-in-gel methods for immunological analysis II. *Progress in Allergy* 1962; **6**: 30-154
- Oudkerk Pool M, Ellerbroek PM, Ridwan BU *et al.* Serum antineutrophil cytoplasmic auto-antibodies in inflammatory bowel disease are mainly associated with ulcerative colitis. A correlation study between perinuclear autoantibodies and clinical parameters, medical, and surgical treatment. *Gut* 1993; **34**: 46-50.
- Oudkerk Pool M, Remaux D, Pena AS *et al.* Differences in the prevalence of anti-neutrophil autoantibodies in European patients with inflammatory bowel disease. *Clin Exp Immunol* 1993; **93 Suppl 1**: Abstract 120: 47.

- Parlevliet KJ, Henzen-Logmans C, Oe PL, Bronsveld W, Balm AJM, Donker AJM. Antibodies to components of neutrophil cytoplasm: a new diagnostic tool in patients with Wegener's granulomatosis and systemic vasculitis. *QJMed* 1988; **66**: 55-63.
- Patel RT, Varaganam M, Youngs D, Keighley MRB. Antineutrophil cytoplasmic antibodies with specificity for lactoferrin in ulcerative colitis. *Clin Exp Immunol* 1993; **93 Suppl 1**: Abstract 59: 31.
- Pettersson E, Heigl Z. Antineutrophil cytoplasmic antibody (cANCA and pANCA) titers in relation to disease activity in patients with necrotizing vasculitis : a longitudinal study. *Clin Nephrol* 1992; **37**: 219-228.
- Pudifin DJ, Naicker S, Patton MS *et al.* Circulating auto-antibodies to neutrophil cytoplasmic antigens in vasculitis. A report of 3 cases. *SA Med J* 1989; **75**: 73-75.
- Rasmussen N, Borregaard N, Wiik A. Anti-neutrophil-cytoplasm antibodies in Wegener's granulomatosis are not directed against alkaline phosphatase. *Lancet* 1987; **1**: 1488.
- Rasmussen N, Sjölin C, Isaksson B, Bygren, Wieslander J. An ELISA for the detection of anti-neutrophil cytoplasm antibodies (ANCA). *J Immunol Methods* 1990; **127**: 139-145.
- Rasmussen N, Petersen J. (Eds) Wegener's granulomatosis and Anti neutrophil cytoplasmic antibody (ANCA). Proceedings of the clinical symposium on Wegener's granulomatosis, Zweibrücken 1990. *APMIS Suppl 19*; 1990; **98**: 68 pages.
- Rasmussen N, Petersen J, Jensen H, Andersen V. Histopathological findings in biopsies from patients with Wegener's granulomatosis. *APMIS Suppl 19* 1990; **98**: 15-16.
- Rasmussen N, Petersen J. Cellular immune responses and pathogenesis in c-ANCA positive vasculitides. *J Autoimmun* 1993; **6**: 227-236.

- Reed SL, Keene WE, McKerrow JH. Thiol proteinase expression and pathogenicity of *Entamoeba histolytica*. *J Clin Microbiol* 1989; **27**: 2772-2777.
- Roberts DE. Antineutrophil cytoplasmic autoantibodies. *Clin Lab Med* 1992; **12**: 85-98.
- Roberts JM Taylor RN, Goldfien A. Endothelial cell activation as a pathogenetic factor in preeclampsia. *Seminar Perinatol* 1991; **15**: 86-93.
- Roberts DE, Peebles C, Curd JG, Tan EM, Rubin RL. Autoantibodies to native myeloperoxidase in patients with pulmonary hemorrhage and acute renal failure. *J Clin Immunol* 1991; **11**: 389-397.
- Rollino C, Roccatello D, Coppo R *et al.* Classical and perinuclear anti-neutrophil cytoplasm antibodies and antimyeloperoxidase antibodies in rapidly progressive glomerulonephritis. *Am J Nephrol* 1991; **11**: 318-324.
- Rossi F, Jayne DRW, Lockwood CM, Kazatchkine MD. Anti-idiotypes against anti-neutrophil cytoplasmic antigen autoantibodies in normal human polyspecific IgG for therapeutic use and in the remission sera of patients with systemic vasculitis. *Clin Exp Immunol* 1991; **83**: 298-303.
- Rump JA, Schölmerich J, Gross V *et al.* A new type of perinuclear anti-neutrophil cytoplasmic antibody (p-ANCA) in active ulcerative colitis but not in Crohn's disease. *Immunobiology* 1990; **181**: 406-413.
- Rump JA, Scholmerich J, Roth M *et al.* A new type of p-ANCA in active ulcerative colitis. *Am J Kidney Dis* 1991; **18**: 214.
- Salata RA, Ravdin JL. The interaction of human neutrophils and *Entamoeba histolytica* increases cytopathogenicity for liver cell monolayers. *J Infect Dis* 1986; **154**: 19-26.
- Saulsbury FT, Kirkpatrick PR, Bolton WK. IgA antineutrophil cytoplasmic antibody in Henoch-Schönlein purpura. *Am J Nephrol* 1991; **11**: 295-300.

- Savage COS, Winearls CG, Jones S, Marshall PD, Lockwood CM. Prospective study of radioimmunoassay for antibodies against neutrophil cytoplasm in diagnosis of systemic vasculitis. *Lancet* 1987; **1**: 1389-1393.
- Savage COS, Tizard J, Jayne D, Lockwood CM, Dillon MJ. Antineutrophil cytoplasm antibodies in Kawasaki disease. *Arch Dis Child* 1989; **64**: 360-363.
- Savage COS, Lockwood CM. Autoantibodies in primary systemic vasculitis. *Adv Intern Med* 1990; **35**: 73-92.
- Savage COS, Lockwood CM. Antineutrophil antibodies in vasculitis. *Adv Nephrol* 1990; **19**: 225-236.
- Savage COS, Pottinger BE, Gaskin G, Lockwood CM, Pusey CD. Vascular damage in Wegener's granulomatosis and microscopic polyarteritis: presence of anti-endothelial cell antibodies and their relation to antineutrophil cytoplasm antibodies. *Clin Exp Immunol* 1991; **85**: 14-19.
- Savage COS, Cooke SP. The role of the endothelium in systemic vasculitis. *J Autoimmun* 1993; **6**: 237-249.
- Savage JA, Gallicchio M, Georgiou T, Davies DJ. Diverse target antigens recognized by circulating antibodies in anti-neutrophil cytoplasm antibody-associated renal vasculitides. *Clin Exp Immunol* 1990; **82**: 238-243.
- Savage JA, Gallicchio MC, Stockman A *et al.* Anti-neutrophil cytoplasm antibodies in rheumatoid arthritis. *Clin Exp Immunol* 1991; **86**: 92-98.
- Saxon A, Shanahan F, Landers C, Ganz TG, Targan S. A distinct subset of antineutrophil cytoplasmic antibodies is associated with inflammatory bowel disease. *J Allergy Clin Immunol* 1990; **86**: 202-210.
- Shaw G, Ronda N, Bevan JS, Esnault V, Griffiths DF, Rees A. Antineutrophil cytoplasmic antibodies (ANCA) of IgA class correlate with disease activity in adult Henoch-Schönlein purpura. *Nephrol Dial Transplant* 1992; **7**: 1238-1241.

- Snook JA, Chapman RW, Fleming K, Jewell DP. Anti-neutrophil nuclear antibody in ulcerative colitis, Crohn's disease and primary sclerosing cholangitis. *Clin Exp Immunol* 1989; **76**: 30-33.
- Specks U, DeRemee RA. Significance of antibodies to cytoplasmic components of neutrophils. (Editorial) *Thorax* 1989; **44**: 369-370.
- Specks U, Wheatley CL, McDonald TJ, Rohrbach MS, DeRemee RA. Anticytoplasmic autoantibodies in the diagnosis and follow-up of Wegener's granulomatosis. *Mayo Clin Proc* 1989; **64**: 28-36.
- Stegeman CA, Cohen-Tervaert, Huitema MG, Kallenberg CGM. Serum markers of T cell activation in relapses of Wegener's granulomatosis. *Clin Exp Immunol* 1993; **91**: 415-420.
- Stroncek DF, Egging MS, Eiber GA, Clay ME. Neutrophil alloantibodies react with cytoplasmic antigens: a possible cause of false-positive indirect immunofluorescence assays for autoantibodies to neutrophil cytoplasmic antigens. *Am J Kidney Dis* 1993; **21**: 368-373.
- Targan SR, Saxon A, Landers C, Ganz T, Shanahan F. Serum antineutrophil cytoplasmic autoantibodies distinguish between ulcerative colitis from Crohn's disease patients. *Gastroenterology* 1989; **Suppl 96**: A 505 (Abstract).
- Tsutsimi V, Mena-Lopez R, Anaya-Velazquez F, Martinez-Palomo A. Cellular bases of experimental liver abscess formation. *Am J Pathol* 1984; **117**: 81-91.
- Ulmer M, Rautmann A, Gross WL. Immunodiagnostic aspects of autoantibodies against myeloperoxidase. *Clin Nephrol* 1992; **37**: 161-168.
- Van der Woude FJ, Rasmussen N, Lobatto S *et al.* Autoantibodies against neutrophils and monocytes: tool for the diagnosis and marker of disease activity in Wegener's granulomatosis. *Lancet* 1985; **1**: 425-429.
- Van der Woude FJ, Daha MR, Van Es LA. The current status of neutrophil cytoplasmic antibodies. *Clin Exp Immunol* 1989; **78**: 143-148.

- Van der Woude FJ. Possible pathogenetic implications of ANCA in vasculitic syndromes. *APMIS Suppl 19* 1990; **98**: 29-30.
- Venning MC, Arfeen S, Bird AG. Antibodies to neutrophil cytoplasmic antigen in systemic vasculitis. (Letter) *Lancet* 1987; **2**: 850.
- Venning MC, Quinn A, Broomhead V, Bird AG. Antibodies directed against neutrophils (C-ANCA and P-ANCA) are of distinct diagnostic value in systemic vasculitis. *Q J Med* 1990; **77 (284)**: 1287-1296.
- Wathen CW, Harrison DJ. Circulating Anti-neutrophil antibodies in systemic vasculitis. (Letter) *Lancet* 1987; **1**: 1037.
- Weiss SJ. Tissue destruction by neutrophils. *N Eng J Med* 1989; **320**: 365-376.
- Wieslander J. How are antineutrophil cytoplasmic autoantibodies detected? *Am J Kidney Dis* 1991; **18**: 154-158.
- Wiik A. Granulocyte specific antinuclear antibodies. Possible significance for the pathogenesis, clinical features and diagnosis of rheumatoid arthritis. *Allergy* 1980; **35**: 263-289.
- Wiik A. Delineation of a standard procedure for indirect immunofluorescence detection of ANCA. *APMIS Suppl 6* 1989; **97**: 12-13.
- Wiik A. Current classification and definitions of autoantibodies to neutrophil granulocytes. *APMIS Suppl 19* 1990; **98**: 24-25. (176)