

Investigating the effects of *Cinnamomum-cassia* nanoparticle conjugate on the Histomorphology of the kidney in type 2 diabetic rats.

By

**KOFFI KOUAME
207503022**



**A Thesis submitted to
Discipline of Clinical
Anatomy
School of Laboratory Medicine and Medical
Sciences College of Health Sciences
University of
KwaZulu-Natal
Durban, South Africa**

**In fulfilment of the Requirement for the Degree
of Doctor of Philosophy in Clinical Anatomy**

**Supervisor: Prof Onyemaechi Okpara Azu
Co-Supervisors: Dr Coleridge Stephen Naidu
Dr Aniekan Imo Peter**

Investigating the effects of *Cinnamomum-cassia* nanoparticle conjugate on the Histomorphology of the kidney in type 2 diabetic rats.

By

**KOFFI KOUAME
207503022**



**A Thesis submitted to
Discipline of Clinical
Anatomy**

**School of Laboratory Medicine and Medical
Sciences College of Health Sciences
University of
KwaZulu-Natal
Durban, South Africa**

**In fulfilment of the Requirement for the Degree
of Doctor of Philosophy in Clinical Anatomy**

**Supervisor: Prof Onyemaechi Okpara Azu
Co-Supervisor: Dr Coleridge Stephen Naidu
Dr Aniekan Imo Peter
January 2019**

Preface

The study described in this thesis was carried out in the Discipline of Clinical Anatomy, School of Laboratory Medicine and Medical Sciences, College of Health Sciences, University of KwaZulu-Natal, Durban, South Africa from February 2016 to April 2019, under the supervision of Prof. O.O. Azu, Dr. E.C. S Naidu and Dr A. I. Peter for the award of Doctor of Philosophy Degree in Clinical Anatomy.

Declaration

I, Mr. KOFFI KOUAME, declare as follows:

That the work described in this thesis, to my knowledge, has not been submitted to UKZN or any other tertiary institution for the purpose of obtaining an academic qualification, whether by myself or any other party.

That my contributions to the project were as follows:

I was involved in the design and submission of the proposal for ethics approval by the University Animal Research Ethics Committee.

I was wholly responsible for carrying out the experiments and data and sample collection.

I performed all sample analyses, collate and did all the data analyses.

I was responsible for the writing of all the manuscripts and the thesis.

This thesis does not contain other person's written, data, pictures or other information unless specifically acknowledged as being sourced from other persons or researchers. Where other written sources have been quoted then:

Their words have been re-written but the general information attributed to them has been referenced

Where their exact word has been used, then it has been properly referenced in the reference section.



Signed

25-04-2019

Date

Dedication

To GOD, the owner and source of knowledge and understanding as well as to My family.

Acknowledgements

I deeply acknowledge THE LORD, my creator, my pillar and source of inspiration for His grace, wisdom, knowledge, and understanding he has bestowed upon me all through the period of this study. On your wings only have I soared, I am thankful Lord!

I would like to express my sincere gratitude to my Supervisor Prof O.O Azu, my Co-supervisors Dr E. C. S. Naidu and Dr A. I. Peter for their continuous support, patience and mentorship to pursue a Doctor of Philosophy Degree. I could not have imagined having better advisors and mentors for my Ph.D. study. I am really grateful.

I appreciate the support and contributions of all the people I worked with in the Morphology and Andrology group at various stages/time during my study. Prof. Onyemaechi Azu, DR. Edwin Naidu, DR. Aniekan Peter, DR. Edidiong Akang, DR. Ifeoluwa Okewumi, DR onanuga ismail, DR. Tosin Ogedengbe, Ugochukwu Offor, DR. Misturah Adana, Thato Mogologolo, Slindile Mdlalose, DR. Aung khaing Zaw and Tebatso manyaka.

I acknowledge the College of Health Sciences, UKZN for their financial support to my study. This work is partly supported by the National Research Foundation of South Africa to the grant awarded to Prof OO Azu (Unique Grant no: U 99053)

and Dr Roshila Moodley (Unique Grant no. 94041). We also thank the School of Chemistry and Physics, UKZN (Westville Campus) especially the support of Judie Magura and Bongisiwe Shelembe.

I also acknowledge the UKZN Nanotechnology Platform.

My thanks to the Staff of Biomedical Resource Unit, for their enormous assistance.

I also acknowledge and appreciate the support I received from Professor Moses Chimbari (Former Dean of Research, College of Health Sciences, UKZN) during my study.

I appreciate very immensely the assistance of Ms MaryAnn Marilyn Francis: Public Relations Manager- College of Health Sciences.

THANK YOU GOD THE FATHER, THANK YOU GOD THE SON, THANK YOU GOD THE HOLY SPIRIT

Table of contents	Page
Title page.....	i
Preface.....	ii
Declaration.....	iii
Dedication.....	iv
Acknowledgements.....	v
Table of contents.....	vi
List of figures.....	x
List of tables.....	xi
Abbreviations.....	xii
Abstract.....	xiv
<i>Isifingqo (Isizulu Abstract)</i>	xvi
CHAPTER ONE: INTRODUCTION AND LITERATURE REVIEW	1
1.0 Background.....	1
1.1 Prevalence of diabetes mellitus.....	3
1.2 Diabetes Mellitus in Africa.....	5
1.3 Classification of diabetes.....	8
1.3.1 Type 1 Diabetes Mellitus (T1DM).....	9
1.3.2 Type 2 Diabetes Mellitus (T2DM).....	10
1.4 Diabetes nephropathy	11
1.5 Diagnosis of diabetic nephropathy	16
1.6 Insulin.....	17
1.6.1 Insulin secretion.....	21
1.6.2 Insulin degradation.....	22
1.6.3 Insulin receptor	22
1.6.4 Effects of insulin on its targets.....	24
1.6.5 Action of insulin on glucose transporters (GLUT).....	24
1.6.6 Action of insulin on the liver.....	24
1.6.7 Effect of insulin on muscle.....	25
1.6.8 Effect of insulin on adipose tissue.....	25
1.7 Current antidiabetic drugs.....	26

1.7.1 Metformin.....	26
1.7.2 Glibenclamide.....	29
1.8 Overview of current animal models of T2D.....	30
1.8.1 Diet induced models of T2D	30
1.8.1.1 Fat fed Model.....	30
1.8.2 Chemically induced rodent models of T2D	30
1.8.2.1 Alloxan	30
1.8.2.2 Streptozotozin	31
1.9 Models of Streptozotozin-nicotinamide	33
1.10 Overview of Anatomy of kidney.....	34
1.10.1 Anatomy of the rat kidneys.....	34
1.11 Anatomy of Human kidneys.....	37
1.11.1 Nephrons as the functional unit of the kidney.....	40
1.11.2 Histology of the kidney.....	41
1.11.3 Renal Circulation.....	44
1.11.4 Urine Formation.....	46
1.11.5 Glomerular Filtration.....	46
1.11.5.1 Glomerular filtrate rate (GFR).....	47
1.11.6 Tubular Reabsorption.....	48
1.11.7 Selective Reabsorption.....	48
1.11.8 Tubular Secretion.....	48
1.12 Nanoparticles and Herbal Formulations.....	49
1.13 Diabetes and Nanotechnology.....	52
1.14 Diabetes and Silver nanoparticles	54
1.15 Diabetes and herbal remedies	56
1.16 <i>Cinnamomum cassia</i>	57
1.17 Statement of problem.....	62
1.18 Justification.....	63
1.19 Aims.....	64
1.20 Specific objectives.....	64
1.21 Research questions.....	65
1.22 Contribution to knowledge.....	65

1.23 Animal management/ Experimental design.....	65
1.24 Non diabetic group.....	67
1.25 Diabetic group.....	67
1.26 Induction of type 2 diabetes.....	69
1.27 Body and Kidney Weight	69
1.28 Urinalysis	69
1.29 Collection of Blood Samples	71
1.30 Histopathological Examination of Kidneys.....	71
1.31 Histochemical Evaluation of the Kidneys.....	73
1.32 Stereological Analyses of Kidneys.....	73
1.33 Transmission electron microscope	74
1.34 Measurement of kidney tissue Malondialdehyde (MDA) level	74
1.35 Measurement of kidney tissue Glutathione Concentration (GSH).....	76
1.36 Renal function analyses.....	76
1.37 Statistical analysis	76
References.....	78
BRIDGING text-between chapter one and two.....	93
CHAPTER two-Manuscript...one.....	94
BRIDGING between chapter two and three	102
CHAPTER three-Manuscript two	103
BRIDGING text between chapters three and four	134
BRIDGING between chapters four and five	135
BRIDGING between chapters five and Six.....	136
CHAPTER SEVEN, SYNTHESIS, CONCLUSION AND RECOMMENDATION.....	137
7.0 Synthesis	137
7.1 Conclusions	157
7.2 Recommendations.....	157
References	159
Appendix	166

List of figures

	Page
Figure 1.1: The Diabetes Epidemic: Global Projections.....	4
Figure 1.2: Pancreas.....	17
Figure 1.3: Structure of human proinsulin.....	19
Figure 1.4 Model of the control of insulin release from the pancreatic β -cells by glucose.....	20
Figure 1.5 Schematic diagram of the probable structure of the insulin receptor tetramer in the activated state.....	22
Figure 1.6: Mechanism of action metformin.....	27
Figure 1.7: Chemical Structure of Streptozotozin	30
Figure 1.8: Schematic drawing showing location of kidneys.....	35
Figure 1.9: Sagittal section of rat kidney.....	37
Figure 1.10: Schematic diagram showing sagittal section of human kidneys.....	38
Figure 1.11: Schematic diagram showing structure of the nephron.....	40
Figure 1.12: Microscopic anatomy of the kidney.....	43
Figure 1.13: Renal Circulation.....	44
Figure 1.14: Chemical struture of Cinnamomum cassia.....	60
Figure 1.15: Sprague –Dawley rats housed in the the Plastic cages.....	65
Figure 1.16: Experimental design.....	67
Figure 1.17: Sprague – Dawley rats housed in a metabolic cage.....	69
Figure 1.18 Dissected Sprague-Dawley rat on autopsy table.....	71

List of tables

	Page
Table 1.1: Classification of diabetes Mellitus.....	9
Table 1.2: Analysis of the plant Cinnamomum cassia	59
Table 1.3: List of manuscript from project.....	75

Abbreviations

ADH	Antidiuretic hormone
ADP-ribose	Adenosine diphosphate ribose
Ag ⁺	Silver ion
AgNPs	Silver nanoparticles
AgNO ₃	Silver trioxonitrate (Abou-Seif and Youssef)
ALT	Alanine aminotransferase
AMPK, kinase	Adenosine monophosphate-activated protein
ATP	Adenosine triphosphate
ARV	Antiretroviral
AST	Aspartate transaminase
AV	Absolute volume
Cc	Cinnamomum Cassia
CcAgNPs	Cinnamomum cassia silver nanoparticles
CoA	Acetyl Co-Enzyme A
CPP	Cell penetrating peptides
DCT	Distal convoluted tubules
DMLB	Distributed Multi-criteria load balancing
DM	Diabetes Mellitus
ECMs	Extracellular Matrix
ESKD	End Stage Kidney disease
FBG	Fasting blood glucose
FFA	Free fatty acids
FTIR	Fourier transform infrared spectroscopic

GBM	Glomerular basement membrane
GFAT	Glutamine fructose-6-phosphate aminotransferase
GFR	Glomerular filtration rate
GLUT-2	Glucose transporter 2
GSH	Glutathione
HAART	Highly active antiretroviral therapy
HDL	High density lipoprotein
H&E	Hematoxylin and Eosin
IgA	Immunoglobulin
IRS	Insulin-receptor substrates
KW	Kidney weight
LDL	Low density lipoproteins
MDA	Malondialdehyde
MDRD	Modification of diet in renal disease
MT	Masson's trichrome
NAD	Nicotinamide adenine dinucleotide
NDDS	Novel drug delivery system
NPs	Nanoparticles
OGT	Oral glucose tolerance
OsO ₄	Osmium tetroxide
PAS	Periodic acid Schiff
PBMC	Peripheral blood mononuclear cell
PCT	Proximal convoluted tubules
PPAR- γ	Peroxisome proliferator-activated receptor
ROS	Reactive oxidant species
SDS	Sodium dodecyl sulfate
STEM	Scanning transmission electron microscopy
STZ	Streptozotocin
T1D	Type 1 diabetes

T2D

Type 2 diabetes

TBA

Thiobarbituric acid

TB

Tuberculosis

TEM

Transmission Electron Microscopy

Abstract

Introduction

Diabetic nephropathy remains one of the biggest complications of diabetes. The incidence is increasing and more patients are experiencing progressive kidney failure due to lack of hyperefficient treatment. This study investigated the antidiabetic activity of *Cinnamomum cassia* silver nanoparticles (AgNPs) [(CcAgNPs)] and its effects on the kidneys of Sprague-Dawley rats induced with type 2 diabetes following administration of Streptozotocin.

Materials and methods

Adult healthy, pathogen-free male Sprague-Dawley rats, of a total number of 65 (N=65), weighing 250.0 ± 20 g were divided into 10 groups. Groups A-E (positive controls) consists of 30 rats, with 6 rats per group and the experimental groups F-J, consists of 35 rats, with 7 animals per group. Diabetes was induced in animals using Streptozotocin 60 mg/kg administered intraperitoneally. The animals were subjected to various treatments with Cc (100 mg/kg and 200 mg/kg) and CcAgNPs (5 mg/kg and 10 mg/kg). The treatments were administered orally using orogastric gavage and administration was carried out daily following treatment protocol for 56 days. The selected protocol for the experiment was officially approved by the Animal Ethics Committee (protocol reference number: AREC/74/016D).

Cinnamomum cassia Silver Nanoparticles (CcAgNPs) was synthesized using the green option and characterized using UV (ultraviolet)–TEM (Transmission electron microscopy)–FTIR (Fourier-transform infrared spectroscopy) –XRD (X-ray powder diffraction), prior to administration. The animals were sacrificed on day 56. Blood and urine samples were collected for biochemical analysis. The kidneys were examined for histopathological changes using Hematoxylin and Eosin (H&E),

periodic acid Schiff and Masson's trichrome staining. Transmission Electron Microscope (TEM) and Stereological studies were carried out as well.

Results

Urinalysis showed extensive protein and albumin deposits in the urine. Ketones and nitrites levels which are markers of renal function were significantly lower ($p < 0.05$) in groups treated with CcAgNPs compared to negative controls. Urea and creatinine were also significantly ($p < 0.05$) reduced in treated groups compared to negative controls. The levels of reduced glutathione (GSH) was significantly different across all groups ($p < 0.05$). Serum Malondialdehyde (MDA) concentrations were significantly ($p < 0.05$) lower in CcAgNPs compared to controls.

Liver enzymes (alanine aminotransferase) ALT was reduced significantly in groups treated with a low dose of CcAgNPs compared to negative controls. In the group treated with high dose (10 mg/kg) of CcAgNPs, (Aspartate transaminase) AST levels were significantly lower ($p < 0.05$), compared to the group treated with Cc (*Cinnamomum cassia*) and to the negative control.

Stereological studies showed significantly decreased ($p < 0.05$) number of glomeruli and tubules in groups treated with Cc and CcAgNPs, compared to the negative control.

Transmission Electron Microscope (TEM) revealed the thickness of glomerular basement membrane, in experimental groups, compared to positive controls.

Histopathology of renal tissue showed severe glomerular distortion, tubular lesions with H & E and thickening of the basement membrane; pyknotic nuclei and vacuolization with PAS and MT, in the untreated negative control group. Positive controls showed regular glomeruli with normal Bowman's capsular space, normal basement membrane and regular capillary network compared to negative controls. The degree of histopathological changes in the glomeruli and tubules appear to be dose-dependent.

Conclusion

Diabetes negatively alters the cytoarchitecture and biochemistry of the kidneys of Sprague-Dawley rats while *Cinnamomum cassia* Silver Nanoparticles have the potential to ameliorate these changes. The possible pathway involved CcAgNPs may provoke the release of insulin-like, as well as the thioredoxin (Trx), which is one of the central antioxidants that can alleviate renal injuries in diabetic nephropathy.

Keywords: *Cinnamomum cassia*; silver nanoparticles; diabetes; histomorphology

Isifingqo (Isizulu Abstract)

Singeniso

Enye yezinkinga ezinkulu zesifo sikashukela i-nephropathy yesifo sikashukela. Lesi sigameko sanda futhi iziguli eziningi zibhekene nokuhluleka kokuqeda izinso ngenxa yokuntula ukwelashwa okuphumelelayo. Lolu cwaningo luphenye umsebenzi we-antidiabetic we-Cinnamomum cassia- we-nanoparticles wesiliva (i-AgNPs) [(CcAgNPs)] kanye nemiphumela yayo ezinsweni zama-Sprague-Dawley amagundane abanjwe ngohlobo lwesifo sikashukela ngemuva kokuphathwa kwe-Streptozotzin.

Izimpahla nezindlela

Amantombazane angamahhala, ama-pathogen angamahhala ama-sprague-Dawley amagundane, angama-65 (N = 65), anesisindo esingama- 250.0 ± 20 g ahlukane ngamaqembu angu-10. Amaqembu A-E (ukulawula okuhle) aqukethe amagundane angu-30, namaqembu angu-6 ngeqembu kanye namaqembu okuhlola (isifo sikashukela) F-J, aqukethe amagundane angu-35, anezilwane ezingu-7 ngeqembu ngalinye. Isifo sikashukela sathinteka ezilwaneni ezisetshenziswa nge-intraperitoneally Streptozotzin 60 mg / kg. Izilwane zazitholwa ngezindlela ezihlukahlukene zokwelashwa nge-Cc (100 mg / kg no 200 mg / kg) kanye ne-CcAgNPs (5 mg / kg no-10 mg / kg). Lezo zelashwa zenziwa ngomlomo ngokusebenzisa i-oro-gastric gavage kanye nokuphathwa okwenziwa nsuku zonke emva kokulandela ukwelashwa kwezinsuku ezingu-56. Ikomidi leNyuvesi yaseKwaZulu-Natali yokuziphatha kwezilwane (AREC), lavuma ukucwaninga ngenombolo yereferensi yokuziphatha: AREC / 074/016 D.

I-Cinnamomum cassia yesiliva i-nanoparticles (CcAgNPs) yenziwe ngokwenziwa kohlobo oluhlaza futhi luchazwe nge-UV (ultraviolet) - I-TEM (i-Transmission electron microscopy) -FTIR (i-Fourier-transform spectroscopy infrared) -XRD (i-X ray diffraction), ngaphambi kokuphatha. Izilwane

zahlathwa ngosuku lwama-56. Amasampuli egazi ne-urine aqoqwe ukuhlaziywa kwezinto eziphilayo. Izinso zahlolwa ngezinguquko zakhe ezingasetshenziswa kusetshenziswa i-Hematoxylin ne-eosin (i-H & E), i-periodic acid Schiff ne-Masson's trichrome . I-Transmission Electron Microscope (TEM) kanye nezifundo zesayensi zenziwa ukugcina nokukala izici ze-ultrastructural izinso.

Imiphumela

Ukuhlolwa kwe-urinalysis kubonise amaprotheni amaningi futhi i-albin ibeka imali emcinini. Amazinga kaKetoni nama-nitrites ayimisebenzi yokweqa ($p < 0.05$) ngamaqembu aphathwa nge-CcAgNPs uma kuqhathaniswa nokulawulwa okungalungile. I-Urea ne-creatinine nayo yaba kakhulu ($p < 0.05$) inciphise ekuphatheni uma kuqhathaniswa nokulawulwa okungalungile. Amazinga we-glutathione encishisiwe (i-GSH) awafani neze kakhulu kuwo wonke amaqembu ($p < 0.05$). I-Serum Malondialdehyde (MDA) yayigxile kakhulu ($p < 0.05$) ephansi ku-CcAgNPs uma kuqhathaniswa nezilawuli.

Ama-enzyme enesibindi (i-alanine aminotransferase) i-ALT yancishiswa ngamaqembu aphathwa nge-dose ephansi ye-CcAgNP uma kuqhathaniswa nokulawulwa okungalungile. Eqembu lalashwa ngezinga eliphezulu (10 mg / kg) lama-CcAgNPs, ama-AST ama-AST amazinga ayephansi kakhulu ($p < 0.05$), uma kuqhathaniswa neqembu eliphathwa ngeCc (Cinnamomum cassia) nokulawulwa okubi.

Ucwaningo lwezinkanyezi lubonakele kakhulu ($p < 0.05$) inombolo ye-glomeruli nama-tubules ngamaqembu aphathwe nge-Cc ne-CcAgNPs, uma kuqhathaniswa nokulawulwa okungalungile. - I-Transmission Electron Microscope (TEM) yembula ukuqina kwekhanda eliphansi le-glomerular, emaqenjini okuhlola, uma kuqhathaniswa nokulawula okuhle.

Ukuphefumula kwakhe kwamathambo e-renal kubonakele ukuphazamiseka okukhulu kwe-glomerular, izilonda ze-tubular nge-H & E kanye nokuqina kwesimbatho esincane, i-pyknotic nuclei kanye nokuphumula ngaphandle kwe-PAS no-MT, eqenjini lokulawula elingalungile. Izilawuli

ezinengqondo zibonisa i-glomeruli evamile nekhala elijwayelekile le-Bowman's capsular, insimu evamile yesigqebhezana nesisetshenziswa senethiwekhi ejwayelekile ngokuqhathaniswa nokulawulwa okungalungile. Izinga lokuguquka kwezinto ezithinta izinto ezinhlobonhlobo ku-glomeruli kanye namashubhu kubonakala sengathi kuncike ekutheni.

Isiphetho

Isifo sikashukela sishintsha kabi i-cyto-architecture kanye ne-biochemistry yezinso zama-sprague-Dawley amagundane ngenkathi i-Cinnamomum cassia yesiliva ye-nanoparticles ingakwazi ukuthuthukisa lezi zinguquko. Indlela engabandakanyeka, i-CcAgNPs ingabangela ukukhululwa kwe-insulini efana, kanye ne-thioredoxin (i-Trx), engenye ye-antioxidant ephakathi, ukunciphisa ukulimala kwe-renal ku-nephropathy yesifo sikashukela. Amagama angukhiye: Cinnamomum cassia; nanoparticles zesiliva; isifo sikashukela; i-histomorphology

CHAPTER ONE

INTRODUCTION AND LITERATURE REVIEW

1.0 Background

Diabetes is a group of common serious metabolic disarrangement featured by hyperglycemia, resulting mainly from a deficiency in insulin production in the body. Diabetes is known as a complex, heterogeneous metabolic disorder, caused as a result of the redundant environment as well as genetic factors (Cnop et al., 2005). Type 2 diabetes (originally named non-insulin-dependent or adult onset diabetes) results from the body's inefficient use of insulin (WHO, 2016). Diabetes is on the rise and is no longer a disease of mostly rich nations. The frequency of diabetes is steadily increasing everywhere, most markedly in the world's middle-income countries (WHO, 2016). Diabetes is categorized as one of the most challenging diseases confronting society and health care professionals today (Subramoniam, 2016). Diabetes and its complications are known to be one of the leading causes of high mortality and morbidity rate and a universal problem (WHO, 2016). The prevention of diabetes and its complications is not only a major issue for the future but essential if health for all is to be achieved (WHO, 1999).

Diabetes is a chronic disease that happens when the insulin secreted by the pancreas is not enough or when the body cannot efficiently use the insulin it produces. Blood sugar is controlled by Insulin. The common side effect of unregulated diabetes is hyperglycemia or raised blood sugar which over time leads to severe damage to many of the body's systems, especially the nerves and blood vessels (Roessner et al., 2012). Diabetes and its complications are the foremost cause of mortality and morbidity (Inzucchi et al., 2012). Some genetic factors are also causing diabetes, using the oxidative stress pathways; this is common to type 1 and type 2 diabetes mellitus.

Type 1 diabetes mellitus (T1DM) is an autoimmune disease that leads to the destruction of the pancreatic beta cells, which produces the insulin within the islets of Langerhans. T1DM is most commonly diagnosed in children and young adults, and by the time of diagnosis, patients have very little endogenous insulin secretion. Daily subcutaneous injections replace the Insulin. Unfortunately, in many settings, the absence of efficient policies to create a supportive environment for healthy lifestyles are not being encouraged (WHO, 2016). When diabetes is not regulated, it generates negative consequences for health and well-being. In addition, diabetes and its associated complications (nephropathy, neuropathy, skin conditions, and retinopathy) generate a heavy financial burden on individuals and their families and the economy of nations. People suffering with diabetes are financially harmed by high list prices of insulin as well as high out-of-pocket costs (WHO, 2016).

The serious long-term microvascular complications of diabetes occur in nearly 40% of diabetic patients, diabetic nephropathy is one of the main causes of end-stage kidney disease (ESKD) throughout the world. Diabetic nephropathy has got a risk factor as microalbuminuria (Tuttle et al., 2014). Progressively increasing albumin in the urine is a sign of early diabetic nephropathy (Perkins et al., 2003). The medicines that lower blood pressure is mainly used to treat diabetic nephropathy as they protect the kidneys. These medicines possess the property to reverse kidney damage and are started as soon as any amount of protein is detected in the urine. Generally, two or more medicines may be needed to lower blood pressure, in order to protect the kidneys, when patients experience high blood pressure (Beck et al., 2018).

The International Obesity personnel estimated that there are approximately 300 million individuals suffering from obesity and out of this number, 150 million persons suffer from type 2 diabetes (Reuter, 2007; Shirwaikar et al., 2006) (figure 1.1). In South Africa, 80,000 persons were reported to have diabetes and the international community expected this statistical result to climb to over 1.2 million in 2030. (WHO, 2016) (figure 1.1).

Because the symptoms Type 2 diabetes can be mild and may develop gradually, it takes about seven years for a person to be diagnosed with the disease. As a result, about 30% of people with Type 2 diabetes will be experiencing serious complications by the time they are diagnosed (Chen et al., 2012). Heart disease, stroke, blindness, amputations, and kidney failure are listed among the complications of diabetes. Early diagnosis and proper treatment may avoid these complications. Type 2 diabetes is brought a heavy burden on the South African healthcare system. Effective management of diabetes requires efficient daily treatment, regular monitoring, a healthy diet associated with lifestyle and ongoing education. The costs associated with diabetes are alarming. The hospital and medication costs constitute the direct cost of diabetes and disability grants as well as indirect costs, such as work absenteeism, time spent caring for sick relatives and less productivity (Seuring et al., 2015).

The percentage of diabetes-related deaths in South Africa in people younger than 60 years is about 76% and this represent the most economically active age group of the population. Health expenditure for adults diabetics in South Africa is projected to increase by 50% between 2010 and 2030 (Peer et al., 2014).

1.1 Prevalence of diabetes mellitus

Diabetes mellitus is a heterogeneous disorder with varying prevalence among different ethnic groups. It affects a large number of people around the world. In 2011, it was estimated that 366 million people had DM and this number is expected to reach 552 million by 2030 as shown below in figure 1.1 (Whiting et al., 2011). In the same year (2011), IDF reported that China, India, and the USA had 90.0, 61.3 and 23.7 million peoples living with diabetes may be increased up to 129.7, 101.2, and 29.3 million people respectively, by 2030 (Hu et al., 2013). Further, IDF reported that in 2010, the number of people with T2DM will be increasing from 285 million to 438 million by 2030, with more than 70% of cases from developing countries (Shaw et al., 2010) (figure 1.1).

Home et al. (2013) reported that WHO revealed that the highest increases in diabetes prevalence

have occurred in low- and middle-income countries of Africa, Asia, and South America. It was once believed that DM is unusual in the developing world but has now arisen as a major public health issue in Africa. In Sub-Saharan Africa, about 90% of type 2 Diabetes Mellitus cases were recorded (Levitt et al., 2011). The expected increase for sub-Saharan Africa is 98%, from 12.1 million in 2010 to 23.9 million in 2030 (Sicree et al., 2010) (figure 1.1). Similarly, the frequency of DM in Ethiopia was 2.5 % in the year 2000 and it is estimated to rise to 3.5 % by 2030 (Atlas, 2006). According to Atlas (2006), 4.6 million deaths were directly linked to diabetes, constituting 6.8% of the total global mortality in each year (Home et al., 2013). It was projected that diabetes-related deaths will be increasing by 50% in the next 10 years if no urgent action is taken (WHO, 2016) (figure 1.1). The number of deaths in Ethiopia attributed to diabetes reached over 21,000 in 2007. Nigatu et al. (2013) also reported that this estimation was increased to about 25,000 in 2011.

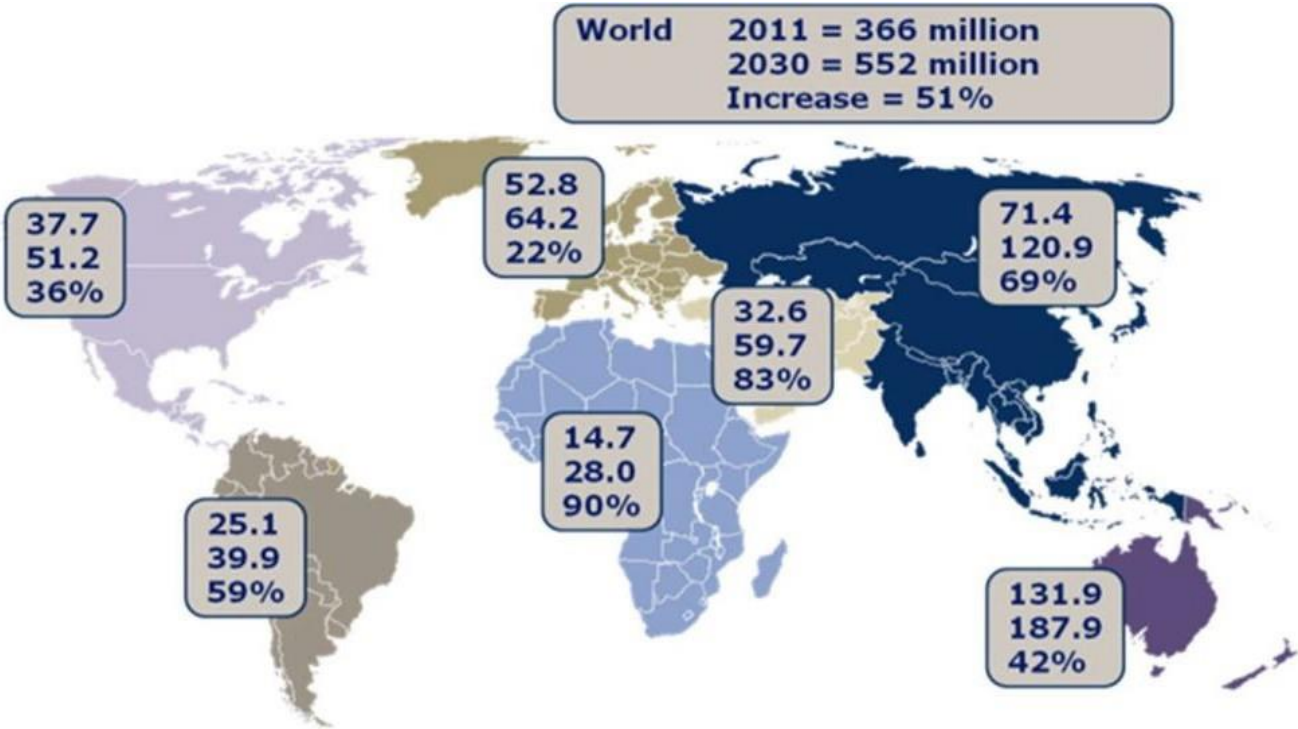


Figure 1.1: The Diabetes Epidemic: Global Projections, 2010-2030 (Kumar et al., 2018).

1.2 Diabetes Mellitus in Africa

Most countries are facing demographic transition in Africa and African societies from the urban area are increasingly rising within the sphere of the influence of Western market economies. The lifestyle of city dwellers tends to be linked to material, with the adoption of cosmopolitan behavior and consumption of resources. These changes in lifestyle have evolved against a background of increasing diabetes mellitus prevalence as well as diabetic complications in Africa (Zimmet, 1999). However, the African societies in rural zone, have seen an increase in DM due to environmental factors, which appear to be associated with drought, poverty, war, and socio-economic deprivation.

In South Africa, a number of studies were conducted, and it was revealed that there were at least 6.5 million diagnosed diabetics cases and possibly up to an equal number who are currently undiagnosed (Guariguata et al., 2014). In South Africa, the incidence of diabetes was high and was estimated to be 14% in the Colored community, 13% in the Indian community, 6% in the African community and 6% in the European community (Puoane et al., 2002).

Epidemiological data had boosted the current knowledge of diabetes in sub-Saharan Africa, taken during sporadic, predominantly convenience-based community testing initiatives and hospital data from patients who experienced diabetes complications (Pastakia et al., 2017). There were few comprehensive surveys which showed huge variations in prevalence that makes it difficult to have an accurate estimate of the impact of diabetes in the region (Hall et al., 2011). Type 2 diabetes is revealed to be the predominant form of diabetes in sub-Saharan Africa with estimated 85%–95% cases (Sobngwi et al., 2001). It is common knowledge that 62.5% of diabetics cases are undiagnosed in the World and the majority of those patients are in the sub-Saharan Africa region (Guariguata et al., 2014). Lack of access to health care facilities, poorly trained health care providers, ignorance and lack of screening is contributing to the increasing percentage of under-diagnosed cases.

The rapid urbanization of sub-Saharan African populations has further anticipated to increase the number of cases and subsequently the incidence of diabetes (Pastakia et al., 2017). This had increased the number of population who are exposed to the more diabetogenic sedentary lifestyle with a diet rich in calorie, living in urban area (Mbanya et al., 2010). The cultural attitude of some population among Sub-Saharan African cultures that perceive being overweight or obese as a symbol of wealth and prosperity, has also increased the incidence of diabetes. Type 2 diabetes prevalence was 1.5 – 4 times higher in urban settings compared with rural settings, because of the shift of lifestyle in urban zone (Jamison, 2006). The rapid urbanization taking place in sub-Saharan African populations has further complicated the situation. In 2013, the study revealed that about 37% of the population lived in urban areas compared with only 10%–15% in 1950 (Muthuri et al., 2016). Sub-Saharan Africa will be the fastest growing diabetic population living in urban area in the world in 2030, with an increase of 50% of the number of cases (Muthuri et al., 2016).

Moreover, increase in diabetes prevalence depends on changes in lifestyle adding to nutrition, being common in sub-Saharan African populations. Life expectancy in sub-Saharan Africa increasing along with the probability of developing diabetes. Additional gains in life expectancy in Africa, associated to improvement of health care infrastructures and living conditions, will continue to increase the prevalence of diabetes as the population ages (Mbanya et al., 2010).

The vantage point from both economic and health care is that diabetes is particularly devastating in sub-Saharan Africa. The highest rate of morbidity and mortality in the world is unfortunately linked to diabetes in sub-Saharan Africa, particularly in the population who are able to work (Guariguata et al., 2014). 76.4% of deaths recorded were basically caused by diabetes among people aged <60 years in sub-Saharan Africa in 2014, (Guariguata et al., 2014). The late diagnosis and poor care that patients receive throughout the course of the disease are the sources of the primary reasons for these high rates of morbidity and mortality.

In sub-Saharan Africa, associated infections (HIV, TB, and Pneumonia) to diabetes generates a twofold burden. There are needs to have greater focus on addressing mental health conditions, like depression in order to manage these more commonly diabetes-related complications, that often aggravate care for patients with diabetes. Diabetes specialist clinic in Kenya revealed that 21% of its patients from a rural zone were experiencing depressive symptoms, that were associated with worsened glycaemic control compared with screen negative patients (Shirey et al., 2015).

Cost is a major barrier to access medicines for patients with diabetes. Medicines consume large portions of household incomes in diabetes populations. Health care expenditure is mostly out-of-pocket, further promoting the vicious cycle of poverty. The care for a person suffering from diabetes in Mali necessitated nearly 70% of a family's income (Azevedo and Alla, 2008). While in Nigeria it was recorded that a monthly mean cost of 1 NGN for a diabetic person equaled 29% of the total monthly income of an individual on minimum wage (Ogbera and Kuku, 2012).

Sub-Saharan African Populations of origin are mostly considered at high risk of developing diabetes (Choukem et al., 2014). In Africa, it has been reported that the degree of urbanization of the geographical location and time spent in that particular environment has got an impact on the incidence of T2D (Choukem et al., 2014). Africans living in Africa to Afro-Caribbean, African Americans and African immigrants living in other developed countries showed an increase of prevalence of T2D, compared to other population. Mbanya et al. (2010) reported T2D incidence of 0.8% and 2% among Cameroon population living in rural and urban area respectively as well as of 8.5% in Jamaica and 14.6% among blacks living in Manchester, UK. It was reported that Black South African patients showed rapid progression to type 2 diabetes, compared to white South African patients with impaired glucose tolerance (Mbanya et al., 2010). In sub-Saharan African, the causes for the rapid deterioration of beta-cell function and most importantly the rapid progression of diabetes patients are not conclusive. With regards to the cosmopolitan diabetic population, there is need to formulate new approaches for the management of diabetes mellitus (Cubero and Rojas, 2017).

1.3 Classification of Diabetes Mellitus

A suitable classification is needed for the management of diabetes mellitus using orderly epidemiologic and clinical research. Furthermore, the process to comprehend the etiology of disease and studying its natural history engages the potential to identify and differentiate between its various forms and placing them into a rational etiopathologic framework (Alberti et al., 2004). In 1979, the National Diabetes Data Group elaborated the current classification of diabetes and other categories of glucose intolerance, based on research on this heterogeneous syndrome. Two important forms of diabetes are recognized in the countries located in the Western zone; insulin dependent diabetes mellitus (IDDM, type I diabetes) and non-insulin dependent diabetes (NIDDM, type II diabetes) (Table 1.1).

Apart from these important types of diabetes mellitus, other recognized types of diabetes comprises Maturity Onset Diabetes of the Young (MODY), an autosomal dominant genetic defect of β -cell function, whereby patient developed hyperglycemia at early onset by the age of 25 years due to an impairment of insulin production with minimal or no loss of insulin action (Asmat et al., 2016; Bissinger et al., 2018). Others include gestational diabetes mellitus; a condition defined by the presence of impaired glucose tolerance in pregnancy and has been linked to increased prevalence of complications in pregnancy including intra-uterine fetal death (IUFD), stillbirths and macrosomic babies (Bissinger et al., 2018). Recently, type 3 diabetes mellitus (T3DM) was described, and can be characterized by brain tissue resistance to insulin action. The features are similar to those of Alzheimer's disease which shows positive responses to insulin sensitizers (Suzanne, 2012). Table 1.1 shows the classification of diabetes mellitus.

Table 1.1: Classification of Diabetes Mellitus

Class of Diabetes Mellitus	Mechanism of Diabetes Development
Type 1 Diabetes Mellitus	Pancreatic beta-islet cell destruction; Absolute insulin deficiency
Type 2 Diabetes Mellitus	Insulin resistance, relative insulin deficiency
Gestational Diabetes	Insulin resistance
Others	Genetic defects in B-cell dysfunction Genetic defects in Insulin action Disease of exocrine pancreas Endocrinopathies Drugs or chemical Induced Infection Immune mediated defects Genetic syndromes associated with DM

Source: Adapted from www.care.diabetesjournals.org.

1.3.1 Type 1 Diabetes Mellitus (T1DM)

Type I diabetes is generally characterized by the sudden onset of severe symptoms, dependence on exogenous insulin to assist life and disposition to ketosis even in the basal state, all of which is caused by absolute insulin deficiency. In developing countries, among children and young adults, T1DM formally termed juvenile diabetes is the most prevalent type of diabetes (Alberti et al., 2004). It is a catabolic disorder characterized by an increase of glucagon within the plasma, in which circulating insulin is virtually lacking and the pancreatic B cells fail to respond to all insulinogenic stimuli (Olubomehin, 2014).

People whose immune systems are genetically predisposed to develop a vigorous autoimmune response against pancreatic B cell antigens will be developing T1DM subsequent to an infectious or toxic environmental contingency. Sensitized immunocytes extrinsic factors viruses such as the mumps virus and coxsackievirus B4, chemical agents or destructive cytotoxins and antibodies released from that might affect B cell functioning including damage.

Development of B cell failure after viral infections may be linked to an underlying genetic defect relating to pancreatic B cell replication of the patient or function. In addition, exact HLA genes may increase sensitivity to a diabetogenic virus or may be associated with certain immune response genes that prompt patients to a destructive autoimmune response against their own islet cells (auto-aggression). When immunosuppressive drugs such as cyclosporine or azathioprine are given at the initial manifestation of T1DM, pancreatic B cell damage appears to be lessened, supports the importance of auto-aggression by the immune system as a serious factor in the pathogenesis of this type of diabetes (Olubomehin, 2014).

1.3.2 Type 2 Diabetes Mellitus (T2DM)

Type 2 diabetes mellitus greatly outnumbered all other forms of diabetes. Exogenous insulin for prevention of ketonuria is not needed for patients with T2DM and those patients are not prone to ketosis. However, they may require insulin for the correction of fasting hyperglycemia if this cannot be achieved with the use of diet or oral agents, severe stress precipitated by infections or trauma may lead to ketosis (Alberti et al., 2004).

Because the body does not utilize insulin efficiently, it causes T2DM, although the pancreas produces insulin. Insulin-receptors or other intermediates in the insulin signaling pathways within body cells are insensitive to insulin due to peripheral tissue insulin resistance and consequently, glucose does not readily enter the tissue leading to hyperglycemia or elevated blood glucose concentrations (Porte

et al., 2005). There are many evidences that demonstrate that diabetic complications are mainly associated with oxidative stress caused by generation of free radicals (Pitkänen et al., 1992). Type-2 diabetes mellitus (T2DM) constitutes a multifunctional disease which is associated with hyperglycaemia and lipoprotein disorders (Ugochukwu and Babady, 2002). Damage to the cell, in turn results in the increase of reactive oxygen species (ROS) production. Abnormally high level of ROS are thought to play an important role in promoting the development and pathogenesis of T2DM. Free radicals are readily formed during the diabetic state and these play an important role in the genesis of diabetic complications (Ahmed et al. 2014a). Antioxidant enzymes such as superoxide dismutase (SOD), catalase (CAT), glutathione peroxidase (GPx) and reduced glutathione (GSH) play an important role in scavenging these free radicals by breaking them down. Researchers have pointed out a defect in the normal ROS scavenging machinery in T2DM patients when compared to normal controls (Ahmed et al. 2013). Disorders in the lipid profile are so profound that diabetes has been called more “a disease of lipid than carbohydrate metabolism” (Rawi et al., 1998).

Obesity, which generally results in impaired insulin action, is a common risk factor for this type of diabetes, and most patients with T2DM are obese (Olubomehin, 2014) and multiple anti- diabetic agents are required to keep adequate glycaemic control (Kendall et al., 2009).

1.4 Diabetic Nephropathy

Diseases of the kidney are a common finding in people with diabetes, with up to half demonstrating signs of kidney damage in their lifetime (Weir et al., 2004). The common cause of end-stage renal failure is diabetic nephropathy which is a significant complication of DM. The pathogenesis of DN involves mainly oxidative stress as common events and antioxidants may play a beneficial role in its prevention. Oxidative stress persuaded by generation of free radicals is linked to diabetic complications (Ahmed et al., 2015). Hyperglycaemia and lipoprotein abnormalities are mainly associated with Type-2 diabetes mellitus (T2DM), which is a multifunctional disease (Ahmed et al., 2015). Enhancement of reactive oxygen species (ROS) production is caused by damage to the cell. The development and pathogenesis of T2DM are generated from an abnormally high level of ROS. The genesis of diabetic complications is

associated with the formation of free radicals during the diabetic state (Matough et al., 2012). Diabetes has been also named “more a disease of lipid than carbohydrate metabolism because of the high disturbances in the lipid profile.

Major complications of diabetes are coronary artery disease, nephropathy, retinopathy, and neuropathy. The development of most of these complications is mainly provoked by oxidative stress (Giacco and Brownlee, 2010). When antioxidant mechanisms are not working efficiently, oxidative stress may happen, especially in dietary deficiencies of vitamin E, vitamin C or the essential elements like selenium, zinc, and manganese among others. The antioxidant enzymes glutathione peroxidase, superoxide dismutase, and catalase are formed by the later elements. Excessive endogenous production of free radicals by diseases progression as in diabetes mellitus and cancer constitutes one of the causes of oxidative stress (Irshad and Chaudhuri, 2002).

The major ROS sources in the diabetic nephropathy were: autoxidation of glucose, the activation of polyol pathways, mitochondrial respiratory chain deficiencies, xanthine oxidase activity, NAD(P)H oxidase, advanced glycation end products (AGEs) and nitric oxide synthase (Adiga et al., 2016). Injuries of the glomeruli, tubular interstitial tissue and vasculature are caused by the increased oxidative stress levels. It will result in the mesangial expansion of extracellular matrix and caused an increased glomerular filtration rate, urine protein excretion, the progression of glomerular sclerosis and tubular interstitial fibrosis (Nath, 1992).

Chronic hyperglycaemia causes increased insulin secretion in an attempt to lower blood glucose levels, causing hyperinsulinemia. Another interesting feature of diabetes type 2, the hyperglycaemia, resulting from three main effects, namely: increased generation of hepatic glucose, decrease of insulin secretion and finally reduction in glucose intake (insulin resistance) (Stumvoll et al., 2005). As insulin resistance arises from dysfunction of the main event in insulin functioning in the liver, liver-related biochemical mechanisms including gluconeogenesis, glycogenolysis, glycogen synthesis, and glycolysis become dysfunctional. Insulin hepatic resistance in the liver leads to an inability to suppress the hepatic generation of glucose. Fasting hyperglycaemia (described earlier as blood glucose levels exceeding 140 mg/dl) in type 2 diabetes patients has been attributed mainly to increased hepatic glucose production (Day, 2005).

Moreover, insulin considered against diabetic medication has demonstrated a few symptoms, for example; hypoglycaemia and weight variations from the norm, and deficient to control related complexities. (Antopolsky et al., 2012) along these lines revealed that the infection may provoke certain difficulties, for example; renal parenchymal illness or renal dead tissue, and additionally renal sore in which there is extension of the renal case from oedema or hematoma provoked, following flank pain. That ceaseless ailment will additionally cause an increment in the connective tissue of kidneys and accordingly cause tubular cell devastation, corruption and in addition renal abscess. Furthermore, the internal structure, for example, glomerular filtration rate will relentlessly decrease because of the effect of diabetes on the kidneys and fundamental circulatory strain will be expanded too (Ahmad, 2015). Glomerular basement membrane (GBMs) will be thickened, which, alongside mesangial extension, will prompt diminished patency of hair like lumens and

diminished ultrafiltration surface territory which SAKAI and Kriz (1987); called membranous proliferative glomerulonephritis.

Although, in the case of type II diabetes mellitus, there is elevated GFR during their early manifestation. The increased GFR is usually not as pronounced as are observed with insulin-dependent diabetes mellitus. In addition, at the time of detection of diabetes, there is a greater incidence of hypertension and microalbuminuria present, with as many as 10% to 25% of patients presenting with these abnormalities. Type II cases may have unrecognized diabetes, living with the disease for many years because they are not ketosis-prone and may live with other associated conditions predisposing to renal abnormalities (Skorecki et al., 2015).

Currently the disease is treated and managed by nine (9) major types of drugs of diabetes namely insulin, sulfonylureas such as glibenclamide (commonly called glyburide), biguanides such as metformin (also known as Glucophage), the dipeptidyl peptidase iv inhibitors eg sitagliptin, the Glucagon-like peptide 1 agonists, alpha-glucosidase inhibitors such as acarbose, thiazolidinediones such as pioglitazone and less commonly phenylalanine derivatives and meglitinides.

The severe, chronic complication of diabetes mellitus is diabetic nephropathy, which is the leading cause of end-stage renal failure in diabetic patients. The disease results from the combined effects of various genetic and environmental factors. Elevated glucose and cholesterol levels, increased production of inflammatory cytokines are the predisposing factors which lead to the progression of renal damage in diabetic nephropathy. Generating reactive oxygen species (ROS) and attenuating antioxidative machinery via glycation of the antioxidant enzymes are caused by elevated glucose levels, recognized as a pathogenic factor of chronic diabetic complications by (Goodwill and Frisbee, 2012).

The major cause of end-stage kidney disease (ESKD) throughout the world, occurring in nearly 40% of diabetic patients is basically, a devastating complication of diabetes, and its prevalence has more than doubled in the past decade, largely due to the increasing proportion of obesity as well as type II diabetes mellitus (Himmelfarb and Sayegh, 2010).

Clinically, the sequence of stages starting with initial glomerular hyperfiltration, glomerular hypertrophy, and microalbuminuria are the features of diabetic nephropathy. Elevated mean arterial pressure (MAP), is usually seen in patients with diabetic nephropathy (Manigrasso and Maric-Bilkan, 2013). It is further characterized by progressive glomerular basement membrane thickening, and mesangial matrix expansion, which lead to the development of glomerular sclerosis. The subsequent renal biopsy shows diffuse or nodular (Kimmelsteil-Wilson) glomerulosclerosis (Skorecki et al., 2015). Although the Kimmelsteil-Wilson lesion is a classified pathognomonic for advanced diabetic nephropathy. Only approximately 25% of patients manifest this lesion. In light-chain nephropathy, a nodular pattern of glomerulopathy imitating Kimmelsteil-Wilson lesions may also be seen. Nodular glomerular lesions may be observed as cases showing amyloidosis and membranoproliferative glomerulonephritis type II (Skorecki et al., 2015).

An additional pathognomonic finding revealed that both afferent and efferent arteriolar hyalinosis, characterized diabetic nephropathy unlike the arteriolar lesion of essential hypertension, which is restricted to the afferent arteriole (Skorecki et al., 2015). In overt diabetic nephropathy, the decline in renal function in a number of progressive renal diseases causes also progressive tubulointerstitial fibrosis, including diabetic nephropathy. GFR will subsequently commence declining from the normal range, although, serum creatinine may remain in the normal range (Skorecki et al., 2015).

Hyperfiltration is the earliest stage of diabetic nephropathy, where the glomerular filtration rate (GFR) is significantly increased than normal. Identification of hyperfiltration is not clinically useful, as it appears difficult to determine using the regular testing technique (Lemley et al., 2000).

The earliest clinical sign of diabetic nephropathy is chronic albuminuria. Initially, a small amount of albumin is leaked, below the detection via urine dipstick. This stage is qualified as “microalbuminuria” (McFarlane et al., 2013). This can progress negatively so that the urinary albumin excretion is sufficiently increased to be detectable by a urine dipstick, a stage known as “overt nephropathy.” The normal rate of progression from normoalbuminuria to microalbuminuria then to overt nephropathy is basically slow, typically for a period of 5 years or longer to progress through each stage (Jacobsen et al., 1999).

There is a persistent decline in renal function to end-stage disease where a nephrotic range of proteinuria is at a value of >3.5 g/24 hours, seen in advanced diabetic nephropathy and also associated with systemic hypertension, without manifestation of inflammatory glomerular (red blood cell casts) or tubulointerstitial white blood cells casts lesions. The kidneys may be therefore inappropriately oversized for the observed degree of renal insufficiency (Skorecki et al., 2015).

The socio-economic consequences of diabetes are highly significant and a major world power such as China lost over USD 558 billion from national income, due to diabetes and its complications (Tomino et al., 2012).

1.5 Diagnosis of Diabetic Nephropathy

Monitoring renal function parameters appear to be a good indicator for early diagnosis of diabetic nephropathy. Testing regularly all diabetic patients by means of a dipstick test (a diagnostic tool used to determine pathological changes in urine) to detect the onset of microalbuminuria, every year for type 1 diabetes mellitus, from the 5th year of diabetes, and every year since its discovery in type 2 diabetes mellitus (Gross et al., 2005). Two positive tests performed over a period of 3 to 6 months, may easily confirm the diagnosis. It must also have eliminated some other causes, especially urinary tract infection or another renal disease. Below 20 mg/d of albumin in the urine, indicates that excretion is normal. It is usually not detected by dipstick testing. Just as a debutante urine dipsticks is reactive, it does not yet detect microalbuminuria, between 30 and 200 mg/day (Gross et al., 2005).

Proteinuria may be confirmed by an assay of a sample of urine or urine collection issued for 24 hours. In 10% of the cases, renal biopsy is performed for rapid progression of nephropathy and for suspicion of another kidney disease. However, in most cases, these conditions are diagnosed without biopsy, especially in type 1 diabetes mellitus and association of microalbuminuria in the urine which is a major indication of diabetic nephropathy.

1.6 Insulin

The pancreas is a long, slender organ, most of its structure is located posterior to the bottom half of the body of the stomach (Figure 1.2). Although the pancreas is primarily an exocrine gland, which is secreting a variety of digestive enzymes, the organ has also an endocrine function. The pancreatic islets are clusters of cells generally known as the islets of Langerhans are mainly designed to secrete glucagon, insulin, somatostatin, and pancreatic polypeptide (PP) hormones (Longnecker, 2014).

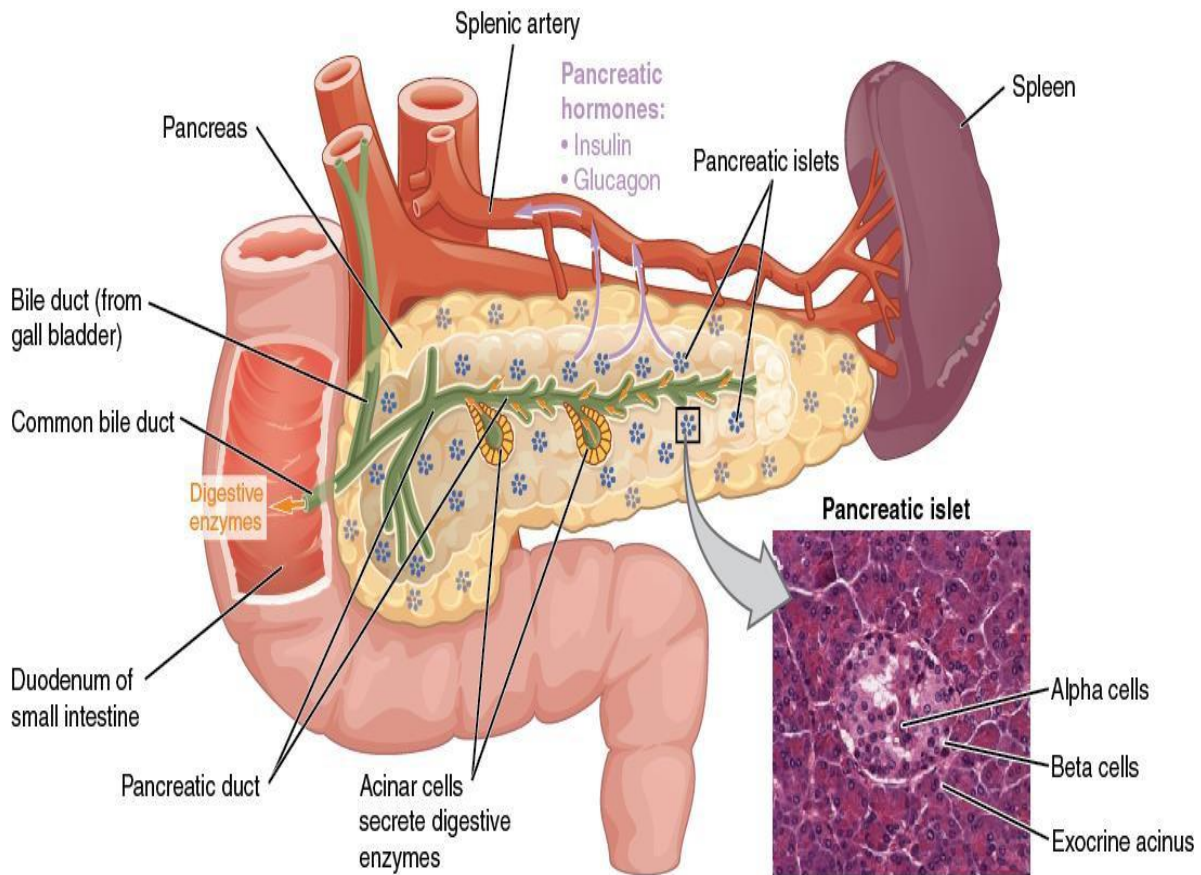


Figure 1.2: Pancreas. www.pharmatips.net. January 2019.

The pancreatic islets contain four major varieties of cells (Longnecker, 2014):

- (i) The alpha cell produces the hormone called glucagon and constitutes approximately 20 percent of each islet. Glucagon plays an important role in the regulation of blood glucose. When the blood glucose levels decrease, it stimulates the release of the hormone (Figure 1.2).
- (ii) The beta cell secretes the insulin hormone, which constitutes approximately 75 percent of each islet. The increase in blood glucose levels stimulates the release of insulin hormone (Figure 1.2).

(iii) The delta cell constitutes about 4% of the islet cells and secretes mainly the peptide hormone somatostatin, which is an inhibiting hormone, designed to inhibit the release of both glucagon and insulin (Figure 1.2).

The PP cell accounts for about 1% of islet cells, responsible for the secretion of the pancreatic polypeptide hormone. It is known to play an important role in appetite, as well as in the regulation of pancreatic exocrine and endocrine secretions (Figure 1.2).

The beta-cells of the pancreatic islets synthesize insulin from preproinsulin which is a single chain precursor of 110 amino acids. After translocation through the membrane of the rough endoplasmic reticulum, proinsulin will then be formed from the 24-amino-acid N-terminal signal peptide of preproinsulin. Here, the molecule folds and the disulphide bonds are formed (Figure 1.3). In the Golgi-complex, human proinsulin will go through a process of conversion to insulin, subsequently, four basic amino acids and the remaining connector or C peptide are removed by proteolysis. This process will result in the formation of two-peptide chains (A and B) (Figure 1.3) of the insulin molecule, which contains one intra-subunit and two inter-subunit disulfide bonds. The A chain usually is composed of 21 amino acids and the B chain 30. The two major chains compose insulin and form a highly ordered structure with several helical regions in both the A and B chains.

Two ions of Zn^{2+} are coordinated in a proinsulin hexamer and pancreatic β cells stored in the granules in the form of insulin. It is believed that Zn^{2+} has a functional role in the formation of crystals and that crystallization facilitates remarkably the conversion of proinsulin to insulin, as well as the storage hormone (Jones and Persaud, 2017).

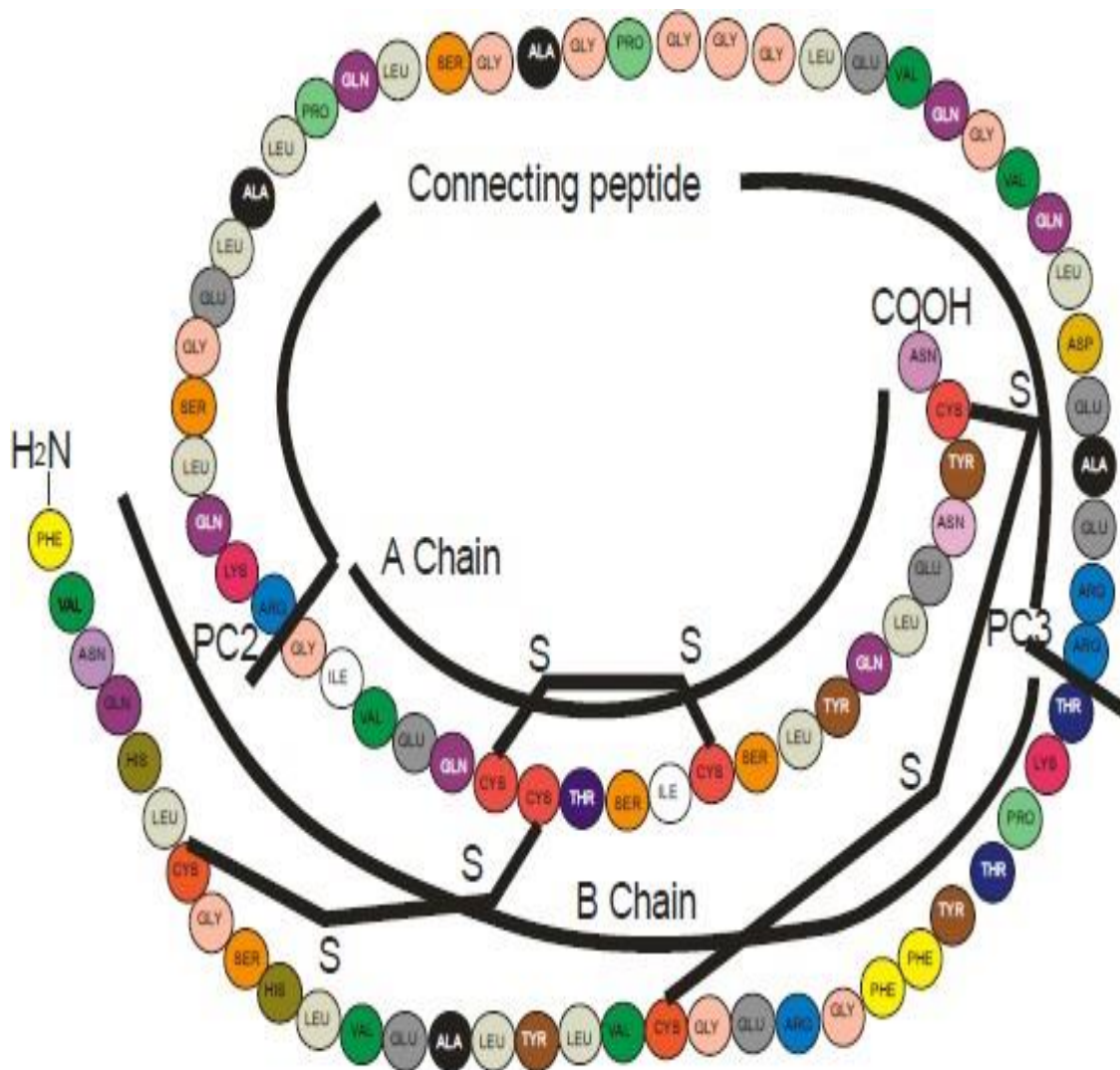


Figure 1.3: Structure of human proinsulin. Insulin is shown as the shaded peptide chains, A and B (Cubero and Rojas, 2017).

1.6.1 Insulin secretion

Insulin is mainly released from pancreatic β -cells at a low basal rate and at a much higher rate subsequent to response to a variety of stimuli, such as blood glucose levels. Hyperglycaemia results in increased intracellular ATP (adenosine triphosphate) levels, which will lead to close the ATP-dependent potassium channels. Decreased outward potassium levels through this channel result in depolarization of the β -cell and the opening of voltage-gated calcium channels. Thence the increased intracellular of calcium triggers the secretion of the hormone (Figure 1.4).

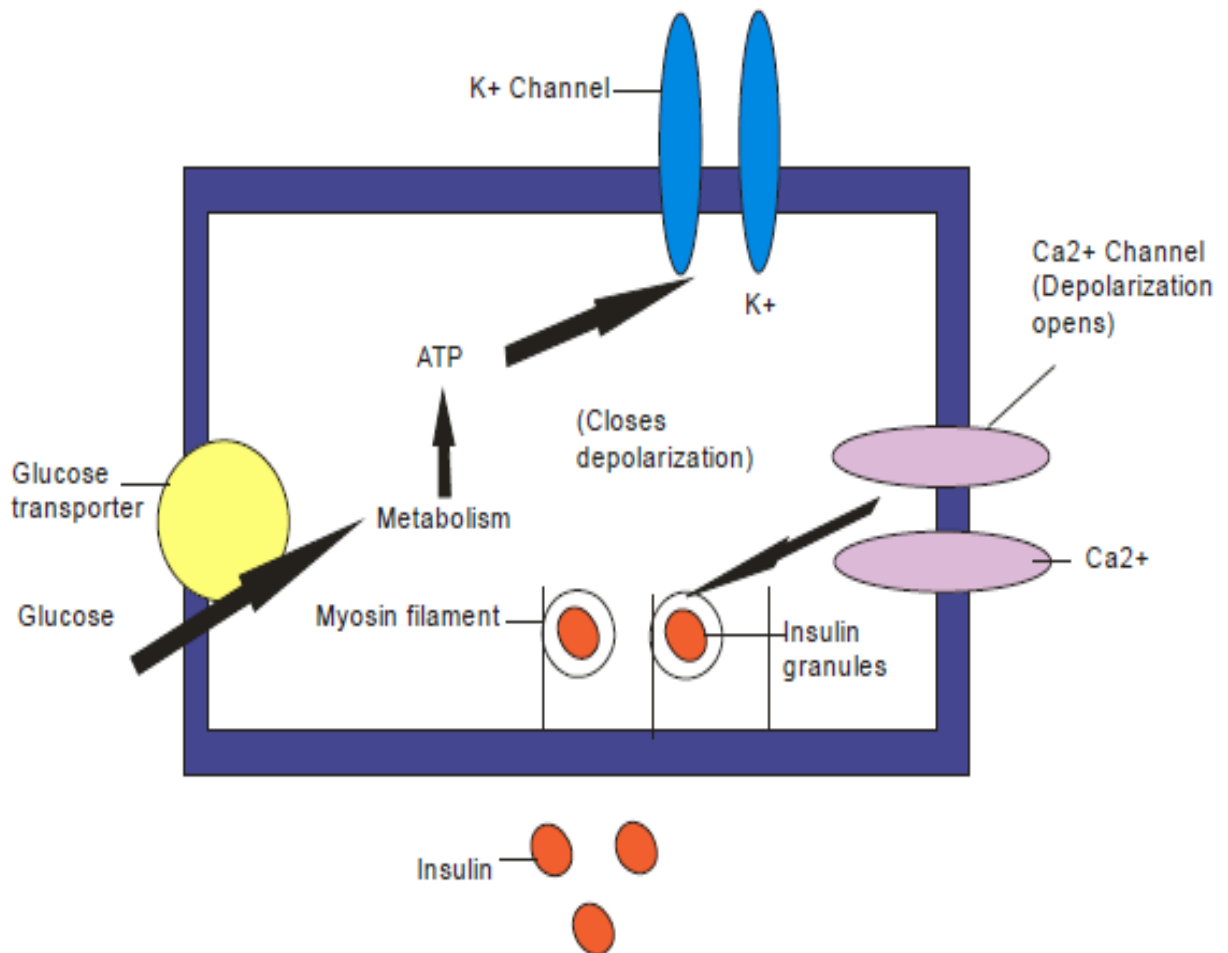


Figure 1.4: Model of the control of insulin release from the pancreatic β -cells by glucose (Olubomehin, 2014).

1.6.2 Insulin degradation

Insulin hormone is removed from the circulation by the two main organs, Liver and kidney, presumably by hydrolysis of the disulfide connection between the two chains A and B through the action of glutathione insulin transhydrogenase (insulinase). After this reductive cleavage, further degradation by proteolysis will happen. Kidneys are removing 35 – 40% of the endogenous hormone, while the liver normally clears the blood of approximately 60% of the insulin released from the pancreas by virtue of its location as the terminal site of the portal vein blood flow. However, in diabetics patients, insulin-treated, receiving subcutaneous insulin injections, this ratio is reversed such that 60% of exogenous insulin hormone is being cleared by the kidney and the liver is removing no more than 30-40%. The half-life of circulating insulin is 3-5 minutes (Olubomehin, 2014).

1.6.3. Structures of Insulin receptor

Once insulin has entered the circulation, specialized receptors that are located on the membranes of most cells, bound the hormone. However, the biological responses promoted by this insulin–receptor complexes have only been identified in some target tissues, e.g. muscle, liver, and adipose tissue. Those biological receptors, with high specificity and affinity, bind insulin hormone, in the picomolar range. The full insulin receptor consists of two heterodimers, each heterodimer is containing an alpha subunit, which is entirely extracellular and constitutes the recognition site, and a beta subunit that spans the membrane (Figure 1.5). The β - subunit possesses a tyrosine kinase. When insulin binds to the alpha subunit on the outer surface of the cell, tyrosine kinase activity is subsequently stimulated in the beta portion. Although the β dimeric form is capable of binding insulin hormone, it does so with a much lower affinity than the tetrameric β form. Self-phosphorylation of the β portion of the receptor causes an increased aggregation of β heterodimers and leads to the stabilization of the activated state of the receptor tyrosine kinase.

In clinical situations, elevated levels of circulating insulin in obesity or insulinoma, causes the concentration of insulin receptors to be reduced. This downregulation of insulin receptors seems to provide an intrinsic mechanism whereby the target cells may act to limit their response to excessive hormone concentrations (Olubomehin, 2014).

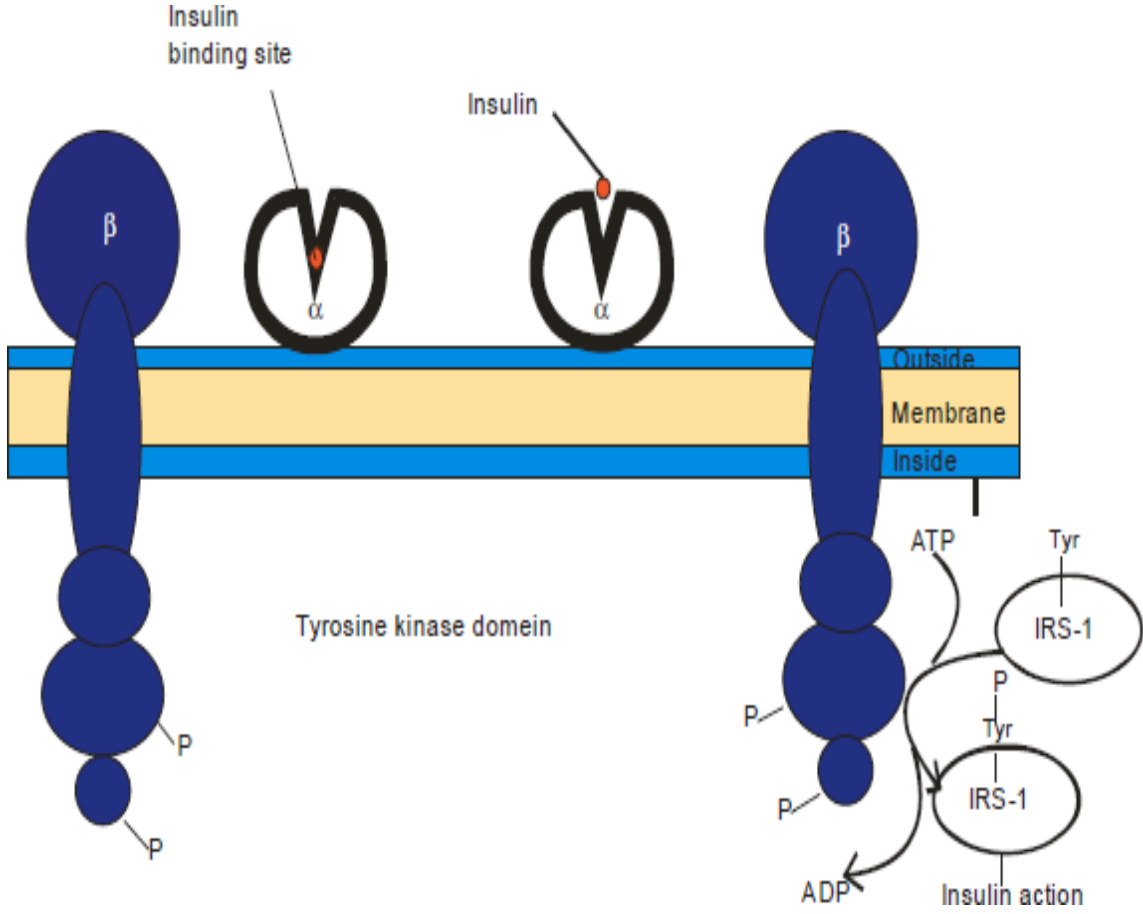


Figure 1.5: Schematic diagram of the probable structure of the insulin receptor tetramer in the activated state (Olubomehin, 2014).

1.6.4 Effects of insulin on its targets

Insulin promotes the storage of fat as well as glucose, using specialized target cells which influences cell growth as well as metabolic functions of a wide variety of tissues.

1.6.5 Action of insulin on glucose transporters

Insulin has demonstrated the important effect on several transport molecules to facilitate glucose movement across cell membranes. These transporters may play a major role in the etiology of diabetes as well as the manifestation. The glucose transporter, GLUT 4, represent quantitatively, the most important in terms of lowering blood glucose, is inserted into the membranes of muscle and adipose cells from intracellular storage vesicles. Defects in the glucose transporter (GLUT 2), mediated transport of glucose into pancreatic β -cells may contribute to the development of reduced insulin secretion which characterizes type II diabetes.

1.6.6 Action of insulin on the liver

The function of the liver is to increase storage of glucose (glycogen) and to reset the liver to the fed state by reversing catabolic mechanisms, such as glycogenolysis, ketogenesis, and gluconeogenesis, which are associated with the post-absorptive state. Liver remains, the first major organ reached by endogenous insulin via the portal circulation. These effects are caused by activating pyruvate kinase, phosphofructokinase, and glucokinase, while relieving gluconeogenic enzymes, including pyruvate carboxylase, phosphoenolpyruvate carboxykinase, fructose biphosphatase, and glucose 6-phosphatase which are activated by insulin-induced phosphorylations. The indirect effects of Insulin in decreasing hepatic gluconeogenesis and ketogenesis are reducing the fatty acid flux to the liver

through its antilipolytic action on adipocytes. In addition, insulin decreases urea production, protein catabolism, cAMP (cyclic adenosine monophosphate) in the liver, contributes to the promotion of triglyceride synthesis and increases potassium and phosphate uptake by the liver.

1.6.7 Effect of insulin on muscle

Protein synthesis is promoted by insulin hormone, by increasing the amino acid transport and by stimulating ribosomal activity. It also promotes glycogen synthesis to replace the glycogen stores expended by series of activities executed by muscle. This is accomplished by increasing the transportation of glucose into the cells of the muscles and by inducing glycogen synthase and contributing to inhibit glycogen phosphorylase.

1.6.8 Effect of insulin on adipose tissue

Circulating free fatty acids may be reduced by the insulin hormone. Additionally insulin will be promoting the triglyceride storage in adipocytes by three mechanisms:

- 1) induction of lipoprotein lipase, which actively hydrolyzes the triglycerides contained in the circulating lipoproteins;
- 2) transportation of glucose into cells which will lead to the generation of glycerophosphate as a metabolic product permitting esterification of fatty acids supplied by lipoprotein hydrolysis;
- 3) direct inhibition of intracellular lipase, subsequent to the reduction of intracellular lipolysis of stored triglyceride (Olubomehin, 2014).

1.7 Current Anti-Diabetic Drugs

Nine (9) major types of drugs are currently used in the treatment and management of diabetes namely insulin, sulfonylureas such as glibenclamide (commonly called glyburide), biguanides such as metformin (also known as Glucophage), the dipeptidyl peptidase iv inhibitors eg sitagliptin, the Glucagon-like peptide 1 agonists, alpha-glucosidase inhibitors such as acarbose, thiazolidinediones such as pioglitazone and less commonly phenylalanine derivatives and meglitinides (Setter et al., 2003). While, Metformin, is official, a biguanide, and primarily derived from its parent compound, guanidine, originally found in the plant *Galega officinalis* (Bailey and Day, 1989).

1.7.1 Metformin

Metformin remains the most widely used and prescribed anti-diabetic drug in the world (Grisouard et al. (2010) and has been a well-known drug for over half a century for the treatment of type 2 diabetes (Howlett and Bailey, 1999). Metformin may be used in monotherapy or in well-designed combination with other drugs such as the insulin or sulfonylureas (Krentz and Bailey, 2005). Unlike sulfonylureas (e.g. glibenclamide), metformin does not possess the capacity to increase insulin secretion, (Howlett and Bailey, 1999) but rather improves hepatic sensitivity to insulin thereby causing an apparent decrease of both fasting and postprandial blood glucose (Dunn and Peters, 1995).

Metformin is associated with an increased expression of glucose transporters and glycolytic enzymes (Figure 1.6). This serves to widely increase glucose utilization, and thus decrease considerably blood glucose levels (Grisouard et al., 2010). In experimental animal, metformin may elevate the tyrosine kinase activity, which is involved in insulin signaling (DeFronzo et al., 1991). An increase of tyrosine kinase will cause improvement both skeletal glucose usage and glycogen synthesis and causing the reduction of blood glucose levels (Prato et al., 1995). Metformin has also been found to hugely offer

some beneficial results for lipid profiles. It has been shown to successfully reduce total cholesterol, triglycerides and LDL cholesterol. It has, however, shown no significant increases to high-density lipoprotein (HDL) cholesterol levels (Trischitta et al., 1992).

The detailed pathway by which metformin acts are still poorly understood (Leverve et al., 2003). One of those mechanisms involves the capability of metformin to trigger AMP-activated protein kinase (AMPK) (Figure 1.6) which appears to be the regulatory enzyme in energy homeostasis within the body (Zhou et al., 2012). Researchers revealed that metformin plays an important role in the reduction of both cellular respiratory and mitochondrial functions through the inhibition of the enzymatic activity of chemical complex I in the respiratory channels both in skeletal muscle and hepatocytes (Detaille et al., 2002). Grisouard et al. (2010) demonstrated that AMPK might be concurrently activated in response to the hindrance of complex I.

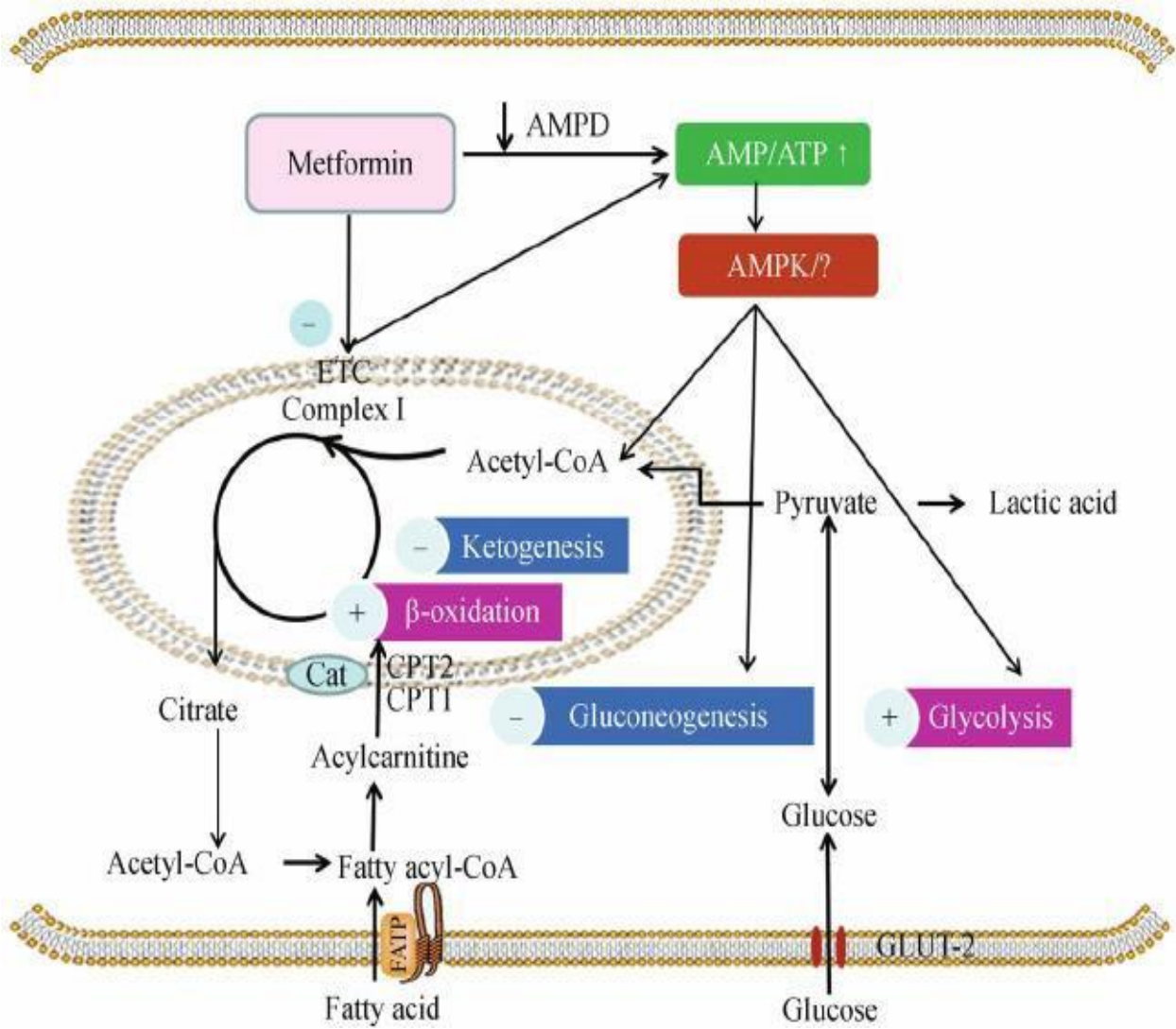


Figure 1. 6: Mechanism of action of metformin. Adapted from Bailey and Day (2010).

1.7.2 Glibenclamide

Glibenclamide, also called glyburide (Langer et al., 2000) is part of the second-generation sulphonylurea antidiabetic drug that is used currently to treat type 2 diabetes. This drug causes increase in plasma concentrations of insulin, while reducing plasma concentrations of both glucose and non-esterified fatty acids. It works by increasing insulin secretion by the pancreatic β -cells. It cannot be effective if the pancreatic β -cells are destroyed (Musbah and Furman, 1980). Glibenclamide have been shown to increase insulin sensitivity in the liver and subsequently reducing gluconeogenic activity.

The vivo studies by McGuinness and Cherrington (1990) revealed the capability of glibenclamide to elevate insulin's opposing effect on the gluconeogenic hormone called glucagon. These researchers also noted that in the absence of insulin in the case of diabetes type 1, glibenclamide could not perform negatively on the action of glucagon. However, glibenclamide may play an indirect role as an inhibitor of glucagon while improving the action of insulin.

It may reach its hypoglycaemic effects by several mechanisms such as: increasing glycogen synthesis by improving production of glycogen synthase, obstructing glycogenolysis by reducing phosphorylase α activity and thereafter stopping gluconeogenesis, increasing metabolic mechanism flux to glycolysis by decreasing A- kinase – activity (Caro, 1990). It also triggers other major biochemical mechanisms such as the glycolytic pathway by increasing the action of the main rate-limiting enzyme of this pathway (glucosidase), which phosphorylates glucose to glucose-6-phosphate. This would cause glucose to be metabolized by the liver and to generate energy in excess amounts that would be stored as glycogen in muscle or fat in adipose tissue.

1.8 Overview of current animal models of T2D

1.8.1 Diet induced models of T2D

1.8.1.1 Fat fed models

The most commonly used fat fed mouse model is the Diet Induced Obese (DIO) model using male C57BL/6J mice. The development of obesity is subjective to the amount of fat added to the diet, with high-fat diets used to induce obesity, whilst low-fat diets are unable to induce obesity. An important consideration when using fat fed rodents to induce insulin resistance is the initiation of fat feeding in diets at a young age between 6-8 weeks, as this has been shown to be most effective to develop obesity (Reuter, 2007). Mice are basically fed from a diet that contains 40-60% of calories from fat. These are high fat fed male C57BL/6J, approximately 8 times higher fat content compared with control mice for 8-16 weeks, although experimental mice became diabetic after just 4 weeks. The longer duration of fat-feeding contributes to the development of insulin resistance, impaired glucose tolerance revealing elevated serum insulin and glucose, abnormal lipid profiling and hyperglycaemia in a mild to moderate state; the degree to which is mainly dependent on the duration of the experiment and the type of fat (Reuter, 2007). Pancreatic islet dysfunction is also noted in this model, which is essential pathogenesis for T2D. The DIO rat model most popularly uses outbred Sprague-Dawley rats as it has a major sensitivity to high-fat diets to inducing insulin resistance and diabetes contrary to other rat strains.

1.8.2 Chemically induced rodent models of T2D

1.8.2.1 Alloxan

Alloxan was the first chemical inducer of T2D used in 1943 (Goldner and Gomori, 1943). Alloxan is a uric acid derivative that destroys only pancreatic β -cells through the mechanisms of oxidative stress (RERUP, 1970). On the other hand, Streptozotocin (STZ), is a natural antibiotic generated by the

bacterial species *Streptomyces achromogenes* (Islam and Wilson, 2012). It remains structural the analog of N-acetyl glucosamine that acts as a potent alkylating agent which results in the disruption of glucose transport, glucokinase activity as well as the induction of multiple DNA strand breaks (Goyal et al., 2016).

1.8.2.2 Streptozotozin

The natural antibiotic, Streptozotocin (STZ) (Figure 1.7) is produced by the microorganisms *Streptomyces*, (Fröde and Medeiros, 2008). It is a derivative from nitroso group and urea and structural analog of N-Acetyl-D-glucosamine (GlcNAc) Konrad et al. (2001) that acts as a potent alkylating agent which will cause disarrangement of glucose transport, glucokinase activity as well as induction of multiple DNA strand break (Bolzán and Bianchi, 2002).

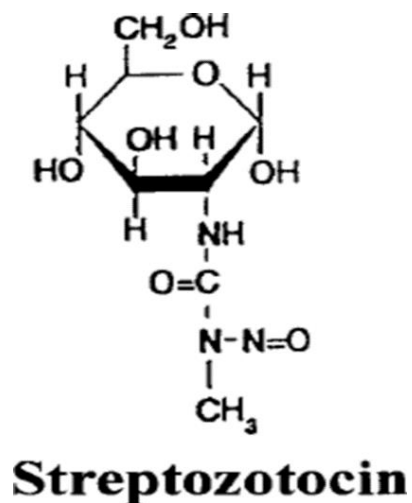


Figure 1.7: Chemical Structure of STZ adopted from Konrad et al. (2001)

STZ is able to penetrate the pancreatic β -cells through Glucose transporter 2 (GLUT-2) receptors resulting in DNA damage through alkyl group from one molecule to another, as well as causing the production of toxic superoxide and hydroxyl radicals. These radicals result in the destruction of the pancreatic β -cells by necrotic mechanisms (Szkudelski, 2001). Due to this reason, the use of STZ in diabetic research is widely used and it has been a non-surgical method to safely induce diabetic hyperglycaemia as well as progressive pancreatic β -cell destruction (Amirshahrokhi et al., 2008). Inducing diabetes with STZ has been vital as it selectively targets pancreatic β -cells through the alkylation of their DNA. It has been of major help in both types of diabetics for research (Zhang et al., 2015).

The residual pancreatic β -cell mass that will remain after the administration of STZ is estimated at 20%, which will progressively increase to 50% due to regeneration mechanisms of the pancreatic β -cell (Masiello, 2006). A mere single high dose of STZ administration (Figure 1.7), results in massive pancreatic β -cell damage, and is more characteristic of type 1 diabetes, whereas the injection of a low dose of STZ causes only partial disorder to insulin secretory mechanisms seen in type 2 diabetes (Srinivasan and Ramarao, 2007).

Several combinations over the decades were safely used to develop models for type 2 diabetes for selected research, including single high dose STZ injection, multiple low dose STZ injections or in combination with nicotinamide. It is, however, known that a single high dose of STZ administration, higher than 60 mg/kg body weight (BW) causes wide pancreatic β -cell destruction. This is more than the characteristic of type 1 diabetes, whereas low dose STZ injections between 40-55 mg/kg BW can cause only partial dysfunction to insulin production mechanisms as observed in type 2 diabetes (Srinivasan and Ramarao, 2007). But the dosages lower than 35 mg/kg BW in rats fed with ad libitum, with commercial diet fails to bring forth any hyperglycaemic effects in the experimental rats (Srinivasan and Ramarao, 2007). These composed drugs can be administered either via intravenously (I.V) or via intraperitoneally (I.P) at the following concentrations, 35-65 mg/kg body weight in rats, 100-200 mg/kg body weight of STZ in mice (Islam and Wilson, 2012).

1.9 Models of Streptozotocin-nicotinamide

Nicotinamide is the amide derivative of nicotinic acid and is commonly used as an agent in diabetic research. It is a potent scavenger of free radicals and provides a valuable portion of the coenzyme nicotinamide adenine dinucleotide (NAD). High dose of nicotinamide has been revealed to have a protective role in pancreatic β -cell survival against both exogenous toxic agents as well as from immune responses (Knip et al., 2000). This can reduce the toxic effects caused by STZ on pancreatic β -cells (Masiello, 2006). STZ causes damage of DNA in pancreatic β -cells and activates the enzyme poly (ADP-ribose) synthetase.

Nicotinamide inhibits the activity of the enzyme, thereby causing reduction of the apoptotic levels within the damaged pancreatic β -cells, and promoting pancreatic β -cell survival (Masiello, 2006). The STZ-nicotinamide model was originally brought forward by (Masiello et al., 1998) and later, (Nakamura et al., 2006) adapted similarly to a non-obese non-genetic model of type 2 diabetic in mice. The STZ-nicotinamide models may, therefore, guarantee many similarities to type 2 diabetics that are non-obese. This model is mainly characterized by normal weight gain and insulin secretion despite a moderate disruptive ability to produce insulin from pancreatic β -cells. Furthermore, it shows minimal disruptive fasting blood glucose levels and only mild glucose intolerance (Nakamura et al., 2006). This model possesses some positive effects in comparison to another non-genetic type 2 diabetics models as it can quickly change in a 5 weeks' time period, thus, helping to reduce experimental costs.

1.10 Overview of Anatomy of kidney

1.10. 1 Anatomy of the rat kidneys

The kidney of the rat is smooth and their borders are convex and concave. Each of the kidneys has got surfaces located dorsally and ventrally and medial and lateral borders. Each kidney has got indented hilus and an upper and lower pole. This is in agreement with Al-Samawy (2012), who also revealed that the kidneys of Wistar rat were bean shape and smooth. The hilus and sides of the kidney of the rat are surrounded by adipose tissue.

Anatomically the rat kidneys are located alongside the vertebral column in the abdominal cavity (Figure 1.8) and above their poles are situated at the suprarenal glands. The right kidney is situated more cranially than the left. The right kidney is situated more cranial than the left kidney and related to the liver while the left is related to the stomach, pancreas, descending colon, spleen and small intestine. This result is supported by that of Al-Samawy (2012) who registered that the paired kidneys of the two investigated rodents were bean shaped and dark red bodies located in the dorsal wall of the abdominal cavity. The mean weight of the right kidney is about 1.1 gm while the left one is about 0.96 gm. The mean length, width, and thickness of the right kidney are 1.28 cm, 0.88 and 0.81 cm respectively while those of the left are 1.23 cm, 0.85 and 0.79 cm.

The color of rat kidneys is reddish-brown and are covered by a thin connective tissue capsule that is adherent to subcapsular connective tissue, in agreement with (Mohamed, 2014). Each kidney is made of connective tissue which may contain a distinct layer of smooth muscle in its deepest portion and is enclosed by a fibroconnective tissue capsule. With reference to the histology, the kidney of rat is formed by two regions, the outer cortex, and the inner medulla. The cortex and medulla are arranged into more pyramidal shape called renal pyramids. The apex of each pyramid is named renal papilla (Figure 1.9). The nephron forms the basic and functional unit of the rat kidney.

Each nephron may be safely subdivided into a number of distinct parts into the cortex and medulla. The nephron composed of a renal corpuscle and the first part of nephron consists of glomerulus and Bowman's capsule, the proximal convoluted tubules, a loop of Henle which arranged into ascending and descending limb and then the distal convoluted tubules. In the cortex, we may observe renal corpuscles, proximal convoluted tubules and distal convoluted tubules (Mohamed, 2014). The renal corpuscle is a rounded or irregular structure which forms the glomeruli that are enveloped by Bowman's capsule. The Bowman's capsule is formed by two thin cellular layers, the outer parietal layer and an inner visceral layer. The parietal layer consists of a flat single layer of squamous epithelium enclosing a narrow space, or the urinary space is continuous with the lumen of the proximal convoluted tubule. The visceral layer is surrounding the glomerular capillaries. The visceral space of renal corpuscle communicates with arteries of glomeruli (Mohamed, 2014). The renal corpuscle is a spherical structure formed by glomerulus which is enclosed by Bowman's capsule.

The initial and terminal parts of the nephron are composed by the proximal convoluted tubule and distal convoluted. The proximal convoluted tubule arises from the arterial epithelium of Bowman's capsule of the urinary space of the renal corpuscle. The proximal tubule exits as a small, uneven lumen and a single layer of cuboidal cells with eosinophilic, granular cytoplasm. The proximal tubules and the distal convoluted tubules are different, in that the cells lining are of the cuboidal type with rounded and large nuclei, possess no brush border. The distal convoluted tubules appear shorter than the proximal convoluted tubules and are fewer in number in the regional cortex (Mohamed, 2014).

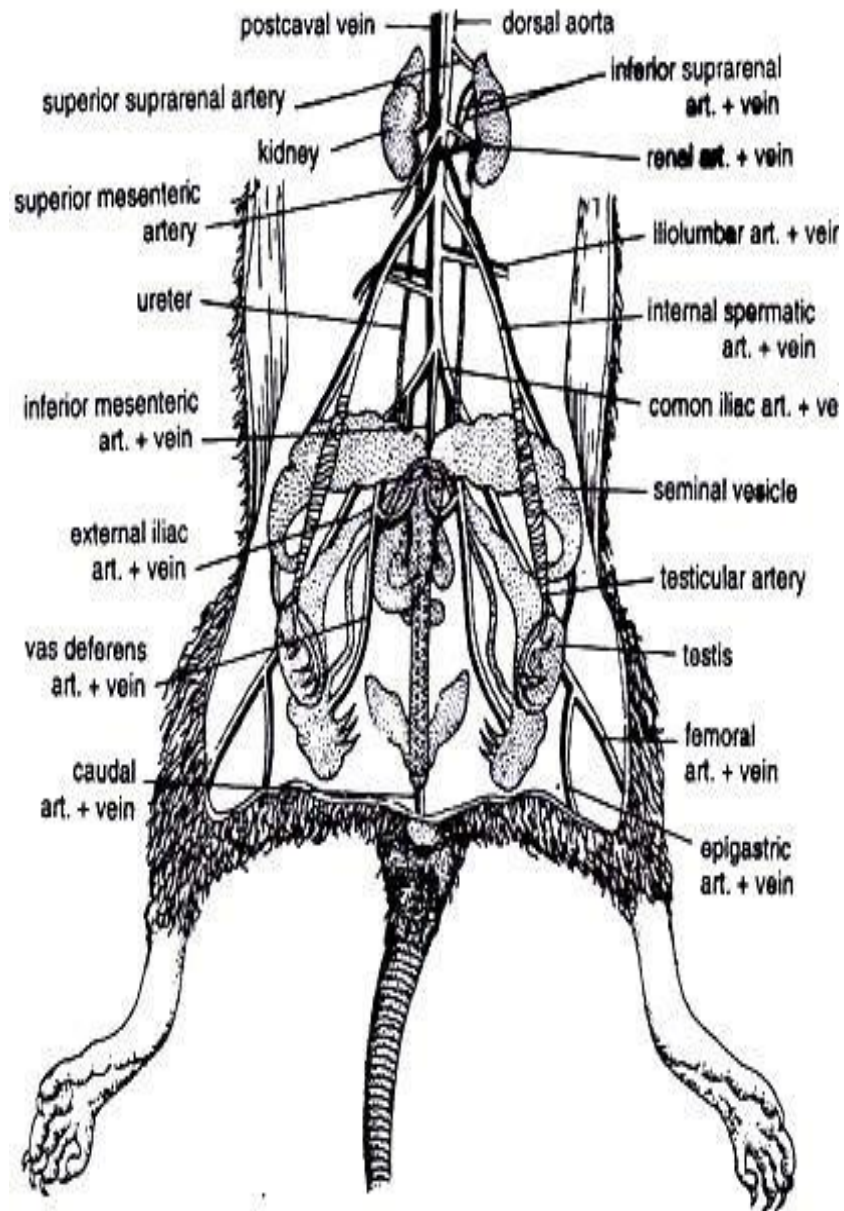


Figure 1.8: Schematic drawing showing location of the kidneys in the abdomen of a rat.

www.biologydiscussion.com (February 2019).

1.11 Anatomy of Human kidneys

The kidneys are two bean-shaped organs that lie on either side of the spine in the retroperitoneal space between the parietal peritoneum and the posterior abdominal wall. They are roughly the size of 11 cm long and the male kidney is typically a bit larger than the female kidney. About 25 percent of the cardiac output at rest is released to the kidneys, the reason why kidneys are well vascularized. One of the major excretory organs of the body is the kidney (Al-Samawy, 2012). Each kidney weighs about 120 to 150gms and a thin, tough fibrous capsule protect the kidney as a protective layer.

The hilum of the kidney is concave, located medially, receives the renal artery that enters to deliver oxygenated blood and renal vein exits with deoxygenated blood. In addition, the ureter leaves the kidney at the same point. The components of the kidney are arranged in three layers. A frontal section through the kidney reveals an outer region called the renal cortex and an inner region called the medulla (Al-Samawy, 2012). The cortex has a brownish red and granular appearance. It contains the corpuscles of the kidneys and convoluted tubules (Figure 1.10). At intervals, cortical tissue penetrates the medulla in the form of columns, called columns of Bertini. Tubular structures and the nephrons are found in the medulla which has a striated appearance, radially. Medulla mass is divided into 8 to 18 medullary or Malpighian pyramids (Figure 1.10). The basal portion of each pyramid is in contact with the cortex and the apex projects into a minor calyx (Al-Samawy, 2012).

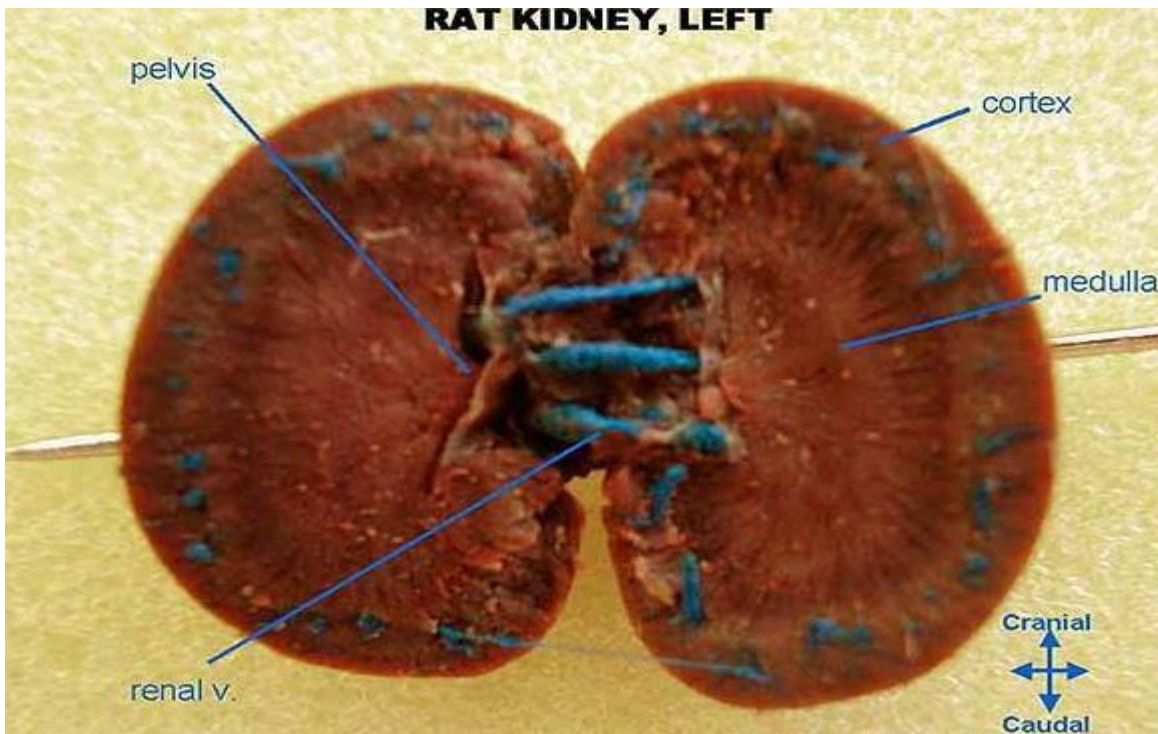


Figure 1.9: Sagittal section of rat kidney. www.sharelike.me, February, 2019

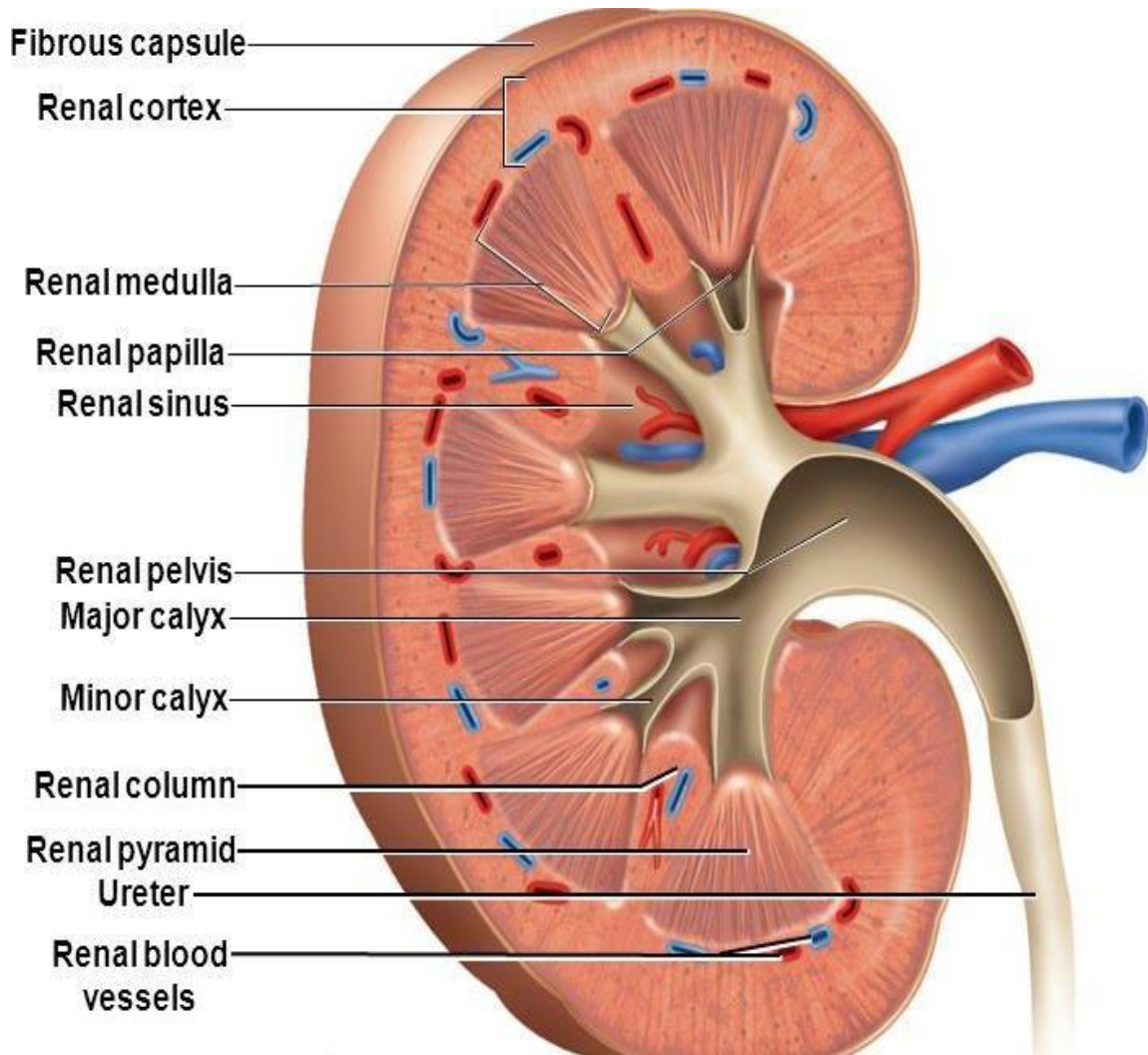


Figure 1.10: Schematic diagram showing sagittal section of human kidney (Adapted from Rolfe, 2017).

1.11.1 Nephrons as the functional unit of the kidney

The “functional units” of the kidney are nephrons. They cleanse the blood and balance the constituents of the circulation. The afferent arterioles form a tuft of high-pressure capillaries is about 200 μm in diameter. The rest of the nephron consists of a continuous sophisticated tubule whose proximal end surrounds the glomerulus in an intimate embrace (Suchy-Dicey et al., 2016). This is the Bowman’s capsule. The renal corpuscle is composed of glomerulus and Bowman’s capsule. Some nephrons have a short loop of Henle that does not expand beyond the cortex, and they are called cortical nephrons. About 15 percent of nephrons have long loops of Henle that are found deep into the medulla named juxtamedullary nephrons (Suchy-Dicey et al., 2016). The nephrons possess various portions that are functioning differently in their capacity to reabsorb water and specific solutes (Figure 1.11). While much of the reabsorption and secretion occur passively based on the polarity, the regulation of the amount of water that is sponged up or lost is strictly performed. This water management is mainly performed by ADH and aldosterone, and indirectly by renin. Most water is recovered in the PCT, loop of Henle, and DCT. About 10 percent (about 18 L) reaches the collecting ducts. ADH helps to recover almost all of the water passing through the collecting ducts, in cases of dehydration, or almost none of the water, in cases of over-hydration (Suchy-Dicey et al., 2016).

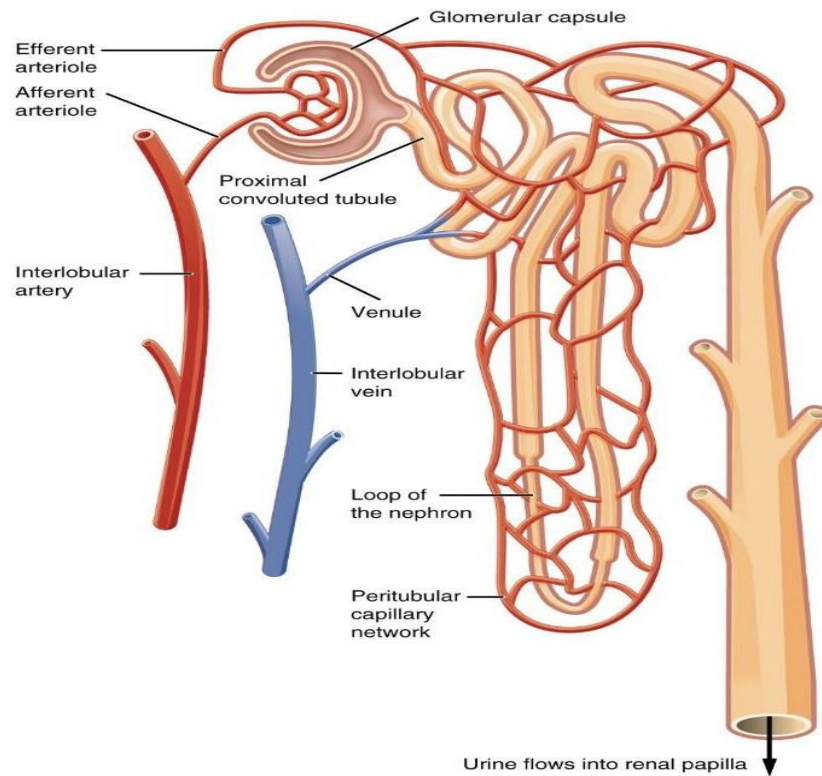


Figure 1.11: Schematic diagram showing structure of the nephron. Adapted from Feig et al. (2008).

1.11. 2 Histology of the kidney

The internal or visceral layer surrounding the glomerular capillaries possesses modified epithelial cells named podocyte. The podocytes are constituted by long processes, called foot processes and foot projections, or pedicels, which serve as the origins of the name podocyte (Al-Samawy, 2012). The glomerulus ("little ball") is essentially a small knot of capillaries and supporting structures suspended within Bowman's capsule. The glomerulus will initially filtrate the plasma that is eventually processed into the urine. Because of this function, the glomerulus appears as the most significant component of the nephron. Mesangial cell nuclei may sometimes be recognized as small, irregularly shaped, and rather heterochromatic nuclei within the glomerulus. Lacis cells or cells of

Goormaghtigh are extra-glomerular mesangial cells, which occupy the space between the glomerulus and the macula densa of the distal tubule. The mesangial cells are covered by the mesangial matrix that is extracellular material which apart from offering some mechanical support to the glomerular capillaries, the function of the mesangial matrix is unknown.

Proximal convoluted tubules possess internally lining cuboidal epithelial cells which rest on the basement membrane and are thin structures distinguishable by the widest lumen (Figure 1.12). The descending of the proximal tubules is much related in the structure to the proximal convoluted tubules while the straight (ascending) segments of the distal tubules are like the distal convoluted tubules. These cells are characterized by ground eosinophilic cytoplasm, large nuclei located in the center and possess apical surface that is mainly covered by microvilli (brush border) (Al-Samawy, 2012). Simple cuboidal epithelium constitutes the lining structure of the proximal convoluted tubule whose cells have several characteristic features. The brush border is plainly visible in routine histological preparations, but proximal tubule cells tend to have indistinct apical ends (in contrast to the more definite apical border of cells comprising distal tubules and collecting ducts). Cells have a high proportion of mitochondria in their cytoplasm, to provide the energy in order to pump ions and molecules against their concentration (Al-Samawy, 2012). The apical end of each cell has a brush border of microvilli. Microvilli provide an increased surface area to accommodate the membrane channels that are responsible for absorbing into the cell small molecules from the filtrate in the tubular lumen.

Tubules descending segments of the proximal tubules, ascending segments of the distal tubules and the collecting tubules constitute the medullary rays (Al-Samawy, 2012). While the epithelial lining of distal convoluted tubules shows extensive lumen and the cuboidal cells can be identified by the cytoplasm, clearly less eosinophilic than that of the proximal tubules and the apical surface of the distal convoluted tubule (Figure 1.12). Straight parts of the tubules and the loop of Henle are found in the medulla only. The loop of Henle is the structure which consists of two segments, thick and thin descending and ascending.

The loop of Henle is a major feature of the renal tubule, associated with the remarkable function of the renal medulla in water conservation. Basically, the loop of Henle helps to establish a hypertonic saline environment within the medulla, which in turn allows subsequent recovery of water from collecting ducts and associated concentration of urine within the collecting ducts. Descending limb, having an initial short thick segment followed by a long thin segment, and an ascending limb, with a thin segment followed by a thick segment form the loop of Henle. The descending thick segment is lined by simple cuboidal epithelium that is structurally similar to the proximal convoluted tubule. This segment is essentially a continuation of the proximal tubule (sometimes called pars recta in contrast to pars convolute). Simple squamous epithelium lining in the descending thin segment as well the ascending thin segment (Murayama and Sakai, 1975).

But simple cuboidal epithelium lining in the ascending thick segment that is structurally similar to the distal convoluted tubule (as for the proximal tubule, this segment is sometimes called pars recta of the distal tubule in contrast to pars convolute).

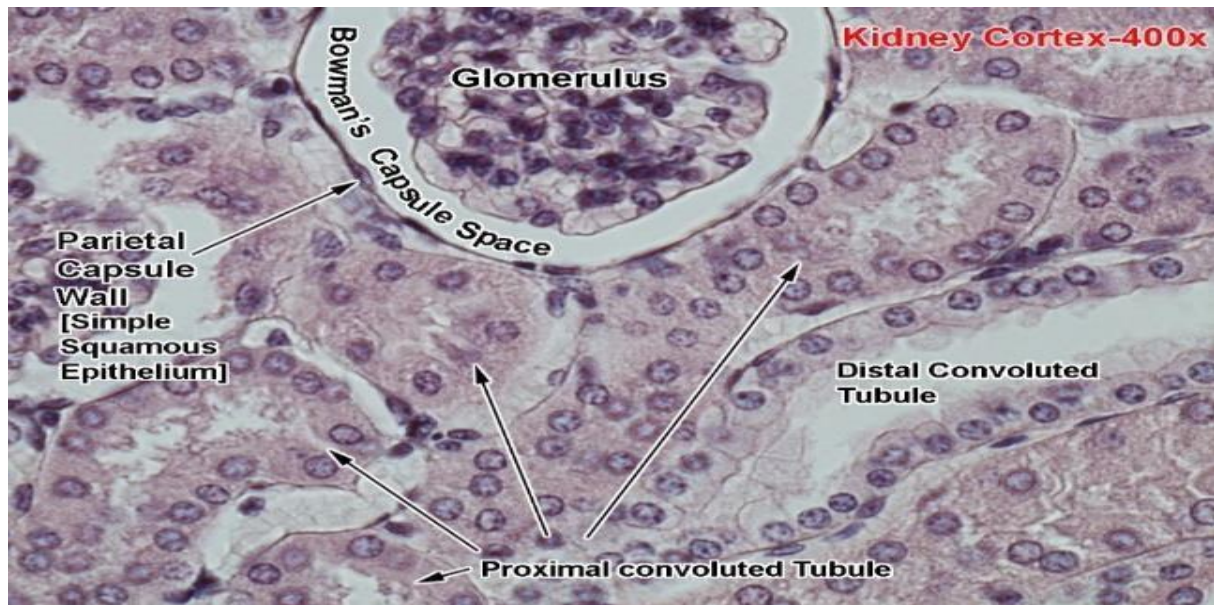


Figure 1.12: Image of Microscopic anatomy of Kidney, February, 2019. www.auanet.org. Magnification $\times 400$.

1.11.3 Renal Circulation

From the left interior side of the abdominal aorta arise the renal arteries, immediately below the superior mesenteric artery, and supply the kidneys with blood. Each is directed across the crus of the diaphragm, so as to form nearly a right angle (Figure 1.13). The renal arteries carry a large amount of total blood flow to the kidneys. Up to 25% of total cardiac output may pass the renal arteries to be filtered by the kidneys (Fattah et al., 2019). Paired renal arteries are formed by the Aorta, each of which enters the kidney at the hilum and will be dividing into an anterior and posterior branch, which later, breaks into about five segmental arteries. The interlobar arteries are formed by segmental arteries, which penetrate the medulla between the pyramids to reach the border zone between the medulla and cortex. Henceforth, they, in turn through a horizontal course join with adjacent arteries to form the arcuate arteries (arterial arches). Several straight arteries are produced from these arches and run radially outward through the cortex. They are then named interlobular arteries. Numerous afferent arterioles are the division of each interlobular artery, which subdivides into 4 to 5 large capillary loops, which unite to the efferent arterioles to form the renal portal system.

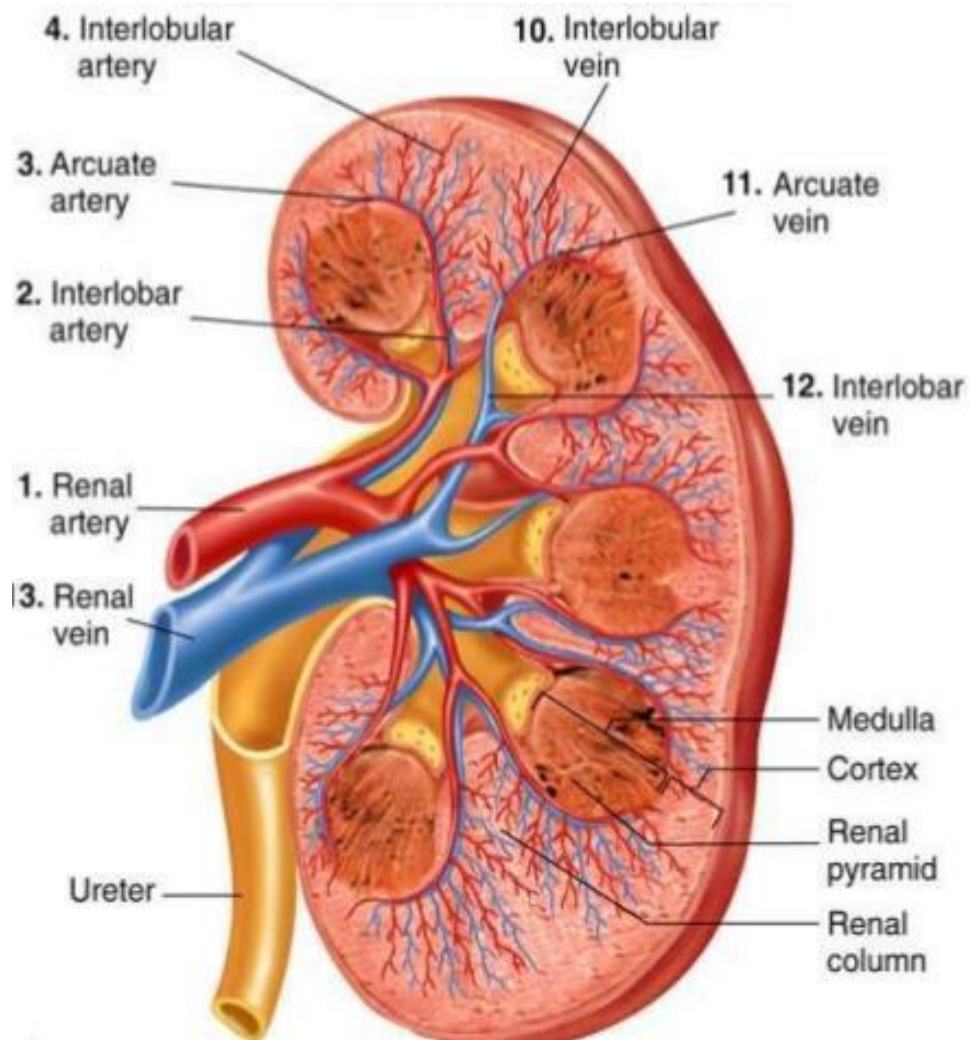


Figure 1.13: Renal circulation, February, 2019. www.pt.slideshare.net.

1.11.4 Urine Formation

Kidneys excrete the rejected substances, including metabolic end products, and those substances, which are present in excessive quantities in the body, via urine. Normally, the body generates about 1-1.5 liters of urine per day. The mechanism of urine formation passes through various processes. It commences with a portion of blood that enters the glomerular capillaries. The plasma is filtered into the Bowman's capsule. When this filtrated blood passes through the tubular portion of the nephron, it undergoes several changes with regard to its quality and quantity (Suchy-Dicey et al., 2016). Many desirable substances like glucose, amino acids, water and electrolytes are picked up from the tubules. This is tubular reabsorption. Some undesirable substances are ejected into the tubule through the blood vessels of the peritubular area. This process is called tubular secretion or excretion.

The production of the urine follows three steps:

- (i) Glomerular filtration;
- (ii) Reabsorption through the tubules, and;
- (iii) Secretion via the tubules.

1.11.5 Glomerular Filtration

The circulation of the blood through the glomerular capillaries enables the plasma to be filtered into the Bowman's capsule. Plasma proteins are the only substances which are not filtered among others. The filtered fluid is the glomerular filtrate (Suchy-Dicey et al., 2016). During the filtration process, substances pass through three layers of filtrating membrane namely:

1. The endothelium of capillary membrane
2. Basement membrane and

3. Endothelium of visceral layers of bowmen's capsule

The glomerular filtration is named ultra-filtration due to minute particles that are filtered. The plasma proteins are not filtered because of their larger molecular size than size of the slit pores. The composition of glomerular filtrate is similar to that of plasma except in the absence of plasma proteins.

1.11.5.1 Glomerular filtrate rate (GFR)

The total quantity of filtrate generated in all the nephrons of both kidneys during a period of time depends on the glomerular filtration rate. Normal glomerular filtration rate is 125 ml per minute or about 180 litre/day. The glomerular filtration rate constitutes the volume of filtrate formed by both kidneys per minute (GFR). About, 5 L of blood are ejected per min under resting conditions by the heart (Levey et al., 1999).

The amount of blood generated equates to a volume of about 180 L/day in male and 150 L/day in female. Meanwhile, 75% of this filtered blood is pushed back into the circulation by reabsorption so that only about 1–2 litres of urine are generated per day (Levey et al., 1999). Although up to 180 litres per day passes through the nephrons, obviously, major portion of that fluid and its contents will be reabsorbed. Proximal convoluted tubule (PCT), loop of Henle, distal convoluted tubule (DCT), and the collecting ducts are the recovery sites.

1.11.6 Tubular Reabsorption

When the glomerular filtrate crosses (passes through) the tubular portion of nephron, quantitative and qualitative changes rapidly occur. The tubular epithelial cells possess the power to reabsorb huge amount of water, electrolytes and other substances. The substances, which are reabsorbed, are injected into the interstitial fluid of the renal medulla, and thence the substances are moved into the blood in the peritubular capillaries. Because the substances are ejected back into the blood, the entire process is named tubular reabsorption.

1.11.7 Selective Reabsorption

The kidney selectively reabsorbs the substances found in the glomerular filtrate via the tubular cells, based on the needs of the body. This is the selective tubular reabsorption. Active reabsorption and Passive reabsorption are forming the process of reabsorption. In active reabsorption, molecules are moved against the electrochemical gradient and subsequently demands utilization of energy and the energy is derived from ATP while in passive reabsorption, molecules will be passing more along the electrochemical gradient which does not require energy.

1.11.8 Tubular Secretion

This refers to a process whereby some materials are secreted into the lumen from the peritubular capillaries through the tubular epithelial cells. During this process some substances, such as hydrogen ions, creatinine, and drugs will be subjected to be cleaned from the blood through the peritubular capillary mechanism within the collecting duct. The urine will subsequently form as end product, which is a collection of substances, that are basically not reabsorbed during glomerular filtration or tubular reabsorption (Suchy-Dacey et al., 2016).

Water that has not been reabsorbed forms mainly the urine, which is the way in which the body lowers blood volume, by increasing the amount of water that becomes urine instead of becoming reabsorbed. Many salts and other waste components compose the urine. Urine does not contain red blood cells and sugar under normal condition, whence found, it may indicate glomerulus injury and diabetes mellitus respectively. Tubular secretion of solutes is more efficient than glomerular filtration and it is strong mechanism for elimination of drug, subsequently may cause important clinical consequences of secretion disorder. Investigating tubular secretion as an independent marker of kidney function may provide a light into the etiology of kidney disease and improve prediction of adverse outcomes. One may estimate the secretion function by recording secreted solute.

1.12 Nanoparticles and Herbal Formulations

Despite the introduction of various antidiabetic and hypoglycemic agents, diabetes and its associated complications continue to pose a major problem in the world population (Subramoniam, 2016). Various types of currently used anti-diabetic drugs cannot manage blood glucose levels and develop side effects and/or insufficient response after prolonged use of these drugs. The necessity to look for new medicines and interventions that can be used to manage this metabolic disorder has been noted by various researchers and practitioners in this field (Subramoniam, 2016). This is supported by (Martone et al., 2010), who stressed that alternative therapy is required; and there is currently a need to shift towards African indigenous plant and herbal formulations. Biomedical applications using nanoparticles (NPs) have become a very active research area in recent years (Mieszawska et al., 2013).

Compared with conventional formulations, nanotechnology-based drug carriers have more medical benefits (Zhou et al., 2012). Novel drug delivery systems (NDDS) not only reduce the repeated administration to overcome non-compliance, but also help to increase the therapeutic value by

reducing toxicity and increasing the bioavailability. Nanotechnology is the novel approach. Nano-sized drug delivery systems of herbal drugs have potentials for enhancing the activity and contribute to overcome problems linked to plant medicines (Subramoniam, 2016). Hence, integration of the nanocarriers as a NDDS in the traditional medicine system is essential to combat and control efficiently chronic diseases like asthma, and cancer, in addition to diabetes (Subramoniam, 2016).

Incorporation of the herbal extracts into novel formulation systems have certain added advantages, such as overcoming bulk dosing and lower absorption, which are the major problems being faced, and thus drawing the attention of major pharmaceutical corporations (Subramoniam, 2016). Plants have long demonstrated the capacity to assimilate and aggregate inorganic metallic particles (Shah et al., 2015). The use of *Cinnamomum cassia* in nanoparticles synthesis, appears eco-accommodating, compared to the naturally based system like parasites, which have different focal points, maintains a strategic distance and have a tendency to be costly (Shah et al., 2015).

On the other hand, biosynthesis of silver nanoparticles from plants or plant-based concentrates as *Cinnamomum cassia* has all the earmarks of being sheltered, have generally short generation times, and have a lower development cost in contrast with other natural frameworks. Moreover, plant-based biosynthesis has a straight forward technique that can be effortlessly scaled up for substantial scale generation of nanoparticles.

It has been revealed that not every natural substance can securely be combined with nanoparticles because of their chemical exercises and characteristic metabolic action (Shah et al., 2015). Consequently, it is essential to precisely determine fitting organic substance important to make nanoparticles with very much characterized properties, for example, size and morphology (Shah et al., 2015). *Cinnamomum cassia* is endorsed as a powder that is typically utilized and blended with different meds (Ghasemi Pirbalouti et al., 2014). Researchers have revealed that Cinnamon has insulin potentiating movement and in this way it might assume a part in glucose digestion (Magistrelli, 2010).

In spite of wide utilization of Cinnamon, for many remedies, the world does not have adequate understanding on organ toxicity or safety of *Cinnamomum cassia* especially after long term treatment.

Nanoparticles have many advantages for herbal drugs, including enhancement of solubility and bioavailability, protection from toxicity, enhancement of pharmacological activity, enhancement of stability, improving tissue macrophage distribution, sustained delivery, protection from physical and chemical degradation (Subramoniam, 2016). Nanoparticles have made major contributions to clinical medicine in the areas of drug/gene delivery. Nanocarriers have the ability to:

- i. protect the associated peptide from degradation in the gastrointestinal fluids;
- ii. facilitate the intestinal absorption of the associated peptide,
- iii. have a large (functional) surface which is able to bind, adsorb and carry other compounds such as drugs, and proteins.

NPs have a surface that might be chemically more reactive compared to their analogues (Borm et al., 2004). The biocompatible nanoparticles with physical, chemical and biological properties can be applied to optimize and overcome the limitations of conventional administration by improving drug solubility, increasing the rate of drug release and developing the penetration and distribution of drugs. Therefore, drug delivery systems provide the routes for drug delivery, which dramatically promote therapeutic effect of drugs (Karimi et al., 2016). The study done by Murthy (2007), about the toxicological effects of nanoparticles associated with medical applications such as iron oxide and nanoparticles revealed no toxicity. Nanoparticles have been found to be “nontoxic” according to many anecdotal reports (Connor et al., 2005).

1.13 Diabetes and Nanotechnology (Nanomedicine)

Nanotechnology is a branch of science and technology operating at the nanoscale, which is about 1 to 100 nanometers. Nanomedicine is defined as integration of nanotechnology in medicine to improve human health care. Nanoscience and nanotechnology possess a wide range of applications in various fields, such as green chemistry, herbal drug research (Riehemann et al., 2009). New opportunities for advancing biomedical science and disease treatment in human health care are opened up through new field of nanomedicine (Table 1.3). Rapid advances in health care, creates Nanomedicine scale limitations excludes at the lower end atoms (0.1 nm) and at the upper-end biological entities such as bacteria (1000–10000 nm) and body cells. Human body has configured many of its bio components as nanostructures, such as proteins, mitochondria, ion channels, membranes, secretory granules, lysosomes and many others, but new nanomaterials and structures are now being manufactured that might be of use in medicine, such as nanoparticles, capsules, films and tubes, and complex molecules (Riehemann et al., 2009).

Nanomedicine can be classified into measurement (or ‘nanometrology’), which deals with either measurement of very small amounts of analyses (e.g. microphysiometer) or using very small sized devices for measuring (e.g. Quantum dots) (Carneiro and Programme, 2002). Therapy, as all of the manipulations and constructions of materials at the nano-level used for therapies (e.g. Artificial Nano pancreas). The major problems faced by conventional finger-prick capillary blood glucose, self-monitoring are widely accepted. It is painful (leading to non-compliance) and cannot be performed when the patient is sleeping or driving a motor vehicle (times when the patient is especially vulnerable to hypoglycemia) and, because it is intermittent, it can miss dangerous fluctuations in blood glucose concentrations between tests. Currently in the market several implanted needle-type enzyme electrodes or micro dialysis probes are available for continuous glucose monitoring but those are limited impaired by responses and unpredictable signal drift in vivo, and also need calibration against capillary glucose tests and contributes to sensor inaccuracies (Garg and Hirsch, 2018).

The successive repeated insertion of the sensor probe is also semi-invasive. Nanomedicine is needed to overcome the fact that drug (herbal medicine) needs more time to show anti-diabetic activity because herbal drugs are basically more insoluble in nature. Herbal mediated silver nanoparticles (HMSNP's) are using less particle size, more surface area, more solubility which results in the optimum dose of drug that can reach to systemic circulation and onsite of action is very quick.

To efficiently solve the problem of intracellular reservoirs, Nanoparticulate systems using encapsulated payload can be internalized either by non-specific endocytosis or receptor-mediated endocytosis (Amiji et al., 2009). With regard to receptor-mediated endocytosis, the surface of nanoparticulate carrier needs to be adapted with a specific ligand that will recognize its receptor on the cell of interest. Nanoparticles bearing specific superficial layer with arginine-rich cell penetrating peptides (CPP) has been shown to enhance intracellular delivery (Amiji et al., 2009). As an example, some authors positively utilized encapsulated saquinavir in biodegradable hydrophobic polymeric designed with nanoparticles and made with poly (ethylene oxide)-modified poly(epsilon-caprolactone) (PEO-PCL) (Shah and Amiji, 2006).

The management of diabetes has new research area in nanotechnology which is perceived to be effective (Awan et al., 2016). One of the important applications of nanotechnology in the medical field is the use of it in drug delivery to target tissues for therapy of disease such as diabetes (Table 1.3). In addition, one of the limitations in the use of traditional medicine systems is that there is lack of target specificity, which reduces the effects of compounds due to drug metabolism in the body and the cellular toxicity of some drugs (Lee, 1995). In another study, animals with Streptozotocin-induced diabetes showed marked reductions in blood glucose levels after 4 weeks of continuous administration of aqueous extract of Cassia fistula and Cassia fistula gold nanoparticles (Daisy and Saipriya, 2012).

Decreased serum urea, creatinine, and uric acid are observed more effectively upon oral administration of nanoparticles to diabetics rats, than crude extracts of *Cinnamomum cassia*, and this is explained by the regenerative ability over the renal tubules (Tedong et al., 2006). Various chronic diseases such as diabetes, cancer, AIDS, nephritis, metabolic and neurodegenerative disorders may be manageable through the scavenging power of enzymatic and non-enzymatic antioxidants of nanoparticles (Kuppusamy et al., 2016). The free radicals formation are controlled by the antioxidant agents, including enzymatic and non-enzymatic substances. Cellular damage including brain damage, atherosclerosis and cancer are caused by free radicals. Reactive oxygen species (ROS) such as superoxide dismutase, hydrogen peroxides and hydrogen radicals contributing to the production of free radicals. Biomolecules such as proteins, glycoprotein, lipids, fatty acids, phenolic, flavonoids and sugars controlled free radical formation (Kuppusamy et al., 2016).

1.14 Diabetes and Silver nanoparticles

Insulin therapy has several negative effects like insulin resistance and may contribute to several other complications, under diabetic state. There is, thus, major need for an efficient and economic therapeutic molecule that is capable of positively and safely controlling diabetic mellitus and its complications while also preventing oxidative stress pathways associated with diabetes mellitus. Discovery of new safer molecules, capable of manipulating those available structures, naturally into Nano size could be advantageous for their greater potential to greatly improve health care (Sahoo et al., 2007).

Wide range of biological applications characterized the gold nanoparticles, because of their unique physical and chemical properties. Gold nanoparticles have been, recently, positively, demonstrated into various biomedical fields, (biosensors, immunoassays, genomics, photo thermolysis of cancer cells, microorganism's detection and control, targeted drug delivery, optical imaging, monitoring of biological cells and tissues by exploiting resonance scattering, or in vivo photoacoustic techniques (Kumar et al., 2011). Great attention has been given to gold compounds, as anti-inflammatory agents through their ability to inhibit expression of NF-kappa B and subsequent inflammatory reactions

(BarathManiKanth et al., 2010). Swarna Bhasma which possess immunomodulatory, antioxidative and restorative activity, used in cerebral ischaemic rats, has revealed their perceptive application in the treatment of ischaemia and cerebral damages (BarathManiKanth et al., 2010).

There is a serious lack of information concerning the impact of nanoparticles on human health and the environment, despite the positive and wide application of nanoparticles. Several bioactivities were performed using metal nanoparticles, especially silver and gold (Pandiarajan et al., 2016).

Silver nanoparticles has opened doors to their wide-spread use, because of their strong antimicrobial property, in bedding, water purification, toothpaste, shampoo, rinse, infant nipples nursing bottles, fabrics, deodorants, filters, kitchen utensils, toys and humidifiers. Metallic silver has been subjected to engineered nanotechnology causing some extraordinary novel morphologies and characteristics. Silver nanoparticles (AgNPs) are groups of silver atoms ranging in size from 1 to 100 nm, in at least one dimension (typically spherical diameter) (Table 1.3). Silver nanoparticles (AgNPs), an emerging Nanomedicine is renowned for its promising therapeutic possibilities (Table 1.3), in health care, due to its significant properties such as biocompatibility, high surface reactivity and strong resistance to oxidation (Morones et al., 2005).

Silver nanoparticles possess inhibitory activity against VPF/VEGF165, that lead to proliferation of endothelial cells, and provide clear evidence over their therapeutic potential in the treatment of diseases like chronic inflammation, pathological neovascularization, rheumatoid arthritis, and neoplastic disorders (Shen et al., 2017). While the small size of nanoparticles makes them so useful in the domain of medicine and industries, it may also present a potential hazard to human health and the environment. Because, silver nanoparticles have demonstrated promising potential medicinal activity to manage inflammatory and autoimmune diseases, their medicinal activity has triggered enormous interest that lead to the investigation of their anti-oxidative and anti-hyperglycemic activity in diabetes (BarathManiKanth et al., 2010).

1.15 Diabetes and herbal remedies

For the treatment and management of type II diabetes, numerous medicinal plants are used by local communities of South Africa. Plants extracts such as crude botanical, are also commonly used in the treatment and control of diabetes (Boaduo et al., 2014). Acarbose has shown a major role in the treatment of non-insulin-dependent diabetes mellitus. The use of herbal remedies for diabetes management is considered an important treatment modality available in South Africa (Boaduo et al., 2014). Medicinal plants, *Cinnamomum cassia* is known to basically contain an insulin-like peptide. They have been widely studied to some extent as antidiabetic agents under either in vitro or ex vivo conditions. It is used in Africa as an astringent, germicide for chronic bronchitis and many other ailments. Several clinical trials using *Cinnamomum cassia* has proven its efficacy and its effectiveness in lowering plasma glucose levels in diabetic patients (Borzoei et al., 2018).

Herbal remedies have attracted huge interest, due to its local availability, lack of side effects associated with the oral hypoglycemic agents; and their lower cost compared to conventional therapeutic agents (Nookabkaew et al., 2006). Medicinal Plants are known to be excellent sources of antidiabetic medicines (Marles and Farnsworth, 1995). Some of the new bioactive drugs isolated from plants continue efficiently to develop antidiabetic activity, during the past few years, compared with the oral hypoglycemic agents used in clinical therapy (Malviya et al., 2010). In the management and treatment of diabetes, many studies have confirmed the benefits of medicinal plants with hypoglycemic effects (Marles and Farnsworth, 1995; Malviya et al., 2010). Complications of diabetes may be delayed by the effects of these plants and correct metabolic abnormalities (Malviya et al., 2010).

Recently, complementary and alternative medicines have triggered attention in their major role for the treatment of various acute and chronic diseases, Aruoma et al. (2006), and previous studies Azu et al. (2010) support the use of plant-based adjuvants for disease management like diabetes, cancers, etc. An estimated 80% of Africans are said to rely on complementary and alternative medicines for

the management of diverse physio-pathological conditions (Milan et al., 2008). For the majority of this group of individuals, consultation with traditional health practitioners (THP) is the first call for health services (Owen-Smith et al., 2007). The high burden of diabetic nephropathy has drawn the attention of several studies designed to accommodate a holistic management viewpoint, involving the use of traditional medicines.

Of the various classes of plants, interest has been focused on medicinal plants with various kinds of pharmacological properties such as anti-inflammatory, antibacterial and antidiabetic properties etc. The *Cinnamomum cassia*, plant has been recognized to possess antidiabetic properties (Marles and Farnsworth, 1995). Coumarin (2H-chrome-2-one) (Figure 1.14), Ravindran et al. (2003), the least complex portion from this class (Table 1.2), as an unadulterated compound or as a constituent of Tonka beans had been utilized as a flavouring specialist in nourishment, mixed drinks and tobacco (Egan et al., 1990).

1.16 Cinnamomum Cassia

Cinnamomum cassia, also known as Chinese cassia or Chinese cinnamon, is an evergreen tree originating from southern China and widely cultivated in southern and eastern Asia (India, Indonesia, Laos, Malaysia, Taiwan, Thailand, and Vietnam). In South Africa, mostly in KwaZulu Natal region, it is used as a spice and for medicinal remedy in various illnesses, such as diabetes. Nowadays, the plant is also found in the Southern Africa countries like Zimbabwe, Namibia, Mozambique, etc. *Cinnamomum cassia* may grow under a wide range of climatic conditions, such as warm and humid climate with a well distributed annual rainfall of around 2000-2500 mm, and average temperatures of about 27°C (Anitha and Hore, 2018). Tropical evergreen rainforests offer better climate conditions to wild cinnamon trees. It grows positively at low altitudes and is usually grown without shade, but being basically a forest tree, light shade is tolerated. It grows very well on various soils in the tropics,

but soil type has a pronounced impact on bark quality. In some countries, fine sandy and lateritic gravelly soils rather than rocky and stony substrates may be best.

These ecological characteristics of both cinnamon and cassia are more or less the same. The species occurs up to 2000 m altitude, on well-drained hillside soils of low fertility and pH 4-6 (Ravindran et al., 2003). All the plants part is aromatic, but only its leaves and bark are exploited commercially. The essential constituent of leaves and bark oil are Cinnamaldehyde. The leaves are opposite, glabrous above, minutely hairy below, three ribbed from about 5 mm above the base and are triplinerved. The trees are coppiced periodically keeping the height to 3 -4 m, the bark produced from higher altitudes has got better quality, with reference to their oil. The immature fruits are often dried and sold in the market as cassia buds.

Cinnamomum cassia is ready for harvesting after two to three years when the plants reach a height of 1.5 to 2 m with three to four shots, and the bark turn in brown in colour. Harvesting can be done twice yearly depending on the season. Two to three crops are taken every year depending on the rainfall. *Cinnamomum cassia* extracts has been shown to have antidiabetic effects in vitro ((Marles and Farnsworth, 1995). It has also, been reported that *Cinnamomum cassia* lowers blood glucose, blood pressure, and serum cholesterol levels and have anti-oxidant and free-radical scavenging properties as well as being hepato-protective (Ranasinghe et al., 2017).

In addition, Ranasinghe et al. (2017) pointed out the following beneficial health effects of *Cinnamomum cassia*: (1) lowering of blood glucose, blood pressure and serum cholesterol, (2) antioxidant and free-radical scavenging properties, (3) inhibition of tau aggregation and filament formation (hallmarks of Alzheimer's disease), (4) anti-secretagogue and anti-gastric ulcers (hepato-protective). Moreover, Hoehn and Stockert (2012) also, demonstrated similar beneficial health effects

of *Cinnamomum cassia*: 1) lowering of blood glucose, blood pressure, and serum cholesterol, 2) antioxidant and free-radical scavenging properties, 3) inhibition of tau aggregation and filament formation (hallmarks of Alzheimer's disease), 4) anti-secretagogue and anti-gastric ulcer, 5) hepatoprotective. Cinnamaldehyde (extracted from *Cinnamomum cassia*) has been shown to have antidiabetic effects in vitro (Lee, 2002).

A meta-analysis by Ranasinghe et al. (2017) and a systematic review by Bandara et al. (2012)) on the effects of *Cinnamomum cassia* extracts on diabetes showed numerous advantageous effects both in-vitro and in-vivo. In-vitro, *Cinnamomum cassia* has demonstrated a potential for diabetes management (Knip et al., 2000). Reducing post-prandial intestinal glucose absorption by (1) contributing in the inhibition of the activity of enzymes involved in carbohydrate metabolism (pancreatic α -amylase and α -glycosidase), (2) Contributing to trigger cellular glucose uptake by membrane translocation of GLUT-4, (3) Activating glucose metabolism and glycogen synthesis, (4) Inhibiting gluconeogenesis by effects on key regulatory enzymes and stimulating insulin release and increase insulin receptor activity. However, this research did not either point out the beneficial impact of *Cinnamomum cassia* extracts on the morphology of diabetic kidneys

Table 1.2: Analysis of the plant *Cinnamomum Cassia*

Contents	Results	Required
Water	11.6%	
Total ash	18.01%	
Acid insoluble ash	4.2%	Max 12.0
Volatile oil	0.3%	Max 7.0
Cumarin	2.04%	MAX 2.0
Microbiology	1.743 MG/kg	Min 1.0
Mculds	60000 CFU/G	Max 100.000
E-Coli	<10 CFU/G	10.00
Staphylococcus aureus	<10 CFU/G	Max 100
Bacillus cereus	1.700 CFU/G	MAX 10.000
Sulphite reducing clostridia	150 CFU/G	MAX 10.00

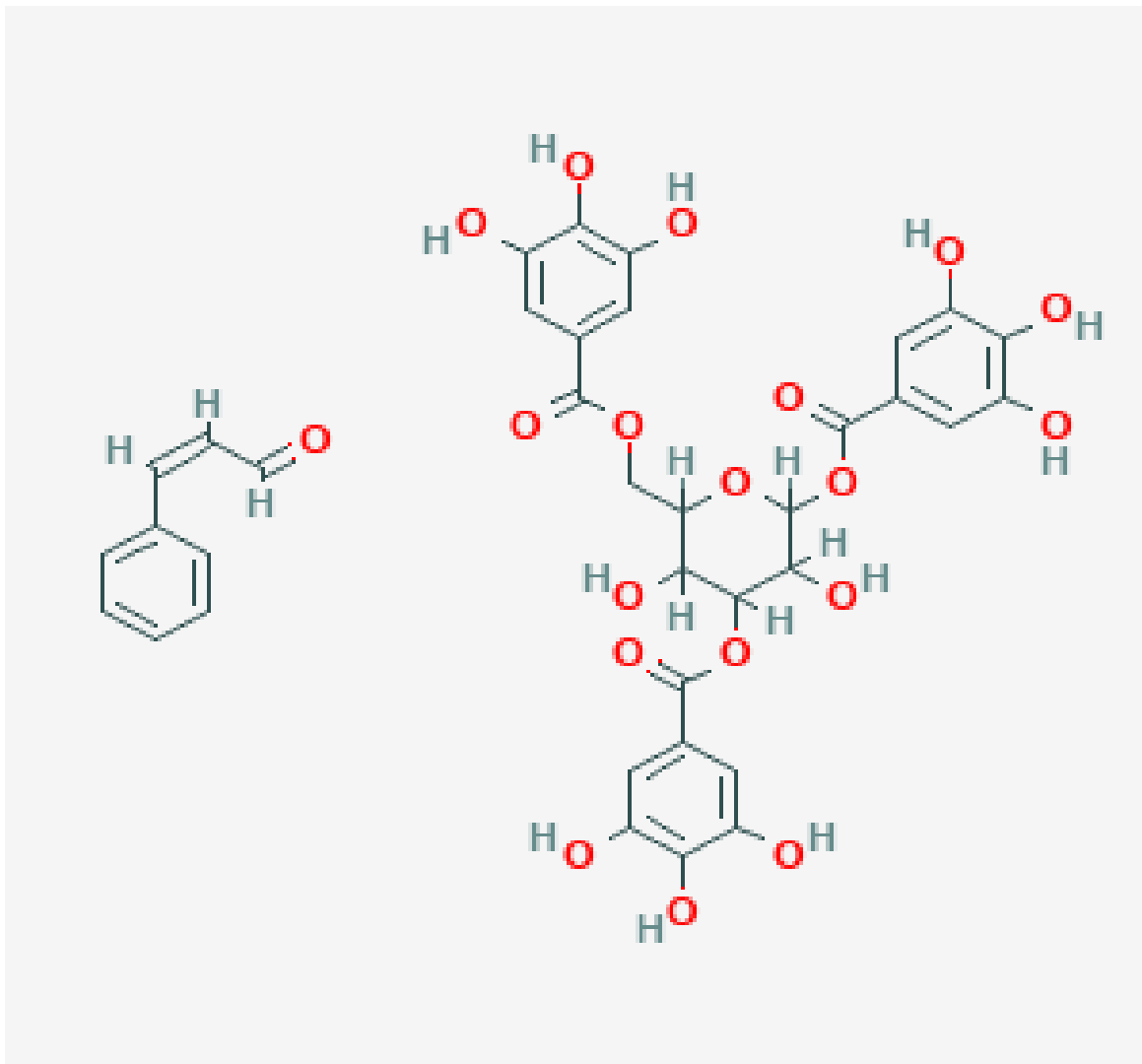


Figure 1.14: Chemical Structure of *Cinnamomum cassia*, powder, adapted from US National Library National center for biotechnology information, 2018.

1.21 Statement of problem

Diabetes affects the size of kidneys as well as the corticomedullary architecture due to medullary fibrosis (Raparia et al., 2013); called nephrosclerosis. Antopolsky et al. (2012) revealed that diabetes causes chronic kidney disease which ultimately leads to renal dysfunction. Diabetes will further cause kidney tissue hyperplasia and hypercellularity, consequently leading to tubular cell destruction, necrosis as well as renal hemorrhage.

Glomerular filtration rate will steadily decline due to the impact of diabetes on the kidneys and systemic blood pressure will be increased as well. Glomerular basement membranes (GBMs) will be thickened, which along with mesangial expansion will lead to capillary wall occlusion and decreased glomerular surface area (Raparia et al., 2013). This in addition to extracellular matrix accumulation, cytoplasmic lipid droplets and presence of hyaline substances further disrupts the endothelial homeostasis and eventually lead to tissue lesion. This lesion is characterized by an imbalance between the oxidant-antioxidant pathways in the endothelial cells giving rise to deposition of free radicals in the renal intracellular milieu. The presence of free radicals and the simultaneous decline of antioxidant defense potentialities observed in diabetic patients, advance the development of diabetic complications (Godin et al., 1988).

The renal tubules in diabetic patients will show changes that are usually associated with glomerular alterations and tubular atrophy. The dilatations of proximal and distal convoluted tubules with an accumulation of lipid droplets in the epithelial cells are the effects of diabetic nephropathy (Raparia et al., 2013). It is a fact that various types of currently used antidiabetic drugs cannot fully control glucose level and often cause side effects and or insufficient response after prolonged use of these drugs. In addition, insulin considered as a major anti-diabetic drug has shown several side effects such as hypoglycaemia and weight abnormalities.

1.18 Justification

The problems associated with diabetes continues to attract the attention of researchers both in experiments and clinical trials due to its heterogeneous nature that is majorly characterized by insulin resistance and pancreatic β -cell dysfunction. With its global prevalence particularly the type 2 diabetes, intensive studies have been carried out into the pharmacodynamics of insulin-mimetic drugs with majority of these work being performed on animal models (Islam and Wilson, 2012).

Investigation of animal models in the pharmacokinetics or pharmacodynamics of diabetic drugs may represent a similar pattern in humans. Therefore, using animal models for diabetic research offers significant insight into the biochemical pathways that may be similar to humans in clinical research. In this study, the rat serves as a suitable model for investigating the kidney based on its similarity in structure and physiologic functions, while being considered as easy to handle and less expensive. More, so while it may not be feasible to carry out the experimental protocol on humans, yet. The associated microvascular complications (diabetic nephropathy) of diabetes necessitate the need for a complementary medicinal plant that can revert or ameliorate the deleterious consequences posed by diabetes.

The search for medicinal plants has continued to grow due to its easy accessibility, relatively low cost, and perceived effectiveness. It is estimated that 80% of the general population in sub-Saharan Africa rely on African traditional medicines to treat various diseases (Hostettmann et al., 2000). *Cinnamomum Cassia* falls into this category and has been widely used for the treatment of various ailments within the region and studies have attributed this to the pharmacological properties it possesses (Albrecht et al., 1995).

1.19 Aims

The aims of this study are:

1. To develop a novel approach in synthesizing silver nanoparticles using *Cinnamomum cassia* extracts for the management of type 2 diabetes in the kidney of experimental rats.
2. To investigate the histomorphological and biochemical effects of *Cinnamomum cassia* extracts nanoparticles on the kidneys of type 2 diabetic rats.

1.20 Specific objectives

- i. To evaluate the impact of *Cinnamomum cassia* extracts (nanoparticle conjugate) on the renal histomorphology of STZ induced type 2 diabetic rats.
- ii. To evaluate and report the biochemical and histopathological effects of *Cinnamomum cassia* and *Cinnamomum cassia* silver nanoparticles on the kidneys.
- iii. To assess any possible renal toxicity of the effects of *Cinnamomum cassia* extracts (nanoparticle conjugate) in STZ-induced type 2 diabetic rats.
- iv. To investigate the ultrastructural changes on renal tissue and mesangial cells of the kidneys of STZ- induced type diabetic rats, treated with *Cinnamomum cassia* extracts (nanoparticle conjugate).
- v. To determine the antioxidant effects of *Cinnamomum cassia* extracts (nanoparticle conjugate) on STZ- induced oxidative stress. To measure the biomarkers of damaged kidneys using the urine and the blood of the experimental rats.

1.21 Research questions

1. Does *Cinnamomum cassia* possess antioxidant properties?
2. Does *Cinnamomum cassia* silver nanoparticles possess antioxidant properties
3. Can the known chronic hyperglycaemia effect of STZ be corrected by Cc and or CcAgNPs?
4. Can the persistent hyperglycaemia on the experimental animals be mitigated by Cc and or CcAgNPs?
5. Can the histopathological and biochemical effects of long-term hyperglycaemia on the kidneys be reversed by Cc or CcAgNPs?
6. Does CcAgNPs mitigate renal clinically impairment in diabetic nephropathy?

1.22 Contribution to knowledge

This study is the first to report on the use of *Cinnamomum cassia* capped into silver nanoparticles in an experimental model for diabetic nephropathy. The study hopes to use qualitative and quantitative techniques that would offer additional interpretive values in renal pathology and morphology.

1.23 Animal management/ Experimental design

Sixty-five (65) healthy adult male Sprague Dawley weighing between 250 g to 270 g were used for this study. Animals were allowed to acclimatize for 7 days before commencement of the experiment. The animals were fed ad libitum and maintained at the Animal House of the Biomedical Resources Unit, University of KwaZulu-Natal (Council, 2010). The selected protocol for the experiment was officially approved by the Animal Ethics Committee (protocol reference number: AREC/74/016D). The experimental rats had unrestricted access to consume food (standard rat pellets) as well as water. Rats were all housed in plastic cages (3 rats/cage) with the dimensions of 30 cm long, 20 cm wide and 13 cm high. Their beds, used in the cages, were made with soft wood shavings, utilized as bedding

in the cages. Experimental Rats were maintained and conditioned under the standardized animal house (temperature: 28~31 °C; light: approximately 12 hr. natural light per day; humidity: 50~55%). The animals were later randomly distributed into five (Carneiro and Programme, 2002) non-diabetic groups (A-E) of six (6) rats per group, and diabetic group (F-J) of five (7) rats per group (Figure 1.15).



Figure 1.15: Sprague - Dawley rats housed in the plastics cages

1.24 Non diabetic group

Group A received 1ml normal saline (Negative control) (Figure 1.16)

Group B received *Cinnamomum cassia* extracts (100 mg/kg).

Group C received *Cinnamomum cassia* extracts (200mg/kg).

Group D received *Cinnamomum cassia* silver nanoparticles (5 mg/kg).

Group E received *Cinnamomum cassia* silver nanoparticles (10 mg/kg).

1.25 Diabetic group

Group F received 1 ml of normal saline (Positive control) (Figure 1.16)

Group G received *Cinnamomum cassia* extracts (100mg/kg).

Group H received *Cinnamomum cassia* extracts (200mg/kg).

Group I received *Cinnamomum cassia* (5 mg/kg).

Group J received *Cinnamomum cassia* (10 mg/kg).

Cinnamomum cassia silver nanoparticles and *Cinnamomum cassia* were dissolved in normal saline. All treatments were administered orally and daily for 56 days using a rat gavage needle (Turner et al., 2012).

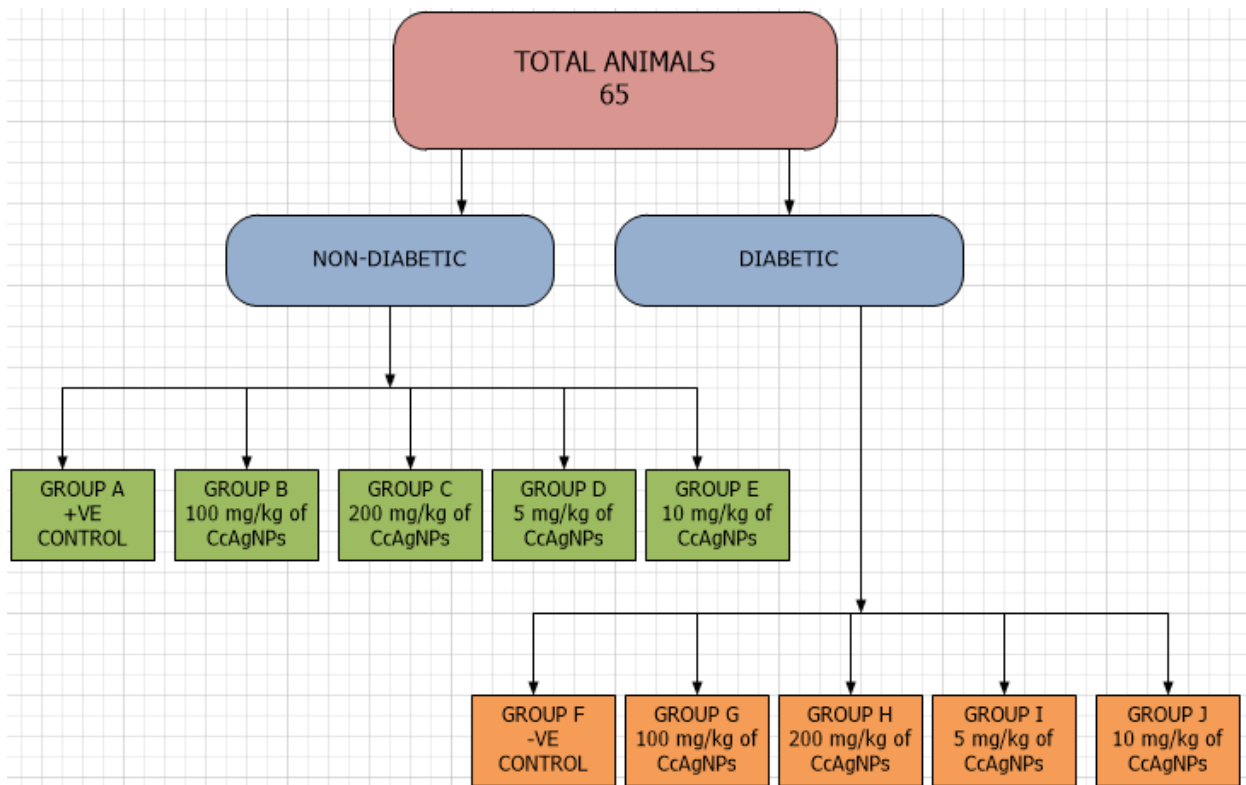


Figure 1.16: Experimental design

1.26 Induction of type 2 diabetes.

Diabetes was induced by firstly intraperitoneal injection of 100 mg/kg of nicotinamide (Sigma Aldrich, South Africa) which was dissolved into normal saline; 15 minutes before administration of Streptozotocin at a dose of 60 mg/kg i.p. Meanwhile, STZ was dissolved into citrate buffer at PH (4.50) immediately before use. The animals were then kept under observation. After 72 Hours the blood glucose of the animals was tested using; Accu-chek Active 50, blood glucose strips (Dis-Chem SA), with blood, collected from the tail vein of the rats. The animals with a fasting blood glucose level > to 9 mmol/l were considered diabetics. In addition, urinary measurements were monitored for urinalysis.

1.27 Body and Kidney Weight

The body weights (BW) of experimental rats were carefully recorded on the first day before treatment (initial) and thereafter on a weekly basis for 56 days, day of sacrifice, which gave the final weight. kidney weight (KW) was measured using an electronic balance (Mettler Toledo; Microsep (Pty) Ltd, Greifensee, Switzerland). Kidneys of each rat were measured individually, and the average value obtained for each of the two measurements was regarded as one observation. The values were expressed in grams (g) for KW.

1.28 Urinalysis

Animals were relocated in different metabolic cages weekly for collection of urine (Figure 1.17). Urinalysis was then performed to detect and measure the level of various substances in the urine, including protein, glucose (sugar), ketones, blood, and other substances. For these tests, we used a thin strip of plastic (dipstick) impregnated with chemicals that react with substances in the urine and quickly change color. They are urine test strip or dipstick test (a basic diagnostic tool used to determine early kidney disease in our experiments rats).



Figure 1.17: Sprague – Dawley rats housed in a metabolic cage.

1.29 Collection of Blood Samples

At the end of the experimental period, all animals were sacrificed (Figure 1.18) by an expert, after inhalation of excess halothane in a gas anaesthetic chamber. Blood samples were then carefully collected by utilizing cardiac puncture into pre-cooled tubes filled with heparin and serum bottles; deposited on ice for 3 hours and thereafter centrifuged in a desktop centrifuge model 90-1 (Jiangsu Zhangji Instruments Co., China) for 15 minutes at 3000 revolutions per minute. Serum was gradually poured into Eppendorf tubes and stored at -80 °C for further analysis.

1.30 Histopathological Examination of Kidneys

Kidneys were carefully removed and weighed following a laparotomy (Figure 1.18). They were examined for gross pathology and immediately fixed in 10% Neutral buffered saline. After 2 days of fixation, the kidneys were processed for histology. Following standard histology procedure, kidneys tissues were exposed to consecutive section at 4 µm intervals using a microtome (Microm HM 315, Germany) and stained with hematoxylin and eosin (H&E). The closed evaluation was performed by histopathologist blinded to the study protocol.

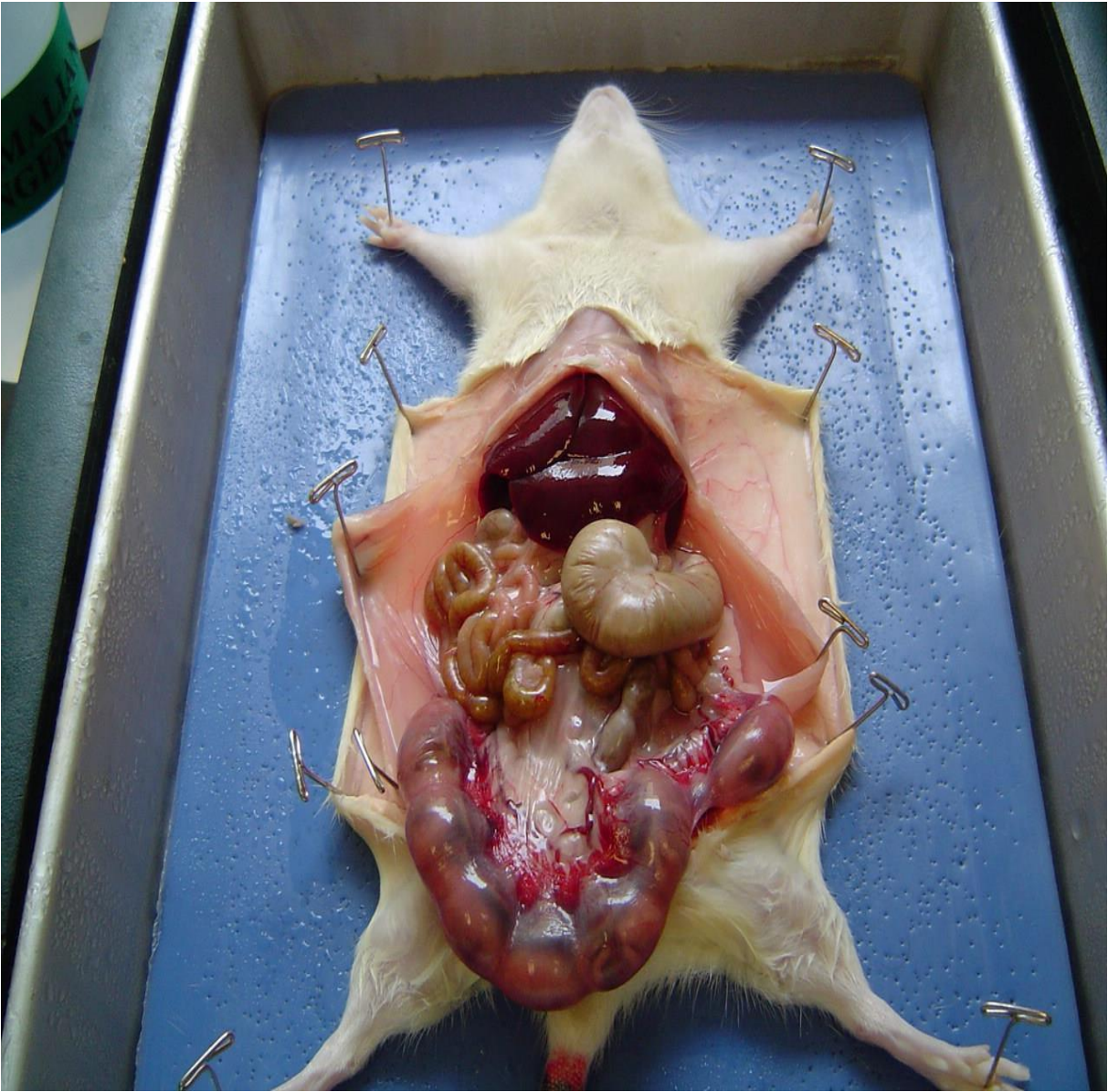


Figure 1.18: Dissected Sprague-Dawley rat on Autopsy table, Adapted from (McLachlan and Patten, 2006).

1.31 Histochemical Evaluation of the Kidneys

In order to perform histochemical analysis, kidneys tissues were carefully stained with Periodic acid Schiff, a technique to assess glycogen and neutral polysaccharides. Examination of the stained tissue sections was done by a histopathologist blinded to the study protocol.

For histochemical analysis, kidney tissue was also stained with Masson's trichrome. This is a three-color staining protocol used in histology for kidney pathologies (e.g. glomerular fibrosis). It is suited for distinguishing cells from surrounding connective tissue staining red keratin and muscle fibers, blue or green collagen and bone, light red or pink cytoplasm, and dark brown to black cell nuclei. It also differentiates between collagen and smooth muscle in tumors, and the increase of collagen in diseases such as cirrhosis. It is a routine stain for kidney biopsies.

1.32 Stereological Analyses of Kidneys

The method was performed using the point-counting strategy in order to calculate the volumes of the glomeruli and tubules. This was done in accordance with the idea formerly described by (Weibel, 1979). We selected four different sections, whereby between two points, we kept a distance of 5 mm within a particular kidney and six fields per section were randomly chosen for analysis.

Under the microscope, fields of view were sampled from the sections before final measurements are sampled from the fields of view. Then random sampling was introduced at each step of the selection process, in the positioning and in the orientation of slices. Whatever quantity is being estimated, slice position was randomized, spread the sample as evenly as possible throughout the whole specimen. Fields of view from tissue sections was sampled using the x- and y-axes of microscope stage micrometers.

Fields were sampled from images captured using Leica SCN 400 (Leica Microsystems GmbH, Wetzlar, Germany) and measured at X 100 magnification using image analyzer Leica (DMLB) and Leica microsystem software. The Volume densities of the structures of the kidneys was determined by randomly superimposing a transparent grid comprising 160 test points per image arranged in a quadratic array (Freitas et al., 2011).

1.33 Transmission electron microscope (TEM)

Transmission electron microscope (TEM) was used to further provide a more detailed morphologic and compositional information on samples (most especially on glomeruli and tubules). This was done after the tissues were fixed overnight at 4 °C in 3% glutaraldehyde in 0.1 M sodium cacodylate buffer (pH 7.4) and transferred to 0.1 M phosphate buffer (pH 7.2). The cells were post-fixed in 1% osmium tetroxide in S-collidine, dehydrated in graded ethanol, transferred to propylene oxide, and embedded in Epon 812. Semi-thin sections (25nm) were stained with 1% methylene blue. The samples were further sectioned into ultrathin slices (75 nm), with glass knife, using ultramicrotome contrasted with uranyl acetate and lead citrate and observed in transmission electron microscope (Bressenot et al., 2009).

1.34 Measurement of kidney tissue Malondialdehyde (MDA) level

Kidney tissue was homogenized in 0.2M sodium phosphate buffer (7.8 pH) and then centrifuged for 15 mins at 15000g. The supernatant was collected and used for the measurement of lipid peroxidation. The procedure was carefully performed according to Chenni et al. (2007) with little modification. This methodology uses the complex formed from the reaction between Malondialdehyde (MDA) and Thiobarbituric acid (TBA). Into an assay mixture containing 200µL of 8.1% sodium dodecyl sulfate (SDS), 750 µL of 20% acetic acid (pH, 3.5), 2mL of 0.25% TBA and 850µL of distilled water, 200µL

of sample of MDA standard series (0, 7.5, 15, 22.5, and 30 μm) was added in a Pyrex screw-capped test tube. The mixture was heated at 95 $^{\circ}\text{C}$ for 60 min in a sand bath, cooled down to room temperature and the absorbance read at 532 nm using spectrophotometer - Synergy HTX multi-mode reader, VACUTECH, USA. Thiobarbituric acid reactive substances (TBARS) concentrations in the samples were extrapolated from the MDA standard curve.

1.35 Measurement of kidney tissue Glutathione Concentration (GSH)

Glutathione concentration was assessed in renal tissue according to methodology modified from (Rotimi et al., 2018). The sample was first precipitated with 10% Trichloroacetic acid (TCA) and then centrifuged at 2000 rpm for 0 min at 25 °C. The reaction mixture contained 100 µL of supernatant, 50 µL of 0.5mM 5, 5'-dithio-bis-2-nitrobenzoic acid (DTNB) and 150 µL of 0.2 M sodium phosphate buffer (pH 7.8). After 15 min incubation at 25 °C, the absorbance was measured at 412 nm using a spectrophotometer (Synergy HTX multi-mode reader, VACUTECH, USA) and GSH concentrations extrapolated from a standard GSH curve.

1.36 Renal Function Analyses

Serum was used for the estimation of blood urea nitrogen (BUN) and serum creatinine (CR-S) using a Beckman Coulter Synchron® system(s) BUN and CR-S assay kit. Beckman Coulter Synchron® system BUN assay kit and Beckman Coulter Synchron® system CR-S assay kit were obtained from Global Viral Laboratory, Durban, South Africa.

1.37 Statistical analysis

Analyses were carried out using one-way analysis of variance, followed by Dunnett's multiple comparison post-hoc tests using Graph pad prism ® statistical software version 5.02. Values were expressed as mean ± standard deviation and all results tested for significance at the 95% confidence level ($p < 0.05$).

Table 1.3: List of manuscript from project

S/no	Reference	Manuscript title	Journal	Status
1	Kouame et al., 2018	Effect of long-term administration of Cinnamomum cassia silver nanoparticles on organs (kidneys and liver) of Sprague-Dawley rats	Turkish Journal of Biology. doi:10.3906/biy-1805-103	Published
2	Kouame et al., 2018	Histologic and biochemical effects of Cinnamomum cassia nanoparticles in kidneys of diabetic Sprague-Dawley rats	Bosnian Journal of Basic Medical Sciences https://www.bjbms.org https://blog.bjbms.org	Published
3	Kouame et al., 2018	Green silver nanoparticles synthesis using Cinnamomum cassia		Under review
4	Kouame et al., 2018	Investigating, the ultrastructural changes using TEM, on renal tissue and mesangial cells of the kidneys of STZ- induced diabetic rats, treated with CcAgNPs.		Under preparation
5	Kouame et al., 2018	Quantitative Morphometric Study of the renal corpuscle of treated with Cc and treated with CcAgNPs in Streptozotocin-Diabetic Rats		Under preparation

References

- ADIGA, U. & MALAWADI, B. N. 2016. *Association of Diabetic Nephropathy and Liver Disorders*.
- AHMAD, S. 2015. Pharmacognostical Phytochemical and Anti Diabetic Studies On *Tephrosia villosa* Pers.
- AHMED D, SHARMA M, MUKERIEE A, RAMTEKE PW, KUMAR V (2013) Improved glycaemic control, pancreas protective and hepatoprotective effect by traditional poly-herbal formulation “Qurs Tabasheer” in streptozotocin induced diabetic rats. *BMC Complement Altern Med* 13:10. doi:10.1186/1472-6882-13-10
- AHMED D, SHARMA M, KUMAR V, BAJAJ HK, VERMA A (2014a) 2 β -hydroxybetulinic acid 3 β -caprylate: an active principle from *Euryale Ferox* Salisb. seeds with antidiabetic, antioxidant, pancreas & hepatoprotective potential in streptozotocin induced diabetic rats. *J Food Sci Technol*. doi:10.1007/s13197-014-1676-0
- AHMED, D., KUMAR, V., VERMA, A., SHUKLA, G. S. & SHARMA, M. J. S. 2015. Antidiabetic, antioxidant, antihyperlipidemic effect of extract of *Euryale ferox* salisb. with enhanced histopathology of pancreas, liver and kidney in streptozotocin induced diabetic rats. 4, 315.
- ALBERTI, G., ZIMMET, P., SHAW, J., BLOOMGARDEN, Z., KAUFMAN, F. & SILINK, M. 2004. Type 2 diabetes in the young: the evolving epidemic: the international diabetes federation consensus workshop. *Diabetes care*, 27, 1798-1811.
- ALBRECHT, C., THERON, E. & KRUGER, P. 1995. Morphological characterisation of the cell-growth inhibitory activity of rooperol and pharmacokinetic aspects of hypoxoside as an oral prodrug for cancer therapy. *South African Medical Journal*, 85.
- AL-SAMAWY, E. R. 2012. Morphological and Histological study of the kidneys on the Albino rats. *Al-Anbar Journal of Veterinary Sciences*, 5, 115-119.
- AMIJI, M. M., VYAS, T. K. & SHAH, L. K. 2009. Role of nanotechnology in HIV/AIDS treatment: potential to overcome the viral reservoir challenge. *Discovery medicine*, 6, 157-162

- AMIRSHAHROKHI, K., DEHPOUR, A., HADJATI, J., SOTOUDEH, M. & GHAZI-KHANSARI, M. 2008. Methadone ameliorates multiple-low-dose streptozotocin-induced type 1 diabetes in mice. *Toxicology and Applied Pharmacology*, 232, 119-124.
- ANITHA, M. & HORE, J. 2018. Production Technology of Some Major and Minor Spice Crops. *Indian Spices*. Springer.
- ANSARI, S. & FARHA ISLAM, M. 2012. Influence of nanotechnology on herbal drugs: A Review. *Journal of advanced pharmaceutical technology & research*, 3, 142.
- ANTOPOLSKY, M., SIMANOVSKY, N., STALNIKOWICZ, R., SALAMEH, S. & HILLER, N. 2012. Renal infarction in the ED: 10-year experience and review of the literature. *The American journal of emergency medicine*, 30, 1055-1060.
- ARUOMA, O. I., SUN, B., FUJII, H., NEERGHEEN, V. S., BAHORUN, T., KANG, K. S. & SUNG, M. K. 2006. Low molecular proanthocyanidin dietary biofactor Oligonol: Its modulation of oxidative stress, bioefficacy, neuroprotection, food application and chemoprevention potentials. *Biofactors*, 27, 245-265.
- ASMAT, U., ABAD, K. & ISMAIL, K. 2016. Diabetes mellitus and oxidative stress—a concise review. *Saudi Pharmaceutical Journal*, 24, 547-553.
- ATLAS, D. 2006. International diabetes federation. *Press Release, Cape Town, South Africa*, 4.
- AWAN, I. Z., HUSSAIN, S. & KHAN, A. Q. 2016. Wondrous Nanotechnology. *Journal of the Chemical Society of Pakistan*, 38.
- AWAZU, K., FUJIMAKI, M., ROCKSTUHL, C., TOMINAGA, J., MURAKAMI, H., OHKI, Y., YOSHIDA, N. & WATANABE, T. 2008. A plasmonic photocatalyst consisting of silver nanoparticles embedded in titanium dioxide. *Journal of the American Chemical Society*, 130, 1676-1680
- AZEVEDO, M. J. 2017. Health in Africa and the Role of International Organizations. *Historical Perspectives on the State of Health and Health Systems in Africa, Volume II*. Springer.
- AZU, O., DURU, F., OSINUBI, A., OREMOSU, A., NORONHA, C., ELESHA, S. & OKANLAWON, A. 2010. Histomorphometric effects of *Kigelia africana* (Bignoniaceae) fruit extract on the testis following short-term treatment with cisplatin in male Sprague–Dawley rats. *Middle East Fertility Society Journal*, 15, 200-208.
- BAILEY, C. J. & DAY, C. 1989. Traditional plant medicines as treatments for diabetes. *Diabetes care*, 12, 553-564.

- BARATHMANIKANTH, S., KALISHWARALAL, K., SRIRAM, M., PANDIAN, S. R. K., YOUN, H.-S., EOM, S. & GURUNATHAN, S. 2010. Anti-oxidant effect of gold nanoparticles restrains hyperglycemic conditions in diabetic mice. *Journal of nanobiotechnology*, 8, 16.
- BECK, J., GREENWOOD, D. A., BLANTON, L., BOLLINGER, S. T., BUTCHER, M. K., CONDON, J. E., CYPRESS, M., FAULKNER, P., FISCHL, A. H. & FRANCIS, T. 2018. 2017 National standards for diabetes self-management education and support. *The Diabetes Educator*, 44, 35-50.
- BISSINGER, R., BHUYAN, A. A. M., QADRI, S. M. & LANG, F. 2018. Oxidative stress, eryptosis and anemia: a pivotal mechanistic nexus in systemic diseases. *The FEBS journal*
- BOADUO, N. K. K., KATERERE, D., ELOFF, J. N. & NAIDOO, V. J. P. B. 2014. Evaluation of six plant species used traditionally in the treatment and control of diabetes mellitus in South Africa using in vitro methods. 52, 756-761.
- BOLZÁN, A. D. & BIANCHI, M. S. 2002. Genotoxicity of streptozotocin. *Mutation Research/Reviews in Mutation Research*, 512, 121-134.
- BORM, P. J., SCHINS, R. P. & ALBRECHT, C. 2004. Inhaled particles and lung cancer, part B: paradigms and risk assessment. *International Journal of Cancer*, 110, 3-14.
- BORZOEI, A., RAFRAF, M., NIROMANESH, S., FARZADI, L., NARIMANI, F., DOOSTAN, F. J. J. O. T. & MEDICINE, C. 2018. Effects of cinnamon supplementation on antioxidant status and serum lipids in women with polycystic ovary syndrome. 8, 128-133.
- BRESSENOT, A., MARCHAL, S., BEZDETNYA, L., GARRIER, J., GUILLEMIN, F., PLÉNAT, F. J. J. O. H. & CYTOCHEMISTRY 2009. Assessment of apoptosis by immunohistochemistry to active caspase-3, active caspase-7, or cleaved PARP in monolayer cells and spheroid and subcutaneous xenografts of human carcinoma. 57, 289-300.
- BROWN, P. K., QURESHI, A. T., MOLL, A. N., HAYES, D. J. & MONROE, W. T. 2013. Silver nanoscale antisense drug delivery system for photoactivated gene silencing. *ACS nano*, 7, 2948-2959.
- CARNEIRO, K. J. P. P. C. B. T. H. L. E. G. O. M. & PROGRAMME, T. U. T. T. E. F.-W. 2002. The need for measurement and testing in nanotechnology.
- CARO, J. F. 1990. Effects of glyburide on carbohydrate metabolism and insulin action in the liver. *The American journal of medicine*, 89, S17-S25.

- CHENNI, A., YAHIA, D. A., BOUKORTT, F., PROST, J., LACAILLE-DUBOIS, M. & BOUCHENAK, M. 2007. Effect of aqueous extract of *Ajuga iva* supplementation on plasma lipid profile and tissue antioxidant status in rats fed a high-cholesterol diet. *Journal of ethnopharmacology*, 109, 207-213.
- CHEN, X. & SCHLUESENER, H. 2008. Nanosilver: a nanoparticle in medical application. *Toxicology letters*, 176, 1-12.
- CHEN, X. & SCHLUESENER, H. 2008. Nanosilver: a nanoparticle in medical application. *Toxicology letters*, 176, 1-12
- CHOUKEM, S., FABREGUETTES, C., AKWO, E., PORCHER, R., NGUEWA, J., BOUCHE, C., KAZE, F., KENGNE, A., VEXIAU, P., MBANYA, J. J. D. & METABOLISM 2014. Influence of migration on characteristics of type 2 diabetes in sub-Saharan Africans. 40, 56-60.
- CNOP, M., WELSH, N., JONAS, J.-C., JÖRNS, A., LENZEN, S. & EIZIRIK, D. L. 2005. Mechanisms of pancreatic β -cell death in type 1 and type 2 diabetes: many differences, few similarities. *Diabetes*, 54, S97-S107.
- CONNOR, E. E., MWAMUKA, J., GOLE, A., MURPHY, C. J. & WYATT, M. D. 2005. Gold nanoparticles are taken up by human cells but do not cause acute cytotoxicity. *Small*, 1, 325-327.
- COUNCIL, N. R. 2010. *Guide for the care and use of laboratory animals*, National Academies Press
- CROOKS, R. M., ZHAO, M., SUN, L., CHECHIK, V. & YEUNG, L. K. 2001. Dendrimer-encapsulated metal nanoparticles: synthesis, characterization, and applications to catalysis. *Accounts of chemical research*, 34, 181-190.
- CUBERO ALPÍZAR, C. & ROJAS VALENCIANO, L. P. 2017. Comportamiento de la diabetes mellitus en Costa Rica. *Horizonte sanitario*, 16, 211-220.
- DAISY, P. & SAIPRIYA, K. 2012. Biochemical analysis of *Cassia fistula* aqueous extract and phytochemically synthesized gold nanoparticles as hypoglycemic treatment for diabetes mellitus. *International journal of nanomedicine*, 7, 1189.
- DAY, C. 2005. Are herbal remedies of use in diabetes? *Diabetic Medicine*, 22, 10-12.
- DEFRONZO, R. A., BARZILAI, N. & SIMONSON, D. C. 1991. Mechanism of metformin action in obese and lean noninsulin-dependent diabetic subjects. *The Journal of Clinical Endocrinology & Metabolism*, 73, 1294-1301.

- DESAI, N. 2012. Challenges in development of nanoparticle-based therapeutics. *The AAPS journal*, 14, 282-295.
- DETAILLE, D., GUIGAS, B., LEVERVE, X., WIERNSPERGER, N. & DEVOS, P. 2002. Obligatory role of membrane events in the regulatory effect of metformin on the respiratory chain function. *Biochemical pharmacology*, 63, 1259-1272.
- DONG, X.-Y., GAO, Z.-W., YANG, K.-F., ZHANG, W.-Q. & XU, L.-W. 2015. Nanosilver as a new generation of silver catalysts in organic transformations for efficient synthesis of fine chemicals. *Catalysis Science & Technology*, 5, 2554-2574.
- DORIA, G., CONDE, J., VEIGAS, B., GIESTAS, L., ALMEIDA, C., ASSUNÇÃO, M., ROSA, J. & BAPTISTA, P. V. 2012. Noble metal nanoparticles for biosensing applications. *Sensors*, 12, 1657-1687.
- DUNN, C. J. & PETERS, D. H. 1995. Metformin. *Drugs*, 49, 721-749
- EGAN, D., O'KENNEDY, R., MORAN, E., COX, D., PROSSER, E. & THORNES, R. D. 1990. The pharmacology, metabolism, analysis, and applications of coumarin and coumarin-related compounds. *Drug metabolism reviews*, 22, 503-529.
- EL-NOUR, K. M. A., EFTAIHA, A. A., AL-WARTHAN, A. & AMMAR, R. A. 2010. Synthesis and applications of silver nanoparticles. *Arabian journal of chemistry*, 3, 135-140.
- FATTAH H, LAYTON A, VALLON V. How do kidneys Adapt to a deficit or loss in Nephron Number? *Physiology (Bethesda)*. 2019 May 01; 34 (3): 189-197
- FEIG, D. I., KANG, D.-H. & JOHNSON, R. J. J. N. E. J. O. M. 2008. Uric acid and cardiovascular risk. 359, 1811-1821.
- FREITAS, K. M. D., COSTA, K. L., CAMPOS, P. K. A., MELO, F. C. S. A. D., PAULA, T. A. R. D. & MATTA, S. L. P. D. 2011. Effects of catuaba cristal® on the testis of wistar rats. *Brazilian Archives of Biology and Technology*, 54, 901-906.
- FRÖDE, T. & MEDEIROS, Y. 2008. Animal models to test drugs with potential antidiabetic activity. *Journal of Ethnopharmacology*, 115, 173-183.
- GHASEMI PIRBALOUTI, A., FATAHI-VANANI, M., CRAKER, L. & SHIRMARDI, H. 2014. Chemical composition and bioactivity of essential oils of *Hypericum helianthemoides*, *Hypericum perforatum* and *Hypericum scabrum*. *Pharmaceutical biology*, 52, 175-181.

- GIACCO, F. & BROWNLEE, M. 2010. Oxidative stress and diabetic complications. *Circulation research*, 107, 1058-1070.
- GODIN, D. V., WOHAIEB, S. A., GARNETT, M. E. & GOUMENIOUK, A. 1988. Antioxidant enzyme alterations in experimental and clinical diabetes. *Molecular and cellular biochemistry*, 84, 223-231.
- GOLDNER, M. & GOMORI, G. 1943. Alloxan diabetes in the dog. *Endocrinology*, 33, 297-308.
- GOODWILL, A. G. & FRISBEE, J. C. J. V. P. 2012. Oxidant stress and skeletal muscle microvasculopathy in the metabolic syndrome. 57, 150-159.
- GOYAL, S. N., REDDY, N. M., PATIL, K. R., NAKHATE, K. T., OJHA, S., PATIL, C. R. & AGRAWAL, Y. O. 2016. Challenges and issues with streptozotocin-induced diabetes—A clinically relevant animal model to understand the diabetes pathogenesis and evaluate therapeutics. *Chemico-biological interactions*, 244, 49-63.
- GRISOUARD, J., TIMPER, K., RADIMERSKI, T. M., FREY, D. M., PETERLI, R., KOLA, B., KORBONITS, M., HERRMANN, P., KRÄHENBÜHL, S. & ZULEWSKI, H. 2010. Mechanisms of metformin action on glucose transport and metabolism in human adipocytes. *Biochemical pharmacology*, 80, 1736-1745.
- GROSS, J. L., DE AZEVEDO, M. J., SILVEIRO, S. P., CANANI, L. H., CARAMORI, M. L. & ZELMANOVITZ, T. 2005. Diabetic nephropathy: diagnosis, prevention, and treatment. *Diabetes care*, 28, 164-176.
- GUARIGUATA, L., LINNENKAMP, U., BEAGLEY, J., WHITING, D. & CHO, N. 2014. Global estimates of the prevalence of hyperglycaemia in pregnancy. *Diabetes research and clinical practice*, 103, 176-185.
- HALL, V., THOMSEN, R. W., HENRIKSEN, O. & LOHSE, N. 2011. Diabetes in Sub Saharan Africa 1999-2011: epidemiology and public health implications. A systematic review. *BMC public health*, 11, 564.
- HASSAN, Z., AHMAD, M. A. A. M., NAIDU, S. R., KUMAR, G. & UMACHIGI, S. P. 2008. Hypoglycaemic effects of aqueous extract of *Gynura procumbens*. *Pharmacologyonline*, 1, 30-50.
- HIMMELFARB, J. & SAYEGH, M. H. 2010. *Chronic Kidney Disease, Dialysis, and Transplantation E-Book: A Companion to Brenner and Rector's The Kidney*, Elsevier Health Sciences.

- HOME, P., HADDAD, J., LATIF, Z. A., SOEWONDO, P., BENABBAS, Y., LITWAK, L., GULER, S., CHEN, J.-W. & ZILOV, A. 2013. Comparison of national/regional diabetes guidelines for the management of blood glucose control in non-western countries. *Diabetes Therapy*, 4, 91-102.
- HOSTETTMANN, K., MARSTON, A., NDJOKO, K. & WOLFENDER, J.-L. 2000. The potential of African plants as a source of drugs. *Current Organic Chemistry*, 4, 973-1010.
- HOWLETT, H. C. & BAILEY, C. J. 1999. A risk-benefit assessment of metformin in type 2 diabetes mellitus. *Drug safety*, 20, 489-503.
- HU, Y., CHEN, Y., DING, L., HE, X., TAKAHASHI, Y., GAO, Y., SHEN, W., CHENG, R., CHEN, Q. & QI, X. 2013. Pathogenic role of diabetes-induced PPAR- α down-regulation in microvascular dysfunction. *Proceedings of the National Academy of Sciences*, 201307211.
- INZUCCHI, S. E., BERGENSTAL, R. M., BUSE, J. B., DIAMANT, M., FERRANNINI, E., NAUCK, M., PETERS, A. L., TSAPAS, A., WENDER, R. & MATTHEWS, D. R. 2012. Management of hyperglycaemia in type 2 diabetes: a patient-centered approach. Position statement of the American Diabetes Association (ADA) and the European Association for the Study of Diabetes (EASD). *Diabetologia*, 55, 1577-1596.
- IRSHAD, M. & CHAUDHURI, P. 2002. Oxidant-antioxidant system: role and significance in human body.
- ISLAM, M. S. & WILSON, R. D. 2012. Experimentally induced rodent models of type 2 diabetes. *Animal Models in Diabetes Research*. Springer.
- JACOBSEN, P., ROSSING, K., TARNOW, L., ROSSING, P., MALLET, C., POIRIER, O., CAMBIEN, F. & PARVING, H.-H. 1999. Progression of diabetic nephropathy in normotensive type 1 diabetic patients. *Kidney International*, 56, S101-S105.
- JAMISON, R. L. & GEHRIG JR, J. J. J. H. O. P., RENAL PHYSIOLOGY. BETHESDA, MD: AM PHYSIOL SOC 1992. Urinary concentration and dilution: physiology. 1219-1279.
- JONES, P. M. & PERSAUD, S. J. 2017. 6 Islet Function and Insulin Secretion. *Textbook of Diabetes*, 87-102.
- KENDALL, D. M., CUDDIHY, R. M. & BERGENSTAL, R. M. 2009. Clinical application of incretin-based therapy: therapeutic potential, patient selection and clinical use. *The American journal of medicine*, 122, S37-S50.

- KARIMI, M., ESLAMI, M., SAHANDI-ZANGABAD, P., MIRAB, F., FARAJISAFILOO, N., SHAFAEI, Z., GHOSH, D., BOZORGOMID, M., DASHKHANEH, F. & HAMBLIN, M. R. 2016. pH-Sensitive stimulus-responsive nanocarriers for targeted delivery of therapeutic agents. *Wiley Interdisciplinary Reviews: Nanomedicine and Nanobiotechnology*, 8, 696-716.
- KNIP, M., DOUEK, I., MOORE, W., GILLMOR, H., MCLEAN, A., BINGLEY, P., GALE, E. & GROUP, E. 2000. Safety of high-dose nicotinamide: a review. *Diabetologia*, 43, 1337-1345.
- KONRAD, R. J., MIKOLAENKO, I., TOLAR, J. F., KAN, L. & KUDLOW, J. E. 2001. The potential mechanism of the diabetogenic action of streptozotocin: inhibition of pancreatic β -cell O-GlcNAc-selective N-acetyl- β -D-glucosaminidase. *Biochemical Journal*, 356, 31-41.
- KRENTZ, A. J. & BAILEY, C. J. 2005. Oral antidiabetic agents. *Drugs*, 65, 385-411.
- KUMAR, K. N., KATKURI, S. & RAMYACHARITHA, I. 2018. A study to assess prevalence of diabetes mellitus and its associated risk factors among adult residents of rural Khammam. *International Journal Of Community Medicine And Public Health*, 5, 1360-1365.
- KUPPUSAMY, P., YUSOFF, M. M., MANIAM, G. P. & GOVINDAN, N. 2016. Biosynthesis of metallic nanoparticles using plant derivatives and their new avenues in pharmacological applications—An updated report. *Saudi Pharmaceutical Journal*, 24, 473-484.
- LAKE, B. 1999. Coumarin metabolism, toxicity and carcinogenicity: relevance for human risk assessment. *Food and Chemical Toxicology*, 37, 423-453.
- LANGER, O., CONWAY, D. L., BERKUS, M. D., XENAKIS, E. M.-J. & GONZALES, O. 2000. A comparison of glyburide and insulin in women with gestational diabetes mellitus. *New England Journal of Medicine*, 343, 1134-1138.
- LEE, H.-S. 2002. Inhibitory activity of Cinnamomum cassia bark-derived component against rat lens aldose reductase. *J Pharm Pharm Sci*, 5, 226-230.
- LEE, W. M. 1995. Drug-induced hepatotoxicity. *New England Journal of Medicine*, 333, 1118-1127.
- LEMLEY, K. V., ABDULLAH, I., MYERS, B. D., MEYER, T. W., BLOUCH, K., SMITH, W. E., BENNETT, P. H. & NELSON, R. G. 2000. Evolution of incipient nephropathy in type 2 diabetes mellitus. *Kidney international*, 58, 1228-1237.
- LEVERVE, X., GUIGAS, B., DETAILLE, D., BATANDIER, C., KOCEIR, E., CHAUVIN, C., FONTAINE, E. & WIERNSPERGER, N. 2003. Mitochondrial metabolism and type-2 diabetes: a specific target of metformin. *Diabetes & metabolism*, 29, 6S88-6S94

- LEVEY, A. S., BOSCH, J. P., LEWIS, J. B., GREENE, T., ROGERS, N. & ROTH, D. 1999. A more accurate method to estimate glomerular filtration rate from serum creatinine: a new prediction equation. *Annals of internal medicine*, 130, 461-470.
- LEVITT, N. S., STEYN, K., DAVE, J. & BRADSHAW, D. 2011. Chronic noncommunicable diseases and HIV-AIDS on a collision course: relevance for health care delivery, particularly in low-resource settings—insights from South Africa—. *The American journal of clinical nutrition*, 94, 1690S-1696S.
- LONGNECKER, D. S. 2014. Anatomy and Histology of the Pancreas. *Pancreapedia: The Exocrine Pancreas Knowledge Base*.
- MAGISTRELLI, A. M. 2010. Effects of ground cinnamon on postprandial blood glucose levels between obese and normal weight individuals.
- MALVIYA, N., JAIN, S. & MALVIYA, S. 2010. Antidiabetic potential of medicinal plants. *Acta Pol Pharm*, 67, 113-118.
- MANIGRASSO, M. B. & MARIC-BILKAN, C. 2013. Peptides, sex, diabetes, and the kidney. *Handbook of Biologically Active Peptides (Second Edition)*. Elsevier.
- MARLES, R. J. & FARNSWORTH, N. R. 1995. Antidiabetic plants and their active constituents. *Phytomedicine*, 2, 137-189.
- MARTONE, P. T., BOLLER, M., BURGERT, I., DUMAIS, J., EDWARDS, J., MACH, K., ROWE, N., RUEGGERBERG, M., SEIDEL, R. & SPECK, T. 2010. Mechanics without muscle: biomechanical inspiration from the plant world. *Integrative and comparative biology*, 50, 888-907.
- MASIELLO, P. 2006. Animal models of type 2 diabetes with reduced pancreatic β -cell mass. *The international journal of biochemistry & cell biology*, 38, 873-893.
- MATOUGH, F. A., BUDIN, S. B., HAMID, Z. A., ALWAHAIBI, N. & MOHAMED, J. 2012. The role of oxidative stress and antioxidants in diabetic complications. *Sultan Qaboos University Medical Journal*, 12, 5.
- MBANYA, J. C. N., MOTALA, A. A., SOBNGWI, E., ASSAH, F. K. & ENORU, S. T. J. T. L. 2010. Diabetes in sub-saharan africa. 375, 2254-2266.
- MCFARLANE, P., GILBERT, R. E., MACCALLUM, L. & SENIOR, P. 2013. Chronic kidney disease in diabetes. *Canadian journal of diabetes*, 37, S129-S136.
- MCGUINNES, O. P. & CHERRINGTON, A. D. 1990. Effect of glyburide on hepatic glucose metabolism. *The American journal of medicine*, 89, S26-S37.

- MIESZAWSKA, A. J., MULDER, W. J., FAYAD, Z. A. & CORMODE, D. P. 2013. Multifunctional gold nanoparticles for diagnosis and therapy of disease. *Molecular pharmaceuticals*, 10, 831-847.
- MILAN, F. B., ARNSTEN, J. H., KLEIN, R. S., SCHOENBAUM, E. E., MOSKALEVA, G., BUONO, D. & WEBBER, M. P. 2008. Use of complementary and alternative medicine in inner-city persons with or at risk for HIV infection. *AIDS patient care and STDs*, 22, 811-816.
- MOHAMED, A. A. MORPHOLOGICAL AND HISTOLOGICAL STUDY OF THE NORMAL KIDNEYS OF THE HOUSE MICE.2019.
- MORONES, J. R., ELECHIGUERRA, J. L., CAMACHO, A., HOLT, K., KOURI, J. B., RAMÍREZ, J. T. & YACAMAN, M. J. 2005. The bactericidal effect of silver nanoparticles. *Nanotechnology*, 16, 2346.
- MURTHY, S. K. 2007. Nanoparticles in modern medicine: state of the art and future challenges. *International journal of nanomedicine*, 2, 129.
- MURAYAMA, Y. & SAKAI, F. 1975. Effects of fasting on the Henle's loop function of rat kidney. *The Japanese Journal of Pharmacology*, 25, 475-477
- MUSBAH, M. & FURMAN, B. 1980. In vitro metabolic effects of gliclazide and glibenclamide in the rat. *Journal of Pharmacy and Pharmacology*, 32, 550-553.
- MUTHURI, S. K., OTI, S. O., LILFORD, R. J. & OYEBODE, O. 2016. Salt reduction interventions in sub-Saharan Africa: a systematic review. *PloS one*, 11, e0149680
- NAKAMURA, T., TERAJIMA, T., OGATA, T., UENO, K., HASHIMOTO, N., ONO, K. & YANO, S. 2006. Establishment and pathophysiological characterization of type 2 diabetic mouse model produced by streptozotocin and nicotinamide. *Biological and Pharmaceutical Bulletin*, 29, 1167-1174.
- NATH, K. A. J. A. J. O. K. D. 1992. Tubulointerstitial changes as a major determinant in the progression of renal damage. 20, 1-17.
- NIGATU, T., OLDENBURG, B., ELLIOTT, J., SETSWE, G. & WOLDEGIORGIS, M. A. 2013. The incidence of cardiovascular disease, cancer and type 2 diabetes comorbidities in HIV infection: A systematic review. *Journal of Nursing Education and Practice*, 3, 58.
- NOWACK, B. & BUCHELI, T. D. J. E. P. 2007. Occurrence, behavior and effects of nanoparticles in the environment. 150, 5-22.

- OGBERA, A. O. & KUKU, S. F. 2012. Insulin use, prescription patterns, regimens and costs.-a narrative from a developing country. *Diabetology & metabolic syndrome*, 4, 50.
- OLUBOMEHIN, O. 2014. *ANTI-DIABETIC AND ANTI-OXIDANT EVALUATION OF ANTHOCLEISTA DJALONENSIS A. CHEV AND ANTHOCLEISTA VOGELII PLANCH.*
- ORGANIZATION, W. H. 1999. Definition, diagnosis and classification of diabetes mellitus and its complications: report of a WHO consultation. Part 1, Diagnosis and classification of diabetes mellitus. Geneva: World health organization.
- ORGANIZATION, W. H. 2016. *Global report on diabetes*, World Health Organization.
- OWEN-SMITH, A., DICLEMENTE, R. & WINGOOD, G. 2007. Complementary and alternative medicine use decreases adherence to HAART in HIV-positive women. *AIDS care*, 19, 589-593.
- PANDIARAJAN, J., BALAJI, S., MAHENDRAN, S., PONMANICKAM, P. & KRISHNAN, M. 2016. Synthesis and toxicity of silver nanoparticles. *Nanoscience in Food and Agriculture 3*. Springer.
- PANTIC, I. 2014. APPLICATION OF SILVER NANOPARTICLES IN EXPERIMENTAL PHYSIOLOGY AND CLINICAL MEDICINE: CURRENT STATUS AND FUTURE PROSPECTS. *Reviews on Advanced Materials Science*, 37.
- PANYAM, J. & LABHASETWAR, V. 2003. Biodegradable nanoparticles for drug and gene delivery to cells and tissue. *Advanced drug delivery reviews*, 55, 329-347.
- PASTAKIA, S. D., PEKNY, C. R., MANYARA, S. M. & FISCHER, L. 2017. Diabetes in sub-Saharan Africa—from policy to practice to progress: targeting the existing gaps for future care for diabetes. *Diabetes, metabolic syndrome and obesity: targets and therapy*, 10, 247.
- PEER, N., KENGNE, A.-P., MOTALA, A. A. & MBANYA, J. C. 2014. Diabetes in the Africa Region: an update. *Diabetes research and clinical practice*, 103, 197-205.
- PERKINS, B. A., FICOCIELLO, L. H., SILVA, K. H., FINKELSTEIN, D. M., WARRAM, J. H. & KROLEWSKI, A. S. J. N. E. J. O. M. 2003. Regression of microalbuminuria in type 1 diabetes. 348, 2285-2293.
- PHOGAT, N., ALI KHAN, S., SHANKAR, S., ANSARY, A. A. & UDDIN, I. 2016. Fate of inorganic nanoparticles in agriculture. *Adv. Mater. Lett*, 7, 3-12.

- PITKÄNEN OM, MARTIN JM, HALLMAN M, ÅKERBLUM HK, SARIOLA H, ANDERSSON SM (1992) Free radical activity during development of insulin-dependent diabetes mellitus in the rat. *Life Sci* 50(5):335–339
- PORTE, D., BASKIN, D. G. & SCHWARTZ, M. W. 2005. Insulin signaling in the central nervous system: a critical role in metabolic homeostasis and disease from *C. elegans* to humans. *Diabetes*, 54, 1264-1276.
- PRATO, S. D., MARCHETTO, S., PIPITONE, A., ZANON, M., DE KREUTZENBERG, S. V. & TIENGO, A. 1995. Metformin and free fatty acid metabolism. *Diabetes/metabolism reviews*, 11, S33-S41.
- PUOANE, T., STEYN, K., BRADSHAW, D., LAUBSCHER, R., FOURIE, J., LAMBERT, V. & MBANANGA, N. 2002. Obesity in South Africa: the South African demographic and health survey. *Obesity research*, 10, 1038-1048
- RAGHAVENDRA, R., ARUNACHALAM, K., ANNAMALAI, S. K. & AARRTHY, M. J. M. 2014. Diagnostics and therapeutic application of gold nanoparticles. 2, 4.
- RANASINGHE, P., JAYAWARDENA, R., PREMAKUMARA, G., KATULANDA, P., CONSTANTINE, G. & GALAPPATHTHY, P. 2017. Evaluation of pharmacodynamic properties and safety of *Cinnamomum zeylanicum* (Ceylon cinnamon) in health adults: study protocol for a phase I clinical trial. *MOJ Bioequivalence Bioavailability*, 3, 28.
- RANASINGHE, P., PIGERA, S., PREMAKUMARA, G. S., GALAPPATHTHY, P., CONSTANTINE, G. R. & KATULANDA, P. 2013. Medicinal properties of ‘true’ cinnamon (*Cinnamomum zeylanicum*): a systematic review. *BMC complementary and alternative medicine*, 13, 275.
- RAPARIA, K., USMAN, I. & KANWAR, Y. S. 2013. Renal morphologic lesions reminiscent of diabetic nephropathy. *Archives of pathology & laboratory medicine*, 137, 351-359.
- RAVINDRAN, P., NIRMAL-BABU, K. & SHYLAJA, M. 2003. *Cinnamon and cassia: the genus Cinnamomum*, CRC press.
- Rawi S, Abdel Moneim A, Ahmed OM (1998) Studies on the effect of garlic oil and glibenclamide on alloxan diabetic rats. *Egypt J Zool* 30:211–228
- Rerup C.C. (1970) Drugs producing diabetes through damage of the insulin secreting cells. *Pharmacol Rev*, Vol 22, pp. 485-518.

- REUTER, T. Y. 2007. Diet-induced models for obesity and type 2 diabetes. *Drug Discovery Today: Disease Models*, 4, 3-8.
- RIEHMANN, K., SCHNEIDER, S. W., LUGER, T. A., GODIN, B., FERRARI, M. & FUCHS, H. 2009. Nanomedicine—challenge and perspectives. *Angewandte Chemie International Edition*, 48, 872-897.
- ROESSNER, C., PAASCH, U., KRATZSCH, J., GLANDER, H.-J. & GRUNEWALD, S. J. R. B. O. 2012. Sperm apoptosis signalling in diabetic men. 25, 292-299.
- ROTIMI, O. A., ROTIMI, S. O., OLUWAFEMI, F., ADEMUYIWA, O. & BALOGUN, E. A. J. T. R. 2018. Oxidative stress in extrahepatic tissues of rats co-exposed to aflatoxin B1 and low protein diet. 34, 211.
- SAKAI, F. & KRIZ, W. 1987. The structural relationship between mesangial cells and basement membrane of the renal glomerulus. *Anatomy and embryology*, 176, 373-386
- SAHOO, S., PARVEEN, S. & PANDA, J. 2007. The present and future of nanotechnology in human health care. *Nanomedicine: Nanotechnology, Biology and Medicine*, 3, 20-31.
- SETTER, S. M., ILTZ, J. L., THAMS, J. & CAMPBELL, R. K. 2003. Metformin hydrochloride in the treatment of type 2 diabetes mellitus: a clinical review with a focus on dual therapy. *Clinical therapeutics*, 25, 2991-3026.
- SEURING, T., ARCHANGELIDI, O. & SUHRCKE, M. J. P. 2015. The economic costs of type 2 diabetes: a global systematic review. 33, 811-831.
- SHAH, M., FAWCETT, D., SHARMA, S., TRIPATHY, S. K. & POINERN, G. E. J. 2015. Green synthesis of metallic nanoparticles via biological entities. *Materials*, 8, 7278-7308.
- SHAH, L. K. & AMIJI, M. M. J. P. R. 2006. Intracellular delivery of saquinavir in biodegradable polymeric nanoparticles for HIV/AIDS. 23, 2638-2645.
- SHAW, J. E., SICREE, R. A. & ZIMMET, P. Z. 2010. Global estimates of the prevalence of diabetes for 2010 and 2030. *Diabetes research and clinical practice*, 87, 4-14.
- SHEN, X., LI, T., CHEN, Z., GENG, Y., XIE, X., LI, S., YANG, H., WU, C. & LIU, Y. 2017. Luminescent/magnetic PLGA-based hybrid nanocomposites: a smart nanocarrier system for targeted codelivery and dual-modality imaging in cancer theranostics. *International journal of nanomedicine*, 12, 4299

- SHIREY, K., MANYARA, S. M., ATWOLI, L., TOMLIN, R., GAKINYA, B., CHENG, S., KAMANO, J., LAKTABAI, J. & PASTAKIA, S. 2015. Symptoms of depression among patients attending a diabetes care clinic in rural western Kenya. *Journal of clinical & translational endocrinology*, 2, 51-54.
- SHIRWAIKAR, A., RAJENDRAN, K. & BARIK, R. 2006. Effect of aqueous bark extract of *Garuga pinnata* Roxb. in streptozotocin-nicotinamide induced type-II diabetes mellitus. *Journal of ethnopharmacology*, 107, 285-290.
- SICREE, R., SHAW, J., ZIMMET, P. & HEART, B. 2010. The global burden. *Diabetes and impaired glucose tolerance Baker IDI Heart and Diabetes Institute*.
- SKORECKI, K., CHERTOW, G. M., MARSDEN, P. A., TAAL, M. W., ALAN, S. & LUYCKX, V. 2015. *Brenner and Rector's The Kidney E-Book*, Elsevier Health Sciences.
- SOBNGWI, E., NDOUR-MBAYE, M., BOATENG, K. A., RAMAIYA, K. L., NJENGA, E. W., DIOP, S. N., MBANYA, J.-C., OHWOVORIOLE, A. E. J. D. R. & PRACTICE, C. 2012. Type 2 diabetes control and complications in specialised diabetes care centres of six sub-Saharan African countries: the Diabcare Africa study. 95, 30-36
- SRINIVASAN, K. & RAMARAO, P. 2007. Animal model in type 2 diabetes research: An overview. *Indian Journal of Medical Research*, 125, 451.
- SUBRAMONIAM, A. 2016. *Plants with anti-diabetes mellitus properties*, CRC Press.
- SUCHY-DICEY, A. M., LAHA, T., HOOFNAGLE, A., NEWITT, R., SIRICH, T. L., MEYER, T. W., THUMMEL, K. E., YANEZ, N. D., HIMMELFARB, J. & WEISS, N. S. 2016. Tubular secretion in CKD. *Journal of the American Society of Nephrology*, 27, 2148-2155
- SUZANNE, M. 2012. Therapeutic targets of brain insulin resistance in sporadic Alzheimer's disease. *Frontiers in bioscience (Elite edition)*, 4, 1582.
- SZKUDELSKI, T. 2001. The mechanism of alloxan and streptozotocin action in B cells of the rat pancreas. *Physiological research*, 50, 537-546.
- TEDONG, L., DIMO, T., DZEUFIET, P. D. D., ASONGALEM, A. E., SOKENG, D. S., CALLARD, P., FLEJOU, J. F. & KAMTCHOUING, P. 2006. Antihyperglycemic and renal protective activities of *Anacardium occidentale* (Anacardiaceae) leaves in streptozotocin induced diabetic rats. *African Journal of Traditional, Complementary and Alternative Medicines*, 3, 23-35.
- TOMINO, Y., COOPER, M. E., KURTZ, T. W. & SHIMIZU, Y. 2012. Experimental models of type-2 diabetic nephropathy. *Experimental Diabetes Research*, 2012.

- TRISCHITTA, V., ITALIA, S., MAZZARINO, S., BUSCEMA, M., RABUAZZO, A. M., SANGIORGIO, L., SQUATRITO, S. & VIGNERI, R. 1992. Comparison of combined therapies in treatment of secondary failure to glyburide. *Diabetes Care*, 15, 539-542.
- TUTTLE, K. R., BAKRIS, G. L., BILOUS, R. W., CHIANG, J. L., DE BOER, I. H., GOLDSTEIN-FUCHS, J., HIRSCH, I. B., KALANTAR-ZADEH, K., NARVA, A. S. & NAVANEETHAN, S. D. J. A. J. O. K. D. 2014. Diabetic kidney disease: a report from an ADA Consensus Conference. 64, 510-533.
- UGOCHUKWU NH, BABADY NE (2002) Antioxidant effects of *Gongronema latifolium* in hepatocytes of rat models of non-insulin dependent diabetes mellitus. *Fitoterapia* 73:612–618
- WEIBEL, E. 1979. Practical methods for biological morphometry. London. *Stereological methods*, 1, 40-116.
- WEIR MR. Albuminuria predicting outcome in diabetes: incidence of microalbuminuria in Asia-Pacific Rim. *Kidney Int* 2004;66:S38e9.
- WHITING, D. R., GUARIGUATA, L., WEIL, C. & SHAW, J. 2011. IDF diabetes atlas: global estimates of the prevalence of diabetes for 2011 and 2030. *Diabetes research and clinical practice*, 94, 311-321.
- YAZID, M. N. A. W. M., SIDIK, N. A. C., MAMAT, R. & NAJAFI, G. 2016. A review of the impact of preparation on stability of carbon nanotube nanofluids. *International Communications in Heat and Mass Transfer*, 78, 253-263
- ZHANG, X.-F., CHOI, Y.-J., HAN, J. W., KIM, E., PARK, J. H., GURUNATHAN, S. & KIM, J.-H. 2015. Differential nanoreprotoxicity of silver nanoparticles in male somatic cells and spermatogonial stem cells. *International journal of nanomedicine*, 10, 1335.
- ZHANG, L., ZHANG, F., YANG, X., LONG, G., WU, Y., ZHANG, T., LENG, K., HUANG, Y., MA, Y. & YU, A. 2013. Porous 3D graphene-based bulk materials with exceptional high surface area and excellent conductivity for supercapacitors. *Scientific reports*, 3, 1408
- ZHOU, X., WANG, B., ZHU, L. & HAO, S. 2012. A novel improved therapy strategy for diabetic nephropathy: targeting AGEs. *Organogenesis*, 8, 18-21.
- ZIMMET, P. 1999. Diabetes epidemiology as a tool to trigger diabetes research and care. *Diabetologia*, 42, 499-518.
- ZULKIPLI, I. N., DAVID, S. R., RAJABALAYA, R. & IDRIS, A. 2015. Medicinal plants: a potential source of compounds for targeting cell division. *Drug target insights*, 9, DTI. S24946.

BRIDGING

BETWEEN CHAPTER ONE and TWO

Diet and lifestyle choices contribute to the development of type 2 diabetes mellitus. The rise of type 2 diabetes mellitus in the world, particularly in Africa has attracted an urgent need to manage the Scourge. The previous chapter looked at the etiopathology of diabetes as well as the current antidiabetic drugs used in the management of the disease. The literature review revealed the remarkable contribution of *Cinnamomum Cassia* as a medicinal plant in the management of diabetes and the positive health benefit of *Cinnamomum Cassia* silver nanoparticles on type 2 diabetes mellitus. However, the following chapter will be outlining possible adverse effects of CcAgNPs on internal organs (Kidney and Liver) of non-diabetic rats.

CHAPTER TWO

PUBLISHED ARTICLE

Effect of Long-Term Administration of *Cinnamomum Cassia* Silver Nanoparticles On Organs (Kidneys and Liver) Of Sprague-Dawley Rats

Koffi KOUAME^{1*}, Aniekan Imo PETER¹, Edidiong Nnamso AKANG^{1,2}, Misturah ADANA¹, Roshila MOODLEY³, Edwin Coleridge NAIDU¹, Onyemaechi Okpara AZU^{1,4}

¹ Discipline of Clinical Anatomy, School of Laboratory Medicine and Medical Sciences, University of KwaZulu-Natal, Private Bag X 54001, Durban 4000, South Africa.

² Department of Anatomy, College of Medicine, University of Lagos, Lagos, Nigeria.

³ School of Chemistry and Physics, University of KwaZulu-Natal, Westville Campus. Private Bag X54001, Durban, 4000, South Africa.

⁴ Department of Anatomy, School of Medicine, University of Namibia, Windhoek, Namibia

Correspondence: 207503022@stu.ukzn.ac.za

Published in Turkish Journal of Biology

28-08-2018- Published Online.

Effect of long-term administration of *Cinnamomum cassia* silver nanoparticles on organs (kidneys and liver) of Sprague-Dawley rats

Koffi KOUAME^{1*}, Aniekan Imo PETER¹, Edidiong Nnamso AKANG^{1,2}, Misturah ADANA¹, Roshila MOODLEY³, Edwin Coleridge NAIDU¹, Onyemaechi Okpara AZU^{1,4}

¹Discipline of Clinical Anatomy, School of Laboratory Medicine and Medical Sciences, University of KwaZulu-Natal, Durban, South Africa

²Department of Anatomy, College of Medicine, University of Lagos, Lagos, Nigeria

³School of Chemistry and Physics, University of KwaZulu-Natal, Westville Campus, Durban, South Africa

⁴Department of Anatomy, School of Medicine, University of Namibia, Windhoek, Namibia

Received: 27.05.2018 • Accepted/Published Online: 28.08.2018 • Final Version: 10.12.2018

Abstract: This study investigated the toxic effects of silver on the kidneys and livers of Sprague-Dawley rats after administering multiple doses of silver nanoparticles synthesized using extracts of *Cinnamomum cassia* (CcAgNPs). Twenty-four Sprague-Dawley rats (250 ± 20 g) were randomly assigned to four groups (A–D) of six animals per group and treated for 8 weeks. Group A was administered 200 mg/kg of *Cinnamon Cassia* extract (Cc), group B 5 mg/kg of CcAgNPs, group C 10 mg/kg of CcAgNPs, and group D normal saline. Body weight was measured weekly and fasting blood glucose was measured fortnightly. At the end of the experiment, animals were euthanized and organs (livers and kidneys) were fixed in neutral buffered formalin and processed for light microscopy (H&E). Body weight differences were significantly higher ($P < 0.05$) in the low-dose Cc group and the kidney to body weight ratio was not significant. Renal function analysis of proteins and ketones showed a significant increase in CcAgNP-treated rats ($P < 0.05$). Kidney and liver histology showed distortions in hepatocytes and sinusoidal linings with infiltrations especially in the higher dose groups. Kidney histology mirrored degenerative changes in glomerular and Bowman's capsules with fibrillary mesangial interstitium. CcAgNPs impairs renal and hepatic morphology and function after a long period of administration.

Key words: Histology, nanomedicine, toxicity, degenerative, congestion

1. Introduction

Silver nanoparticles (AgNPs) have gained unique attention because of their attractive properties, including their high surface to volume proportions, reactant properties, and antimicrobial impact (Okafor et al., 2013). This is particularly relevant in the health sciences as it opens new frontiers in drug synthesis and delivery needed to target some of the sanctuary sites difficult for normal therapeutic doses of drugs to penetrate (Peter et al., 2018). However, most techniques used for the synthesis of nanoparticles (NPs) are costly and may negatively influence biological systems. Therefore, green synthesis using plant materials offers a relatively more secure and ecofriendly methodology for NP synthesis and has been readily adopted for silver nanomaterials. Plants offer an attractive system for NP synthesis because of their capacity to deliver an extensive variety of optional metabolites with weak potential for toxicity. Plant extracts offer less biohazard, are environmentally friendly, and are less delicate to

handle compared to microscopic organisms and therefore offer a green option for biosynthesis, such as AgNPs (Pandey et al., 2013). It is pertinent to mention that some plants are already being exploited in this technique for green nanoparticle synthesis, including the leaves of *Olea europaea* and the bark of the *Cinnamomum zeylanicum* tree, used as a part of conventional prescriptions in Turkey and in other nations (Kumar et al., 2013).

Cinnamomum cassia, also known as Chinese cassia or Chinese cinnamon, is an evergreen tree originating from southern China and widely cultivated there and elsewhere in southern and eastern Asia (India, Indonesia, Laos, Malaysia, Taiwan, Thailand, and Vietnam). In South Africa, mostly in the KwaZulu-Natal region, it is used as a spice and for medicinal remedy in various illnesses, such as diabetes. Lee (2002) earlier reported its antidiabetic property in vitro. *Cinnamomum cassia* extracts offer additional qualities for use in NP synthesis due to their phytoconstituents (phenolics and flavonoids), which act

* Correspondence: 207503022@stu.ukzn.ac.za
498

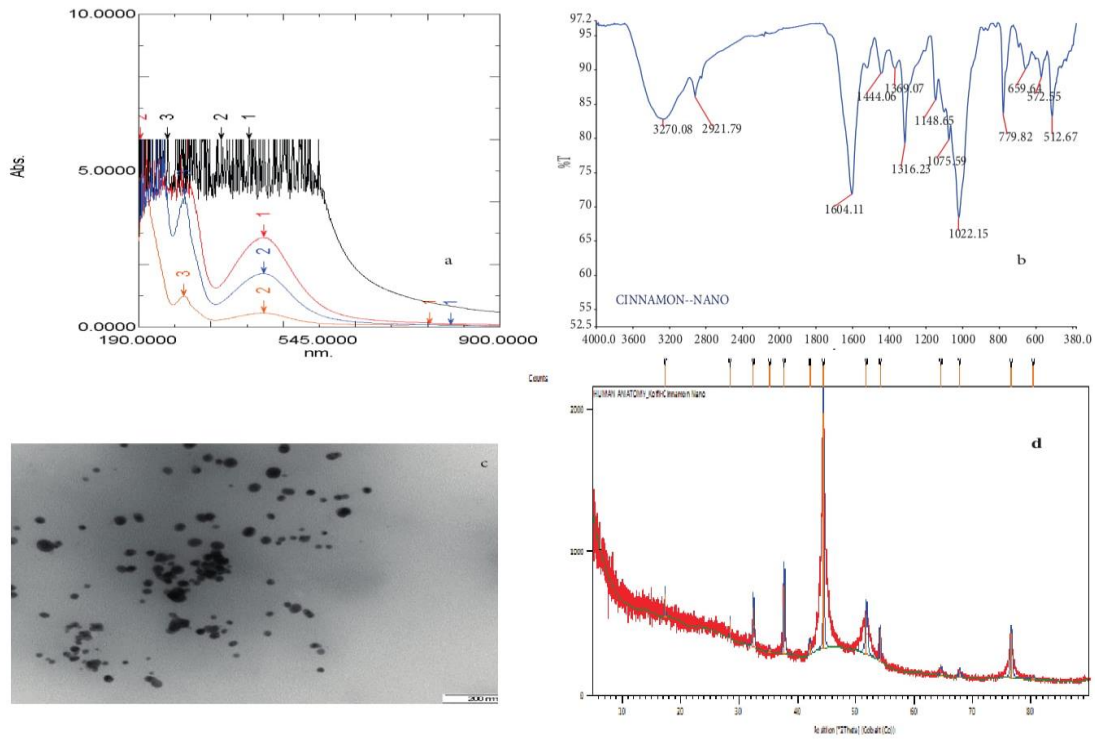


Figure 1. a) UV-Vis absorption spectra for *Cinnamomum cassia* silver nanoparticles (CcAgNPs), b) FTIR spectra of aqueous *Cinnamomum cassia* silver nanoparticles (CcAgNPs), c) TEM images of *Cinnamomum cassia* silver nanoparticles (CcAgNPs), d) XRD patterns of *Cinnamomum cassia* silver nanoparticles (CcAgNPs).

2.7. Experimental design

In this experiment, Sprague-Dawley rats were randomly assigned to different groups. The following groups of six animals each were treated. Group A comprised rats that received Cc (200 mg/kg), orally, once per day. Group B comprised rats administered a low dosage of CcAgNPs (5 mg/kg), orally, once per day. Group C comprised rats administered a higher dosage of CcAgNPs (10 mg/kg), orally, once per day (Sulaiman et al., 2015). CcAgNPs were dissolved in normal saline and administered orally, once daily, and group D comprised rats (the control) that also

received normal saline (1 mL). All administrations were done at 1000 hours daily for 56 consecutive days, through a rat gavage needle (Daisy and Saipriya, 2012). Body weight was recorded every week in the morning between 0800 and 1000 hours using an electronic balance (Zeiss, Germany; 0.000 g). After 56 days of administration, all animals were sacrificed using excess halothane anesthetic. Blood was then collected via transcardial puncture for biochemistry. Liver and kidney tissues were harvested after a laparotomy and processed for light microscopic studies. In addition, the weights of each kidney and liver were recorded.

2.8. Histopathological examination of kidney and liver tissues

Organs were washed in saline and fixed in 10% neutral buffered formalin for 24 h. Samples were transferred to 70% ethanol (Latendresse et al., 2002). They were then processed using ascending grades of ethyl alcohol to dehydrate the samples, and xylene was used as the clearing agent. Samples were then mounted in molten Paraplast at 58–62 °C; slices of 4–5 µm were cut using a microtome (HM 315 microtome, Walldorf, Germany) from the prepared blocks and stained with hematoxylin and eosin (H&E). Sections were viewed and photographed using an Olympus light microscope (Olympus BX51, Olympus Optical Co. Ltd., Tokyo, Japan) with an attached camera (Olympus E-330).

2.9. Statistical analysis

All results are presented as the mean ± standard deviation of the mean. Statistical investigations were done utilizing one-way analysis of difference (ANOVA) followed by Tukey's post hoc tests utilizing Graph Pad Prism Version 5. This allowed statistical comparison between the control and treated groups and statistical significance was acknowledged at $P < 0.05$.

3. Results

3.1. Effect of CcAgNPs on weight of body and vital organs

The oral treatment of rats with low and high doses of CcAgNPs (5 mg/kg and 10 mg/kg) impacted the body weight of experimental animals compared to the control as well as those treated with Cc. Body weight of experimental rats treated with CcAgNPs at low doses increased significantly compared to those treated with high doses and the control ($P < 0.05$) (Table). In addition, weights of kidneys and livers of rats were not different between those treated at low doses of CcAgNPs and the control as well

as the group treated with Cc and this was not statistically significant at $P < 0.05$.

3.2. Effect of CcAgNPs on blood glucose

It was observed that fasting blood glucose levels of control animals were essentially similar to those of treated animals. Animals in groups B and C treated with CcAgNPs (5 mg/kg and 10 mg/kg, respectively) showed the same levels of fasting blood glucose (Figure 2).

3.3. Effect of CcAgNPs on renal function parameters

It was observed that protein, ketone, and hemoglobin levels in the urine of control animals were lower than those of treated animals. Animals in group B, treated with low doses of CcAgNPs (5 mg/kg), showed a moderate presence of protein, ketone, and hemoglobin in the urine, while those in group C, treated with high doses of CcAgNPs (10 mg/kg), displayed considerable presence of urine markers (Figure 3).

3.4. Effect of CcAgNPs on the morphology of livers in Sprague-Dawley rats

Histological sections of liver tissues of rats were prepared and stained with the standard H&E technique and are presented in Figures 4A–4D. Figure 4A shows a liver section with outlines of hepatocytes showing nuclei that are clearly visible while the central vein appears distorted with loss of sinusoidal lining. Histologic sections of rats treated with 5 mg/kg of CcAgNPs (Figure 4B) show a distorted cytoarchitecture of hepatocytes, widened sinusoidal spaces, and focal congestion in the central veins. There are also infiltrations in the sinusoidal spaces. Rats treated with 10 mg/kg of CcAgNPs (Figure 4C) showed severe and generalized distortions in hepatocellular arrangement with nuclear condensation and pyknosis and areas of vacuolar changes suggestive of loss of liver architectural support/or fibrosis. Sections of the control rats (Figure 4D) essentially show normal hepatocytes lining sinusoidal spaces with

Table. Effect of *Cinnamomum cassia* silver nanoparticles (CcAgNPs) on weight of body and vital organs (mean ± SD, in mg).

Group	BWi	BWf	BWd	KW	BWKR	BWKRI	LW	BWLR	BWLRI
A	220 ± 6.6	220 ± 10	0	1.9 ± 0.14	0.89 ± 0.029	8.9	8.4 ± 0.70	0.0038 ± 0.002	0.38
B	310 ± 13	380 ± 17*	70. ±00	2.2 ± 0.67	0.005 ± 0.0003	0.5	12 ± 0.49	0.032 ± 0.003	3.2
C	310 ± 15	350 ± 23	40 ± 00	2.1 ± 0.08	0.006 ± 0.0006	0.6	12 ± 0.36	0.034 ± 0.002	3.4
D	320 ± 8	360 ± 17*	40 ± 00	2.4 ± 0.11	0.0067 ± 0.0003	0.67	13 ± 0.43	0.036 ± 0.021	3.6

*: Statistically significant ($P < 0.05$). Group A – rats treated with Cc, Group B – rats treated with low doses (5 mg/kg) of CcAgNPs, Group C – rats treated with high doses (10 mg/kg) of CcAgNPs, and Group D – control.

BWi = Initial body weight, BWf = final body weight, BWd = body weight, KW = kidney weight, BWKR = body weight/kidney ratio, BWKRI = body weight/kidney ratio index, LW = liver weight, BWLR = body weight/liver ratio AND BWLRI = body weight liver ratio index.

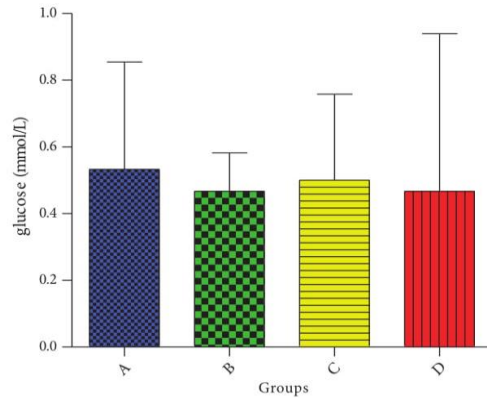


Figure 2. Effect of *Cinnamomum cassia* silver nanoparticles (CcAgNPs) on blood glucose of Sprague-Dawley rats. Group A – rats treated with Cc, Group B – rats treated with low doses (5 mg/kg) of CcAgNPs, Group C – rats treated with high doses (10 mg/kg) of CcAgNPs, and Group D – control. Not statistically significant at $P < 0.05$.

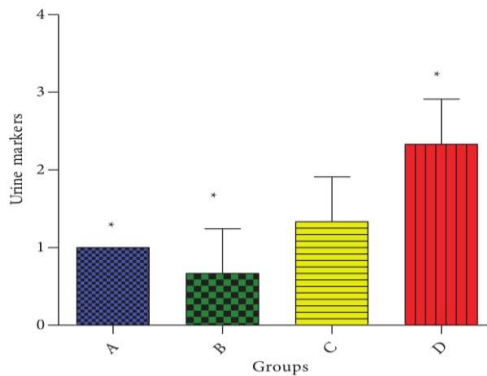


Figure 3. Effect of *Cinnamomum cassia* silver nanoparticles (CcAgNPs) on renal function parameters of urine proteins, ketones, and hemoglobin markers in Sprague-Dawley rats. *: Statistically significant ($P < 0.05$). Group A – rats treated with Cc, Group B – rats treated with low doses (5 mg/kg) of CcAgNPs, Group C – rats treated with high doses (10 mg/kg) of CcAgNPs, and Group D – control.

arrays of radiation towards the central vein. Hepatocyte nuclei are clearly visible and well stained.

3.5. Effect of CcAgNPs on the morphology of kidneys of Sprague-Dawley rats

Histological sections of kidney tissues of rats in the group treated with Cc (Figure 5A) showed the outline of renal corpuscles with glomeruli and Bowman’s capsular space distinctly showing mild atrophy of glomeruli. The nuclei of collecting tubules are identifiable and mesangial materials are delineated, showing areas of vacuolar changes. Sections from the kidney of rats treated with 5 mg/kg of CcAgNPs (Figure 5B) exhibited Bowman’s space and glomerular tissue congestion suggestive of necrotic changes. The mesangial tissues also showed nuclei of tubules that appeared deeply stained and interspersed. There was generalized atrophy of glomeruli with fibrillary meshwork in kidney tissues of rats treated with 10 mg/kg of CcAgNPs (Figure 5C) compared to the control (Figure 5D). In the control group (Figure 5D), histological sections appear essentially normal with glomeruli and Bowman’s capsular spaces depicting clear outlines with no detectable pathology. The mesangium is essentially preserved with nuclei of tubules visible and normal.

4. Discussion

While the utilization of AgNPs for biomedical purposes continues to grow, our insights and understanding of their impacts on living cells and on biochemical structures remains insufficient (Adeyemi et al., 2015; Sulaiman et al., 2015). In this study, we explored the effects of varied doses of CcAgNPs on the livers and kidneys of Sprague-Dawley rats following oral treatment. Although animals treated with CcAgNPs showed no obvious signs of distress during the experimental period, they appeared to be less active and alert compared to the control group. There were no clear differences between the skin colors of the groups. Abdominal palpations did not reveal any abnormal mass, which was confirmed at autopsy.

Data from this study report changes in the body weight and organ/body weight ratios. These changes in organ/body weight ratios may be suggestive of toxicity subsequent to the administration of CcAgNPs, as corroborated by previous researchers who revealed that NPs altered body and organ weights considerably (Sulaiman et al., 2015). Our results contrast with the reports of Song et al. (2017), which showed that Cc extract administration significantly decreased body weights, food intakes, and serum levels of glucose in obese mice.

While *Cinnamomum cassia* is commonly been used for weight control in traditional medicines, this discordancy may likely be attributed to the diverse experimental design inherent in the two studies as well as other possible

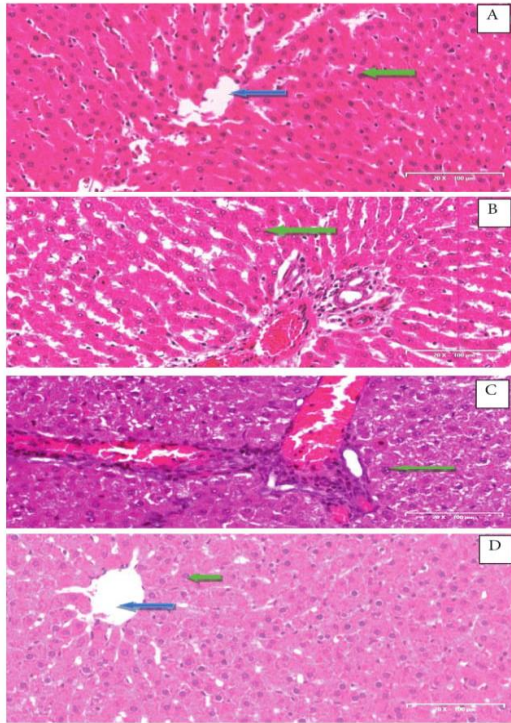


Figure 4. Effect of *Cinnamomum cassia* silver nanoparticles (CcAgNPs) on histological profile of liver in Sprague-Dawley rats. Group A – rats treated with Cc, Group B – rats treated with low doses (5 mg/kg) of CcAgNPs, Group C – rats treated with high doses (10 mg/kg) of CcAgNPs, and Group D – control. Blue arrow: central vein; green Arrow: hepatocytes.

mechanistic pathways not clearly understood. Similarly, aqueous extracts from cinnamon have been shown to increase in vitro glucose uptake and glycogen synthesis alongside increased phosphorylation of the insulin receptor. These overall effects are likely to aid in triggering the insulin cascade system with potential hypoglycemic effects (Jarvill-Taylor et al., 2001). Our results did not show any significant changes in blood glucose levels between the control group and treated animals, and neither did CcAgNPs.

As far as the histopathological studies were concerned, they showed degenerative changes and atrophy in renal and hepatic tissues of the rats treated with CcAgNPs in

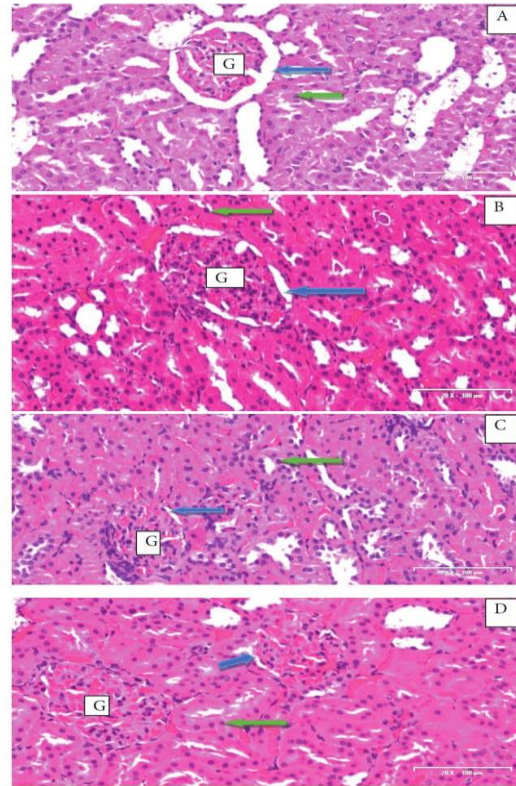


Figure 5. Effect of *Cinnamomum cassia* silver nanoparticles (CcAgNPs) on the histological profile of kidneys in Sprague-Dawley rats. Group A – rats treated with Cc, Group B – rats treated with low doses (5 mg/kg) of CcAgNPs, Group C – rats treated with high doses (10 mg/kg) of CcAgNPs, and Group D – control. G: Glomeruli; blue arrow: Bowman's space; green arrow: nuclei.

this study and this was exacerbated in the group receiving higher dose of CcAgNPs. Recent studies point to the potential of NPs aggregating in tissues such as the liver, which may provoke such observed alterations (Sulaiman et al., 2015) even in liver cells of rats (Hussain et al., 2005).

While some authors proposed that AgNPs decrease the action of mitochondria, which causes the reduction of accessible vitality for cells (Hussain et al., 2005), it is also possible that damage to the hepatocytes could be attributed to absorption of silver after oral administration

(Furchner et al., 1968). More so, Cc is reported to be used for the treatment of diabetes, attributable to the phenolics contained therein, and it is possible that its beneficial role in diabetic nephropathy treatment is plausible.

For renal markers of injury (ketones, proteins, and albumin) as well as qualitative histological evaluations, these derangements were more prominent with the higher dose of CcAgNPs. In agreement with our study, other studies reported toxic side effects on the renal tissue, which subsequently impacted renal function (Vasanth and Kurian, 2017), but this does not agree with studies by Luo et al. (2013) and Yan et al. (2015), possibly due to the fact that refined active compounds were tested directly or perhaps due to the differences in the experimental design as some were tested on animals in diabetic states.

Although our study did not report antioxidant markers, Cc has been reported to be rich in type A polyphenols, demonstrated to be responsible for improvements in fasting glucose even in clinical trial subjects (Anderson et al., 2008). The extract has also shown a significant ameliorative role in the antioxidant system in response to elevated levels of titanium dioxide nanoparticles or titanium dioxide bulk salt-induced oxidative stress with restoration of the histological damages in rat livers treated

with titanium dioxide nanoparticles or titanium dioxide bulk salt (Shakeel et al., 2017).

In conclusion, our findings revealed that biosynthesized silver nanoparticles using extracts from *Cinnamomum cassia* (CcAgNPs) caused injury to vital organs such as the liver and kidneys in normal healthy rats. The toxic effects appear related to the internal deposition of AgNPs, which in turn appeared dose-related. It is recommended that detailed immunological and electron microscopic evaluations of the tissues be carried out alongside other markers of liver/kidney injuries (biochemical assays for enzymes) in order to clearly establish specific alterations according to the dosage of CcAgNPs used.

Acknowledgments

We acknowledge the College of Health Sciences, UKZN, for financial support to doctoral student Koffi Kouame. This work was supported in part by grants of the National Research Foundation of South Africa to the senior author (OOA; Grant U99053) and to Dr Roshila Moodley (Grant 94041). We also thank the School of Chemistry and Physics, UKZN (Westville Campus), and especially the support of Judie Magura and Bongisiwe Shelembe. The authors also acknowledge the UKZN Nanotechnology Platform.

References

- Adeyemi OS, Adewumi I, Faniyan TO (2015). Silver nanoparticles influenced rat serum metabolites and tissue morphology. *J Basic Clin Physiol Pharmacol* 26: 355-361.
- Ahmed, S, Ahmad, M, Swami, B. L, Ikram, S (2016). A review on plants extract mediated synthesis of silver nanoparticles for antimicrobial applications: a green expertise. *Journal of Advanced Research* 7: 17-28.
- Ali ZA, Yahya R, Sekaran SD, Puteh R (2016). Green synthesis of silver nanoparticles using apple extract and its antibacterial properties. *Adv Mater Sci Eng* 2016: 4102196.
- Amin YM, Hawas AM, El-Batal A, Elsayed SHHE (2015). Evaluation of acute and subchronic toxicity of silver nanoparticles in normal and irradiated animals. *Br J Pharmacol Toxicol* 6: 22-38.
- Anderson RA (2008). Chromium and polyphenols from cinnamon improve insulin sensitivity: plenary lecture. *P Nutr Soc* 67: 48-53
- Ansari S, Farha Islam M (2012). Influence of nanotechnology on herbal drugs. A review. *J Adv Pharm Technol Res* 3: 142.
- Azu O (2015). Testicular morphology in spontaneously hypertensive rat model: oxidant status and stereological implications. *Andrologia* 47: 123-137.
- Connor EE, Mwamuka J, Gole A, Murphy C J, Wyatt M D (2005). Gold nanoparticles are taken up by human cells but do not cause acute cytotoxicity. *Small* 1: 325-327.
- Daisy P, Saipriya K (2012). Biochemical analysis of *Cassia fistula* aqueous extract and phytochemically synthesized gold nanoparticles as hypoglycemic treatment for diabetes mellitus. *Int J Nanomedicine* 7: 1189.
- Day W, Hunt J, McGiven A (1976). Silver deposition in mouse glomeruli. *Pathology* 8: 201-204.
- De Jong WH, Van Der Ven LT, Sleijffers A, Park MV, Jansen EH, Van Loveren H, Vandebriel RJ (2013). Systemic and immunotoxicity of silver nanoparticles in an intravenous 28 days repeated dose toxicity study in rats. *Biomaterials* 34: 8333-8343.
- Dos Santos CA, Seckler MM, Ingle AP, Gupta I, Galdiero S, Galdiero M, Rai, M (2014). Silver nanoparticles: therapeutical uses, toxicity, and safety issues. *J Pharm Sci* 103: 1931-1944.
- Elobeid MA (2016). Amelioration of streptozotocin induced diabetes in rats by eco-friendly composite nano-cinnamon extract. *Pak J Zool* 48: 645-650.
- Fatima M, Zaidi NUSS, Amraiz D, Afzal F (2016). In vitro antiviral activity of *Cinnamomum cassia* and its nanoparticles against H7N3 influenza A virus. *Journal of Microbiology and Biotechnology* 26: 151-159.
- Furchner J, Richmond C, Drake G (1968). Comparative metabolism of radionuclides in mammals-IV. Retention of silver-110m in the mouse, rat, monkey, and dog. *Health Phys* 15: 505-514.
- Hussain S, Hess K, Gearhart J, Geiss K, Schlager J (2005). In vitro toxicity of nanoparticles in BRL 3A rat liver cells. *Toxicol In Vitro* 19: 975-983.

- Hussain SM, Javorina AK, Schrand AM, Duhart HM, Ali SF, Schlager JJ (2006). The interaction of manganese nanoparticles with PC-12 cells induces dopamine depletion. *Toxicol Sci* 92: 456-463.
- Ismail OO, Isaac JA, Ugochukwu O, Oluwatosin OO, Aniekan PI, Edwin NC, Onyemaechi AO (2017). Impaired expression of testicular androgen receptor and collagen fibers in the testis of diabetic rats under HAART: The role of *Hypoxis hemerocallidea*. *Folia Histochem Cyto* 55: 149-158.
- Jarvill-Taylor KJ, Anderson RA, Graves DJ (2001). A hydroxychalcone derived from cinnamon functions as a mimetic for insulin in 3T3-L1 adipocytes. *J Am Coll Nutr* 20: 327-336.
- Khlebtsov N, Dykman L (2011). Biodistribution and toxicity of engineered gold nanoparticles: a review of in vitro and in vivo studies. *Chem Soc Rev* 40: 1647-1671.
- Kim YS, Song MY, Park JD, Song KS, Ryu HR, Chung YH, Kelman BJ (2010). Subchronic oral toxicity of silver nanoparticles. *Part Fibre Toxicol* 7: 20.
- Kumar A, Zhang X, Liang XJ (2013). Gold nanoparticles: emerging paradigm for targeted drug delivery system. *Biotechnol Adv* 31: 593-606.
- Latendresse JR, Warbritton AR, Jonassen H, Creasy DM (2002). Fixation of testes and eyes using a modified Davidson's fluid: comparison with Bouin's fluid and conventional Davidson's fluid. *Toxicol Pathol* 30: 524-533.
- Lee HS (2002). Inhibitory activity of *Cinnamomum cassia* bark-derived component against rat lens aldose reductase. *J Pharm Pharm Sci* 5: 226-230.
- Luo Q, Wang SM, Lu Q, Luo J, Cheng YX (2013). Identification of compounds from the water soluble extract of *Cinnamomum cassia* barks and their inhibitory effects against high-glucose-induced mesangial cells. *Molecules* 18: 10930-10943.
- Ogedengbe, O, Jegede A, Onanuga I, Offor U, Peter A, Akang E, Azu O (2018). Adjuvant potential of virgin coconut oil extract on antiretroviral therapy-induced testicular toxicity. An ultrastructural study. *Andrologia* 50: e12930.
- Okafor F, Janan A, Kukhtareva T, Edwards V, Curley M (2013). Green synthesis of silver nanoparticles, their characterization, application and antibacterial activity. *Int J Environ Res Public Health* 10: 5221-5238.
- Pandey S, Mewada A, Thakur M, Shah R, Oza G, Sharon M (2013). Biogenic gold nanoparticles as fortillas to fire berberine hydrochloride using folic acid as molecular road map. *Mater Sci Eng C* 33: 3716-3722.
- Peter AI, Naidu EC, Akang E, Ogedengbe OO, Offor U, Rambharose S, Azu OO (2018). Investigating organ toxicity profile of tenofovir and tenofovir nanoparticle on the liver and kidney: experimental animal study. *Toxicol Res* 34: 221.
- Shahverdi AR, Fakhimi A, Shahverdi HR, Minaian S (2007). Synthesis and effect of silver nanoparticles on the antibacterial activity of different antibiotics against *Staphylococcus aureus* and *Escherichia coli*. *Nanomed-Nanotechnol* 3: 168-171.
- Shakeel M, Jabeen F, Iqbal R, Chaudhry AS, Zafar S, Ali M, Asghar MS (2018). Assessment of titanium dioxide nanoparticles (TiO₂-NPs) induced hepatotoxicity and ameliorative effects of *Cinnamomum cassia* in Sprague-Dawley rats. *Biol Trace Elem Res* 182: 57-69.
- Shankar S, Teng X, Li G, Rhim JW (2015). Preparation, characterization, and antimicrobial activity of gelatin/ZnO nanocomposite films. *Food Hydrocolloid* 45: 264-271.
- Shankar T, Karthiga P, Swarnalatha K, Rajkumar K (2017). Green synthesis of silver nanoparticles using *Capsicum frutescens* and its intensified activity against *E. coli*. *Resour Effic Technol* 3: 303-308.
- Sulaiman F, Akanji M, Oloyede H, Sulaiman A, Olatunde A, Joel E, Quadri A (2015). Oral exposure to silver/gold nanoparticles: status of rat lipid profile, serum metabolites and tissue morphology. *J Med Sci* 15: 71.
- Sulaiman FA, Adeyemi OS, Akanji MA, Oloyede HOB, Sulaiman AA, Olatunde A, Muritala H (2015). Biochemical and morphological alterations caused by silver nanoparticles in Wistar rats. *Journal of Acute Medicine* 5: 96-102.
- Vasanth SB, Kurian GA (2017). Toxicity evaluation of silver nanoparticles synthesized by chemical and green route in different experimental models. *Artif Cells Nanomed Biotechnol* 45: 1721-1727.
- Webster RG, Bean WJ, Gorman OT, Chambers TM, Kawaoka Y (1992). Evolution and ecology of influenza A viruses. *Microbiol Rev* 56: 152-179.
- World Health Organization (2016). *Global Report on Diabetes*. Geneva, Switzerland: WHO Press.
- Yun JW, You JR, Kim YS, Kim SH, Cho EY, Yoon JH, Kim HC (2018). In vitro and in vivo safety studies of cinnamon extract (*Cinnamomum cassia*) on general and genetic toxicology. *Regul Toxicol Pharm* 95: 115-123.
- Zhang XF, Choi YJ, Han JW, Kim E, Park JH, Gurunathan S, Kim JH (2015). Differential nanoreprotoxicity of silver nanoparticles in male somatic cells and spermatogonial stem cells. *Int J Nanomedicine* 10: 1335.
- Zhou X, Wang B, Zhu L, Hao S (2012). A novel improved therapy strategy for diabetic nephropathy: targeting AGEs. *Organogenesis* 8: 18-21.

BRIDGING

BETWEEN CHAPTERS TWO AND THREE

Silver nanoparticles have opened a new frontier in drug synthesis and delivery needed to target organs in the management of various diseases and their complications. But, there is no agreement with respect to the safety of AgNPs. The previous chapter revealed possible adverse effects of CcAgNPs on internal organs (Kidney and Liver) of non-diabetic Sprague-Dawley rats. However, the following chapter will be focusing specifically on the Histopathology effects of *Cinnamomum cassia* silver nanoparticles (CcAgNPs) on the kidneys of type 2 diabetic Sprague-Dawley rats.

CHAPTER THREE

Koffi Kouame¹, Aniekan Imo Peter¹, Edidiong Nnamso Akang^{1,2}, Roshila Moodley^{3*}, Edwin Coleridge Naidu¹, Onyemaechi Okpara Azu^{1,4}

¹ Discipline of Clinical Anatomy, School of Laboratory Medicine and Medical Sciences, University of KwaZulu-Natal, Private Bag X 54001, Durban 4000, South Africa.

² Department of Anatomy, College of Medicine, University of Lagos, Idi-Araba, Lagos, Nigeria.

³ School of Chemistry and Physics, University of KwaZulu-Natal, Westville Campus. Private Bag X54001, Durban, 4000, South Africa.

⁴ Department of Anatomy, School of Medicine, University of Namibia, Windhoek, Namibia

* Corresponding author: Discipline of Clinical Anatomy, School of Laboratory Medicine and Medical Sciences, University of KwaZulu-Natal, Westville Campus. Private Bag X54001, Durban, 4000, South Africa. Phone: +27312604305. E-mail: azu@ukzn.ac.za; oazu@unam.na

Submitted to Bosnian Journal of Biomedical Sciences (BJBMS)

Manuscript ID: ID3481

Date of Submission: 04-10-2018

BOSNIAN JOURNAL OF BASIC MEDICAL SCIENCES

Journal of the Association of Basic Medical Sciences of FBiH



1.31 ²⁰¹⁷ CiteScore
87th percentile
Powered by Scopus

The Bosnian Journal of Basic Medical Sciences publishes an “Advanced online” manuscript format as a free service to authors in order to expedite the dissemination of scientific findings to the research community as soon as possible after acceptance following peer review and corresponding modification (where appropriate). An “Advanced online” manuscript is published online prior to copyediting, formatting for publication and author proofing, but is nonetheless, fully citable through its Digital Object Identifier (doi®). Nevertheless, this “Advanced online” version is NOT the final version of the manuscript. When the final version of this paper is published within a definitive issue of the journal with copyediting, full pagination, etc. the new final version will be accessible through the same doi and this “Advanced online” version of the paper will disappear.

RESEARCH ARTICLE

Koffi Kouame, et al.: Effect of cinnamon nanoparticles in kidneys of diabetic rats

Histological and biochemical effects of *Cinnamomum cassia* nanoparticles in kidneys of diabetic Sprague-Dawley rats

Koffi Kouame^{1*}, Aniekani Imo Peter¹, Edidiong Nnamso Akang^{1,2}, Roshila Moodley³, Edwin Coleridge Naidu¹, Onyemaechi Okpara Azu^{1,4}

¹Discipline of Clinical Anatomy, School of Laboratory Medicine and Medical Sciences, University of KwaZulu-Natal, Durban, South Africa

²Department of Anatomy, College of Medicine, University of Lagos, Idi-Araba, Lagos, Nigeria

³School of Chemistry and Physics, University of KwaZulu-Natal, Westville Campus, Durban, South Africa

⁴Department of Anatomy, School of Medicine, University of Namibia, Windhoek, Namibia

***Corresponding author:** Koffi Kouame, Discipline of Clinical Anatomy, School of Laboratory Medicine and Medical Sciences, Private Bag X54001, Durban, 4000, South Africa. Phone: +27312604305.

E-mail: kkouame@gmail.com
azu@ukzn.ac.za
oazu@unam.na

Submitted: 13 April 2018/**Accepted:** 02 October 2018

DOI: <https://dx.doi.org/10.17305/bjbms.2019.3481>

Licence: © 2019 ABMSFBIH.

ABSTRACT

This study investigated the antidiabetic activity of *Cinnamomum cassia* (*C. cassia*, Cc) silver nanoparticles (CcAgNPS) and effects of *C. cassia* on the kidneys of rats with induced type 2 diabetes. Twenty-four Sprague-Dawley rats weighing 250 ± 20 g were induced with diabetes by intraperitoneal injection of streptozotocin (STZ, 60 mg/kg). Animals were randomly assigned to one of four groups (n = 6) and treated for eight weeks with normal saline (control, group A), 5 mg/kg of CcAgNPs (group B), 10 mg/kg of CcAgNPs (group C), or 200 mg/kg of Cc (group D). Body weight and fasting blood glucose (FBG) was measured weekly and fortnightly, respectively. At the end of experiments animals were euthanized, blood and kidney tissue samples were collected for biochemistry (oxidative stress markers and renal function parameters) and kidneys were harvested for histology (PAS and H&E staining). Body weight was significantly higher in group B and C vs. control ($p < 0.05$), while no significant differences were observed in the kidney-to-body weight ratio between groups. FBG, glutathione, malondialdehyde, alanine aminotransferase, aspartate aminotransferase, serum urea and creatinine were significantly lower in group B, C and/or D vs. control (all $p < 0.05$). In group A, severe distortion of the glomerular network was observed, marked by the loss of capsular integrity, thickened basement membrane, tubular cells with pyknotic nuclei, vacuolization, and interstitial space with infiltrations. These adverse effects were mitigated by 5 mg/kg and 10 mg/kg of CcAgNPs. Our study confirms structural and functional damage to kidneys caused by diabetes. CcAgNPs have a regenerative potential in diabetes-induced kidney damage and may be used as an antidiabetic agent.

KEYWORDS: *Cinnamomum cassia*; silver nanoparticles; diabetes; histomorphology

INTRODUCTION

Diabetes is no longer a disease of predominantly rich nations and the prevalence of diabetes is steadily increasing in the middle-income countries, including African countries [1]. Despite the introduction of various antidiabetic and hypoglycemic agents, diabetes and associated secondary complications continue to be a major health problem worldwide [2]. Antidiabetic drugs currently in use do not completely control blood glucose levels, moreover, they cause side effects and insufficient response after prolonged use. Therefore, efforts are being made to find new medicines and therapeutic interventions to treat this debilitating condition [2]. Satyanarayan et al. [3] emphasized the need for alternative therapies in patients with diabetes, with a special focus on different indigenous plants. Compared to conventional drug formulations, nanotechnology-based drug carriers are more advantageous for medical use [4] and may be used for the treatment of various diseases.

Nanobiotechnology is a rapidly developing discipline at the intersection of nanotechnology and biology, utilized for the exploration and transformation of biological systems and pharmaceuticals. Targeting of nanocarriers can be improved through conjugation with various active bio-ligands such as biotin [4]. Moreover, core-shell and multi-layered nanoparticles can be loaded with several drugs and modified to enable controlled drug release. The integration of such nanocarriers in the treatment of diabetic nephropathy appears to be very promising [4].

Over the past few years, the success with the so-called green synthesis of biocompatible silver nanoparticles (AgNPs) has gained much attention for its application in biomedical sciences [5]. NPs are particles with a diameter of 100 nm or less that possess unique physical, chemical and biological properties, which make them potent diagnostic and therapeutic tools. Silver (Ag) is the metal of choice for the application of NPs in biology and medicine. AgNPs have been used as anticancer, antiangiogenic, and antibacterial agents [6-8]. Moreover, they

can be used to treat diseases that require a sustained release of a drug at several anatomical sites [9]. Due to the ultra-small size of AgNPs (1–100 nm), they exhibit unique physical, chemical, magnetic and optical properties [10,11]. Furthermore, they enhance solubility, bioavailability, pharmacological activity and stability of drugs, and protect from their toxicity [12]. Incorporation of herbal extracts into novel formulation systems such as nanosized drug delivery systems has captured the attention of major pharmaceutical corporations, due to the ability of those systems to overcome multiple dosage and lower absorption as major problems [12]. Natural products such as medicinal plants have, therefore, been a very good source of green NPs.

Cinnamomum cassia (*C. cassia*) of the plant family Lauraceae, also known as Chinese cassia or Chinese cinnamon, is an evergreen tree originating from southern China and widely cultivated in southern and eastern Asia. Nowadays, *C. cassia* is also found in Southern Africa. *C. cassia* extracts have shown to have antidiabetic effects *in vitro* [6]. In addition, it has been reported that *C. cassia* lowers blood glucose, blood pressure and serum cholesterol levels, exerts antioxidant and free radical scavenging activity, and has hepatoprotective effects *in vivo* [13,14]. However, in contrast to other medicinal plants that have been used as antidiuretic and antihyperlipidemic remedies [15], there is a lack of data on *C. cassia* effects on the kidneys in animal models with diabetes. In this study, we investigated the antidiabetic activity of *C. cassia* silver nanoparticles (CcAgNPs) and effects of *C. cassia* on the kidneys of rats with induced type 2 diabetes.

MATERIALS AND METHODS

Collection of plant material

Pure *C. cassia* powder was obtained from Warren Chem Specialities (Pty), Cape Town (Reference 492733) and silver nitrate (AgNO_3) was obtained from Capital Laboratory (Pty), KwaZulu-Natal.

Preparation of aqueous plants extract

The aqueous extract of *C. cassia* was prepared by adding a fine powder of the plant (10 g) to 300 mL of double-distilled water, which was allowed to boil for 10 minutes [16]. The resulting mixture was filtered and stored in a refrigerator at 4°C until analyzed.

Synthesis of *Cinnamomum cassia* silver nanoparticles (CcAgNPs)

An aqueous solution of AgNO_3 was dissolved in 250 mL Erlenmeyer flasks and added dropwise to 100 mL of the plant extract while stirring and heated at 45°C. This solution was stirred constantly at room temperature for 120 minutes, using a magnetic stirrer. A color change from light brown to dark brown indicated the formation of AgNPs.

Structural analysis of CcAgNPs

The CcAgNPs solution was centrifuged in an Eppendorf Centrifuge (Model: 5804/5804 R, USA). The treated solutions were transferred separately into Eppendorf tubes that were pre-weighed and subjected to purification for 2 hours at 5000 rpm and 4°C.

The bioreduction of Ag^1 to Ag^0 was evaluated using a SHIMADZU UV-2600 UV-Vis spectrophotometer (Shimadzu, Tokyo, Japan), at a range of 120–900 nm and with a resolution of 1 nm. UV-Vis analysis was performed by taking a baseline measurement with the solvent (distilled water) at different wavelengths from 190 nm to 900 nm, at room temperature and pH 3.96 [17]. An aqueous component of *C. cassia* was sampled. The component was scanned over 190 nm to 900 nm wavelength range.

To evaluate the bioreduction and capping functional groups of AgNPs, infrared spectra of the extracts and their corresponding biosynthesized AgNPs were obtained on a Fourier transform infrared (FTIR) spectrophotometer with universal attenuated total reflectance (ATR) sampling accessory (Perkin Elmer Spectrum 100, USA) [17]. The size and morphology of AgNPs were examined using transmission electron microscopy (TEM). Powdered AgNPs were mixed with the pellet and the analysis was immediately carried out using the Perkin Elmer-Spectrum 100 (Perkin Elmer) [17].

Transmission electron microscopy (TEM) was also used to obtain selected area electron diffraction (SAED) patterns of AgNPs to evaluate their crystallinity. For TEM measurements, solutions of synthesized AgNPs were sonicated using a sonication bath (Soniclean, England) and evenly dispersed AgNPs were coated onto carbon-coated TEM grids and placed under a lamp to evaporate the solvent before analysis.

Animal handling and ethics approval

Twenty-four pathogen-free, male, Sprague-Dawley rats weighing 250 ± 20 g were selected for the experiments; they were kept and maintained under laboratory conditions at a temperature of 21.5°C to 2.2°C , humidity ($60 \pm 1\%$), and 12 hour light/dark cycle. They were allowed free access to food (standard pellets) and water, and were fed *ad libitum*.

Animals were allowed to acclimatize in their respective cages for seven days prior to the commencement of experiments. The institutional Ethics Committee of the University of KwaZulu-Natal approved the experimental protocols and procedures used in this study (Ethics references number AREC/074/016 D).

Induction of type 2 diabetes

Hyperglycemia was induced by injecting nicotinamide [100 mg/kg of body weight] (Sigma Aldrich, South Africa) and streptozotocin (STZ, 60 mg/kg, intraperitoneal injection [I.P]).

Nicotinamide was administered 15 minutes before STZ that was dissolved in phosphate buffer citrate at pH 4.5 immediately before use [18].

Animals were then kept under observation for confirmation of diabetes induction. Blood glucose was tested and monitored on days 0, 7, 14, 28, 42, and 56. The animals were tested using Accu-chek Active 50 (Roche) blood glucose test strips, purchased from Dis-Chem, South Africa. Blood was collected from the tail vein of the rats at 10 am daily. The animals with a fasting blood glucose (FBG) level >9 mmol/L were considered diabetic.

Experimental design

Twenty-four STZ-induced diabetic Sprague-Dawley rats were randomly assigned to four groups (six animals per group). In control group A, rats received normal saline (1 mL) orally once per day. Group B rats were orally administered with CcAgNPs at low dose (5 mg/kg), once per day [7]. Group C rats were orally administered with CcAgNPs at high dose (10 mg/kg), once per day [7]. Group D rats were administered with *C. cassia* plant extract at 200 mg/kg. CcAgNPs and *C. cassia* plant extract were dissolved in normal saline and administered orally once daily at 10 am for 56 consecutive days, using a rat gavage needle [17]. FBG was measured on days 0, 14, 28, 42 and 56. Body weight was recorded every week between 8:00 am and 10:00 am using an electronic balance (Zeiss, West Germany (Pty) Ltd; 0.000 g calibration). At the end of the experiment, all rats were euthanized with an overdose of Halothane anesthesia. Blood was immediately withdrawn via cardiac puncture and stored in 10 ml EDTA heparinized tubes. After that, it was centrifuged at 3000 rpm for 10 minutes and serum was collected using Eppendorf tubes and stored at -80°C in a deep freezer.

After laparotomy, organs were harvested for histology. Kidneys were immediately washed with phosphate buffer solution (PBS) to remove blood and then dissected. Blood and kidney tissue samples were used for biochemistry (oxidative stress biomarkers: glutathione [GSH], malondialdehyde [MDA], alanine aminotransferase [ALT], aspartate aminotransferase

[AST], and albumin [ALB]; renal function parameters: serum urea, creatinine, and uric acid). In addition, the weight of the kidneys was recorded.

Measurement of MDA levels in rat kidney tissue

Kidney tissue was homogenized in 0.2 M sodium phosphate buffer (pH 7.8) and then centrifuged for 15 minutes at 12000 rpm to separate the supernatant from the tissue extract, which is done under high speed. The supernatant was then collected and used for the measurement of lipid peroxidation. The procedure was carefully performed according to a previous method with slight modifications [19]. This method indicated the complex formed between MDA and thiobarbituric acid (TBA). Two hundred microliters of MDA standard series (0, 7.5, 15, 22.5, and 30 μ L) was added to a Pyrex screw-capped test tube containing the assay mixture of 200 μ L of 8.1% sodium dodecylsulfate (SDS), 750 μ L of 20% acetic acid (pH 3.5), 2 mL of 0.25% TBA, and 850 μ L of distilled water. The mixture was heated at 95°C for 60 minutes in a sand bath, cooled down to room temperature, and the absorbance was read at 532 nm using the spectrophotometer Synergy HTX multi-mode reader (Vacutec, USA). The concentration of TBA reactive substances (TBARS) in the samples was extrapolated from the MDA standard curve.

Measurement of GSH levels in rat kidney tissue

Glutathione concentration was assessed in rat renal tissue. The sample was first precipitated with 10% trichloroacetic acid (TCA) and then centrifuged at 2000 rpm for 10 minutes at 25°C. This technique was not used to separate the supernatant from the tissue extract but to separate the deproteinized supernatant from the extracted sample (tissue extract). The low centrifugation speed was also used to separate protein sediment according to the following steps: precipitated sample was inserted into the centrifuge, centrifuged, and as a result a supernatant and precipitate were obtained. This reaction mixture contained 100 μ L of

supernatant, 50 μ L of 0.5 mM 5,5'-dithiobis-2-nitrobenzoic acid (DTNB) and 150 μ L of 0.2 M sodium phosphate buffer (pH 7.8). After 15 minutes incubation at 25°C, the absorbance was measured at 412 nm using a spectrophotometer (Synergy HTX multi-mode reader, VACUTEC, USA). GSH concentration was extrapolated from a standard GSH curve.

Histopathological examination of rat kidney tissues

Kidneys were washed in saline and fixed in 10% neutral buffered formalin for 24 hours. The samples were transferred to 70% ethanol solution [20]. Ascending grades of alcohol were then used to dehydrate the samples and xylene was used as a clearing agent. The samples were immersed in molten paraffin wax at 58°C to 62°C. The prepared blocks were cut into slices of 5 μ m using a microtome (Microtome HM 315, Walldorf, Germany) and stained with hematoxylin and eosin (H&E) stain.

Additionally, the periodic acid-Schiff (PAS) staining technique was used to detect the presence of polysaccharides (e.g., glycogen) and mucosubstances (e.g., glycoproteins, glycolipids, and mucins) in rat kidney tissues. The PAS technique is most commonly used to evaluate the thickness of glomerular basement membrane (GBM) in renal disease [21]. The sections were viewed and photographed using an Olympus light microscope (Olympus BX, Tokyo, Japan) with an attached camera (Olympus E-330, Olympus Optical Co. Ltd., Tokyo, Japan).

Statistical analysis

All results are presented as the mean \pm standard error of the mean (SE). One-way analysis of variance (ANOVA) followed by Turkey's post-hoc test was performed using GraphPad Prism version 5.00 for Windows (GraphPad Software, La Jolla, California, USA).

Comparisons with $p < 0.05$ were considered statistically significant.

RESULTS

Synthesis of CcAgNPs

The aqueous solution of biosynthesized AgNPs from *C. cassia* powder showed a dark brown color indicating the formation of AgNPs (150 mg).

Effects of CcAgNPs on rat body and kidney weight

The oral treatment of diabetic rats with a low (5 mg/kg) and high (10 mg/kg) dose of CcAgNPs significantly increased the body weight of experimental animals compared to saline-treated diabetic controls ($p < 0.05$). In addition, the kidney-to-body weight ratio was not significantly different between groups [$p > 0.05$] (Table 1).

Effects of CcAgNPs on FBG levels

A significant reduction in FBG levels was observed in group B (5 mg/kg CcAgNPs), group C (10 mg/kg CcAgNPs), and group D (200 mg/kg *C. cassia* extract) of diabetic rats compared to diabetic control rats treated with saline [$p < 0.05$] (Figure 1).

Effects of CcAgNPs on renal function parameters

Diabetic rats treated with 5 mg/kg (group B) and 10 mg/kg (group C) doses of CcAgNPs showed significantly reduced levels of serum urea and creatinine compared to saline-treated diabetic rats ($p < 0.05$). In addition, this effect of CcAgNPs on the renal function parameters of diabetic rats was higher in group B compared to group C (Figure 2).

Effects of CcAgNPs on the histology of kidneys in diabetic rats

H&E-stained kidney sections of diabetic rats in control group showed a severe distortion of the glomerular architecture, with atrophic and necrotic changes, pyknotic nuclei as well as infiltrations of mesangial spaces and interstitium. Many of the proximal and distal convoluted tubules showed hypertrophic cells and vacuolization (Figure 3A). H&E-stained sections of diabetic rats in group B (5 mg/kg CcAgNPs) showed moderate degenerative changes in the glomeruli. The mesangium and interstitium were essentially normal with cellular components

(Figure 3B). In group C (10 mg/kg CcAgNPs), the kidney sections (Figure 3C) showed glomeruli with Bowman's space and capillary tufts, which appeared normal compared to controls. The kidney sections of diabetic rats in group D (200 mg/kg *C. cassia* extract) looked normal with clearly visible glomeruli, basement membrane of the capsular wall, and mesangial tissue (Figure 3D). The interstitium appeared normal and with no infiltrations. PAS-stained kidney sections of diabetic control rats (group A) showed glomerular distortions and ruptured capsular wall (stained purple), thickened basement membranes, and hypocellularity in the interstitial components. In group B and C, the PAS-staining intensity for glycogens was stronger; moreover the capsular walls of the glomeruli were evident in group B. The mesangial tissues were clearly delineated and interstitial tissue did not indicate any abnormalities. The kidney sections of group D (200 mg/kg *C. cassia* extract) showed PAS-positive glomerular capsular basement layers stained purple, indicating a normal glomerular tuft/capillary meshwork. The proximal and distal convoluted tubular cells with no abnormalities and purple-stained (glycogen) membranes of tubules were clearly visible (Figure 4A-D).

Effects of CcAgNPs on oxidative stress biomarkers

GSH levels were significantly lower in groups B, C, and D compared to control ($p < 0.05$). MDA and AST levels were significantly lower in groups B and C compared to control ($p < 0.05$). ALT levels were significantly lower in group B compared to control ($p < 0.05$). On the other hand, no significant differences were observed in ALB levels between experimental groups and control (Table 2).

DISCUSSION

Diabetes and its vascular complications are associated with different biochemical disorders such as hyperlipidemia and oxidative stress [22]. In our study, the treatment of diabetic rats

with high and low dose of CcAgNPs resulted in weight gain, probably due to changes in glucose and lipid metabolism. The body weight in STZ-induced diabetic rats was reduced partly due to the increased rate of proteolysis and lipolysis in the diabetic state, which leads to muscle wasting and consequent loss of adipose tissue [23]. An increase in body weight in rats treated with CcAgNPs might also be due to higher fluid intake and decreased urinary glucose excretion.

Previous studies have shown the ability of cinnamon to control hyperglycemia in diabetes [13]. In our study, diabetic rats treated with CcAgNPs increased their body weight by decreasing blood glucose levels. Similar findings were reported previously, which showed that oral administration of biosynthesized *Cassia fistula* gold nanoparticles improves body weight in rats with STZ-induced diabetes [17]. The proposed underlying mechanisms by which plant extracts control high blood glucose levels are the stimulation of pancreatic insulin secretion from β -cells in the islets of Langerhans and increased transport of blood glucose to peripheral tissues [24]. *C. cassia* extracts (nanoparticle conjugates) might have direct effects on residual beta cell secretion and probably increase peripheral utilization of glucose, as postulated by Hassan et al. [25]. *Gynura procumbens* water extract showed hypoglycemic effect by promoting glucose uptake through muscles, and *C. cassia* might have a similar mechanism of action. Nevertheless, in this study, we did not perform assays with pancreatic tissue of diabetic rats to confirm these assumptions.

In most of our cases, we observed lesions in the kidney sections similar to those seen in glomerulosclerosis in human patients. Zafar et al. [26] showed glomerular membrane thickening and early hypertrophy of glomeruli in the kidney sections of STZ-induced diabetic rats. Glomerular hypertrophy in diabetes represents an early event in the progression of glomerular pathology, in the absence of mesangial expansion [26,27].

Serum urea and creatinine are useful indices for evaluating the status of renal function. An increase in the level of serum urea may imply impaired renal excretion [28]. In our study, the serum levels of urea and creatinine increased in saline-treated diabetic control rats (Figure 2) but showed a concomitant decline in the groups treated with CcAgNPs, suggesting that renal dysfunction and possible kidney injury occurred in control diabetic rats due to severe hyperglycemia [29]. The observed increase in serum urea and creatinine levels in control diabetic rats was corroborated by the histomorphological changes indicative of early diabetic nephropathy, including mesangial expansion, diffuse GBM thickening and increased mesangial cellularity [29]. On the other hand, these effects were mitigated by 5 mg/kg and 10 mg/kg of CcAgNPs in group B and C, respectively.

In our study, increased ALT and AST levels indicated hepatic dysfunction due to hyperglycemia in STZ-induced diabetic rats (Table 2). ALT and AST are released when the injury involves organelles such as the mitochondria. Transaminases catalyze a transamination reaction and are vital markers of liver injury in clinical diagnostics [30]. A decrease in the level of serum urea after 56 days of administration of CcAgNPs observed in our study might be attributable to reduced amino acid degradation by the liver; moreover, this finding correlates with a decline in ALB levels in CcAgNPs-treated groups. Previously, studies showed that serum creatinine levels in animal model were significantly reduced suggesting enhanced glomerular clearance or impaired muscle metabolism [31,32].

Tissue antioxidant status is suggested to be an important factor in the development of diabetic complications [33]. Medicinal plants used to synthesize AgNPs, including *C. cassia*, exhibit strong antioxidant and free radical scavenging properties [34]. The antioxidant defense system is comprised of several enzymes, such as catalase and GSH, which are responsible for the maintenance of redox homeostasis and prevention of oxidative stress [35]. In

hyperglycemia, MDA levels increase [18] due to increased oxidant production, which impairs the antioxidant defense system via multiple pathways [36].

Diabetes mellitus is a leading cause of kidney disease globally and the assessment of renal functional parameters remains an essential tool in the diagnosis of diabetes. In this study, in addition to urea and creatinine, we have measured serum AST, ALP and ALB levels and showed that increased ALP levels reflected renal insufficiency in saline-treated control diabetic rats, while CcAgNPs-treatment attenuated this effect.

Albuminuria is a known prognostic marker of diabetic nephropathy [37]. Although serum ALB levels in our study were lower in CcAgNPs-treated groups they were not significantly different compared to saline-treated group. The presence of albuminuria in patients with diabetes usually indicates an underlying structural renal damage, as demonstrated by histological studies [38]. While *C. cassia* essential oil is known to contain several active components, such as cinnamaldehyde, flavonoids and coumarins, the specific component responsible for its antidiabetic effects is yet to be identified [39].

CONCLUSION

Our study showed that *C. cassia* silver nanoparticles (CcAgNPs) produced using the green synthesis approach are able to attenuate the histomorphological changes following STZ-induced diabetes, possibly acting via oxidant/antioxidant pathways.

ACKNOWLEDGMENTS

We acknowledge the College of Health Sciences, UKZN for their financial support to the doctoral student, Koffi Kouame. This work is supported in part by the National Research Foundation of South Africa to the senior author (OOA) Grant U99053 and Dr. Roshila Moodley (Grant No. 94041). We also thank the School of Chemistry and Physics, UKZN (Westville Campus) especially the support of Judie Magura and Bongisiwe Shelembe. The authors also acknowledge the UKZN Nanotechnology platform.

DECLARATION OF INTERESTS

The authors declare no conflict of interests.

REFERENCES

- [1] World Health Organization. Global report on diabetes. World Health Organization; 2016.
- [2] Subramoniam A. Plants with anti-diabetes mellitus properties. Boca Raton, FL: CRC Press; 2016. <https://doi.org/10.1201/b19653>.
- [3] Satyanarayana T, Katyayani B, Latha HE, Mathews AA, Chinna EM. Hypoglycemic and antihyperglycemic effect of alcoholic extract of *Euphorbia leucophylla* and its fractions in normal and in alloxan induced diabetic rats. *Pharmacogn Mag* 2006;2(8):244-53.
- [4] Zhou X, Wang B, Zhu L, Hao S. A novel improved therapy strategy for diabetic nephropathy: Targeting AGEs. *Organogenesis* 2012;8(1):18-21. <https://doi.org/10.4161/org.19332>.
- [5] Mieszawska AJ, Mulder WJ, Fayad ZA, Cormode DP. Multifunctional gold nanoparticles for diagnosis and therapy of disease. *Mol Pharm* 2013;10(3):831-47. <https://doi.org/10.1021/mp3005885>.
- [6] Lee HS. Inhibitory activity of *Cinnamomum cassia* bark-derived component against rat lens aldose reductase. *J Pharm Pharm Sci* 2002;5(3):226-30.
- [7] Sulaiman F, Akanji M, Oloyede H, Sulaiman A, Olatunde A, Joel E, et al. Oral exposure to silver/gold nanoparticles: Status of rat lipid profile, serum metabolites and tissue morphology. *J Med Sci* 2015;15(2):71-9. <https://doi.org/10.3923/jms.2015.71.79>.
- [8] Zhang XF, Choi YJ, Han JW, Kim E, Park JH, Gurunathan S, et al. Differential nanoreprotoxicity of silver nanoparticles in male somatic cells and spermatogonial stem cells. *Int J Nanomedicine* 2015;10:1335-57. <https://doi.org/10.2147/IJN.S76062>.
- [9] Panyam J, Labhasetwar V. Biodegradable nanoparticles for drug and gene delivery to cells and tissue. *Adv Drug Deliv Rev* 2003;55(3):329-47. [https://doi.org/10.1016/S0169-409X\(02\)00228-4](https://doi.org/10.1016/S0169-409X(02)00228-4).

- [10] Chen X, Schluesener H. Nanosilver: A nanoparticle in medical application. *Toxicol Lett* 2008;176(1):1-12. <https://doi.org/10.1016/j.toxlet.2007.10.004>.
- [11] Awazu K, Fujimaki M, Rockstuhl C, Tominaga J, Murakami H, Ohki Y, et al. A plasmonic photocatalyst consisting of silver nanoparticles embedded in titanium dioxide. *J Am Chem Soc* 2008;130(5):1676-80. <https://doi.org/10.1021/ja076503n>.
- [12] Ansari S, Farha Islam, Mohd. Sameem. Influence of nanotechnology on herbal drugs: A review. *J Adv Pharm Technol Res* 2012;3(3):142-6. <https://doi.org/10.4103/2231-4040.101006>.
- [13] Ranasinghe P, Piger S, Premakumara GS, Galappaththi P, Constantine GR, Katulanda P. Medicinal properties of 'true'cinnamon (*Cinnamomum zeylanicum*): A systematic review. *BMC Complement Altern Med* 2013;13(1):275. <https://doi.org/10.1186/1472-6882-13-275>.
- [14] Bandara T, Uluwaduge I, Jansz E. Bioactivity of cinnamon with special emphasis on diabetes mellitus: A review. *Int J Food Sci Nutr* 2012;63(3):380-6. <https://doi.org/10.3109/09637486.2011.627849>.
- [15] Malviya N, Jain S, Malviya S. Antidiabetic potential of medicinal plants. *Acta Pol Pharm* 2010;67(2):113-8.
- [16] Shankar T, Karthiga P, Swarnalatha K, Rajkumar K. Green synthesis of silver nanoparticles using *Capsicum frutescens* and its intensified activity against *E. coli*. *Resource-Efficient Technologies* 2017;3(3):303-8. <https://doi.org/10.1016/j.refffit.2017.01.004>.
- [17] Daisy P, Saipriya K. Biochemical analysis of *Cassia fistula* aqueous extract and phytochemically synthesized gold nanoparticles as hypoglycemic treatment for diabetes mellitus. *Int J Nanomedicine* 2012;7:1189-202. <https://doi.org/10.2147/IJN.S26650>.

- [18] BarathManiKanth S, Kalishwaralal K, Sriram M, Pandian SRK, Youn HS, Eom S, et al. Anti-oxidant effect of gold nanoparticles restrains hyperglycemic conditions in diabetic mice. *J Nanobiotechnology* 2010;8(1):16. <https://doi.org/10.1186/1477-3155-8-16>.
- [19] Chenni A, Yahia DA, Boukourt F, Prost J, Lacaille-Dubois M, Bouchenak M. Effect of aqueous extract of *Ajuga iva* supplementation on plasma lipid profile and tissue antioxidant status in rats fed a high-cholesterol diet. *J Ethnopharmacol* 2007;109(2):207-13. <https://doi.org/10.1016/j.jep.2006.05.036>
- [20] Peter AI, Naidu EC, Akang E, Ogedengbe OO, Offor U, Rambharose S, et al. Investigating organ toxicity profile of tenofovir and tenofovir nanoparticle on the liver and kidney: Experimental animal study. *Toxicol Res* 2018;34(3):221-9. <https://doi.org/10.5487/TR.2018.34.3.221>.
- [21] Agarwal S, Sethi S, Dinda A. Basics of kidney biopsy: A nephrologist's perspective. *Indian J Nephrol* 2013;23(4):243-52. <https://doi.org/10.4103/0971-4065.114462>.

- [22] Abou-Seif MA, Youssef AA. Evaluation of some biochemical changes in diabetic patients. *Clin Chim Acta* 2004;346(2):161-70. <https://doi.org/10.1016/j.cccn.2004.03.030>.
- [23] Budin SB, Ismail H, Chong PL. *Psidium guajava* fruit peel extract reduces oxidative stress of pancreas in streptozotocin-induced diabetic rats. *Sains Malaysiana* 2013;42(6):707-13.
- [24] Hassan Z, Ahmad MAAM, Naidu SR, Kumar G, Umachigi SP. Hypoglycaemic effects of aqueous extract of *Gynura procumbens*. *Pharmacologyonline* 2008;1:30-50.
- [25] Hassan Z, Yam MF, Ahmad M, Yusof APM. Antidiabetic properties and mechanism of action of *Gynura procumbens* water extract in streptozotocin-induced diabetic rats. *Molecules* 2010;15(12):9008-23. <https://doi.org/10.3390/molecules15129008>.

- [26] Zafar M, Naqvi S, Ahmed M, Kaimkhani ZA. Altered kidney morphology and enzymes in streptozotocin induced diabetic rats. *Int J Morphol* 2009;27(3):783-90.
<https://doi.org/10.4067/S0717-95022009000300024>.
- [27] Malatiali S, Francis I, Barac-Nieto M. Phlorizin prevents glomerular hyperfiltration but not hypertrophy in diabetic rats. *Exp Diabetes Res* 2008;2008(305403).
<https://doi.org/10.1155/2008/305403>.
- [28] Adeyemi OS, Akanji MA. *Psidium guajava* leaf extract: Effects on rat serum homeostasis and tissue morphology. *Comp Clin Path* 2012;21(4):401-7.
<https://doi.org/10.1007/s00580-010-1106-2>.
- [29] Nabi SA, Kasetti RB, Sirasanagandla S, Tilak TK, Kumar MVJ, Rao CA. Antidiabetic and antihyperlipidemic activity of *Piper longum* root aqueous extract in STZ induced diabetic rats. *BMC Complement Altern Med* 2013;13(1):37. <https://doi.org/10.1186/1472-6882-13-37>.
- [30] Li B, Wang Z, Fang J-J, Xu C-Y, Chen W-X. Evaluation of prognostic markers in severe drug-induced liver disease. *World J Gastroenterol* 2007;13(4):628-32.
<https://doi.org/10.3748/wjg.v13.i4.628>.
- [31] Adeyemi OS, Sulaiman FA. Biochemical and morphological changes in *Trypanosoma brucei brucei*-infected rats treated with homidium chloride and diminazene aceturate. *J Basic Clin Physiol Pharmacol* 2012;23(4):179-83. <https://doi.org/10.1515/jbcpp-2012-0018>.
- [32] Adeyemi O, Sulaiman F, Akanji M, Oloyede H, Sulaiman A, Olatunde A, et al. Biochemical and morphological changes in rats exposed to platinum nanoparticles. *Comp Clin Path* 2016;25(4):855-64. <https://doi.org/10.1007/s00580-016-2274-5>.
- [33] Wohaieb SA, Godin DV. Alterations in free radical tissue-defense mechanisms in streptozocin-induced diabetes in rat: Effects of insulin treatment. *Diabetes* 1987;36(9):1014-8. <https://doi.org/10.2337/diab.36.9.1014>.

- [34] Marles RJ, Farnsworth NR. Antidiabetic plants and their active constituents. *Phytomedicine* 1995;2(2):137-89. [https://doi.org/10.1016/S0944-7113\(11\)80059-0](https://doi.org/10.1016/S0944-7113(11)80059-0).
- [35] Baynes JW. Role of oxidative stress in development of complications in diabetes. *Diabetes* 1991;40(4):405-12. <https://doi.org/10.2337/diab.40.4.405>.
- [36] King GL, Loeken MR. Hyperglycemia-induced oxidative stress in diabetic complications. *Histochem Cell Biol* 2004;122(4):333-8. <https://doi.org/10.1007/s00418-004-0678-9>.
- [37] Borch-Johnsen K, Wenzel H, Viberti G, Mogensen C. Is screening and intervention for microalbuminuria worthwhile in patients with insulin dependent diabetes? *BMJ* 1993;306(6894):1722-5. <https://doi.org/10.1136/bmj.306.6894.1722>.
- [38] Lahdenkari AT, Lounatmaa K, Patrakka J, Holmberg C, Wartiovaara J, Kestilä M, et al. Podocytes are firmly attached to glomerular basement membrane in kidneys with heavy proteinuria. *J Am Soc Nephrol* 2004;15(10):2611-8. <https://doi.org/10.1097/01.ASN.0000139478.03463.D9>.
- [39] Hanhineva K, Törrönen R, Bondia-Pons I, Pekkinen J, Kolehmainen M, Mykkänen H, et al. Impact of dietary polyphenols on carbohydrate metabolism. *Int J Mol Sci* 2010;11(4):1365-402. <https://doi.org/10.3390/ijms11041365>.

TABLES AND FIGURES

TABLE 1. Effects of *Cinnamomum cassia* silver nanoparticles (CcAgNPs) on body weight of streptozotocin-induced diabetic rats

Group	BWI (g)	BWF (g)	W gain/Loss (g)	KW (g)	KBWR
Control (saline)	240±21	210±19	Loss	2.7±0.81	0.89±0.48
5 mg/kg CcAgNPs	290±16*	300±19*	Gain	2.4±0.26	0.87±0.23
10 mg/kg CcAgNPs	220±14	230±14*	Gain	2.1±0.34	0.93±0.13
200 mg/kg <i>C. cassia</i> extract	220±12 *	230±16*	Gain	1.9±0.36*	0.89±0.077

Results are expressed as mean ± standard error of the mean. *Statistically significant at $p < 0.05$. BW:

Body weight; BWI: Initial body weight; BWF: Final body weight; W gain/loss: Difference between control diabetics and treated groups, in body weight; KW: Kidney weight; KBWR: Kidney-to-body weight ratio

TABLE 2. Effects of *Cinnamomum cassia* silver nanoparticles (CcAgNPs) on oxidative stress markers in streptozotocin-induced diabetic rats

Group	GSH (mg/L)	MDA (mmol/L)	ALT (U/L)	AST (U/L)	ALB (g/dL)
Control (saline)	0.084±0.004	1.4±0.22	89±0.0	46±14	6.6±1.6
5 mg/kg CcAgNPs	0.035±0.004*	0.60±0.15*	87±0.28*	20±1*	5.4±0.18
10 mg/kg CcAgNPs	0.027±0.005*	0.83±0.07*	88±0.25	9.5±4.4*	5.6±0.19
200 mg/kg <i>C. cassia</i> extract	0.042±0.003*	0.81±0.09	88±0.25	30±9.4	6.05±0.31

Results are expressed as mean ± standard error of the mean. *Statistically significant at $p < 0.05$.

GSH: Glutathione; MDA: Malondialdehyde; ALT: Alanine transaminase; AST: Aspartate transaminase; ALB: Albumin

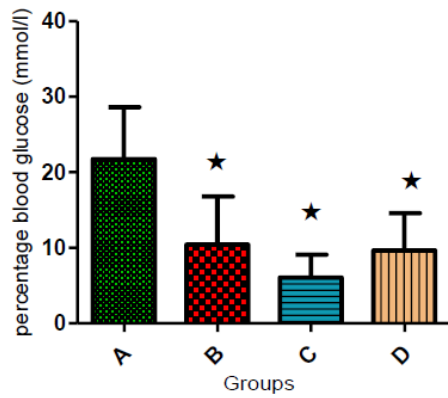


FIGURE 1. Comparison of FBG levels (mmol/L) between different groups of streptozotocin-induced diabetic rats. A significant reduction in FBG levels was observed in group B (5 mg/kg CcAgNPs), group C (10 mg/kg CcAgNPs), and group D (200 mg/kg *C. cassia* extract) of diabetic rats compared to diabetic rats treated with saline (group A) [$*p < 0.05$]. FBG: Fasting blood glucose; CcAgNPs: *Cinnamomum cassia* silver nanoparticles.

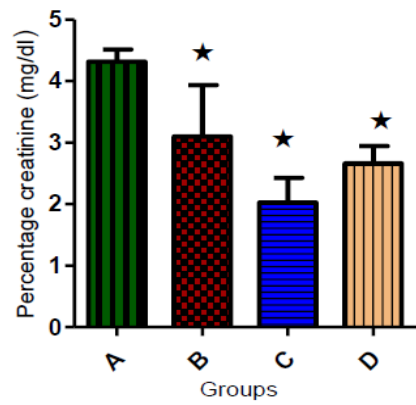
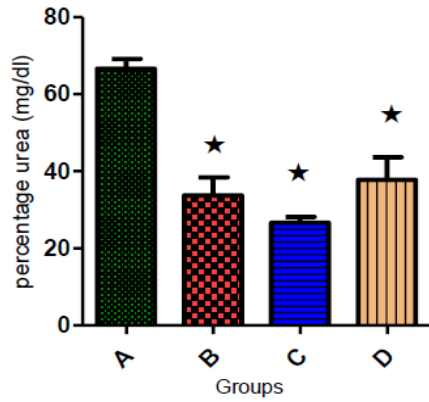
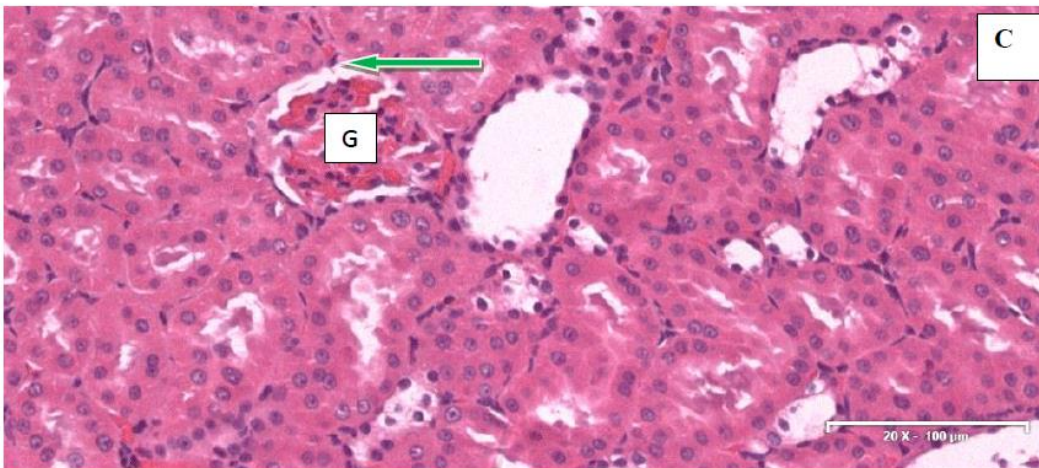
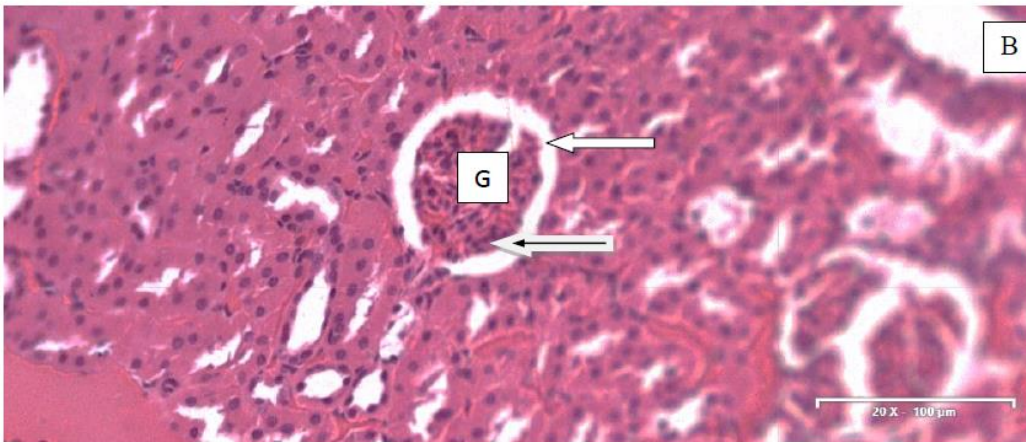
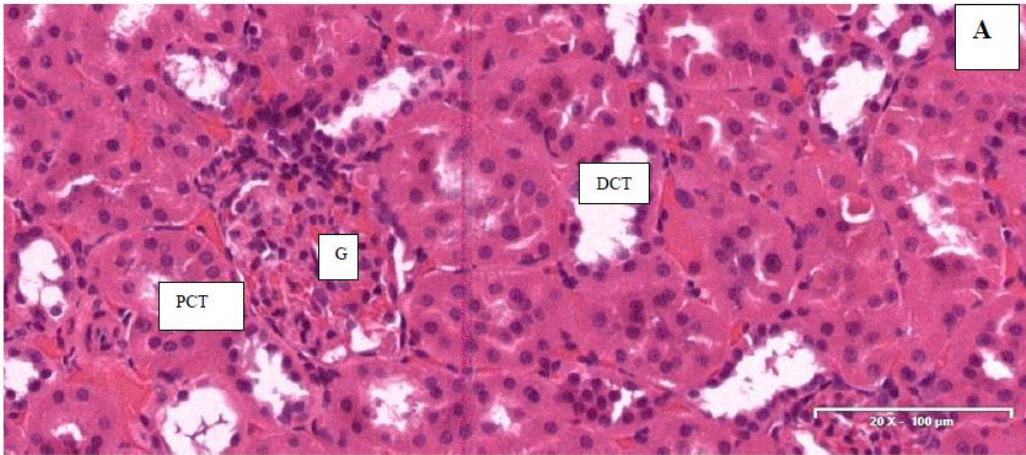


FIGURE 2. Comparison of serum urea and creatinine levels (mg/dL) between different groups of streptozotocin-induced diabetic rats. Diabetic rats treated with 5 mg/kg (group B) and 10 mg/kg (group C) doses of CcAgNPs showed significantly reduced levels of serum urea and creatinine compared to saline-treated diabetic rats (group A) [$*p < 0.05$]. CcAgNPs: *Cinnamomum cassia* silver nanoparticles.



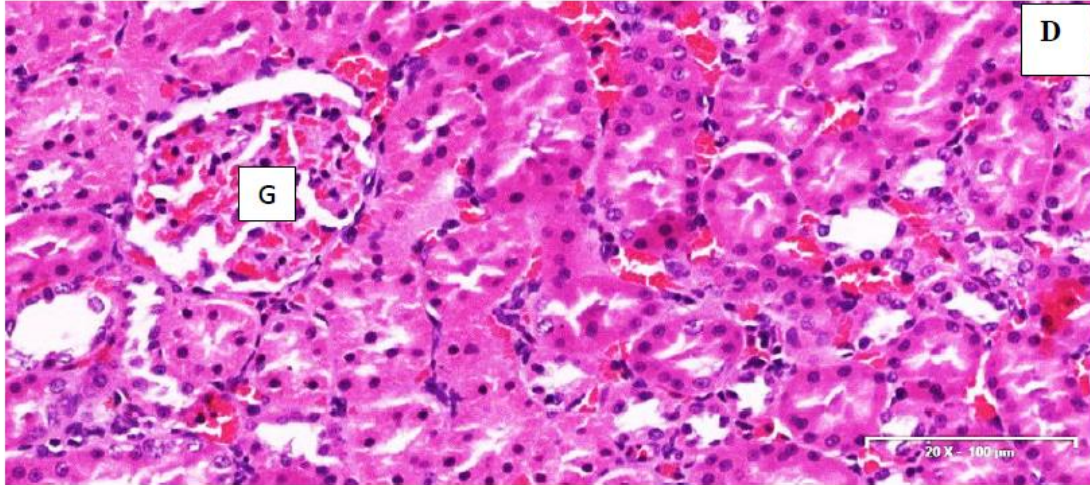
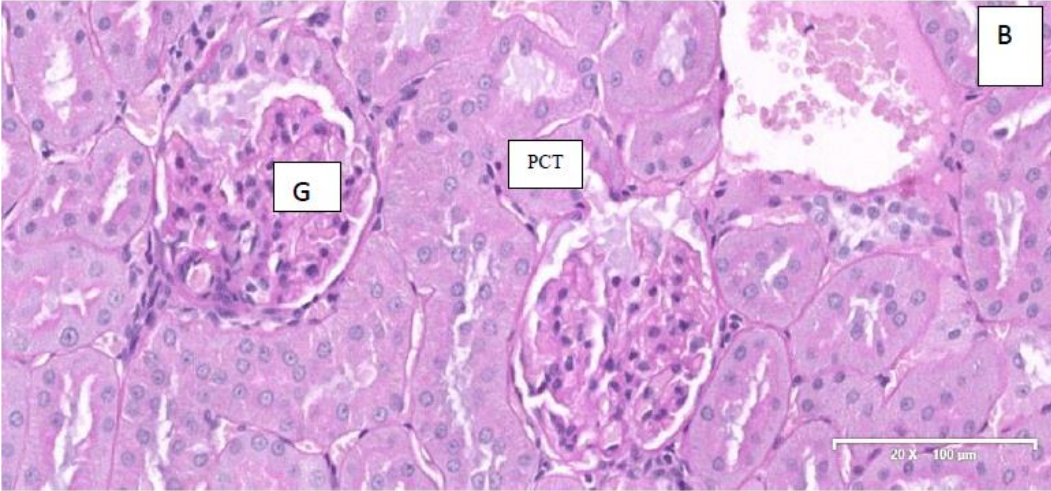
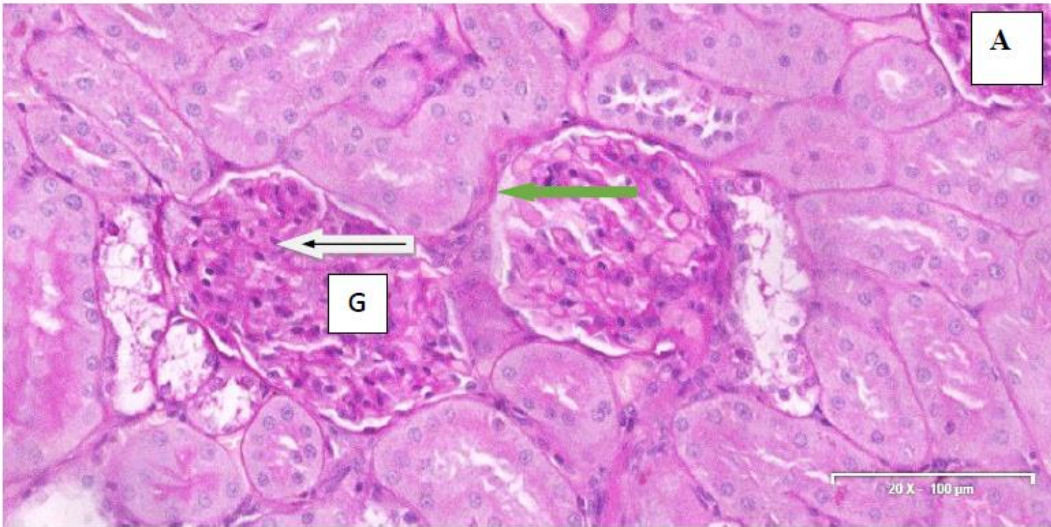


FIGURE 3. Hematoxylin and eosin (H&E)-stained kidney sections of streptozotocin-induced diabetic rats in different groups. A) In control group A (saline), the sections showed a severe distortion of the glomerular architecture, with atrophic and necrotic changes, pyknotic nuclei as well as infiltrations of mesangial spaces and interstitium. Many of the proximal and distal convoluted tubules showed hypertrophic cells and vacuolization. B) In group B (5 mg/kg CcAgNPs), there were moderate degenerative changes in the glomeruli. The mesangium and interstitium were essentially normal with cellular components. C) In group C (10 mg/kg CcAgNPs), the kidney sections showed glomeruli with Bowman's space and capillary tufts, which appeared normal compared to controls. D) The kidney sections of diabetic rats in group D (200 mg/kg *C. cassia* extract) looked normal with clearly visible glomeruli, basement membrane of the capsular wall, and mesangial tissue. G: Glomerulus; DCT: Distal convoluted tubules; PCT: Proximal convoluted tubules; White arrow: Bowman's space; Black arrow: Mesangial cells; Green arrow: Parietal layer; CcAgNPs: *Cinnamomum cassia* silver nanoparticles.



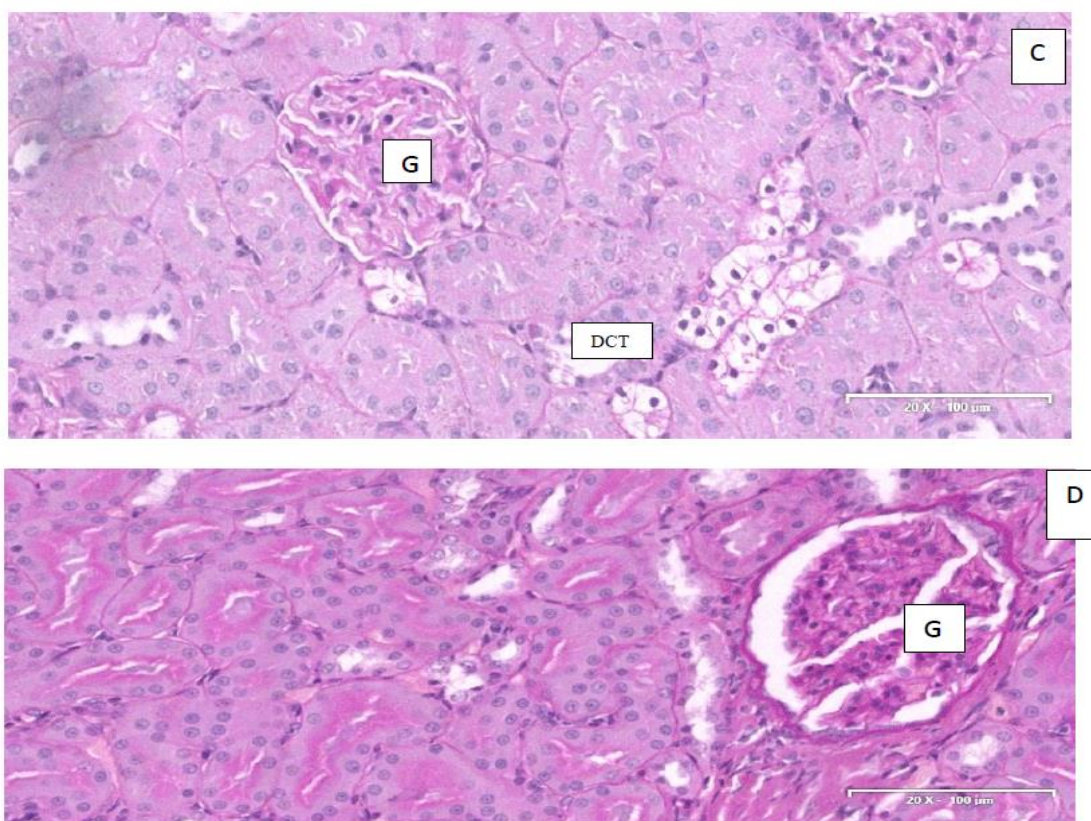


FIGURE 4. Periodic acid-Schiff (PAS)-stained kidney sections of streptozotocin-induced diabetic rats in different groups. A) The sections in control group A (saline) showed glomerular distortions and ruptured capsular wall (stained purple), thickened basement membranes, and hypocellularity in the interstitial components. B-C) In group B (5 mg/kg CcAgNPs) and C (10 mg/kg CcAgNPs), the PAS-staining intensity for glycogens was stronger; moreover the capsular walls of the glomeruli were evident in group B. The mesangial tissues were clearly delineated and interstitial tissue did not indicate any abnormalities. D) The kidney sections of group D (200 mg/kg *C. cassia* extract) showed PAS-positive glomerular capsular basement layers stained purple, indicating a normal glomerular tuft/capillary meshwork. The proximal and distal convoluted tubular cells with no abnormalities and purple-stained (glycogen)

membranes of tubules were clearly visible. Note the thickening of basement membranes in A part. G: Glomerulus; DCT: Distal convoluted tubules; PCT: Proximal convoluted tubules; White arrow: Bowman's space; Black arrow: Mesangial cells; Green arrow: Parietal layer; CcAgNPs: *Cinnamomum cassia* silver nanoparticles.

**BRIDGING
BETWEEN CHAPTERS THREE AND FOUR**

The previous chapter showed the beneficial effects of CcAgNPs on the renal tissue in type 2 diabetic rats. Additionally, the chapter displayed the positive impacts of the green synthesis silver nanoparticles on the biochemicals parameters of diabetics rats. The following chapter will be describing the safely process to synthesise silver nanoparticles using the green option.

Refer to Appendix

BRIDGING

BETWEEN CHAPTERS FOUR AND FIVE

In the previous chapter, a rapid, simple approach was applied for the synthesis of silver nanoparticles using *Cinnamomum cassia* aqueous extract. The plant extract acts both as a reducing agent as well as capping agent. This chapter was, therefore, describing the safely process to synthesise silver nanoparticles using the *Cinnamomum cassia* as a green option.

The following chapter will be focussing on the ultrastructural findings in kidneys of STZ induced diabetics rats, after 56 days of administration of CcAgNPs.

Refer to Appendix

BRIDGING

MANUSCRIPT FIVE

BETWEEN CHAPTERS FIVE AND SIX

In the previous chapter, the study was elaborating on the ultrastructural findings in kidneys of STZ induced diabetics rats, after 56 days of administration of CcAgNPs, using mainly transmission electron Microscope (TEM). The following chapter will be focussing on the stereological investigation of kidneys in the diabetic group.

Refer to Appendix

CHAPTER SEVEN

SYNTHESIS, CONCLUSION AND RECOMMENDATIONS

7.0 Synthesis

Nanotechnology as a virgin field of study has become a highly demanding branch of science with a wide range of interest because of its immense applications to engineering, sciences, pharmaceuticals, and medicine. These wide range applications have brought about advancement in all these fields of study. More importantly, in the field of Diabetology, it has facilitated the invention of oral insulin delivery system and blood sugar measurement device that holds a promising edge in improving the lives of patients suffering from diabetes mellitus (Markowitz et al., 2013). However, these great inventions have also come with their attendant and unknown consequences. Recently, some studies have documented the toxicity and hazards of major elements employed in the chemical synthetic method which have been suggested to be responsible for different adverse effects (Singh et al., 2016). This is one of the reason that is stimulating research into the use of plant-based materials as an alternative in the green synthesis process for nanomedicine.

However, there have been tremendous progress in the chemical synthetic method for nanoparticles using plant materials over decades but more significantly only in the last three decades for the reduction of metal salts, simply because plant extracts are able to reduce metal ions. The use of these plants are based on their important phytochemical components with varieties of biological activities, most importantly, anti-oxidant properties, which act to reduce the toxic effects of these elements. Consequently, this has made the use of plant extracts to synthesize nanoparticles, a very promising aspect of nanotechnology owing to their biological activities (Shanmugam et al., 2017).

Diabetes mellitus is a metabolic disease which is characterized by sustained elevated systemic sugar concentration caused by defective insulin secretion and/or action. This may be with or without attendant microvascular and macrovascular, neurological and frequent serious infectious complications secondary to deranged carbohydrate, fat and protein metabolism and impaired renal function (Daisy and Saipriya, 2012). Worldwide, type-2 diabetic nephropathy (T2DN) remains a member of indelible diseases of the vascular system that manifests in approximately 40% of patients suffering from diabetes who may then present with major end-stage kidney disease (ESKD) (Tomino et al., 2012).

Recent progress in the field of diabetes research and its interface with nanotechnology has attracted the interest of many researchers owing to the dire need to develop treatment strategies that could mitigate the complications arising from diabetes mellitus relating specifically to perturbations in the kidney. In this study, an experimental rodent model was utilized for investigating the consequences of nano-conjugate synthesized plant extract on the morphological and biochemical indices of the kidney. Streptozotocin-induced diabetes is an established paradigm for studying experimental diabetes in animal models successfully inducing sustained hyperglycemia likely due to perturbations in the redox status (Edwards et al., 2008). Streptozotocin is able to induce diabetes by a direct toxic action on pancreatic β islet-cells (Edwards et al., 2008).

Effect on blood glucose, metabolic and morphologic indices

In this study Streptozotocin-induced diabetic animals showed a statistically significant decrease ($P < 0.05$) in blood glucose levels following 56 days of successive administration of both *Cinnamomum cassia* extract and nanoparticles conjugates possibly, as a consequence of the activated release of the huge amount of glucose in the peripheral tissue (Daisy and Saipriya, 2012).

Daisy and Saipriya (2012) had previously reported a direct relationship between insulin secretion and a drop in blood glucose levels in experimentally treated animals and this study shows a 30% drop in glucose upon administration of low dose CcAgNPs with a further 50% glucose decline (10 ± 6.4 mmol/l) following administration of CcAgNPs at twice the concentration (6.1 ± 3 mmol/l). Prabhu et al. (2018) reported that glucose absorption by yeast cells increased following the use of plant leaf extract and AgNPs in a manner similar to dose-dependent. While the main underlying mechanism may be due to the enhanced passage of glucose across the cell membrane and an increase in insulin release by the β cells. Moreover, overarching regulation of type-2 diabetes mellitus and its complications are still issues of debate nevertheless, literature have linked dietary influences to the prevention and control of diabetes and its complications. A study has reported that plant extract of Cinnamon could intensify the action of insulin and reduce blood glucose Azimi et al. (2014) but the precise component remains to be identified.

The sustained elevation in blood glucose in diabetes and the consequent rise in blood urea and creatinine negatively affects the nephrons. Therefore, elevation in serum creatinine and blood urea nitrogen levels in patients suffering from diabetes mellitus is an indication of protracted high blood glucose which results to irretrievable injury to the renal functional unit (Shah et al., 2016). There is speculation in literature attributing the destruction of the functional unit of the kidney, to hyperglycemia, with subsequent to the kidney homeostatic activities. It is the duty of glomerulus, tuft capillaries located within the Bowman's capsule in the nephron of the kidney to filter the serum creatinine, which implies that glomerular filtration is the function of serum creatinine. Therefore, elevation in blood urea nitrogen and serum creatinine plasma concentration occurred subsequent to a decrease in glomerular filtration rate (GFR). Increase serum creatinine and reduced GFR are reliable indicators of kidney dysfunction. But following administration of CcAgNPs, blood glucose of diabetic rats was normalized. A recent study reported a significant increase in the levels of uric acid, serum creatinine, and serum urea, were observed in diabetic untreated rats when compared with non-diabetic rats, also a significant decrease in albumin and protein levels was noticed in all diabetic treatment groups given AgNPs (Prabhu et al., 2018).

A study by BarathManiKanth et al. (2010), shows that the level of creatinine - function, was also significantly decreased comparably in diabetic rats administered Ag-nanoparticles which were similar in size and type to that used in this study. In addition, serum creatinine and blood urea nitrogen levels in rats treated with plant extracts or with AgNPs were within the healthy values (Prabhu et al., 2018). The above results corroborate with our findings, which revealed, a significant decrease in urea (34 ± 4.6 mg/dl and 27 ± 1.5 mg/dl, $P < 0.05$) and also a significant decrease of creatinine (3.1 ± 0.83 mg/dl, and 2.0 ± 0.40 mg/dl, $P < 0.05$) upon administration of both low and high doses of CcAgNPs.

Qualitative histopathological assessment of the kidney tissues showed hypertrophy of the renal corpuscles with an increase of the Bowman capsular space in the diabetic control group which were mitigated following adjuvant treatment with CcAgNPs. Stereological evaluations also revealed a larger diameter of the Bowman capsular space in the diabetic control (20 ± 0.15 μ m) against treated diabetic rat (11 ± 1.2 μ m) and this result was significantly different at $P < 0.05$. Bowman capsule of the renal corpuscle of treated animals (CcAgNPs) demonstrated that diameter was totally different to values in control at a p-value of 0.05 with (104 ± 6596 μ m against 132 ± 7807 μ m).

In addition, electron microscopic evaluations showed thickening of the basement membrane as revealed in the H & E as well as special staining (with Masons trichrome) in diabetic rats, but these perturbations were ameliorated in the treated (CcAgNPs) groups. The urinary space, also known as Bowman's space is a space enclosing the lobules and loops of the glomerulus within the substance of renal corpuscle which serves as exit for glomerular plasma filtrate as it leaves via filtration membrane. The membrane is formed by the union of basement membrane of glomerular epithelium and endothelial basement membrane located outside the capillary endothelium.

The thickening of the filtration membrane which was observed in diabetic rats under various qualitative (H & E, PAS, MT) and quantitative tools (stereology and TEM) suggests that DM could decrease the rate of filtration by obstructing the free flow of fluid.

Electron microscopic evaluations revealed that a decrease in filtration is caused by an increase in diameter of glomerular basement membrane as seen in STZ induced diabetic rats, compared to treated Cc and (CcAgNPs) groups. Several morphological studies on the glomerular filtration barrier in different disease states have been linked to disorders of the kidney (de Souza et al., 2016). A recent study described the inability of the endothelial layer to perform its fenestration activity has been observed in various medical conditions (de Souza et al., 2016). Fewer fenestrae were observed in the endothelial cells over the basement membrane and the urinary space on transmission electron microscopy comparably to those observed in healthy condition (de Souza et al., 2016). Transmission electron microscopy can be employed to easily view the layers of the glomerular basement membrane. For the fact that the effectiveness of the filtration barrier totally depends on its diameter, have made it generate a wide range of research interest (Chiang and Inagi, 2010).

Furthermore, several disease conditions are responsible for different abnormalities seen in the structure of the basement membrane. This condition of membranous nephropathy with thickened glomerular basement membrane was corrected positively by the administration of Cc and CcAgNPs, after 56 days of the experiment.

Ultrafiltration is an important process by which blood is filtered in the Bowman's capsule. The normal filtration rate is in 80 folds of daily blood volume which is amount to 125 ml/min. A decreased GFR may be a sign of renal condition linked to diabetes.

Numerous disorders and diseases can be caused by the malfunctioning glomerulus, as seen in diabetic glomerulosclerosis, acute proliferative and glomerulonephritis (D'amico and Bazzi, 2003). There are three main changes in the glomeruli histological structure of patients suffering from diabetic nephropathy. The first change is the enlargement of the mesangial matrix caused by high blood glucose because of increasing accumulation of matrix proteins. The next has to do with the diameter of the glomerular basement membrane. The last which have been reported to be caused by intraglomerular hypertension is glomerular sclerosis. Researches have suggested that these histological changes seen in the glomeruli structure of diabetic nephropathy have homogenous prognostic benefits (de Souza et al., 2016). Microalbuminuria also a sign of nephron lesion which is an indication of the sudden changes in the kidney structure and beginning of kidney disease manifestation and its complications.

The main responsibility of the functional unit of the kidney, the nephron is to ensure adequate quantity of the circulatory system and blood purification. Within the substance of the nephron is the glomerulus which is a tuft of capillaries of approximately 200 μm formed by afferent arterioles. The renal internal structures disarrangement or disruption will subsequently impact the nephrons and its function that causing the death of this particular group of nephrons. The management of blood glucose level is necessary to limit progressive renal dysfunction in diabetes. The interplay between the interstitium, the tubule and the glomerulus inside the nephron are possible clue in comprehension of multiple disorders as that of diabetic nephropathy.

Recently, evidence have supported that tubular damage, has a vital implication in diabetic nephropathy development and progression, moreover, the extent of the injury of tubulointerstitial have been linked to different consequences on renal outcome in diabetic nephropathy (Hwang et al., 2017).

The mechanisms behind the tubular damage have been described as multiplex. The epithelium lining in the tubules cells is vulnerable to high blood glucose, through tubular reabsorption of sugar in a hyperglycemic state (Hwang et al., 2017). Additionally, chronic hypoxia and local renin-angiotensin system have been reported to contribute to the progression of tubular damage. A recent study revealed that albuminuria may be the cause of fibrosis and tubular inflammation as a result of direct influence on renal tubular cells (Hwang et al., 2017). The proximal tubule, especially, is at risk of these metabolic and hemodynamic imbalances. Some previous researchers have reported increased in diameter of the proximal tubular basement membrane in normoalbuminuria in diabetic conditions (Brito et al., 1998).

In this study, the kidney of rats in diabetic control was distinguished by obvious fibrosis in the tubular interstitium, as well as manifestations of tubular expansion, atrophy in affected cells. Classically, the glomeruli have been described as the key region of damage in diabetic nephropathy and albuminuria have been considered a major prognostic tool. Lately, various biologic markers with respect to tubular damage and inflammation have been identified as powerful indicators of renal outcome (Stephen et al., 2003, N Moresco et al., 2013).

The histopathology analyses demonstrated various lesions of proximal tubules such as an increase of diameters, epithelial and brush borders denudations which were confirmed by the stereological assessments ($22 \pm 6.5 \mu\text{m}$), with loss of the brushes, but upon administration of the CcAgNPs,

there was a remarkable mitigation of the tubular lesions which was also confirmed by the stereological investigation ($13.5 \pm 3.5 \mu\text{m}$) and significantly different at p-value of 0.05.

Additionally, distal tubules showed disruptions and dilations with an increase in diameter in the diabetic control group. The stereological report showed values at $36 \pm 8.8 \mu\text{m}$ with normalization of the tubules upon administration of CcAgNPs to $24 \pm 7.5 \mu\text{m}$. Urinalysis carried out on STZ-induced diabetic rats showed the presence of ketones, albumins, proteins, urea, creatinine, and glucose. But upon treatment with CcAgNPs, there was restoration in some of these parameters. Our study thus revealed that albumin excretion is significantly increased in the diabetic when compared with control groups ($P < 0.05$), and treated groups. Proteinuria level after STZ-induced diabetes resulted in significant increased, versus controls and treated diabetic groups at $P < 0.05$.

Previous studies propose that tubular damage is an important factor in the causes of diabetic kidney disease in vulnerable patients (Hwang et al., 2017). In the tubules, there are broad changes that predispose to tubular damage, reabsorption of protein droplets and atrophy. One and most important alteration, which is usually more than the pathogenesis of tubular atrophy is the increase in diameter of the basement membranes of atrophic tubules. The reason why it has been noticed that, at the beginning of the diabetic nephropathy, there may be increased in size of the kidney as a result of hypertrophy and hyperfiltration, as there will be atrophy with diminution of size and loss of cortico-medullary differentiation at a later stage.

Additionally, other important morphological changes may occur in the diabetic kidney, especially in the renal corpuscles called, capsular lesions drop (de Souza et al., 2016).

This is associated to an initial increase in the level of glomerular filtration rate which has been reported to be crucial to the causes and development of kidney disease in diabetes researches, but there is little or no evidence to substantiate that glomerular hyperfiltration is a contributing factor to the progression of kidney disease in human.

The renal tubule receives plasma filtrate from the glomerulus and processes it into the urine. Each tubule is differentiated into several specialized segments. Different aspects of filtrate reabsorption are localized in different segments. In the cortex, the proximal tubule reabsorbs most minerals and other nutrients from the tubular fluid and transform them into the blood within the peritubular capillaries. The loop of Henle dips into the medulla where it greatly assists to establish the hypertonic environment of medullary interstitial fluid. The distal convoluted tubule changes direction to move toward the juxtaglomerular apparatus of the corpuscle from which the tubule arose. Finally, the collecting duct leads back through the medulla to drain into the pelvis. Variation in the structure of tubular epithelial cells is mainly associated with the functional differentiation of the different tubular segments. Subsequently, it gives the microscopic appearance of the tubules. Therefore, proximal tubules disorders will lead to a failure to reabsorb whereas the disorders of the distal will cause a failure to secrete and this could explain why the urinalysis outcomes of STZ-induced diabetic rats showed the severe presence of ketones, albumins, proteins, urea, creatinine, and glucose. But, upon treatment from CcAgNPs, there was the restoration of the tubules ultrastructure. Previous findings suggest that tubular injury plays a key role in the pathogenesis of DKD in high-risk patients (Hwang et al., 2017).

Effect on oxidative stress and lipid peroxidation in renal tissues

During the last 25 years, a large body of experimental evidence has accumulated from pharmacological intervention studies that suggest an important role for ROS in numerous pathophysiological processes. While a variety of chemical mechanisms of reactive oxygen-induced damage to lipids, proteins, and DNA is fairly well understood; the molecular pathology of oxidant stress-induced tissue injury in vivo remains unclear in many cases (Azu, 2012).

Oxidative stress (OS) results due to an imbalance between the production of ROS and the defense systems that functions to scavenge or destroy them (Azu, 2012). Gonadal dysfunction has been long documented since the early days of the AIDS pandemic Brown et al. (2013) with many studies attributing OS as playing a major role in the pathogenesis of AIDS (Papadopulos-Eleopoulos, 1988). With the stabilization of global prevalence however, many clinical researchers are pointing to the use of antioxidant treatment as a strong means of neutralizing or suppressing the progression of AIDS. Nonetheless, drug-induced OS is implicated as a mechanism of toxicity in numerous tissues and organ systems with HAART also well characterized to mediate its effects via OS mechanisms (Fojtu et al., 2017).

In this study despite exposure to silver nanoparticles (CcAgNPs) at both high (10mg/l) and low (5mg/l) concentrations, GSH antioxidant levels were similar in both treated groups and controls. In contrast, Adeyemi and Faniyan (2014) reported significantly decreased levels of GSH upon administration of silver nanoparticles. We may advocate, that GSH levels, showed a variation between our study and the previous investigation are mainly linked to the concentration of the silver nanoparticles that were administered to the rats. There are several previous reports that claim a reduced level of GSH in complicated diabetes (Rahal et al., 2014). A decreased in GSH level may be one of the factors in the oxidative DNA damage in type 2 diabetic nephropathy. It is hypothesized that maintenance of GSH redox state may be a new option of therapeutic avenue to protect diabetic patients against some intracellular bacterial pathogens (Tiwari et al., 2013).

The decrease in SOD activity may lead to an increase in the level of superoxide radicals which will cause the inactivation of GPx. It was reported that an increase in CAT activity, is to overcome the damaging effect of erythrocyte membrane from oxidative attack. There is a compensatory increase in CAT activity besides GPx in the cell. CAT disposes off the H₂O₂ formed in the cell so that fragility of red blood cells (RBC) is maintained.

The increased CAT activity in diabetes is an indication of the increased production of peroxide radicals (Margină et al., 2013). It is known that Glutathione (GSH) is an antioxidant found in plants, animals, fungi, and some bacteria and archaea.

Reactive oxygen species such as free radicals, peroxides, lipid peroxides, and heavy metals cause damage to major cellular components that may be prevented by Glutathione. It is a tripeptide composed by gamma peptide linkage between the carboxyl group of the glutamate side chain and the amine group of cysteine, and the carboxyl group of cysteine is attached by a normal peptide linkage to a glycine (Valko et al., 2006). Nearly all living cells exposed to oxygen, need superoxide dismutase (SOD), as the important antioxidant defense. This is an enzyme that alternately causes the dismutation (or partitioning) of the superoxide (O_2^-) radical into either ordinary molecular oxygen (O_2) or hydrogen (H_2O_2). Superoxide is generated by-product of oxygen metabolism and when it is not regulated, leads to many types of cell damage. Hydrogen peroxide is also damaging and the catalase (enzyme) causes degradation of the hydrogen peroxide. The Catalase is a common enzyme found in nearly all living organisms exposed to oxygen (such as bacteria, plants, and animals). Water and oxygen derived from the decomposition of hydrogen peroxide caused by catalase. This is a very important enzyme which is protecting the cell from oxidative damage by reactive oxygen species (ROS).

The decrease in SOD activity may lead to the inactivation of GPx, which is provoked by the increased level of superoxide radicals. It was reported that an increase in CAT activity, will assist to overcome the damaging effect of erythrocyte membrane from oxidative attack. There is a compensatory increase in CAT activity besides GPx in the cell. CAT disposes off the H_2O_2 formed in the cell so that fragility of red blood cells (RBC) is maintained. Increased production of peroxide radicals is associated with an increase in CAT activity in diabetes (Margină et al., 2013). The up-regulation in glutathione levels in this experiment possibly supports its antioxidant role/properties. Phenolic has been recognized as a powerful countermeasure against lipid peroxidation, among many classes of compounds. They behave by scavenging free radicals and alleviating the lipid peroxidative side chain, Azu et al. (2010) through their hydrogen-donating ability.

It was reported that an increased levels of renal malondialdehyde (MDA), and decreased levels of glutathione (GSH), as well as SOD activity, were observed in diabetic rats ($P < 0.001$) as compared with treated rats (Jain and Saha, 2017). Chronic hyperglycemia results in oxidative stress; MDA level, which is an index of endogenous lipid peroxidation was found to be increased significantly in the kidney tissue of diabetic rats reflecting increased oxidative stress (Baynes, 1991). Various antioxidants were found to be effective in the treatment and/or the prevention of diabetic complications including diabetic nephropathy (Bhat et al., 2017). This is suggesting that the generation of free radicals has a key role in the oxidative stress and thus in the pathogenesis of DN. In their research, they have noticed a significant increase in the oxidative markers such as MDA, while a decrease in the activity of endogenous antioxidants, that is, SOD and GSH in diabetic kidney was also observed.

The current study showed MDA (0.60 ± 0.15) levels in treated rats, significantly different ($P < 0.05$), vis a vis of control groups (1.4 ± 0.22), following both high and low dose concentration of CcAgNPs, indicating tissues damage, as it is measuring the lipid peroxidation in the cells and the tissues. It is known that an increased oxidative stress is one of the known culprits in the development of nephropathy (Mezzetti et al., 2000). Researchers sought to assess the levels of oxidative stress markers like Malondialdehyde (MDA) and SOD and they revealed that the oxidative stress was increased because of increase of the lipid peroxidation and increases the SOD level (Mezzetti et al., 2000). The current results are also supported by Prabhu et al. (2018) who revealed that there was reparation of the liver tissue in groups treated with piper plant leaf extract and plants-AgNPs when compared to control group, subsequent to restoration of the activity of the lipid peroxidation markers.

BarathManiKanth et al. (2010) also demonstrated that Gold nanoparticles possess anti-oxidative effects, after treatment of diabetic rats at a dose of 2.5 mg/kg. However, imbalanced MDA and GSH levels were reported in type 2 DM patients with microalbuminuria (Ozdemir et al., 2005).

In this study, we re-confirmed that CcAgNPs treatment could protect against an early stage of diabetic nephropathy in the rats with diabetes induced by STZ. Our data revealed, CcAgNPs reduced albuminuria and alleviated renal histopathological injury in diabetic rats. The coupled oxidant/antioxidant balance was observed as a decrease in MDA and an increase in GSH in kidneys of STZ-induced diabetic rats treated with CcAgNPs.

Diabetic nephropathy remains an oxidative-stress related microvascular disease (Roman-Pintos et al., 2016). Hyperglycemia is known to cause oxidative stress that is due to disturbance of the oxidant/antioxidant balance, playing a critical role in kidney injury. The antioxidant treatment plays an important role in optimizing renoprotection in diabetes or another kidney disease (Forbes and Cooper, 2013). In the present study, CcAgNPs and Cc administration was shown to decrease MDA levels and increase GSH levels due to their antioxidant properties suggesting that CcAgNPs and Cc could reduce oxidative stress-mediated glucose-induced renal injury. Various studies have postulated that lipid peroxidation levels increase in clinical and experimental diabetes (Belka, 1998); (Newsholme et al., 2007).

In this study, the MDA concentration was used as an index of lipid peroxidation (and thus oxidative stress status) in diabetic rats. A significant increase of MDA concentration in serum and tissues of the diabetic animals compared to controls was noted. Our results are corroborated by reports of increased lipid peroxidation in serum and kidney of animals with experimental diabetes (Kinalski et al., 2000). This phenomenon is possibly caused by decreased activity of antioxidant enzymes, which causes the uncontrolled generation of free radicals, and the subsequent generation of lipid hydroperoxides (Kinalski et al., 2000).

Liver disease is suspected as a result of biochemical abnormalities of liver function. AST and ALT can serve as markers of hepatocellular injury (Limdi and Hyde, 2003). In our study, AST, ALT, ALP, and albumin levels were not significantly different from control. The adverse effects of substances on animal physiology can vary from minor anatomical changes, such as reduced weight gain, small physiological alterations, changes in the levels of hormones in the blood, to severe effects leading to organ failure and death (Peter et al., 2018). In this current study, Liver enzymes, AST (9.5 ± 4.4) and ALT (87 ± 0.28), was significantly decreased by 8% and 10%, respectively, following administration of a low and high dose of CcAgNPs, compared to controls. Results obtained of the 'restorative' effect of nanoparticles after assessing the metabolic enzymatic markers are confirming the ability of nanoparticles to protect the major organs (kidneys and liver) from damage due to hyperglycemia-induced oxidative stress (BarathManiKanth et al., 2010). This is an indication that CcAgNPs may possess strong positive effects on the markers of the damaged liver when compared to controls. It is in agreement with a study performed by previous scientists and may be attributed to the antioxidant properties inherent in Cinnamon (Amorati et al., 2013).

The liver, an organ, is one of the most amazing organs in the human body with its ability to regenerate itself. Because the functions of the liver are so wide-reaching, it is easy to see how the dysfunction of the kidney affects the function of the liver in many different ways. The increasing deterioration of glomeruli in diabetes causes an increase in liver enzymes production (Glover, 2012).

Kidneys play also an important role in the detoxification process. Kidneys are master regulators and act as a massive filtration system. They are regulating fluid and electrolyte (mineral) balance in the body: this is vital for body cells to be able to perform their functions. Subsequently, they are controlling blood pressure and regulating the body's pH or acid-alkaline balance: even small variances in pH can result in death. In addition, they are a major detoxification organ.

In fact, the kidneys receive and filter about 1200 ml of blood per minute - about a quarter of our total blood flow. Due to this combination of tasks, the kidneys also assist in controlling excessive blood glucose and mineral imbalances.

Liver dysfunction is a known risk factor in diabetes mellitus and diabetic patients are at further risk of developing liver disorders (Adiga et al., 2016). In addition, there is a direct positive correlation between elevated liver enzymes and reduced glomerular filtration (Suchy-Dacey et al., 2016). Our report agreed with previous studies cited above, that upon administration of CcAgNPs, there was an improvement in renal functions as seen clinically, by the measured parameters of urea and creatinine as well as improved liver function clinically expressed via the liver enzymes ALT and AST. These results demonstrated, CcAgNPs ability to limit organ dysfunction in diabetic nephropathy and have hepatocellular protective effects.

The association between liver and renal disease in type II DM have been reported by authors (Adiga and Malawadi, 2016) that, it is important to explore therapeutic measures able to delay the progression of liver and renal conditions associated with DM. This is in agreement with Kouame et al. (2018), who revealed that *Cinnamomum cassia* silver nanoparticles is capable to alleviate biochemical and histological disorders within diabetics' kidneys and liver, which was published under the title "Histologic and biochemical effects of Cinnamomum cassia nanoparticles in kidneys of diabetic Sprague-Dawley rats". These results concur with the study of (Adiga and Malawadi, 2016) who compared the liver profile of diabetic cases with controls and noted a significantly high total bilirubin, ALT and AST in diabetics. The statement was also supported by (Al-Jameil et al., 2014) suggesting an elevation of liver enzymes in diabetic conditions.

There is indeed positive association which was observed between liver enzymes and glomerular function, supporting the protective role of liver enzymes and subsequently indicating a significant correlation between renal and liver disease in DM (Adiga and Malawadi, 2016). The liver disease bears an association with diabetic nephropathy because of the interconnection between renal functions and ALT/AST levels as revealed in our study. It is opined that screening and treating liver conditions might be useful in prolonging the development and progression of diabetic nephropathy.

A retrospective study performed by a team of researchers to know the association between liver disease and renal disease in type II DM reported that risk of liver conditions is common in diabetic nephropathy attributable to high liver fat content. However, the exact pathophysiology factors involved was not known (Adiga and Malawadi, 2016). Continuous liver and kidney conditions may lead to cell death.

Recent studies have revealed that program cell death and necroptosis cell deaths are the important mechanisms that lead to renal tubular cell shrinkage and chronic kidney disease progression in complicated STZ induced diabetic rat (Zhu et al., 2015; Yang et al., 2001). However, the kinetics of cell death during the early and intermediate stages of constantly recurring kidneys disease has remained unclear (BarathManiKanth et al., 2010).

However, the mechanism by which Cc and CcAgNPs exert their anti-diabetic activity was elaborated and is probably the result of its effect at different levels of the insulin-signaling pathway. A possible underlying mechanism by which the plant material controlled the increase of blood glucose levels in diabetic rats is potentiation of pancreatic secretion of insulin from β cells in the islets of Langerhans (Hassan et al., 2008). The cellular response to insulin is acting via insulin receptor, which is a tetrameric protein consisting of two identical extracellular α -subunits that bind insulin as well as two identical transmembrane β -subunits that have intracellular tyrosine kinase activity (Goldfine, 1987). When insulin binds to the α -subunit of the receptor, the β -subunit tyrosine kinase will then be activated, resulting in autophosphorylation of β -subunit tyrosine residues (Byon et al., 1998). Increase of the insulin sensitivity is triggered by increased autophosphorylation and decreased dephosphorylation, of the insulin receptor.

Cinnamon causes an increase in the expression of Peroxisome proliferator-activated receptor thereby increasing insulin sensitivity and decrease blood glucose, subsequently alleviate kidney complications in diabetes (Xie et al., 2011). It can, therefore, be seen that biologically synthesized silver nanoparticles are able to affect the renal system of diabetic rats in such a manner as to limit and partially restore some of the diabetic complications as seen in blood urea and creatinine levels which are indicators of renal function. The continuous control of blood glucose level is necessary to limit progressive renal dysfunction in diabetes. In this investigation, Cc-AgNPs demonstrated its power to control blood glucose levels along with blood creatinine and urea which are known to limit and treat diabetic nephropathy. The postulated mechanism of its beneficial action is mediated through the free radicals scavenging mechanism.

Moreover, certain researchers also, proved that nanoparticles have the power to prevent oxidative stress-mediated ROS production using various types of mechanisms, because its immense aptitude to inhibit inflammatory response created by oxidative stress resulted by toxic elements to the systems, because of their antioxidant effects (Onizawa et al., 2009). Previous studies reported that the foremost and dominant event responsible for the triggering of several mechanistic involved in the pathogenesis of diabetic complications is possibly a single hyperglycemia-induced process of an excess of superoxide from the mitochondrial electron transport coupling (Ceriello, 2003). Thus, results over the ability of nanoparticles in the destruction of ROS induced at long-standing hyperglycemic conditions cited by BarathManiKanth et al. (2010), thereby bringing forth the balanced level of the anti-oxidant protection system of nanoparticles and confirmed the therapeutic application of nanoparticles as a promising antioxidant.

These results are underpinned by findings which advocated the non-cytotoxic effect of nanoparticles, and the tendency of nanoparticles to reduce the generation and release of reactive oxygen and reactive nitrogen species. In addition, they do not prompt secretion of pro-inflammatory cytokines TNF- α and IL1- β , making them suitable candidates for nanomedicine (Carnovale et al., 2019). The most beneficial intervention materials should ideally restore insulin resistance, reverse renal impairment and tissue damage and additionally prevent pancreatic β -cell dysfunction.

Therefore, the overall objective of this study was to investigate the extent to which CcAgNPS meets this ideal by examining the histomorphological and biochemical effects of the substance. Ideally, substitute therapies should generate a commensurate degree of efficacy compared to conventional drug therapy, but without the negative side effects that are often linked with them (Vasu et al., 2003).

Cinnamon activates the phosphorylation of the insulin receptor β -subunit on adipocytes as well as other insulin receptors (Abdul et al., 2014). Glucose transporter type 4, major glucose transporter in the musculoskeletal system, is also under control of insulin. It is well known that insulin promotes the translocation of GLUT-4 from the intracellular compartment to the cell membrane (Sheppard and Kahn, 1999). In diabetes mellitus because of the absence or insufficient sensitivity to insulin, GLUT 4, may be decreased. Researchers, therefore, reported a significant increase in the expression of GLUT 4 receptor under the administration of cinnamon and CcAgNPs, which increase significantly the use of glucose in skeletal muscle cells and causing hypoglycemia.

Recently it was also, reported that cinnamon extracts and CcAgNPs ameliorate type 2 diabetes and its complications by inducing GLUT4 translocation via the AMPK signaling pathway (Medagama, 2015). Therefore, the activation of AMPK induces the translocation of GLUT4 to the plasma membrane, various studies have demonstrated that AMPK and its signaling pathways are potential molecular targets in the development of drugs for the treatment of type 2 diabetes and its complications (Shen et al., 2014). CcAgNPs increases the amount of GLUT4 receptors as well as the receptors of Insulin and Insulin Receptor substrates, thereby causing the entry of glucose into cells.

They demonstrated that extracts of *Cinnamomum cassia* increased the production and translocation to the plasma membrane of the GLUT 4 in adipose tissue and muscle in a dose-dependent manner (Shen et al., 2010). Others, demonstrated a similar finding but quantified the effect by demonstrating an increase of the membrane translocation of GLUT4 from 42.8 % to 73.1 % in cinnamon and Cinnamon silver nanoparticles treated rats when compared to healthy controls, subsequently decrease blood glucose in experimental rats, which is in accord with our finding (Anand et al., 2010). Glucose transporter-1 (GLUT-1) is a receptor found on mammalian cells that is responsible for basal glucose uptake into cells. The specific mechanism of activation of this receptor is poorly understood. It was demonstrated a dose-dependent reduction of serum insulin concentrations and an increase in glucagon-like peptide 1 (GLP-1) under the treatment of cinnamon (Plexopathy, 2009).

Investigations into disease pathways and patterns have hugely expanded, with the majority of the work performed on animal models (Wall and Shani, 2008). This is because the biochemical mechanisms in mammals are largely preserved, enabling researchers to scientifically assume the outcome in humans (Wilson, 2011). Animal model scenario thus plays a significant role as the foundation for good research in human diseases, such as diabetic nephropathy. Thioredoxin-binding protein-2, is the endogenous inhibitor of cellular TRX, inactivating its antioxidative activity by binding to the redox-active cysteine residues. Previous studies revealed that overexpression of TXNIP was a major contributor to hyperglycemia-induced oxidative stress in kidney cells (Yoshihara et al., 2010).

A recent study showed that TXNIP was upregulated by (Hyperglycaemia) HG in mesangial cells, and knockdown of TXNIP reversed the hyperglycemia-induced reduction of TRX function, inhibited HG-induced apoptosis and ROS generation (Lee et al., 2013). It was also found that Mitochondria-targeted, significantly inhibited TXNIP system in diabetic complicated and mesangial cells under hyperglycemia condition. CcAgNPs will subsequently, act on Thioredoxin through a binding system to decrease the blood glucose level in diabetic rats and mitigate renal complications.

The additional hypothesis that lies on the antioxidant effect of *Cinnamomum cassia* silver nanoparticles is their synergy with the thioredoxin, a highly conserved thiol reductase that reacts over an internal inhibitor, thioredoxin-interacting protein (Txnip), and greatly responsible for the antioxidative mechanism through cellular redox balance (BarathManiKanth et al., 2010).

7 1 Conclusion

Silver nanoparticles are known for their immense applications in the field of therapeutics and diagnosis, especially when they are subjected to green synthesis. In the present investigation we have established the anti-oxidative and anti-hyperglycemic activities of *Cinnamomum cassia* silver nanoparticles (CcAgNPs) and of *Cinnamomum cassia* extracts, in Streptozotocin-induced diabetic Sprague-Dawley rats, through the inhibiting ROS over-production under long period hyperglycemic conditions, scavenging free radicals; thus causing the rising of the anti-oxidant protection enzymes. CcAgNPs nanoparticles have shown for their non-toxic and preventive effects over kidneys, without inducing any lethal effects in Sprague-Dawley rats model, thereby, achieving a support control over the diabetic complication. These potential applications of green synthesized silver nanoparticles in averting oxidative stress and their side effects, induced under hyperglycemic conditions has opened up a way for a new resource of cost economic alternative in the treatment and management of diabetic and its complications, such as diabetic nephropathy.

7.2 Recommendations

In view, of the insufficiency from this study, it is recommended that further exploration of the specific molecular pathways and their impacts in hyperglycemic conditions should be engaged.

Thus, a detailed, investigation, over the signaling mechanism, such as thioredoxin (Trx) and GLUT4, behind the anti-oxidative effect of Cinnamomum cassia silver nanoparticles to probe their anti-hyperglycemic role in diabetic conditions, would open door to the strong quest behind the clinical implication of green silver nanoparticles in diabetic nephropathy treatments, in particular and may render it uniquely medical beneficial as an agent of therapeutic choice for diverse complications, in general. treatments, in particular and may render it uniquely medical beneficial as an agent of therapeutic choice for diverse complications, in general.

References

- ABDUL MAJID, F., TEH, L., SAYID ABDULLAH, S., ADAWIYAH AHMAD, R., TAHER, M. & ABD WAHID, M. Preclinical evidence of Malay traditional herbal supplement for diabetes. XXIX International Horticultural Congress on Horticulture: Sustaining Lives, Livelihoods and Landscapes (IHC2014): V World 1125, 2014. 255-262.
- ADIGA, U. & MALAWADI, B. N. 2016. *Association of Diabetic Nephropathy and Liver Disorders*.
- ADEYEMI, O. S. & FANIYAN, T. O. 2014. Antioxidant status of rats administered silver nanoparticles orally. *Journal of Taibah University Medical Sciences*, 9, 182-186.
- AL-JAMEIL, N., KHAN, F. A., ARJUMAND, S., KHAN, M. F., TABASSUM, H. J. I. J. O. C. & PATHOLOGY, E. 2014. Associated liver enzymes with hyperlipidemic profile in type 2 diabetes patients. 7, 4345.
- AMORATI, R., FOTI, M. C., VALGIMIGLI, L. J. J. O. A. & CHEMISTRY, F. 2013. Antioxidant activity of essential oils. 61, 10835-10847.
- ANAND, P., MURALI, K., TANDON, V., MURTHY, P. & CHANDRA, R. 2010. Insulinotropic effect of cinnamaldehyde on transcriptional regulation of pyruvate kinase, phosphoenolpyruvate carboxykinase, and GLUT4 translocation in experimental diabetic rats. *Chemico-biological interactions*, 186, 72-81.
- AZIMI, P., GHIASVAND, R., FEIZI, A., HARIRI, M. & ABBASI, B. J. T. R. O. D. S. R. 2014. Effects of cinnamon, cardamom, saffron, and ginger consumption on markers of glycemic control, lipid profile, oxidative stress, and inflammation in type 2 diabetes patients. 11, 258.
- AZU, O., DURU, F., OSINUBI, A., OREMOSU, A., NORONHA, C., ELESHA, S. & OKANLAWON, A. 2010. Histomorphometric effects of *Kigelia africana* (Bignoniaceae) fruit extract on the testis following short-term treatment with cisplatin in male Sprague–Dawley rats. *Middle East Fertility Society Journal*, 15, 200-208.
- AZU, O. J. J. A. C. R. 2012. The male genital tract in the era of highly active antiretroviral therapy (HAART): implication for antioxidant therapy. 3, 2.
- BARATHMANIKANTH, S., KALISHWARALAL, K., SRIRAM, M., PANDIAN, S. R. K., YOUN, H.-S., EOM, S. & GURUNATHAN, S. 2010. Anti-oxidant effect of gold nanoparticles restrains hyperglycemic conditions in diabetic mice. *Journal of nanobiotechnology*, 8, 16.

- BAYNES, J. W. 1991. Role of oxidative stress in development of complications in diabetes. *Diabetes*, 40, 405-412.
- BELKA, I. C. 1998. Free radical activity, lipid peroxidation and antioxidant status in diabetes mellitus.
- BHAT, S., MARY, S., GIRI, A. P. & KULKARNI, M. J. 2017. Advanced glycation end products (AGEs) in diabetic complications. *Mechanisms of vascular defects in diabetes mellitus*. Springer.
- BRITO, P. L., FIORETTO, P., DRUMMOND, K., KIM, Y., STEFFES, M. W., BASGEN, J. M., SISSON-ROSS, S. & MAUER, M. J. K. I. 1998. Proximal tubular basement membrane width in insulin-dependent diabetes mellitus. 53, 754-761
- BROWN, P. K., QURESHI, A. T., MOLL, A. N., HAYES, D. J. & MONROE, W. T. 2013. Silver nanoscale antisense drug delivery system for photoactivated gene silencing. *ACS nano*, 7, 2948-2959.
- BYON, J. C., KUSARI, A. B., KUSARI, J. J. M. & BIOCHEMISTRY, C. 1998. Protein-tyrosine phosphatase-1B acts as a negative regulator of insulin signal transduction. 182, 101-108.
- CARNOVALE, C., BRYANT, G., SHUKLA, R. & BANSAL, V. J. A. O. 2019. Identifying Trends in Gold Nanoparticle Toxicity and Uptake: Size, Shape, Capping Ligand, and Biological Corona. 4, 242-256.
- CERIELLO, A. 2003. New insights on oxidative stress and diabetic complications may lead to a “causal” antioxidant therapy. *Diabetes care*, 26, 1589-1596.
- CHIANG, C.-K. & INAGI, R. J. N. R. N. 2010. Glomerular diseases: genetic causes and future therapeutics. 6, 539.
- DAISY, P. & SAIPRIYA, K. 2012. Biochemical analysis of Cassia fistula aqueous extract and phytochemically synthesized gold nanoparticles as hypoglycemic treatment for diabetes mellitus. *International journal of nanomedicine*, 7, 1189.
- D'AMICO, G. & BAZZI, C. J. K. I. 2003. Pathophysiology of proteinuria. 63, 809-825.
- DE SOUZA, D. B., GREGÓRIO, B. M., BENCHIMOL, M. & DE MORAIS NASCIMENTO, F. A. 2016. Evaluation of the glomerular filtration barrier by electron microscopy. *Modern Electron Microscopy in Physical and Life Sciences*. IntechOpen.
- EDWARDS, J. L., VINCENT, A. M., CHENG, H. T., FELDMAN, E. L. J. P. & THERAPEUTICS 2008. Diabetic neuropathy: mechanisms to management. 120, 1-34.

- FOJTU, M., GUMULEC, J., STRACINA, T., RAUDENSKA, M., SKOTAKOVA, A., VACULOVICOVA, M., ADAM, V., BABULA, P., NOVAKOVA, M. & MASARIK, M. J. C. D. M. 2017. Reduction of doxorubicin-induced cardiotoxicity using nanocarriers: a review. 18, 237-263.
- FORBES, J. M. & COOPER, M. E. 2013. Mechanisms of diabetic complications. *Physiological*
- GLOVER, D. A. 2012. *The effects of dietary supplementation with Gum arabic on blood pressure and renal function in subjects with Type 2 diabetes mellitus*. Cardiff University.
- GOLDFINE, I. D. 1987. The insulin receptor: molecular biology and transmembrane signaling. *Endocrine Reviews*, 8, 235-255.
- HASSAN, Z., AHMAD, M. A. A. M., NAIDU, S. R., KUMAR, G. & UMACHIGI, S. P. 2008. Hypoglycaemic effects of aqueous extract of *Gynura procumbens*. *Pharmacologyonline*, 1, 30-50.
- HWANG, S., PARK, J., KIM, J., JANG, H. R., KWON, G. Y., HUH, W., KIM, Y.-G., KIM, D. J., OH, H. Y., LEE, J. E. J. J. O. D. & COMPLICATIONS, I. 2017. Tissue expression of tubular injury markers is associated with renal function decline in diabetic nephropathy. 31, 1704-1709.
- J, S., SHANMUGAM, R. & KUMAR, V. 2017. *Phyto-assisted synthesis, characterization and applications of gold nanoparticles – A review*.
- JAIN, D. & SAHA, S. J. E. P. J. 2017. Antioxidant and antihyperglycaemic effects of naringenin arrest the progression of diabetic nephropathy in diabetic rats. 16, 144.
- KINALSKI, M., ŚLEDZIEWSKI, A., TELEJKO, B., ZARZYCKI, W. & KINALSKA, I. J. A. D. 2000. Lipid peroxidation and scavenging enzyme activity in streptozotocin-induced diabetes. 37, 179-183.
- KOUAME, K., PETER, A., AKANG, E., MOODLEY, R., NAIDU, E. & AZU, O. J. B. J. O. B. M. S. 2019. Histological and biochemical effects of *Cinnamomum cassia* nanoparticles in kidneys of diabetic Sprague-Dawley rats.
- LEE, S., KIM, S. M., LEE, R. T. J. A. & SIGNALING, R. 2013. Thioredoxin and thioredoxin target proteins: from molecular mechanisms to functional significance. 18, 1165-1207.
- LIMDI, J. & HYDE, G. J. P. M. J. 2003. Evaluation of abnormal liver function tests. 79, 307-312.

- MARGINĂ, D., ILIE, M., GRADINARU, D., MIULESCU, R. D. & IONESCU-TÎRGOVIȘTE, C. J. A. 2013. Molecular Signatures of oxidative stress: relevance to Clinical And research. 5, 33-37.
- MARKOWITZ, J. T., HARRINGTON, K. R. & LAFFEL, L. M. J. C. D. R. 2013. Technology to optimize pediatric diabetes management and outcomes. 13, 877-885.
- MEDAGAMA, A. B. 2015. The glycaemic outcomes of Cinnamon, a review of the experimental evidence and clinical trials. *Nutrition journal*, 14, 108.
- MEZZETTI, A., CIPOLLONE, F. & CUCCURULLO, F. J. C. R. 2000. Oxidative stress and cardiovascular complications in diabetes: isoprostanes as new markers on an old paradigm. 47, 475-488.
- N MORESCO, R., B SANGOI, M., DE CARVALHO, J., TATSCH, E. & V BOCHI, G. 2013. *Diabetic nephropathy: Traditional to proteomic marker*
- NEWSHOLME, P., HABER, E., HIRABARA, S., REBELATO, E., PROCÓPIO, J., MORGAN, D., OLIVEIRA-EMILIO, H., CARPINELLI, A. R. & CURI, R. J. T. J. O. P. 2007. Diabetes associated cell stress and dysfunction: role of mitochondrial and non-mitochondrial ROS production and activity. 583, 9-24.
- ONIZAWA, S., AOSHIBA, K., KAJITA, M., MIYAMOTO, Y. & NAGAI, A. 2009. Platinum nanoparticle antioxidants inhibit pulmonary inflammation in mice exposed to cigarette smoke. *Pulmonary pharmacology & therapeutics*, 22, 340-349.
- OZDEMİR, G., OZDEN, M., MARAL, H., KUSKAY, S., CETİNALP, P. & TARKUN, I. J. A. O. C. B. 2005. Malondialdehyde, glutathione, glutathione peroxidase and homocysteine levels in type 2 diabetic patients with and without microalbuminuria. 42, 99-104
- PETER, A. I., NAIDU, E. C., AKANG, E., OGEDENGBE, O. O., OFFOR, U., RAMBHAROSE, S., KALHAPURE, R., CHUTURGOON, A., GOVENDER, T. & AZU, O. O. 2018. Investigating Organ Toxicity Profile of Tenofovir and Tenofovir Nanoparticle on the Liver and Kidney: Experimental Animal Study. *Toxicological research*, 34, 221.
- PLEXOPATHY, D. 2009. Cinnamon dose-dependently reduces insulin concentration. *Am J Clin Nutr*, 89, 815-21.
- PRABHU, S., VINODHINI, S., ELANCHEZHIAN, C. & RAJESWARI, D. 2018. Evaluation of antidiabetic activity of biologically synthesized silver nanoparticles using *Pouteria sapota* in streptozotocin-induced diabetic rats: *Journal of diabetes*, 10, 28-42.

- RAHAL, A., KUMAR, A., SINGH, V., YADAV, B., TIWARI, R., CHAKRABORTY, S. & DHAMA, K. J. B. R. I. 2014. Oxidative stress, prooxidants, and antioxidants: the interplay. 2014.
- ROMÁN-PINTOS, L. M., VILLEGAS-RIVERA, G., RODRÍGUEZ-CARRIZALEZ, A. D., MIRANDA-DÍAZ, A. G. & CARDONA-MUÑOZ, E. G. J. J. O. D. R. 2016. Diabetic polyneuropathy in type 2 diabetes mellitus: inflammation, oxidative stress, and mitochondrial function. 2016.
- SHAH, P. K., SHREEWASTAV, R. K. & SINGH, A. G. 2016. Study of Renal Profile In Diabetic Patient at Nobel Medical College Teaching Hospital, Biratnagar. *Journal of Nobel Medical College*, 5, 1-4.
- SHEN, Y., FUKUSHIMA, M., ITO, Y., MURAKI, E., HOSONO, T., SEKI, T. & ARIGA, T. 2010. Verification of the antidiabetic effects of cinnamon (*Cinnamomum zeylanicum*) using insulin-uncontrolled type 1 diabetic rats and cultured adipocytes. *Bioscience, biotechnology, and biochemistry*, 74, 2418-2425.
- SHEN, Y., HONMA, N., KOBAYASHI, K., JIA, L. N., HOSONO, T., SHINDO, K., ARIGA, T. & SEKI, T. 2014. Cinnamon extract enhances glucose uptake in 3T3-L1 adipocytes and C2C12 myocytes by inducing LKB1-AMP-activated protein kinase signaling. *PLoS One*, 9, e87894.
- SHEPPARD, P. & KAHN, B. 1999. Glucose transporters and insulin action. *N Engl J Med*, 341, 248-57.
- SINGH, P., KIM, Y.-J., ZHANG, D. & YANG, D.-C. J. T. I. B. 2016. Biological synthesis of nanoparticles from plants and microorganisms. 34, 588-599.
- STEPHEN, I., HSU, H. & COUSER, W. G. J. J. O. T. A. S. O. N. 2003. Chronic progression of tubulointerstitial damage in proteinuric renal disease is mediated by complement activation: a therapeutic role for complement inhibitors? 14, S186-S191
- SUCHY-DICEY, A. M., LAHA, T., HOOFNAGLE, A., NEWITT, R., SIRICH, T. L., MEYER, T. W., THUMMEL, K. E., YANEZ, N. D., HIMMELFARB, J. & WEISS, N. S. 2016. Tubular secretion in CKD. *Journal of the American Society of Nephrology*, 27, 2148-2155.
- TIWARI, B. K., PANDEY, K. B., ABIDI, A. & RIZVI, S. I. J. J. O. B. 2013. Markers of oxidative stress during diabetes mellitus. 2013.
- TOMINO, Y., COOPER, M. E., KURTZ, T. W. & SHIMIZU, Y. 2012. Experimental models of type-2 diabetic nephropathy. *Experimental Diabetes Research*, 2012.

- VALKO, M., RHODES, C., MONCOL, J., IZAKOVIC, M. & MAZUR, M. J. C.-B. I. 2006. Free radicals, metals and antioxidants in oxidative stress-induced cancer. 160, 1-40.
- VASU, V. T., ASHWINIKUMAR, C., MAROO, J., GUPTA, S. & GUPTA, S. 2003. Antidiabetic effect of *Enicostemma littorale* Blume aqueous extract in newly diagnosed non-insulin-dependent diabetes mellitus patients (NIDDM): a preliminary investigation. *Oriental Pharmacy and Experimental Medicine*, 3, 84-89.
- WALL, R. & SHANI, M. 2008. Are animal models as good as we think? *Theriogenology*, 69, 2-9.
- WILSON, R. D. 2011. *Fructose-fed streptozotocin-injected rat: an alternative model for type 2 diabetes*. University of KwaZulu-Natal, Westville.
- XIE, W., DU, L. J. D., OBESITY & METABOLISM 2011. Diabetes is an inflammatory disease: evidence from traditional Chinese medicines. 13, 289-301.
- YANG, B., EL NAHAS, A. M., THOMAS, G. L., HAYLOR, J. L., WATSON, P. F., WAGNER, B. & JOHNSON, T. S. 2001. Caspase-3 and apoptosis in experimental chronic renal scarring. *Kidney international*, 60, 1765-1776.
- YOSHIHARA, E., CHEN, Z., MATSUO, Y., MASUTANI, H. & YODOI, J. 2010. Thiol redox transitions by thioredoxin and thioredoxin-binding protein-2 in cell signaling. *Methods in enzymology*. Elsevier.
- ZHU, Y., CUI, H., GAN, H., XIA, Y., WANG, L., WANG, Y. & SUN, Y. 2015. Necroptosis mediated by receptor interaction protein kinase 1 and 3 aggravates chronic kidney injury of subtotal nephrectomised rats. *Biochemical and biophysical research communications*, 461, 575-581.

APPENDIX I

ETHICAL CLEARANCE



17 January 2017

Mr Koffi Kouame (207503022)
School of Laboratory Medicine & Medical Sciences
Westville Campus

Dear Mr Kouame,

Protocol reference number: AREC/074/016D

Project title: Investigating the effects of *Cinnamomum-cassia* (nanoparticle conjugate) on the Histomorphology of the kidney in type 2 diabetic rats

Full Approval – Research Application

With regards to your revised application received on 08 January 2017. The documents submitted have been accepted by the Animal Research Ethics Committee and **FULL APPROVAL** for the protocol has been granted with the following condition:

NOTES:

1. For normal animals, 5 animals can be used per group but for diabetic groups, 7 animals can be used per group with a total of $5 \times 5 = 25$ for normal and $7 \times 6 = 42$ for diabetic groups. Total: $25 + 42 = 67$ animals
2. Plant extracts should be dissolved in distilled water or 1% CMC solution before oral administration.

Any alteration/s to the approved research protocol, i.e Title of Project, Location of the Study, Research Approach and Methods must be reviewed and approved through the amendment/modification prior to its implementation. In case you have further queries, please quote the above reference number.

Please note: Research data should be securely stored in the discipline/department for a period of 5 years.

The ethical clearance certificate is only valid for a period of one year from the date of issue. Renewal for the study must be applied for before 17 January 2018.

Attached to the Approval letter is a template of the Progress Report that is required at the end of the study, or when applying for Renewal (whichever comes first). An Adverse Event Reporting form has also been attached in the event of any unanticipated event involving the animals' health / wellbeing.

I take this opportunity of wishing you everything of the best with your study.

Yours faithfully

.....
Prof S Islam, PhD
Chair: Animal Research Ethics Committee

/ms

cc Supervisor: Dr Onyemaechi Okpara Azu
Cc Acting Academic Leader Research: Dr Michelle Gordon

cc Registrar: Mr Simon Mokoena
NSPCA Mr L Duncan

Cc BRU – Mr Sanil Singh

Animal Research Ethics Committee (AREC)


Ms Mariette Snyman (Administrator)

Westville Campus, Govan Mbeki Building

Postal Address: Private Bag X54001, Durban 4000

Telephone: +27 (0) 31 260 8350 Facsimile: +27 (0) 31 260 4809 Email: animalethics@ukzn.ac.za

Website: <http://research.ukzn.ac.za/Research-Ethics/Animal-Ethics.aspx>



100 YEARS OF ACADEMIC EXCELLENCE

Founding Campuses: ■ Edgewood ■ Howard College ■ Medical School ■ Pietermaritzburg ■ Westville

APPENDIX II

MANUSCRIPT THREE

GREEN-SILVER NANOPARTICLES SYNTHESIS USING *CINNAMOMUM CASSIA*

Koffi Kouame¹, Ugochukwu Offor¹, Roshila Moodley^{3*}, Edwin Coleridge Naidu¹, Onyemaechi Okpara Azu^{1,4}

¹ Discipline of Clinical Anatomy, School of Laboratory Medicine and Medical Sciences, University of KwaZulu-Natal, Private Bag X 54001, Durban 4000, South Africa.

² Department of Anatomy, College of Medicine, University of Lagos, Idi-Araba, Lagos, Nigeria.

³ School of Chemistry and Physics, University of KwaZulu-Natal, Westville Campus. Private Bag X54001, Durban, 4000, South Africa.

⁴ Department of Anatomy, School of Medicine, University of Namibia, Windhoek, Namibia

* Corresponding author: Discipline of Clinical Anatomy, School of Laboratory Medicine and Medical Sciences, University of KwaZulu-Natal, Westville Campus. Private Bag X54001, Durban, 4000, South Africa. Phone: +27312604305. E-mail: 207503022@stu.ukzn.ac.za

Abstract

In this study, we report the green synthesis of silver nanoparticles (NPs) using extracts from selected *Cinnamomum cassia* plants. A detailed spectroscopic characterisation of the biosynthesised silver nanoparticles (CcAgNPs) revealed a UV-visible absorption at 450 nm, which was revealing the nanoparticles' surface Plasmon resonance, meanwhile, the Fourier transform infrared (FTIR) vibrational frequencies showed that flavonoids, alkaloids and bonded sugars were mostly responsible for the reduction and stabilisation of the AgNPs. This was further confirmed by additional analysis. The nature, shape and morphology of the biosynthesised CcAgNPs were explored using Transmission Electron Microscopy (TEM), Scanning Electron Microscopy and X-ray (D) analysis. CcAgNPs were mostly spherical and rounded in shape with particle size in the range from 4.28 nm to 30nm. *Cinnamomum cassia* extracts were efficient in the synthesis of AgNPs with an average yield of 150 mg. The synthesised nanoparticles were safely used in the treatment of type 2 induced diabetics rats.

Keywords: Biosynthesis, microscopy, nanoparticles, spectroscopy.

Introduction

Research has moved towards the scientific synthesis and the medical application of nanoscale silver particles have gained serious attention in recent years due to their high quality, physicochemical and biological properties. The biological interactions of silver nanoparticles (AgNPs) are significantly intensified by their wide surface area-to-volume ratio as compared to their bulk counterparts (El-Nour et al., 2010). These properties, adding to their chemical, conductive and optical properties make them suitable for the applications in modern medicine Pantic (2014), biosensing Doria et al. (2012), to transport drug Brown et al. (2013), and catalysis (Crooks et al. 2001; Dong et al., 2015). Their large spectrum quality to fight fungus and bacteria, properties that have made them popular in the domain of consumer products like cosmetics and textiles. Moreover, these properties have also enabled nanoparticles to find application in food processing El-Nour et al. (2010) and water purification (Zhang, 2013).

Nano carrier could exhibit good targeting through conjugation with various interesting active bio-ligands such as biotin. At the same time, core-shell and multilayered nanoparticles could be loaded with several drugs and control the drug-release profile. The integration of Nano carriers into DN therapeutic may therefore be very promising (Zhou et al., 2012). Nano biotechnology is a fast-paced interdisciplinary domain where the nanotechnology is utilised for the exploration and transformation of biological systems. The success of green synthesis of biocompatible silver nanoparticles has gained greater awareness in the past few years for its application in medical-biosciences (Mieszawska et al., 2013). Nanoparticles are molecules which are 100 nm in range and possess interesting physical, chemical and biological properties. That makes them potent molecules for diagnostics and therapeutics in modern medicine. Of the metals silver (Ag) is the metal of choice for applications in biology and medicine. Silver nanoparticles (AgNPs) have been increasingly used as anticancer, antiangiogenic, and antibacterial agents (Zhang et al., 2015; Lee, 2002; BarathManiKanth et al., 2010, and Desai, 2012).

AgNPs can also be used to treat diseases that require a sustained presence of the drug at several anatomical sites (Panyam and Labhasetwar, 2003). It has been reported that the small size of AgNPs (1–100 nm) intensify their physical, chemical, magnetic, and optical properties (Chen and Schluesener, 2008; Awazu et al., 2008).

Medicinal plants are known to be rich sources of biologically active compounds (Zulkipli et al., 2015). The presence of diverse secondary metabolites in addition to primary metabolic products in these plants contribute largely to their efficacy in the green synthesis of AgNPs

Nanoparticles has large number of advantages for herbal drugs, including enhancement of solubility and bioavailability, protection from toxicity, enhancement of pharmacological activity, enhancement of stability, improving tissue macrophages distribution, sustained delivery, protection from physical and chemical degradation, etc (Ansari and Farha Islam, 2012).

Incorporation of the herbal extracts into novel formulation systems have certain added advantages, such as their bulk dosing and less absorption can be overcome, which is the major problem being faced, enticing the attention of major pharmaceutical corporations (Ansari and Farha Islam, 2012). Natural products such as medicinal plants have therefore been a very good source of green nanoparticles.

In this study we will use the powder of the medicinal plant *Cinnamomum cassia* as the reducing agent and aqueous silver nitrate as the precursor for the synthesis of silver nanoparticles (AgNPs). *Cinnamomum cassia* is also called Chinese *cassia* or Chinese cinnamon, is an evergreen tree originating in southern China, and widely cultivated there and elsewhere in southern and eastern Asia (India, Indonesia, Laos, Malaysia, Taiwan, Thailand, and Vietnam). Nowadays, the plant is also found in the African continent.

Medicinal plants have been reported to be useful, worldwide and have been used empirically as antidiuretic and antihyperlipidemic remedies. In this study we are aiming to investigate activity of *Cinnamomum-cassia* silver nanoparticles (AgNP_s) on kidneys and blood glucose of type 2 diabetic rats.

Materials and Methods

Collection of Plant Materials

Pure *Cinnamomum cassia* powder was obtained from Warren Chemistry Warren Chem Specialities (Pty) Ltd and the silver nitrate was obtained from Capital Laboratory PTY LTD.



Figure 4.0 *Cinnamomum cassia* adopted from Emilija Manevska/Getty Images

Preparation of Aqueous Plants Extracts

The aqueous extract of *Cinnamon cassia* was prepared as follows. A fine powder of the plant (10 g) was added to 300 mL of double-distilled water and allowed to boil for 10 minutes (Kanagarasu et al., 2017). The resulting brownish mixtures were filtered and stored in a refrigerator at 4°C until analysed.

Synthesis of Green (Cinnamon Cassia) Silver Nanoparticles (AgNP_s)

In the view to reduce Ag⁺ was achieved by adding 250 mL of aqueous solution of silver nitrate AgNO₃ (1mM) from Capital Laboratory PTY LTD; by drop wise into 100 ml of *Cinnamon cassia* extracts while stirring and heated at 45°C. While steering the colour of the extracts will be changing, from light brown to dark brown, was recorded as a sign of the formation of silver nanoparticles.





Figure 4.1: Process of silver nanoparticle formation—Colour changing, from light brown to dark brown

Quantification of AgNPs

Each AgNPs solution was subjected for centrifugation by using the centrifuge of Eppendorf (Model:5804/5804 R, USA). The treatment solutions (AgNPs at room temperature and at 80 °C) were then off load into different Eppendorf tubes. Tubes were weighed beforehand and were sent for purification for a duration of 2 h at 5000 rpm and at 4 °C. The samples were then moved to the oven to get dry, as only the powder will be used for the experiment, this process was done at 50 °C for 24 h after which the tubes were again re-weighed to assess the yield of the synthesised AgNPs of 150 mg.

Morphological Analysis of AgNP_s and Characterisation of the Bioreductants

UV (Ultraviolet)

The biological reducibility of Ag¹ to Ag⁰ was using a SHIMADZU UV-2600 UV-Vis Spectrophotometer (Japan) at a range of 120-900 nm with a resolution of 1 nm. In order to evaluate the biological reducing and the functional ability to cap for the AgNPs, infra-red spectra of the crude extracts and their corresponding biosynthesised.

FTIR (Fourier Transform Infrared Spectroscopic)

AgNPs were obtained on a Perkin Elmer Spectrum 100 Fourier transform infrared (FTIR) spectrophotometer (Brito et al., 1998) with universal attenuated total reflectance (Tedong et al.,2006) sampling accessory. The size and morphology of the AgNPs were examined using transmission and the scanning electron microscopy.

TEM (Transmission Electron Microscopy)

The TEM was also used to obtain selected area electron diffraction (SAED) of the AgNPs in order to evaluate their crystallinity. For TEM measurements, solutions of synthesised AgNPs were sonicated using a sonication bath (SONICLEAN, England) and the evenly dispersed AgNPs were coated onto carbon-coated TEM grids and placed under a lamp for the evaporation of the solvent before viewing.

XRD Analysis

Then a sample was ground/milled to a very fine powder in a gate pestle and mortar. The powder was then prepared for XRD analysis using the front loading preparation method. The sample was later analysed with a Panalytical Empyrean diffract meter (made in the Netherlands) with an X' Celerator detector and Co-K α radiation. The generator setting was 40 kV (voltage) and 40 mA (Markowitz et al.).

Results and Discussions

Synthesis and Quantification of AgNPs

Aqueous solution (0.60g) of silver nitrate (AgNO₃) was dissolved in 250 mL Erlenmeyer flasks, was then added drop wise into 100ml of Cinnamon extract while stirring and heated at 45°C. Then, the solution was kept under constant stirring at room temperature using a magnetic stirrer for 120 minutes (Yazid et al., 2016). The colour change of the *Cinnamomum cassia* extracts from light brown to dark brown was recorded as a sign of generating silver nanoparticles. It shows that aqueous silver ions could be brought to reduction by aqueous extract of *cinnamomum cassia* powder to cause extremely stable the Silver nanoparticles in water. Therefore, the aqueous solution of biosynthesised AgNPs from *cinnamomum cassia* powder possessed similar shades that give a dark brown colour; strictly indicating the formation of AgNPs. It has been demonstrated that when temperature appears elevated, production of molecular energy increases and brings a speeding effect in the absorption of ions within the silver and further reducing the particle size. According to (Phogat et al., 2016), the colour difference was due to the reduction of silver ions.

UV–Vis Spectral Analysis

The UV–Vis analysis was performed by running a base line with the solvent (distilled water) at different wavelength from 190 to 900 nm, at room temperature and PH: 3.96. An aqueous component of *cinnamon cassia* was sampled. The component was scanned over the 190 to 900 nm wavelength range. Figure belows, shows the UV–Vis spectra of aqueous component as a function of wave variation of with 0.06 g of silver nitrate (AgNO₃) into 250 ml of distilled water solution. The sharp bands of silver colloids were observed at about 500 nm. The intensity of absorption band increases with increasing time period of aqueous component and consequent colour changes were observed from light brown to dark brown.

(Phogat et al., 2016) reported that the UV–Vis absorption spectrum with a distinct peak observed at 445 nm indicated a surface plasmon resonance, which has already been recorded for various metal nanoparticles ranging from 2 to 100 nm in size (Zhang et al., 2013). On contrary, our results display a peak at about 500 nm and the TEM revealed nanoparticles are of smaller size. However, the absorbance peak observed confirms the formation of AgNPs.

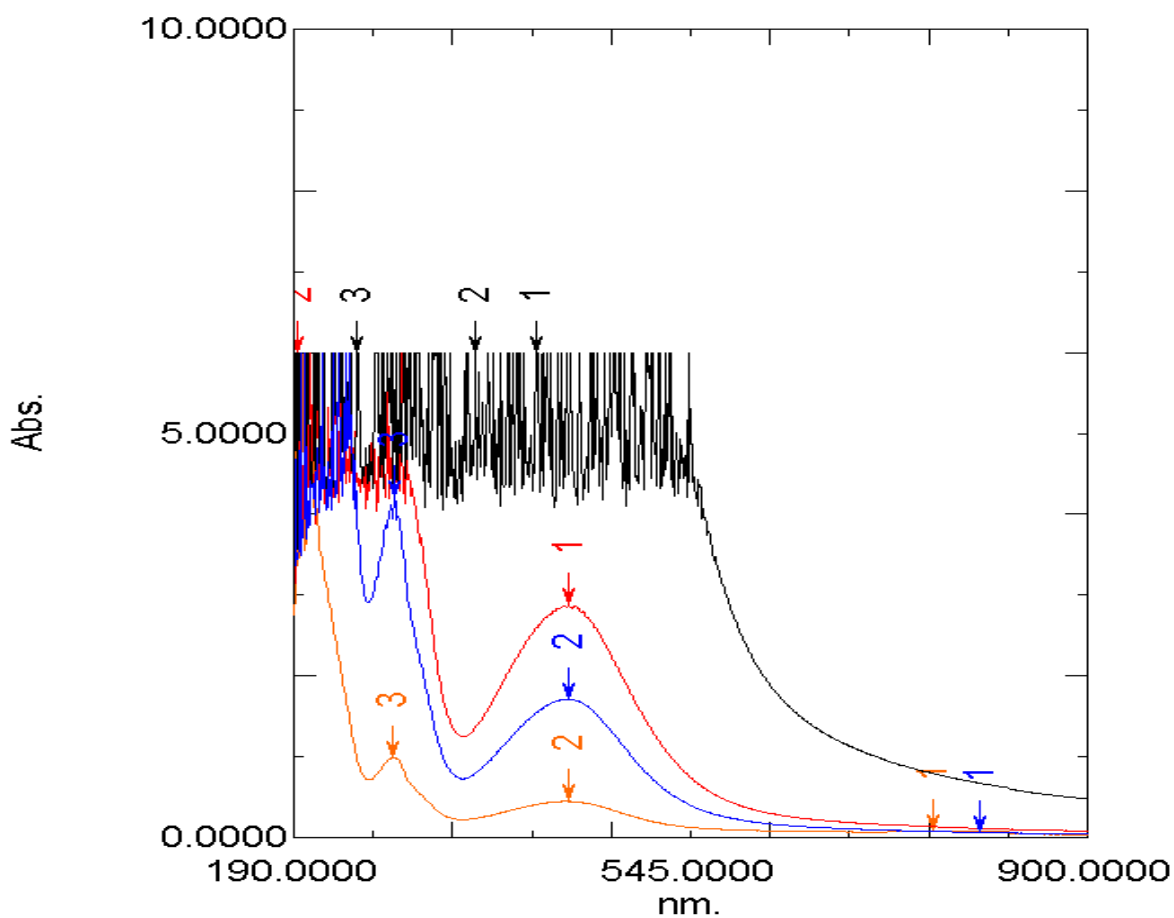


Figure 4.2: The UV-absorption spectra obtained for *Cinnamon Cassia* powder.

A characteristic peak at 500 nm wavelength is clearly observed, which is indicative of the formation of Ag nanoparticles.

Fourier Transform Infrared Spectroscopic (FTIR) Analysis

The functional component present in the Cinnamomum cassia extracts as well as their effects to synthesizing (AgNPs) was quantified using the FTIR diagram. A certain amount of the dried powder of the (AgNPs) was spared on the pellet of the machine and the analysis was immediately carefully performed using Permian Elmer ---Spectrum 100. The absorbance band varies from 3270 to 500 nm. The peak of 3270 cm^{-1} corresponds to the NH, but the carbonic group will be contained in the peak of 2921 cm^{-1} and correspond to OH, meanwhile 1604 to 1316 cm^{-1} should correspond to CO, with a stretching to 1075 cm^{-1} to 1022 cm^{-1} .

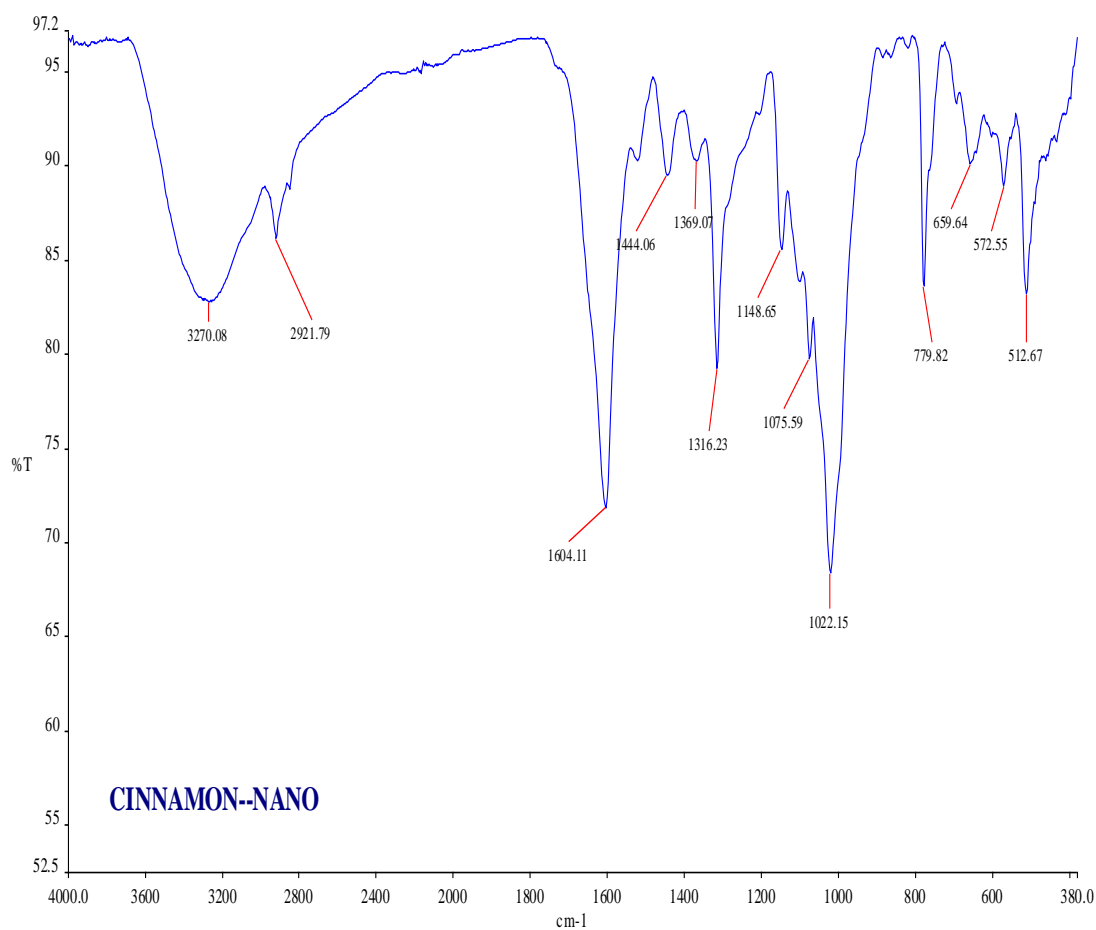


Figure 4.3: FTIR Spectra of aqueous *cinnamon cassia* extract and that of AgNPs

TEM Analysis of Silver Nanoparticles

Methods: A small amount of powder of the nanoparticles was dispersed in ethanol, and then solicated for 10 minutes and dip form, grade into solution. Sample was later dried within 10 minutes. Transmission electron microscopy technique was employed to visualize in depth the shape and morphology of green Silver nanoparticles produced. Transmission Electron Microscopy (TEM) experiments proved the formation of Nano- crystalline silver particles, as shown in Figure 6 and 7.

TEM images obtained confirmed that the morphology of nanoparticles is highly variable with a variety of shapes- spherical, longitudinal and irregular. The nanoparticles predominately adopt a spherical morphology and are not agglomerated into small aggregates. Their size variations are as followed: Minimum 12,92 Maximum 42,44 Standard Deviation 7,07 Variance 49,96 Median 25,64 Mean 25,38 Sum 2055,68. The nanoparticles behaviour appears to be a function of their size and shape, while the difference in shapes and sizes could be due to aggregation and adsorption of compounds in Cinnamon cassia extract onto the surface of silver nanoparticles. Although nanoparticles size is small but they are very effective when compared with the bulk material.

TEM of AgNPs synthesized using *C. angustifolia* reported by (Paton et al., 2014), clearly showed that AgNPs are spherical in shape, which is in line with our results. Further to this, according to (Paton et al., 2014) most of the particles in their TEM pictures are not in contact with each other, but they are bound to the bio-organic material which is responsible for their stability. This remark is largely confirmed by our result where several particles are spread out




Figure 4.4A2: TEM Images of silver nanoparticles using aqueous *cinnamomum cassia* (magnification 200)




Figure 4.4A1: TEM Images of silver nanoparticles using aqueous *cinnamomum cassia* (magnification 200)

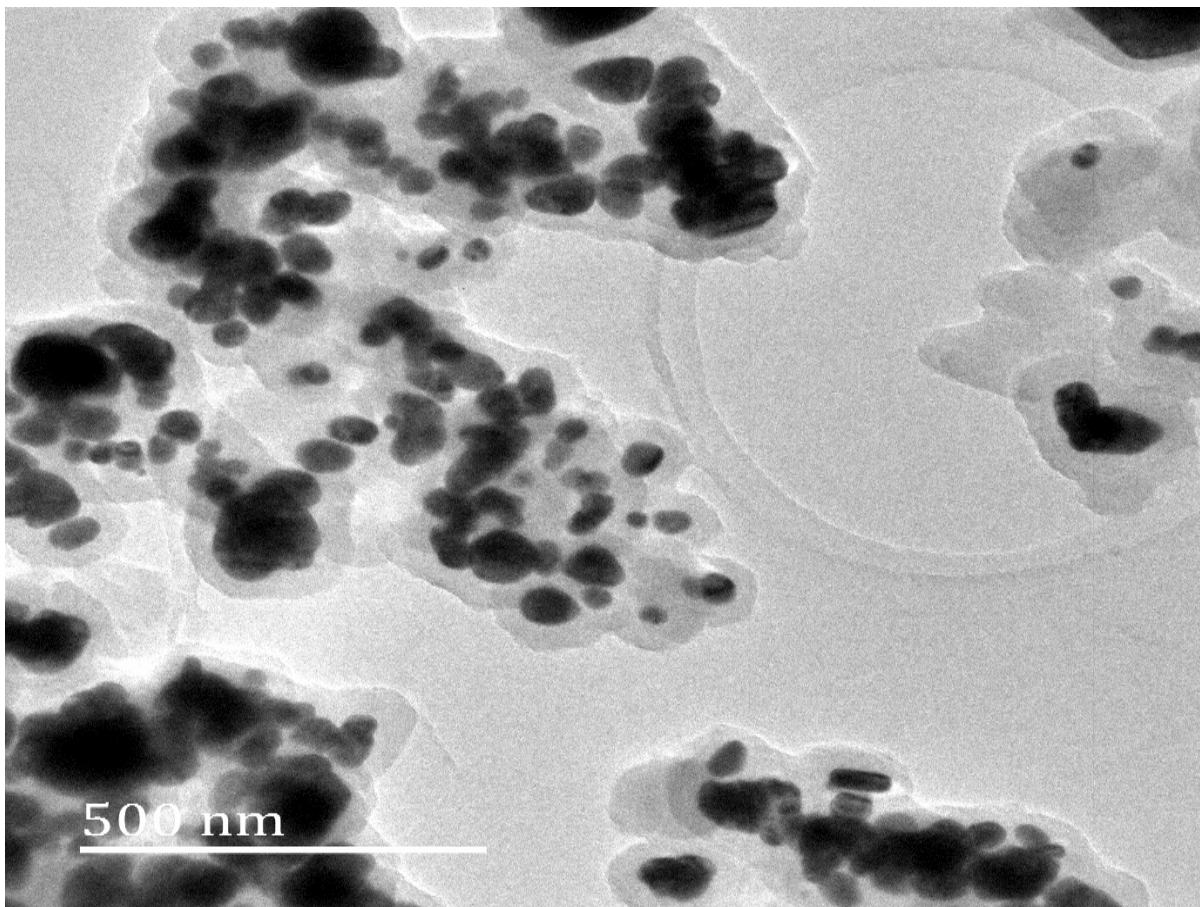


Figure 4.4B: TEM Images of silver nanoparticles using aqueous *cinnamomum cassia* (magnification 500nm)




Figure 4.4C: TEM Images of silver nanoparticles using aqueous *cinnamomum cassia*-Showing measurement of particles

XRD Analysis

The XRD spectrum showed six distinct diffraction peaks. The strong peak (Lee et al., 2013) of silver heights 1646.63 at 44.693 nm indicating that the biosynthesized nanoparticles are indeed made up of only silver. Followed by two medium peaks 468.56 and 310.62,

in addition 2 others medium peaks about 278 and 233.86 were noted. Moreover, one important lower peak was also displayed. The XRD results obtained in our experiment show similarities with those of (Phogat et al., 2016), which confirm the crystalline nature of the AgNPs with regard to the XRD patterns observed in the results.

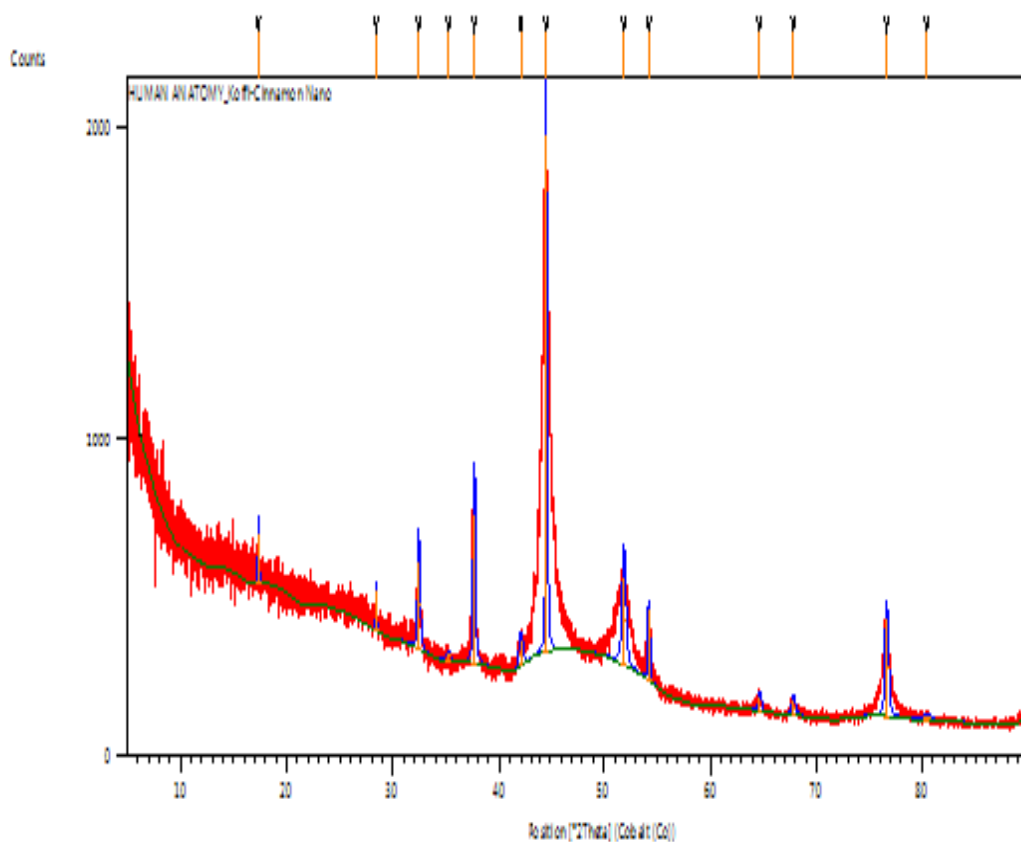


Figure 4.5: XRD patterns of cinnamon nanoparticles synthesized by treating 100 mL aqueous cinnamon with 250 ml aqueous AgNPs.

Discussion

Zeng et al. (2014) reported that the UV–Vis absorption spectrum with a distinct peak observed at 445 nm indicated a surface Plasmon resonance, which has already been recorded for various metal nanoparticles ranging from 2 to 100 nm in size (Sinha et al., 2015; Shankar et al., 2016). On contrary, our results display a peak at about 500 nm and the TEM revealed nanoparticles are of smaller size. However, the absorbance peak observed confirms the formation of AgNPs.

TEM of AgNPs synthesized using *C. angustifolia* reported by Peter et al. (2018) clearly showed that AgNPs are spherical in shape, which is in line with our results. Further to this, according to Peter et al. (2018), most of the particles in their TEM pictures are not in contact with each other, but they are bound to the bio-organic material which is responsible for their stability. This remark is largely confirmed by our result where several particles are spread out.

Conclusion

AgNPs were synthesized using *cinnamomum cassia* extract added to AgNO₃ aqueous solution. The crystalline nature of the AgNPs was evident from sharp peaks when observed via the XRD spectrum with smaller size of CcAgNPs. FTIR analysis suggests that *cinnamomum cassia* extract could act as the reducing agent responsible for the reduction of Ag⁺ into Ag. This method is purely environmentally friendly, of low cost, and simple and therefore may promote the application of green technology for the production of AgNPs.

ACKNOWLEDGEMENTS

We acknowledge the College of Health Sciences, UKZN for their financial support to the doctoral student, Koffi Kouame. This work is supported in part by the National Research Foundation of South Africa to the senior author (OOA) Grant U99053 and Dr Roshila Moodley (Grant No. 94041). We also thank the School of Chemistry and Physics, UKZN (Westville Campus) especially the support of Judie Magura and Bongisiwe Shelembe. The authors also acknowledge the UKZN Nanotechnology platform.

References

- ANSARI, S. & FARHA ISLAM, M. 2012. Influence of nanotechnology on herbal drugs: A Review. *Journal of advanced pharmaceutical technology & research*, 3, 142.
- AWAZU, K., FUJIMAKI, M., ROCKSTUHL, C., TOMINAGA, J., MURAKAMI, H., OHKI, Y., YOSHIDA, N. & WATANABE, T. 2008. A plasmonic photocatalyst consisting of silver nanoparticles embedded in titanium dioxide. *Journal of the American Chemical Society*, 130, 1676-1680.
- BARATHMANIKANTH, S., KALISHWARALAL, K., SRIRAM, M., PANDIAN, S. R. K., YOUN, H.-S., EOM, S. & GURUNATHAN, S. 2010. Anti-oxidant effect of gold nanoparticles restrains hyperglycemic conditions in diabetic mice. *Journal of nanobiotechnology*, 8, 16.
- BRITO, P. L., FIORETTO, P., DRUMMOND, K., KIM, Y., STEFFES, M. W., BASGEN, J. M., SISSON-ROSS, S. & MAUER, M. 1998. Proximal tubular basement membrane width in insulin-dependent diabetes mellitus. *Kidney international*, 53, 754-761.
- BROWN, T. T., COLE, S. R., LI, X., KINGSLEY, L. A., PALELLA, F. J., RIDDLER, S. A., VISSCHER, B. R., MARGOLICK, J. B. & DOBS, A. S. J. A. O. I. M. 2005. Antiretroviral therapy and the prevalence and incidence of diabetes mellitus in the multicenter AIDS cohort study. 165, 1179-1184.
- CHEN, X. & SCHLUESENER, H. 2008. Nanosilver: a nanoproduct in medical application. *Toxicology letters*, 176, 1-12.
- CROOKS, R. M., ZHAO, M., SUN, L., CHECHIK, V. & YEUNG, L. K. 2001. Dendrimer-encapsulated metal nanoparticles: synthesis, characterization, and applications to catalysis. *Accounts of chemical research*, 34, 181-190.
- DESAI, N. 2012. Challenges in development of nanoparticle-based therapeutics. *The AAPS journal*, 14, 282-295.
- DONG, X.-Y., GAO, Z.-W., YANG, K.-F., ZHANG, W.-Q. & XU, L.-W. 2015. Nanosilver as a new generation of silver catalysts in organic transformations for efficient synthesis of fine chemicals. *Catalysis Science & Technology*, 5, 2554-2574.
- DORIA, G., CONDE, J., VEIGAS, B., GIESTAS, L., ALMEIDA, C., ASSUNÇÃO, M., ROSA, J. & BAPTISTA, P. V. 2012. Noble metal nanoparticles for biosensing applications. *Sensors*, 12, 1657-1687.
- EL-NOUR, K. M. A., EFTAIHA, A. A., AL-WARTHAN, A. & AMMAR, R. A. 2010. Synthesis and applications of silver nanoparticles. *Arabian journal of chemistry*, 3, 135-140.
- KANAGARASU, R., BHAVAN, P. S., RAJKUMAR, G., NATHIYA, V., SATGURUNATHAN, T. & MANJULA, T. 2017. Phytochemical characterization of *Alternanthera sessilis* and assessment of its growth promoting potential on the freshwater prawn *Macrobrachium rosenbergii*. *International Journal of Research Studies in Zoology*, 3, 25-38.
- LEE, H.-S. 2002. Inhibitory activity of Cinnamomum cassia bark-derived component against rat lens aldose reductase. *J Pharm Pharm Sci*, 5, 226-230.
- LEE, S., KIM, S. M., LEE, R. T. J. A. & SIGNALING, R. 2013. Thioredoxin and thioredoxin target proteins: from molecular mechanisms to functional significance. 18, 1165-1207.
- MIESZAWSKA, A. J., MULDER, W. J., FAYAD, Z. A. & CORMODE, D. P. 2013. Multifunctional gold nanoparticles for diagnosis and therapy of disease. *Molecular pharmaceuticals*, 10, 831-847.

- PATON, K. R., VARRLA, E., BACKES, C., SMITH, R. J., KHAN, U., O'NEILL, A., BOLAND, C., LOTYA, M., ISTRATE, O. M. & KING, P. 2014. Scalable production of large quantities of defect-free few-layer graphene by shear exfoliation in liquids. *Nature materials*, 13, 624.
- PANTIC, I. 2014. APPLICATION OF SILVER NANOPARTICLES IN EXPERIMENTAL PHYSIOLOGY AND CLINICAL MEDICINE: CURRENT STATUS AND FUTURE PROSPECTS. *Reviews on Advanced Materials Science*, 37.
- PETER, A. I., NAIDU, E. C., AKANG, E., OGEDENGBE, O. O., OFFOR, U., RAMBHAROSE, S., KALHAPURE, R., CHUTURGOON, A., GOVENDER, T. & AZU, O. O. J. T. R. 2018. Investigating organ toxicity profile of tenofovir and tenofovir nanoparticle on the liver and kidney: experimental animal study. 34, 221.
- PHOGAT, N., ALI KHAN, S., SHANKAR, S., ANSARY, A. A. & UDDIN, I. 2016. Fate of inorganic nanoparticles in agriculture. *Adv. Mater. Lett*, 7, 3-12.
- PRABHU, S., VINODHINI, S., ELANCHEZHIAN, C. & RAJESWARI, D. 2018. Evaluation of antidiabetic activity of biologically synthesized silver nanoparticles using *Pouteria sapota* in streptozotocin-induced diabetic rats: *Journal of diabetes*, 10, 28-42.
- SHANKAR, P. D., SHOBANA, S., KARUPPUSAMY, I., PUGAZHENDHI, A., RAMKUMAR, V. S., ARVINDNARAYAN, S., KUMAR, G. J. E. & TECHNOLOGY, M. 2016. A review on the biosynthesis of metallic nanoparticles (gold and silver) using bio-components of microalgae: Formation mechanism and applications. 95, 28-44.
- SINHA, S. N., PAUL, D., HALDER, N., SENGUPTA, D. & PATRA, S. K. J. A. N. 2015. Green synthesis of silver nanoparticles using fresh water green alga *Pithophora oedogonia* (Mont.) Wittrock and evaluation of their antibacterial activity. 5, 703-709.
- YAZID, M. N. A. W. M., SIDIK, N. A. C., MAMAT, R. & NAJAFI, G. 2016. A review of the impact of preparation on stability of carbon nanotube nanofluids. *International Communications in Heat and Mass Transfer*, 78, 253-263.
- ZENG, S., BAILLARGEAT, D., HO, H.-P. & YONG, K.-T. J. C. S. R. 2014. Nanomaterials enhanced surface plasmon resonance for biological and chemical sensing applications. 43, 3426-3452
- ZHANG, X.-F., CHOI, Y.-J., HAN, J. W., KIM, E., PARK, J. H., GURUNATHAN, S. & KIM, J.-H. 2015. Differential nanoreprotoxicity of silver nanoparticles in male somatic cells and spermatogonial stem cells. *International journal of nanomedicine*, 10, 1335.
- ZHANG, H. 2013. Application of silver nanoparticles in drinking water purification.
- ZHOU, X., WANG, B., ZHU, L. & HAO, S. 2012. A novel improved therapy strategy for diabetic nephropathy: targeting AGEs. *Organogenesis*, 8, 18-21.
- ZULKIPLI, I. N., DAVID, S. R., RAJABALAYA, R. & IDRIS, A. 2015. Medicinal plants: a potential source of compounds for targeting cell division. *Drug target insights*, 9, DTI. S24946.

MANUSCRIPT FOUR

Ultrastructural changes in the kidney of diabetic Sprague-Dawley rats treated with Cinnamomum cassia silver nanoparticles.

Koffi Kouame¹, Aniekan Imo Peter¹, Edidiong Nnamso Akang^{1,2}, Ugochukwu Offor¹, Edwin Coleridge Naidu¹, Onyemaechi Okpara Azu^{1,4}

¹ Discipline of Clinical Anatomy, School of Laboratory Medicine and Medical Sciences, University of KwaZulu-Natal, Private Bag X 54001, Durban 4000, South Africa.

² Department of Anatomy, College of Medicine, University of Lagos, Idi-Araba, Lagos, Nigeria.

³ School of Chemistry and Physics, University of KwaZulu-Natal, Westville Campus. Private Bag X54001, Durban, 4000, South Africa.

⁴ Department of Anatomy, School of Medicine, University of Namibia, Windhoek, Namibia

* Corresponding author: Discipline of Clinical Anatomy, School of Laboratory Medicine and Medical Sciences, University of KwaZulu-Natal, Westville Campus. Private Bag X54001, Durban, 4000, South Africa. Phone: +27312604305. E-mail: 207503022@stu.ukzn.ac.za

Abstract

The Streptozotocin (STZ) model of diabetes is being used for studies of diabetic nephropathy although the histological morphological lesions of the kidney are mild and do not resemble those observed in diabetic patients. The Sprague-Dawley rat model of type II diabetes spontaneously develops pronounced abnormalities in renal histology after administration of Streptozotocin (STZ). In the present study, we are aiming to investigate the renal ultrastructure in the STZ Sprague-Dawley diabetics rats after 56 days' treatment with *Cinnamomum cassia* extracts and *Cinnamomum* silver nanoparticles (CcAgNPs). Twenty-four Sprague-Dawley rats (250 ± 20 g) were randomly assigned to four groups (A–D) of six animals per group and treated for 8 weeks. Group A was administered 200 mg/kg of *Cinnamon Cassia* extract, group B 5 mg/kg of CcAgNPs, group C 10 mg/kg of CcAgNPs, and group D normal saline. Body weight was measured weekly and fasting blood glucose was measured fortnightly. At the end of the experiment, animals were euthanized and organs (livers and kidneys) were fixed in neutral buffered formalin and processed for light microscopy (H&E). The renal damage was evaluated by assessing damage indices and by using stereological techniques. In addition, electron microscopy was performed. The glomerular and tubulointerstitial changes were much more pronounced in the diabetic control group compared to the treated group with CcAgNPs. The glomeruli in control groups contained less and larger podocytes as well as smaller mesangial cells embedded in more mesangial matrix compared to treated group. exhibits marked structural lesions, particularly podocyte damage and mesangial expansion that promise to make it a more suitable model for investigation of diabetic glomerulosclerosis. There was change in the Glomeruli Basement Membrane in both groups, but more pronounced in the control. CcAgNPs restores morphology and function of kidney after a long period of administration.

Key words: Histology, glomeruli, tubulointerstitial, Streptozotocin.

Introduction

Diabetes mellitus DeFronzo et al. (1991) is characterized by the absence of insulin leading to glucose overproduction and its underutilization in the liver. However, the insulin-independent tissues such as kidney demonstrate over-utilization of glucose during diabetes due to hyperglycaemia (Witowski and Breborowicz, 1999). Various renal pathological changes along with functional disturbances has been revealed in experimental diabetes (Yokozawa et al., 2001). It was reported thrombospondin-1 (TSP-1) was a matricellular, calcium-binding protein that is involved in cellular responses to growth factors, cytokines, and lesions. Previous studies have demonstrated that in glomerular mesangium fibrosis induced by angiotensin II, many genes expression increased, of which TSP-1 may cause the process of diabetic glomerulosclerosis (Hugo, 2003). Our previous study has shown that up-regulation of TSP-1 expression in diabetic rodent heart can play a role in diabetic cardiomyopathy.

Silver nanoparticles (AgNPs) have gained unique attention because of their attractive properties, including their high surface to volume proportions, reactant properties, and antimicrobial impact (Okafor et al., 2013). This is particularly relevant in the health sciences as it opens new frontiers in drug synthesis and delivery needed to target some of the sanctuary sites difficult for normal therapeutic doses of drugs to penetrate (Peter et al., 2018). However, most techniques used for the synthesis of nanoparticles (NPs) are costly and may negatively influence biological systems.

The human kidney is responsible for several functions, such as filtration of the plasma, blood pressure control, and hormonal production among others. Kidneys are bean-shaped organs located in the retroperitoneal space, irrigated by the renal artery, and covered by its fibrous capsule. Renal parenchyma can be distinguished into cortex and medullar regions, with different anatomic–histological characteristics. Inside a human kidney, there are about one million nephrons, which are composed of tubules and renal corpuscles. The corpuscles contain several tortuous arterioles covered by podocytes. The set of the endothelial layer of these arterioles, its basement membrane, and the podocytes correspond to the glomerular filtration barrier. The ultrafiltration of the plasma by this barrier and formation of the primary urine requires normal glomerular morphology. It is well documented that the podocytes are important to guarantee the selectivity during the filtration process, preventing macromolecules that pass through the slit diaphragm formed between its foot processes.

Many studies suggest that alterations on these cells or on the vessels, as those during hypertension, diabetes, or lupus, can reduce the oxygen flux, leading to hypoxia stage, being responsible for podocyte alteration and death. The glomerular filtration barrier morphology has been extensively studied in several experimental and clinical conditions. For this purpose, electron microscopy (both transmission and scanning) suits perfectly for observing the fine structure of this barrier, indicating with accuracy morphological alterations when present. Thus, in this chapter, we aimed (a) to describe the elements of the glomerular filtration barrier, (b) to present scientific examples of how the glomerular filtration barrier elements are related to different clinical and experimental conditions, and (c) to show how the elements of the glomerular filtration barrier can be analysed by scanning and transmission electron microscopy with qualitative and quantitative methods.

.MATERIALS AND METHODS

Materials and Methods

Collection of Plant Material

Pure *C. cassia* powder was obtained from Warren Chemistry Specialities (Pty), Cape Town (Reference 492733) and silver nitrate (AgNO_3) was obtained from Capital Laboratory (Pty), KwaZulu-Natal.

Preparation of Aqueous Plants Extract

The aqueous extract of *C. cassia* was prepared by adding a fine powder of the plant (10 g) to 300 mL of double-distilled water, which was allowed to boil for 10 min. The resulting mixture was filtered and stored in a refrigerator at 4°C until analysed.

Synthesis of *Cinnamomum Cassia* Silver Nanoparticles (CcAgNP_s)

An aqueous solution of AgNO_3 was dissolved in 250 mL Erlenmeyer flasks, and was then added, dropwise into 100 mL of the plant extract while stirring and heated at 45°C. This solution was stirred constantly at room temperature using a magnetic stirrer for 120 minutes. A colour change from light brown to dark brown indicated the formation of AgNPs.

Structural Analysis of *Cinnamomum Cassia* Silver Nanoparticles (CcAgNP_s)

The CcAgNPs solution was centrifuged with an Eppendorf Centrifuge (Model: 5804/5804 R, USA). The treated solutions were transferred separately into Eppendorf tubes that were pre-weighed, subjected to purification for 2 h at 5000 rpm at 4°C.

Animal Handling and Ethics Approval

Twenty-four (24) pathogen-free, male, Sprague-Dawley rats weighing 250 ± 20 g were selected for the experiments; they were kept and maintained under laboratory conditions at a temperature of $21.5 - 2.2^\circ\text{C}$, humidity ($60 \pm 1\%$), and 12 h light/dark cycle. They were allowed free access to food (standard pellets) and water and fed (*ad libitum*).

Animals were allowed seven days to acclimatize in their respective cages before commencement of experiments. The institutional Ethics Committee of the University of KwaZulu-Natal (Ethics references number AREC/074/016 D) approved experimental protocols and procedures used in this study.

Induction of Type 2 Diabetes

Hyperglycaemia was induced by injecting nicotinamide (100 mg/kg of body weight) (Sigma Aldrich, SA) and Streptozotocin (STZ, 60 mg/kg I.P). Nicotinamide was administered 15 min before the administration of STZ, which was dissolved in phosphate buffer citrate at pH 4.5 immediately before use (18). Animals were then kept under observation for confirmation of successful induction. Blood glucose was tested and monitored on days zero, seven, fourteen, twenty-eight, forty-two and fifty-six, respectively. The animals were tested using Accu - chek Active 50 (Roche), blood glucose strips (Dischem, South Africa), with blood collected from the tail vein of the rats at 10 am daily. The animals with a fasting blood glucose level > 9 mmol/L were considered diabetic.

Experimental Design

Six experimental Sprague-Dawley STZ induced diabetic rats were assigned randomly to the different groups and received different treatment protocols. In Group A (control), rats received normal saline (1 mL) orally once per day.

Group B rats were administered with CcAgNPs at low dose (5 mg/kg) orally, once per day. Group C rats were administered with CcAgNPs at high dose (10 mg/kg) orally, once per day. Group D rats were administered with plant extracts at 200 mg/kg. CcAgNPs and plant extracts were dissolved in normal saline and administered orally once daily at 10 am for 56 consecutive days, using a rat gavage needle.

Fasting blood glucose (FBG) was measured on days 0, 14, 28, 42 and 56. Body weight was recorded every week in the morning between 8:00 and 10:00 am using an electronic balance (Zeiss, West Germany (Pty) Ltd; 0.000 g calibration). At the end of the experiment, all rats were sacrificed with excess Halothane anaesthesia. Blood was then collected via transcardiac puncture for biochemistry and organs harvested after laparotomy for histology studies. In addition, the weight of the kidneys was recorded.

Histopathological Examination of Kidney Tissues

Kidneys were washed in saline and fixed in 10% neutral buffered formalin for 24 h. Samples were transferred to 70% ethanol (Bailey and Day, 1989). They were then processed using ascending grades of alcohol to dehydrate the samples, and xylene was used as the clearing agent. Samples were mounted in molten paraffin at 58 - 62°C. Slices (5 µm) were cut using a microtome (Microtome HM 315, Walldorf, Germany) from the prepared blocks and stained with hematoxylin and eosin dyes (H & E).

Additionally, the periodic Acid-Schiff (Inzucchi et al.,2012) staining technique used in routine histopathological investigations that detects the presence of polysaccharides (e.g. glycogen) and muco-substances (e.g. glycoproteins, glycolipids and mucins) in tissues or slides, was used. The PAS technique is most commonly used to demonstrate the thickness of glomerular basement membrane when renal disease is being assessed. Sections were viewed and photographed using an Olympus light microscope (Olympus BX51, Tokyo, Japan) with an attached camera (Olympus E-330, Olympus Optical Co. Ltd., Tokyo, Japan).

Transmission electron microscope (TEM)

Transmission electron microscope (TEM) was used to further provide a more detailed morphologic and compositional information on samples (most especially on Glomeruli and tubules). This was done after the tissues were fixed overnight at 4°C in 3% glutaraldehyde in 0.1 M sodium cacodylate buffer (pH 7.4) and transferred to 0.1 M phosphate buffer (pH 7.2). The cells were postfixed in 1% osmium tetroxide in S-collidine, dehydrated in graded ethanol, transferred to propylene oxide, and embedded in Epon 812. Semi-thin sections were stained with 1% methylene blue. The samples were further sectioned into ultrathin slices (75 nm), contrasted with uranyl acetate and lead citrate and observed on a transmission electron microscope (Bressenot et al., 2009).

Statistical Analysis

All results are presented as the mean \pm standard error of mean (SE). Statistical analysis was performed using one-way analysis of variance (Oberdörster et al.) followed by Turkey's post-hoc test with Graph Pad Prism 5 version 2007. Comparisons with $P < 0.05$ were considered to be statistically significant.

Results

Synthesis of *Cinnamomum Cassia* Silver Nanoparticles (CcAgNP_s)

The aqueous solution of biosynthesized AgNPs from *C. cassia* powder gave a dark brown colour which was a visual indication of the formation of AgNPs (150 mg).

Effects of *Cinnamomum Cassia* Silver Nanoparticles (Ccagnps) on the Histomorphology of Kidneys

Histological sections of kidney tissues (H & E) in the diabetic control group showed a generalised distortion in glomerular architecture with atrophic and necrotic changes, pyknotic nuclei as well as infiltrations of mesangial spaces and interstitium. Many of the proximal and distal convoluted tubules showed hypertrophic cells and vacuolization (Figure)

Kidney sections of animals administered with 5 mg/kg of CcAgNPs showed moderate degenerative changes in the glomeruli. The mesangium and interstitium were essentially normal with cellular components (Figure). In rats treated with high doses of CcAgNPs (10 mg/kg), kidney sections

(Figure) showed glomeruli with Bowman's space and capillary tufts essentially normal, compared to controls. The kidney sections of the normal control (Figure) was essentially normal with clearly visible glomeruli, basement membrane of capsular wall as well as mesangial tissues. The interstitium was essentially normal with no infiltrations.

PAS-stained sections of the diabetic control (Group A) showed kidney sections with glomerular distortions and ruptured capsular wall (stained purple), thickened basement membranes as well as hypocellularity in the interstitial components. Kidney sections in groups B and C (treated with CcAgNPs at different doses) shows a better histological PAS-staining intensity for glycogens and the capsular walls of the glomeruli in the low-dose group.

The mesangial tissues were clearly delineated and interstitial tissue did not indicate any abnormalities. Group D (normal control) showed kidney sections that are well preserved and PAS-positive glomerular capsular basement layers stained purple indicating a normal glomerular tuft/capillary meshwork. The proximal and distal convoluted tubular cells are clearly shown with no abnormality and the glycogen-stained membranes of tubules are clearly visible (purple).

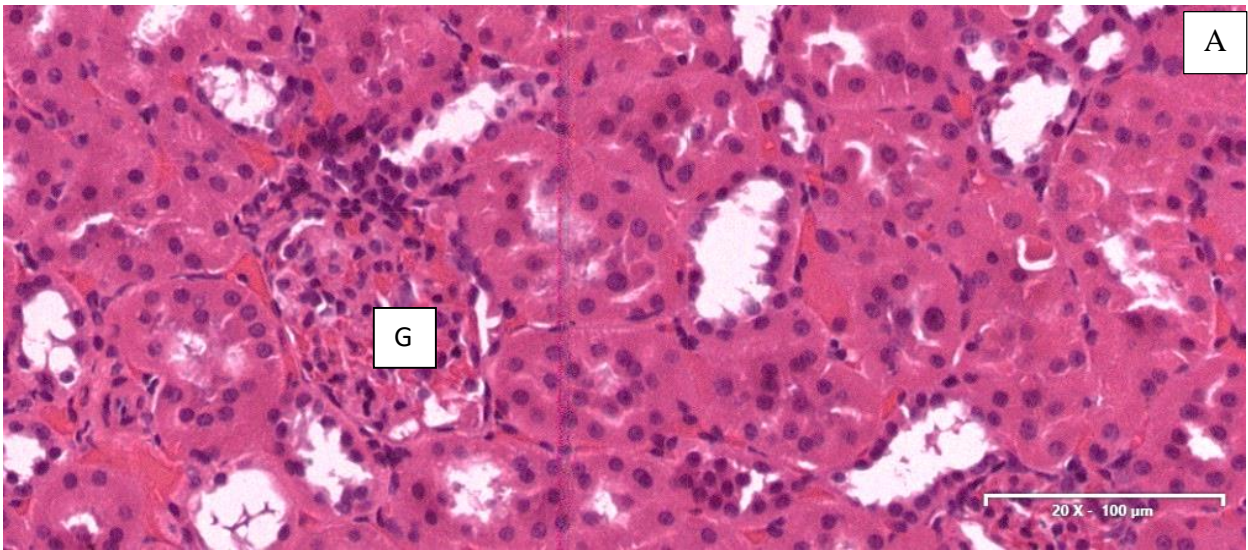


Figure 1: Kidney sections (H & E) from STZ- diabetic Rats-Control group

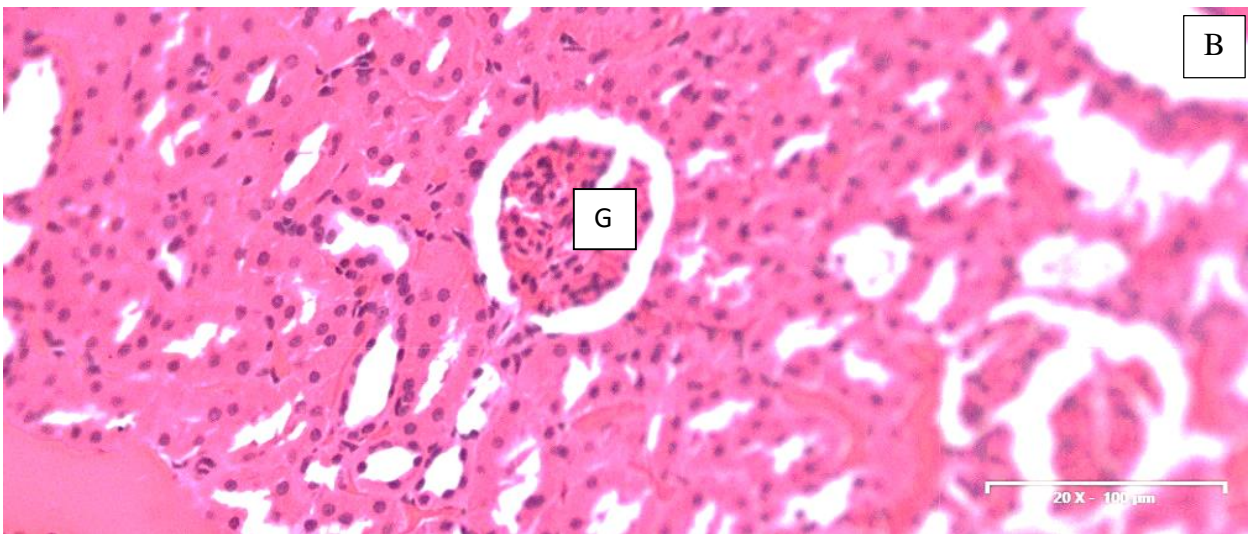


Figure 2. Kidney sections (H & E) from STZ- diabetic rats after treatment with *Cinnamomum cassia* silver nanoparticles (CcAgNPs). -(5 mg/kg).

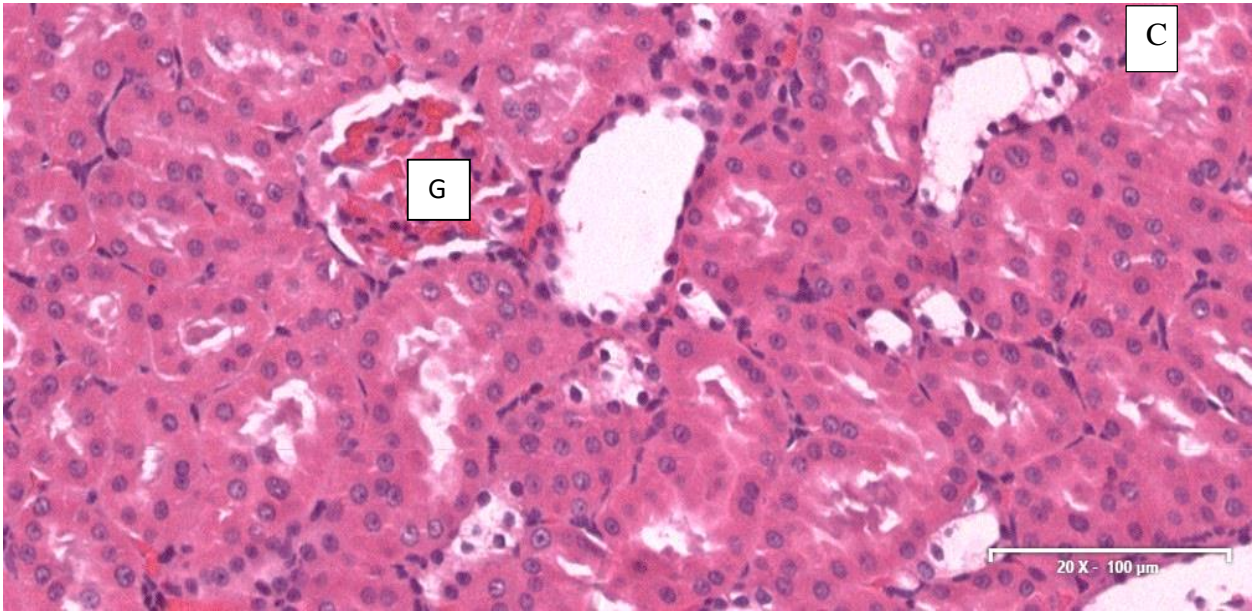


Figure 3. Kidney sections (H & E) from STZ- diabetic rats after treatment with *Cinnamomum cassia* silver nanoparticles (CcAgNPs). (10 mg/kg)

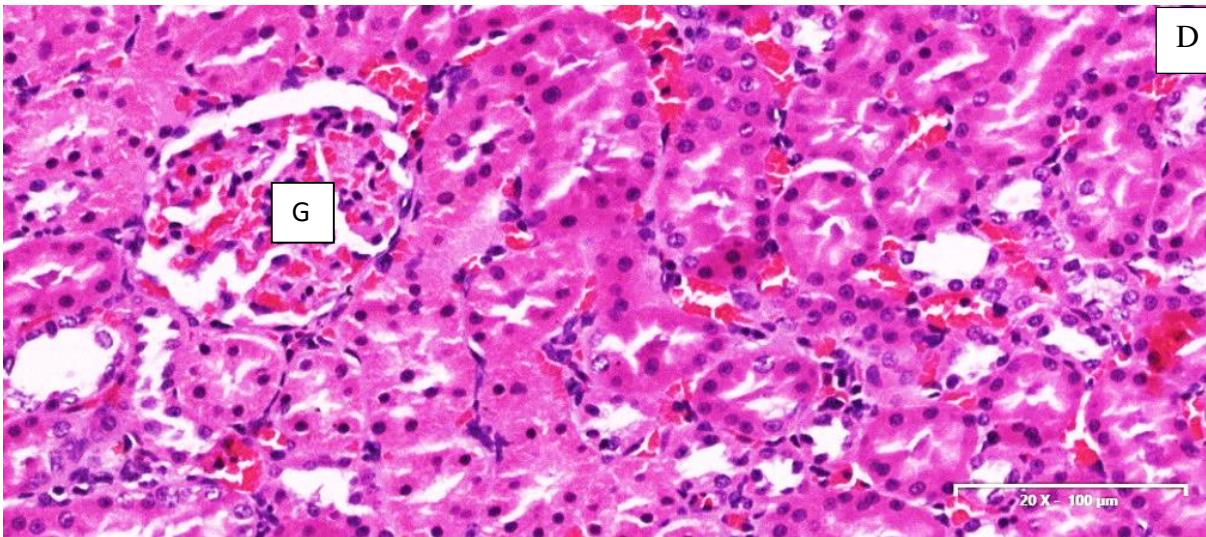


Figure 4. Kidney sections (H & E) from STZ- diabetic rats after treatment with *Cinnamomum cassia*

Ultrastructural Findings of Transmission Electron Microscopy




Figure 2: bowman space—diabetic group under treatment (CcAgNPs).

(magnification X10000)—scale 1 μ m

A= Glomeruli –B=Urine Space

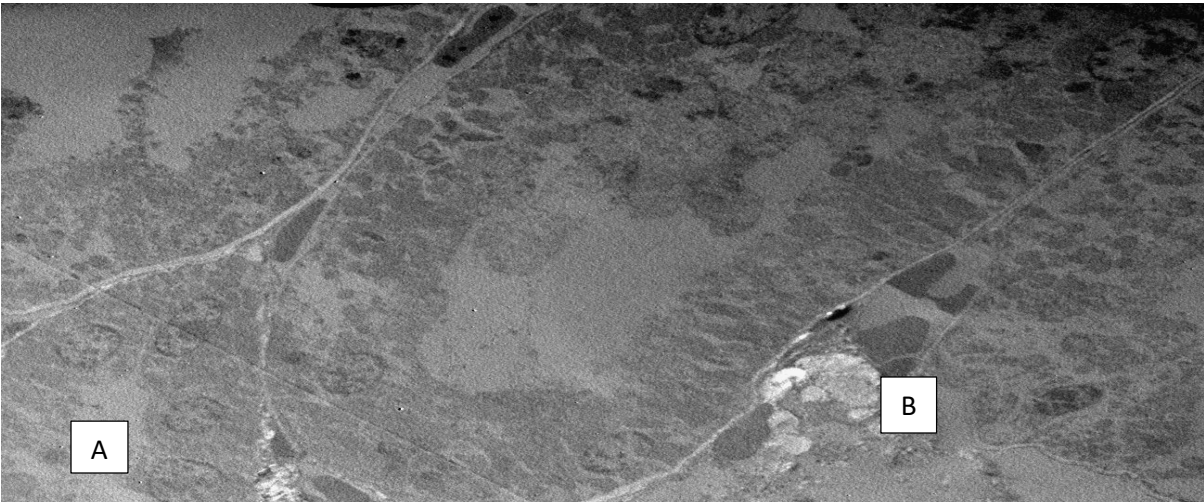

Figure 1: Diabetic group-control.
(magnification X10000)—scale 1 μ m
A= Glomeruli –B=Urine Space

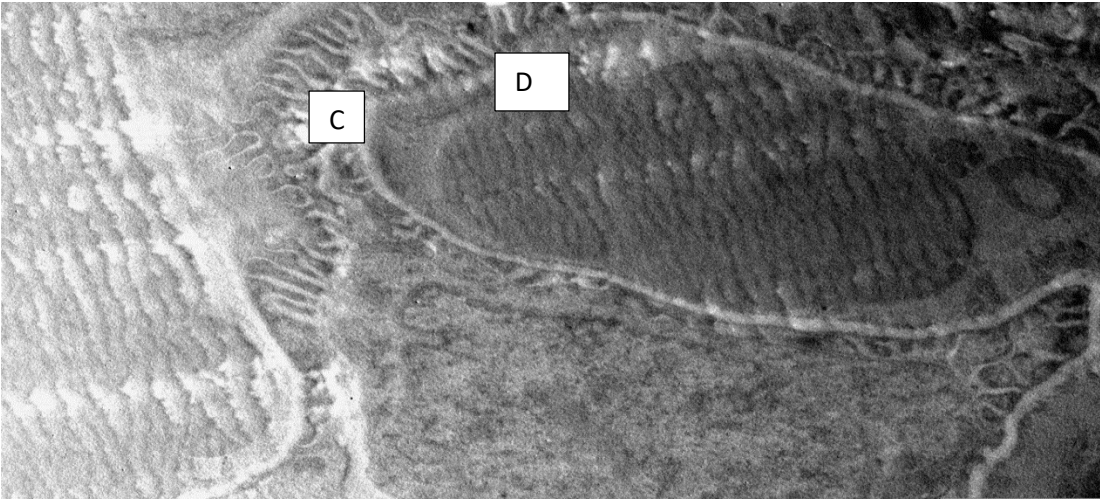


Figure 3: Glomerular basement membrane and podocytes
(magnification X10000)—scale 1 μ m C=Podocytes –D=Glomeruli Membrane

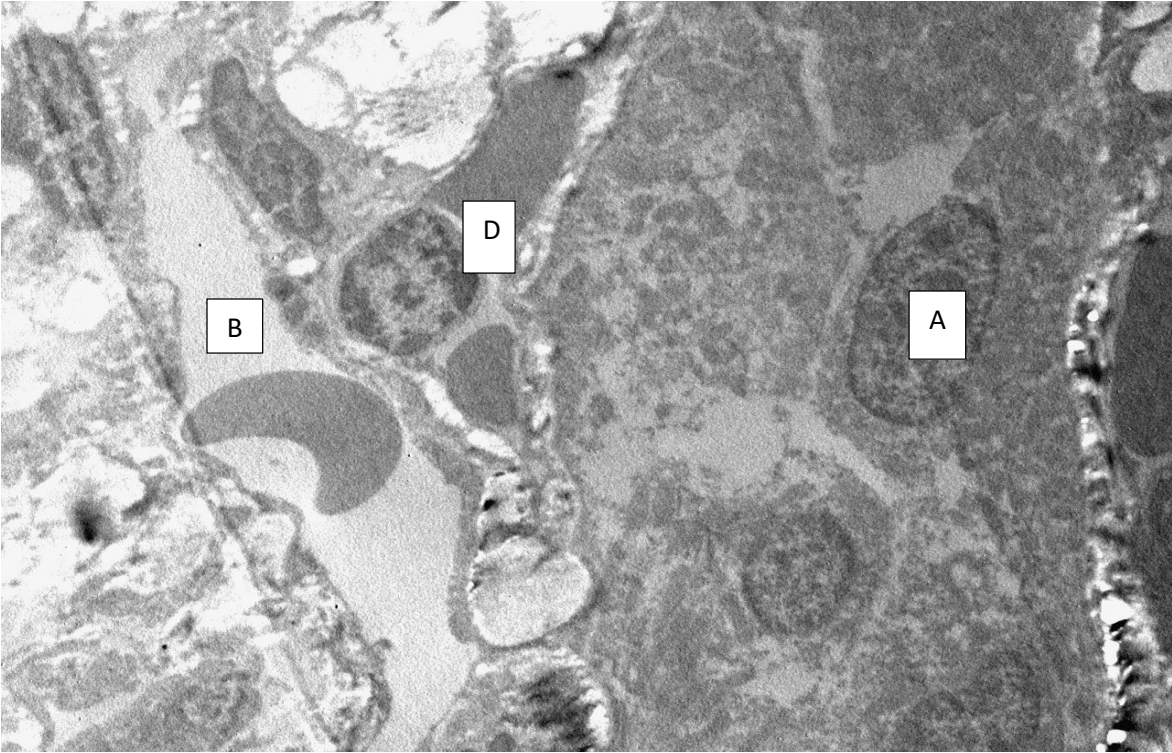


Figure 4:A control diabetic

(Magnification X 10000) Scale bar 1 μm , A= Glomeruli –B=Urine Space, D=Glomerular Membrane.

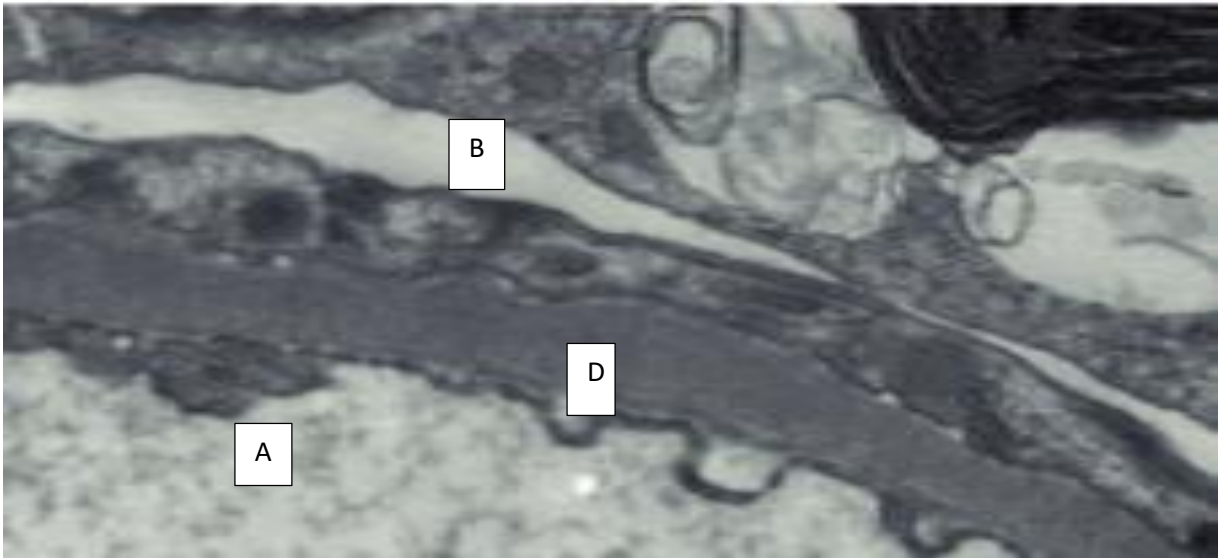


Figure 4:B control diabetic group.

(Magnification 10000), Scale Bar 1 μ m

MANUSCRIPT FIVE

Stereological study of the effects of *Cinnamomum cassia* silver nanoparticles, on the RENAL corpuscles, of diabetics Sprague-Dawley rats.

Koffi Kouame¹, Aniekan Imo Peter¹, Edidiong Nnamso Akang^{1,2}, Roshila Moodley^{3*}, Edwin

Coleridge Naidu¹, Onyemaechi Okpara Azu^{1,4}

¹Discipline of Clinical Anatomy, School of Laboratory Medicine and Medical Sciences, University of KwaZulu-Natal, Private Bag X 54001, Durban 4000, South Africa.

²Department of Anatomy, College of Medicine, University of Lagos, Idi-Araba, Lagos, Nigeria.

³School of Chemistry and Physics, University of KwaZulu-Natal, Westville Campus. Private Bag X54001, Durban, 4000, South Africa.

⁴Department of Anatomy, School of Medicine, University of Namibia, Windhoek, Namibia

* Corresponding author: Discipline of Clinical Anatomy, School of Laboratory Medicine and Medical Sciences, University of KwaZulu-Natal, Westville Campus. Private Bag X54001, Durban, 4000, South Africa. Phone: +27312604305. E-mail: azu@ukzn.ac.za; oazu@unam.na

Abstract

Cinnamomum cassia was extracted to investigate its ant hyperglycemic and protective effects on renal structural changes in STZ-induced diabetes. Eighteen male Sprague Dawley rats were divided into three groups randomly; the first group as diabetic control, the second group as diabetic treated with low dose (5 mg/kg) of CcAgNPs, the third group treated with high dose of CcAgNPs (10mg/kg), through oro-gavage, respectively, for 56 days. Diabetes was induced by administration of 60 mg/kg bw of Streptozotocin intraperitoneally.

Serum glucose level was monitored every day. At the 56 th day, the subjects were sacrificed and the kidneys were removed. Tissue sections were stained by periodic acid Schiff and used for stereological analysis. The means were compared by one-way ANOVA and Tukey's post hoc test at the significance level of $P < 0.05$. The results showed that CcAgNPs significantly restored the blood glucose level toward normal level. High dose of CcAgNPs could significantly decrease the length and space of the bowman space and dimensions of proximal and distal tubules. Both doses of CcAgNPs could significantly prevent the glomerular hypertrophy and reduction of the basement membrane under the effect of CcAgNPs, compared to control. It can be concluded that CcAgNPs at high dose can ameliorate structural nephropathy in diabetic Sprague Dawley rats.

INTRODUCTION

Type 2 diabetes mellitus is about 90% diabetes and had universal widespread evaluate of 2.8% in the year 2000 and is expected to be 4.4% in 2030 (Wild, 2004). Both Type 1 and Type 2 diabetes, complex pathophysiology, including insulin resistance syndrome and hyperglycaemia, which are associated with abnormalities in reactive nitrogen species and fat species (Brownlee, 2001; Green et al., 2004). Streptozotocin (STZ) is surely wide vision antibiotic and cytotoxic chemical that is Three days after the administration of streptozotocin, the development of diabetes in two experimental groups was confirmed by measuring the glucose levels in the blood. Diabetes mellitus is the very popular lifestyle illness distinguished via high blood glucose level and glucose intolerance due to insulin insufficiency, reduced performances 5% of the world community human murderer after cancer and cardiovascular sickness (Taylor, 1999). Type 1 diabetes mediated autoimmune demolition of pancreatic islet beta cells, driving to lack of insulin output. It has ability to take place at all ages. Type 2 diabetes mellitus is about 90% - 95% of all diabetes and had universal widespread evaluate of 2.8% in the year 2000 and is expected to be 4.4% in 2030 (Wild et al., 2004). Both Type 1 and Type 2 diabetes mellitus have complex pathophysiology, including insulin resistance syndrome and hyperglycaemia, which are associated with abnormalities in reactive nitrogen species and fat species., 2004). It has been vastly utilized to stimulate diabetes in animal models particularly rats and mice (Brentjens and Saltz, 2001; Hayashi et al., 2006). Early diabetes mellitus and acute experimental diabetes have been shown to improve renal function and glomerular function (Hostetter, 1981). The number of glomeruli in a kidney can change as a result of disease A decrease in the number of glomeruli ca (John et al., 1992).

The basement membrane thickening is a broadly acknowledged distinctive of small blood vessel diabetic illness (Huang, 1980). In glomeruli and kidneys of diabetic patients, marked basement membranes thickening is monitored. Furthermore, it is believed this alteration might result in the kidneys premature degeneration (Steffes et al., 1979; Isogia experimental diabetes mellitus in animal, STZ and Alloxan are widely utilized medicines. STZ and Alloxan diabetogenic factors damage the B cell of the pancreas. In addition, they have various cytotoxic activities. Intracellular construction of hydrogen peroxide, hydroxyl radicals and superoxide radicals are generated by reaction the Alloxan. Commons Attribution License, which permits toxic to the pancreatic, insulin making beta cells in mammals (Szkudelski, 2001; Hayashi et al., 2006; Takeshita et., 2006). It has been vastly utilized to stimulate diabetes in animal models particularly rats and mice (Brentjens and Saltz, 2006). Early diabetes mellitus and acute experimental diabetes have been shown to improve renal function and glomerular function (Mogensen and Andersen, 1984). The number of glomeruli in a kidney as a result of disease and aging (Heptinstall, 1983). A decrease in the number of glomeruli causes various diseases., 1992). The basement membrane thickening is a broadly acknowledged distinctive of small blood vessel diabetic illness (Huang, 1980). In glomeruli and capillaries in kidneys of diabetic patients, marked basement membranes thickening is monitored. Furthermore, it is believed this alteration might result in the kidneys premature degeneration., 1979; Isogia et al., 1998). As to make entail diabetes contain trace quantities of reactive iron within secondary lysosomes. The lysosomal hydrolases seepage and further cellular degeneration is caused by the ensuing lysosomal membrane damage. The weakness excretion of insulin results in production of nitrite, energizing of islet guanylyl cyclase and collection of cGMP, and inhibition of islet mitochondrial aconitase activity occurred when STZ through the glu transporter (GLUT2) come in to the B cell.

The local liberation of nitric oxide from STZ within islets might mediate impact of STZ on β -cells. This might results in DNA alkylation and insulin tyrosine kinase receptor activity reduction. After that, the damaged DNA makes B cells go through the destruction via necrosis (Szkudelski, 2001).The most significant component of the volatile oil from *Nigella sativa* Thymoquinone (TQ). It has strong antioxidant characteristics. The organs are protected by TQ against oxidative impairment enthused via a range of free radical producing agents like doxorubicin evoked cardiotoxicity, carbon tetrachloride induced hepatotoxicity, nephropathy produced by cisplatin autoimmune and allergic encephalomyelitis and stom mucosal damage evoked via ischemia reperfusion (Nagi and Mansour, 2000; Al-Majed et al., 2006).

.MATERIALS AND METHODS

Materials and Methods

Collection of Plant Material

Pure *C. cassia* powder was obtained from Warren Chemistry Specialities (Pty), Cape Town (Reference 492733) and silver nitrate (AgNO_3) was obtained from Capital Laboratory (Pty), KwaZulu-Natal.

Preparation of Aqueous Plants Extract

The aqueous extract of *C. cassia* was prepared by adding a fine powder of the plant (10 g) to 300 mL of double-distilled water, which was allowed to boil for 10 min. The resulting mixture was filtered and stored in a refrigerator at 4°C until analysed.

Synthesis of *Cinnamomum Cassia* Silver Nanoparticles (CcAgNP_s)

An aqueous solution of AgNO₃ was dissolved in 250 mL Erlenmeyer flasks, and was then added, dropwise into 100 mL of the plant extract while stirring and heated at 45°C. This solution was stirred constantly at room temperature using a magnetic stirrer for 120 minutes. A colour change from light brown to dark brown indicated the formation of AgNPs.

Structural Analysis of *Cinnamomum Cassia* Silver Nanoparticles (CcAgNP_s)

The CcAgNPs solution was centrifuged with an Eppendorf Centrifuge (Model: 5804/5804 R, USA). The treated solutions were transferred separately into Eppendorf tubes that were pre-weighed, subjected to purification for 2 h at 5000 rpm at 4°C.

Animal Handling and Ethics Approval

Twenty-four (24) pathogen-free, male, Sprague-Dawley rats weighing 250 ± 20 g were selected for the experiments; they were kept and maintained under laboratory conditions at a temperature of $21.5 - 2.2^\circ\text{C}$, humidity ($60 \pm 1\%$), and 12 h light/dark cycle. They were allowed free access to food (standard pellets) and water and fed (*ad libitum*).

Animals were allowed seven days to acclimatize in their respective cages before commencement of experiments. The institutional Ethics Committee of the University of KwaZulu-Natal (Ethics references number AREC/074/016 D) approved experimental protocols and procedures used in this study.

Induction of Type 2 Diabetes

Hyperglycaemia was induced by injecting nicotinamide (100 mg/kg of body weight) (Sigma Aldrich, SA) and Streptozotocin (STZ, 60 mg/kg I.P). Nicotinamide was administered 15 min before the administration of STZ, which was dissolved in phosphate buffer citrate at pH 4.5 immediately before use (18). Animals were then kept under observation for confirmation of successful induction. Blood glucose was tested and monitored on days zero, seven, fourteen, twenty-eight, forty-two and fifty-six, respectively. The animals were tested using Accu - chek Active 50 (Roche), blood glucose strips (Dischem, South Africa), with blood collected from the tail vein of the rats at 10 am daily. The animals with a fasting blood glucose level > 9 mmol/L were considered diabetic.

Experimental Design

Six experimental Sprague-Dawley STZ induced diabetic rats were assigned randomly to the different groups and received different treatment protocols. In Group A (control), rats received normal saline (1 mL) orally once per day. Group B rats were administered with CcAgNPs at low dose (5 mg/kg) orally, once per day (7). Group C rats were administered with CcAgNPs at high dose (10 mg/kg) orally, once per day (7). Group D rats were administered with plant extracts at 200 mg/kg. CcAgNPs and plant extracts were dissolved in normal saline and administered orally once daily at 10 am for 56 consecutive days, using a rat gavage needle (17).

Fasting blood glucose (FBG) was measured on days 0, 14, 28, 42 and 56. Body weight was recorded every week in the morning between 8:00 and 10:00 am using an electronic balance (Zeiss, West Germany (Pty) Ltd; 0.000 g calibration). At the end of the experiment, all rats were sacrificed with excess Halothane anaesthesia. Blood was then collected via transcardiac puncture for biochemistry and organs harvested after laparotomy for histology studies. In addition, the weight of the kidneys was recorded.

Histopathological Examination of Kidney Tissues

Kidneys were washed in saline and fixed in 10% neutral buffered formalin for 24 h. Samples were transferred to 70% ethanol (Bailey and Day, 1989). They were then processed using ascending grades of alcohol to dehydrate the samples, and xylene was used as the clearing agent. Samples were mounted in molten paraffin at 58 - 62°C. Slices (5 µm) were cut using a microtome (Microtome HM 315, Walldorf, Germany) from the prepared blocks and stained with hematoxylin and eosin dyes (H & E).

Additionally, the periodic Acid-Schif staining technique used in routine histopathological investigations that detects the presence of polysaccharides (e.g. glycogen) and muco-substances (e.g. glycoproteins, glycolipds and mucins) in tissues or slides, was used. The PAS technique is most commonly used to demonstrate the thickness of glomerular basement membrane when renal disease is being assessed (54). Sections were viewed and photographed using an Olympus light microscope (Olympus BX51, Tokyo, Japan) with an attached camera (Olympus E-330, Olympus Optical Co. Ltd., Tokyo, Japan).

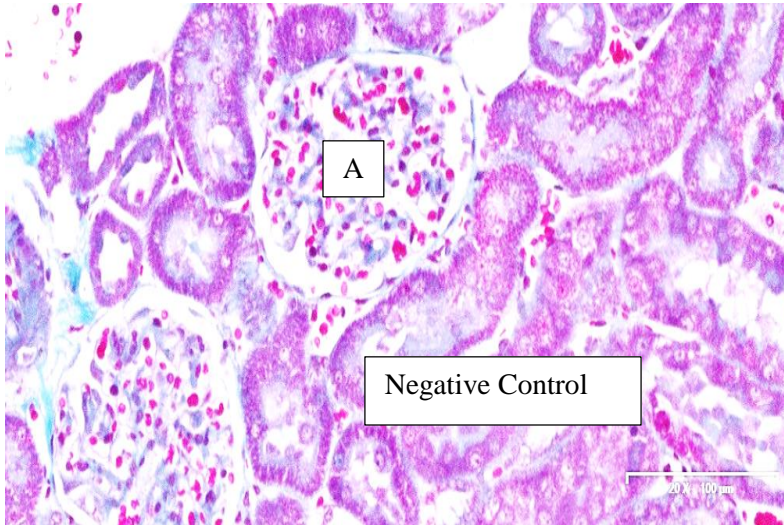


Figure 1: Normal Glomerulus, A

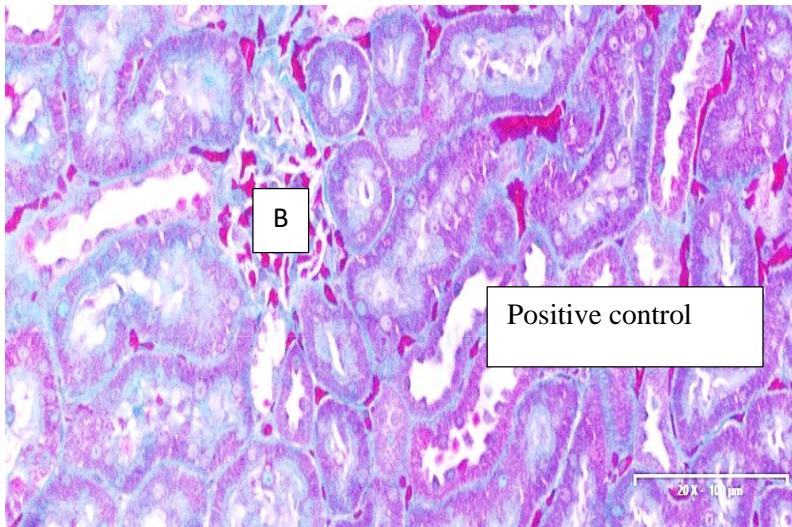
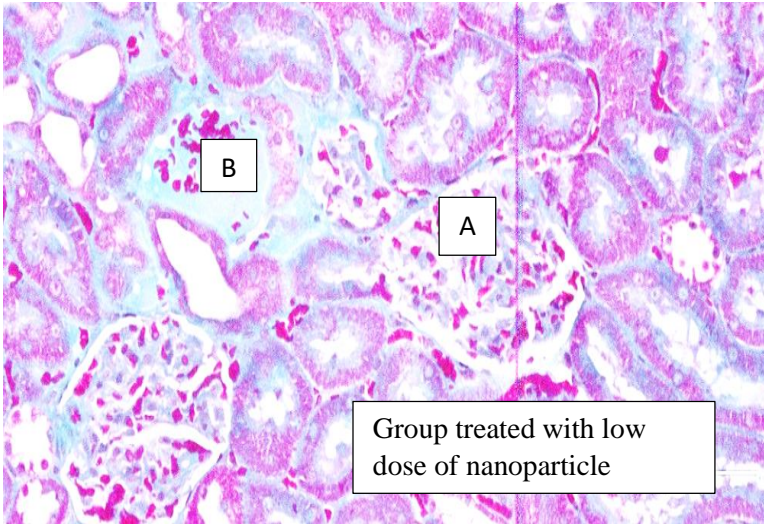


Figure 2: Damaged Glomerulus, B



Glomerula, A and B

Figure 3: Damaged and Undamaged

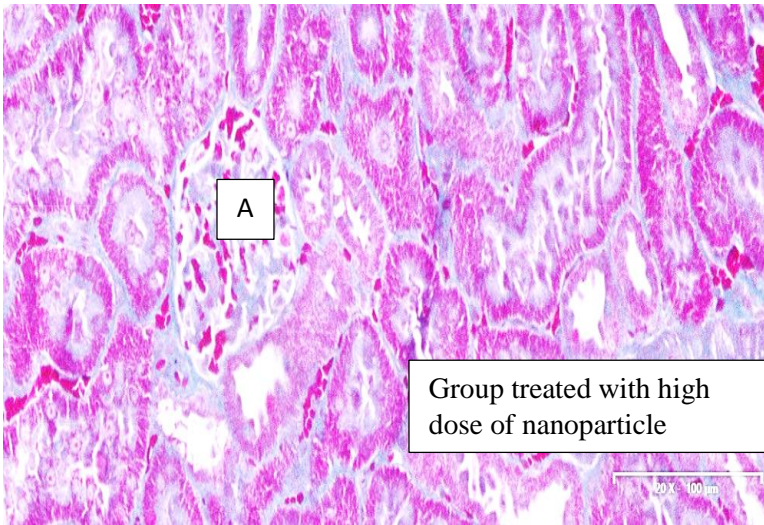
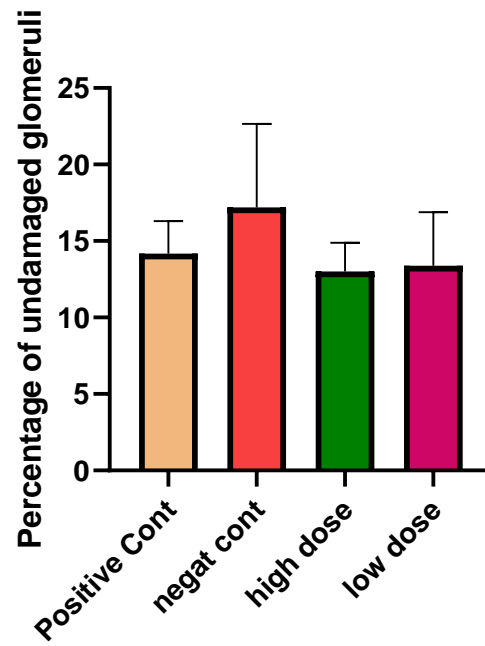


Figure 4: Undamaged Glomerus,A



Treatment groups with Cinnamon silver nanoparticle

Figure 5: Indicating the percentage of Undamaged glomeruli, within separate treatment groups