

**THE EFFECT OF CHILDBIRTH ON THE ANAL SPHINCTERS**  
**DEMONSTRATED BY**  
**ANAL ENDOSONOGRAPHY AND NEUROPHYSIOLOGICAL TESTS**

**by**

**ABDUL HAMEED SULTAN**

**Submitted in partial fulfilment of**

**the requirements for the degree of**

**DOCTOR OF MEDICINE**

**in the**

**Department of Obstetrics and gynaecology,**

**University of Natal**

**Durban, South Africa**

**1994**

## ABSTRACT

Obstetric trauma is a major cause of faecal incontinence in women resulting in considerable social disability. Until recently the development of faecal incontinence has been attributed largely to damage to the pelvic nerves. However the advent of anal endosonography has added a new dimension to our understanding of the pathophysiology of faecal incontinence.

In this thesis, gross dissection and histological studies of 19 anorectal specimens was performed to demonstrate the normal anatomy. Simultaneous dissection and sonography of the anorectum (14 in vivo and 12 in vitro studies) has clarified the normal sonographic anatomy of the anal sphincters. Anal endosonography was performed in 114 healthy volunteers to demonstrate gender differences in anal sphincter anatomy. A prospective study of 12 patients undergoing secondary sphincter repair and 15 patients undergoing lateral internal anal sphincterotomy has validated the appearance of sonographic sphincter defects. A new technique of demonstrating the anal sphincters at rest using vaginal endosonography has been demonstrated in 20 women.

A prospective study of 202 pregnant women using anal endosonography and neurophysiological tests has demonstrated that 35% of primigravidae (13% symptomatic) and 44% of multigravidae (23% symptomatic) develop occult anal sphincter defects during vaginal delivery. Although pudendal nerve damage can be identified in 16% of women 6 weeks after delivery, in the majority this recovers with

time. Forceps delivery was identified as the single independent variable associated with sphincter damage although damage was also sustained in the absence of instrumental delivery.

In a separate study of 50 women who sustained a recognised third degree tear 47% were found to be symptomatic despite a primary sphincter repair. In 85% of these women persistent anal sphincter defects were identified sonographically.

In a further study of 43 women who had an instrumental delivery (17 vacuum and 26 forceps) anal sphincter defects were identified in 81% (38% symptomatic) of women who were delivered by forceps compared to 12% (21% symptomatic) delivered by the vacuum extractor.

One hundred and fifty doctors and midwives were interviewed to assess their knowledge and training in perineal anatomy and repair. There was a clear deficiency in knowledge and inconsistencies in classification of third degree tears were apparent highlighting the need for more focused training in perineal anatomy and repair.

**Dedicated to**

**Razia, Shaista and Kabeer**

**If a man will begin with certainties,  
he shall end in doubts;  
but if he will be content to begin with doubts,  
he shall end in certainties.**

Francis Bacon 1626

## PREFACE

This research represents original work by the author and has not been submitted in any form to another University. Where use has been made of the work of others it has been duly acknowledged in the text.

The research described in this thesis was carried out in the Department of Obstetrics and Gynaecology, St Bartholomew's (Homerton) Hospital, West Smithfield, London and the Departments of Radiology, Physiology and Surgery at St Mark's Hospital, City Road, London, England.

The research described in this thesis was carried out under the supervision of Mr R. J. Nicholls and Professor R. W. Green Thompson.

## ACKNOWLEDGEMENTS

The author wishes to express his sincere gratitude to the following individuals for their assistance in the preparation of this thesis:

Dr Clive Bartram, consultant radiologist, St. Mark's Hospital, who conceived the main project following his pioneering work in anal endosonography as a diagnostic tool in the investigation of faecal incontinence.

Dr Michael Kamm, Consultant Gastroenterologist and Director of The Physiology Unit, St. Mark's Hospital, who trained me to perform anorectal physiology tests and critically reviewed my results.

Professor Christopher Hudson, Professor of Obstetrics and Gynaecology, St. Bartholomew's and Homerton Hospitals, who provided me with invaluable support and advice throughout this project.

My external supervisor (appointed by the University of Natal) Mr John Nicholls, Consultant Surgeon at St. Mark's Hospital and Post-graduate Dean, who provided me with constant encouragement, guidance and allowed me to validate the interpretation of anal endosonographic images during surgery.

My internal supervisor, Professor R.W. Green-Thompson, Head of the Department of Obstetrics and Gynaecology at King Edward VIII Hospital, Natal, for his support

and encouragement in writing this thesis.

Professor Kallichurum from the pathology department at King Edward VIII hospital for some of the post mortem anorectal specimens that were used in this thesis.

At St. Mark's Hospital I would like to thank all the consultant surgeons for their support and also for allowing me to study their patients; the pathology staff, particularly Dr. Ian Talbot for the preparation and assistance in interpretation of histology slides; Nigel Webb, the medical illustrator has been of tremendous assistance to me particularly for his excellent and skilful preparation of prints and drawings presented in this thesis; Peter Lunniss, a colleague and associate research fellow, with whom I jointly performed dissections of post mortem and surgical anorectal specimens.

Professor Tim Chard of the Academic Unit of Obstetrics and Gynaecology and Reproductive Physiology of St Bartholomew's Hospital for his assistance, guidance and constant vigilance throughout this project.

All the obstetric consultants at The Homerton Hospital for allowing me to study their patients and also to the antenatal clinic staff for accommodating me whilst conducting this research.

My appreciation to The Joint Research Board of St Bartholomew's Hospital and the Clinical Directorate of Obstetrics and Gynaecology for funding this project. Financial

assistance was also given by the Directorates of the Departments of Radiology and Physiology of St Mark's Hospital. I have also been granted three travel grants for international presentations by The Wellcome Trust, Beecham Research Laboratories and St Mark's Research Foundation.

Last but not least, my sincere thanks to all the men and women who selflessly volunteered to participate in the studies described in this thesis. Undoubtedly, the findings in this thesis would not have been possible without their participation.

**PUBLICATIONS ARISING FROM THIS THESIS****A] ORIGINAL ARTICLES**

1. Sultan AH, Nicholls RJ, Kamm MA, Hudson CN, Beynon J, Bartram CI.  
Anal Endosonography and correlation with in vitro and in vivo anatomy.  
Br J Surg 1992; 80: 808-811.
  
2. Sultan AH, Kamm MA, Hudson CN, Thomas JM, Bartram CI.  
Anal sphincter disruption during vaginal delivery.  
N Engl J Med 1993; 329: 1905-1911.
  
3. Sultan AH, Kamm MA, Hudson CN, Bartram CI.  
Effects of pregnancy on anal sphincter function and morphology.  
Int J Colorect Dis 1993; 8: 206-209.
  
4. Sultan AH, Kamm MA, Bartram CI, Hudson CN.  
Anal sphincter trauma during instrumental delivery. A comparison  
between forceps and vacuum extraction.  
Int J Gynecol Obstet 1993; 43: 263-270.
  
5. Sultan AH, Kamm MA, Hudson CN.  
Pudendal nerve damage during labour: prospective study before and  
after childbirth.  
Br J Obstet Gynaecol 1994; 101: 22-28.

6. Sultan AH, Kamm MA, Talbot IC, Nicholls RJ, Bartram CI.  
Anal endosonography: Precision of identifying sphincter defects confirmed histologically.  
Br J Surg 1994; 81: 463-465.
7. Sultan AH, Kamm MA, Nicholls RJ, Hudson CN, Bartram CI.  
Endosonography of the anal sphincters: normal anatomy and comparison with manometry.  
Clin Radiol 1994; 49: 368-374.
8. Sultan AH, Kamm MA, Hudson CN, Bartram CI.  
Third degree obstetric anal sphincter tears: risk factors and outcome of primary repair.  
Br Med J 1994; 308: 887-891.
9. Sultan AH, Kamm MA, Nicholls RJ, Bartram CI.  
Internal anal sphincter division during lateral sphincterotomy. Prospective ultrasound study.  
Dis Colon Rectum 1994; 37: 708-718.
10. Sultan AH, Loder PB, Kamm MA, Hudson CN, Bartram CI.  
Vaginal endosonography: A new technique of imaging the anal sphincters at rest.  
Dis Colon Rectum 1994; 37: 1296-1299.

11. Sultan AH, Kamm MA, Hudson CN.  
Obstetric perineal tears: an audit of training.  
J Obstet Gynaecol 1995; 15: 19-23.
  
12. Engel AF, Kamm MA, Sultan AH, Bartram CI, Nicholls RJ.  
Anterior anal sphincter repair in patients with obstetric trauma.  
Br J Surg 1994; 81: 1231-1234.
  
13. Halligan S, Sultan AH, Rottenberg G, Bartram CI.  
Endosonography of the anal sphincters in solitary rectal ulcer syndrome.  
Int J Colorect Dis 1995; 10: 79-82.

#### **BJ REVIEWS AND EDITORIALS**

1. Sultan AH, Kamm MA, Bartram CI, Hudson CN.  
Perineal damage at delivery.  
Contemp Rev Obstet Gynaecol 1994; 6: 18-24.
  
2. Bartram CI, Sultan AH.  
Anal Endosonography in faecal incontinence.  
Gut, Leading article, 1995; 37: 4-6.

3. Sultan AH, Kamm MA, Hudson CN, Thomas JM, Bartram CI.  
Anal sphincter disruption during vaginal delivery.  
Obstet Gynecol Survey 1994; 49(6): 382-383.

#### **C] CHAPTERS IN BOOKS**

1. Sultan AH, Kamm MA.  
Ultrasound of the anal sphincter.  
In: Schuster MM, ed. Atlas of gastrointestinal motility in health and disease. Baltimore: Williams and Wilkins, 1993: 115-121.

#### **[D] LETTERS**

1. Sultan AH, Kamm MA.  
Relationship between parity and anal manometry.  
Dis Colon Rectum 1993; 36(8):783-784.

#### **[E] PUBLISHED ABSTRACTS**

1. Sultan AH, Kamm MA, Bartram CI, Hudson CN. Pudendal nerve damage during childbirth: prospective study pre and post delivery. Gut 1992; 33:S65.

2. Sultan AH, Nicholls RJ, Kamm MA, Hudson CN, Beynon J, Bartram CI. Redefined anal sphincter anatomy - Endosonographic dissection and in vitro studies. *Gut* 1992; 33:S65.
3. Sultan AH, Kamm MA, Hudson CN, Bartram CI. Vaginal delivery causes anal sphincter disruption in 37% of patients (prospective ultrasound study) - A major determinant for development of faecal incontinence. *Gastroenterol* 1992; 102: A522.
4. Sultan AH, Kamm MA, Bartram CI, Hudson CN. Third degree tears: incidence, risk factors and poor clinical outcome after primary sphincter repair. *Gut* 1992; 33(2):S28.
5. Sultan AH, Kamm MA, Hudson CN, Bartram CI. Do female sex hormones affect anal sphincter function and morphology? *Gastroenterol* 1993; 104(4):A588.
6. Sultan AH, Kamm MA, Hudson CN, Bartram CI. Internal anal sphincter damage during sphincterotomy is underestimated. Prospective ultrasound study. *Gut* 1993; 34(1):S41.
7. Sultan AH, Kamm MA, Hudson CN, Bartram CI. Anal sphincter damage occurs in 80% of forceps but only 24% of vacuum deliveries; A major determinant for the development of faecal incontinence. *Gut* 1993; 34(1):S41.

8. Sultan AH, Kamm MA, Hudson CN, Bartram CI. Anal endosonography in fecal incontinence: The new gold standard in diagnosing sphincter defects. *Gastroenterol* 1993; 104(4):A589.
9. Sultan AH, Kamm MA, Hudson CN. Obstetric related pudendal nerve damage can be asymmetrical, and can occur following a Cesarean section: a prospective study. *Gastroenterol* 1993; 104(4):A588.
10. Sultan AH, Hudson CN. Are junior doctors and midwives adequately trained to repair the perineum? *J Obstet Gynaecol* 1993; 13:484-5.
11. Sultan AH, Kamm MA, Bartram CI, Hudson CN. Anal endosonography: an important investigation following traumatic vaginal delivery. *Ultrasound Obstet Gynecol* 1993; 3(1):36.

**PRESENTATIONS:**

- 25.3.92 British Society of Gastroenterology, Sheffield:
- Pudendal nerve damage during childbirth: prospective study pre and post delivery.

- 25.3.92 British Society of Gastroenterology, Sheffield:
- Redefined anal sphincter anatomy - Endosonographic dissection and in vitro studies.
- 13.5.92 American Gastroenterological Association, San Francisco, USA.
- Vaginal delivery causes anal sphincter disruption in 37% of patients - A major determinant for development of faecal incontinence.
- 28.6.92 European Association of Obstetrics and Gynaecology, Helsinki, Finland
- Anal sphincter disruption during vaginal delivery.
- 7.7.92 British Congress of Obstetrics and Gynaecology, Manchester, UK:
- Third degree tears: incidence and poor outcome of primary sphincter repair.
- 9.9.92 British Society of Gastroenterology, Warwick, UK:
- Third degree tears: incidence, risk factors and poor clinical outcome after primary sphincter repair.
- 18.9.92 South African Society of Obstetrics and Gynaecology Congress, Transkei,
- Anal sphincter disruption during vaginal delivery.
- 20.9.92 Cuthbert Crighton Research Forum (South Africa):
- Third degree anal sphincter anal tears and primary repair.

- 20.10.92 William Harvey Day, St. Bartholomew's Hospital, London:
- Anal sphincter disruption during vaginal delivery.
- 21.11.92 Swiss Institute of Coloproctology, Bern, Switzerland:
- Anal Endosonography: technique, interpretation and clinical application.
- 24.11.92 Zurich Postgraduate Surgical Meeting, Triemli Hospital, Switzerland:
- Faecal incontinence: traumatic or neurogenic?
- 4.12.92 Pelvic Floor Discussion Group, St. Mark's Hospital, London:
- Obstetric sphincter damage: the full extent revealed with endosonography and electrophysiology.
- 14.2.93 The Victor Bonney Society Meeting, Hampshire, London:
- Are junior doctors and midwives adequately trained to repair the perineum?
- 18.2.93 International Motility Workshop, St Mark's Hospital, London:
- Mechanisms of incontinence.
  - Live video demonstration of anal endosonography and anorectal physiology tests.

- 17.2.93 The American Gastroenterological Association, Boston, USA:
- Anal endosonography in faecal incontinence: The new gold standard in diagnosing sphincter defects.
- 9.7.93 2nd International Meeting of the European Society of Endosonography in Gynecology and Obstetrics, Kensington, London.
- Anal Endosonography: an important investigation following traumatic vaginal delivery.
- 10.9.93 The 2nd International Scientific Meeting of The Royal College of Obstetricians and Gynaecologists, Hong Kong.
- Anal sphincter damage occurs in 81% of forceps but only 24% of vacuum deliveries.
- 12.10.93 Senior Registrars' and Registrars' Conference. The Royal College of Obstetricians and Gynaecologists, London.
- A prospective study of anal sphincter disruption during vaginal delivery.
- 27.6.94 The Association of Coloproctology of Great Britain and Ireland. The Royal Society of Medicine, London.
- Uro-colpo-proctology. A new subspeciality?

## LIST OF CONTENTS

Section	Title	Page
	List of Tables	xxii
	List of Figures	xxvii
	Glossary	xxx
<b>1</b>	<b>ULTRASONOGRAPHY</b>	<b>8</b>
1.1	Historical Background	8
1.2	Basic Principles of Ultrasound	10
1.3	Endosonography	20
1.4	Instrumentation	22
<b>2</b>	<b>ANAL CONTINENCE MECHANISMS AND ANORECTAL PHYSIOLOGY TESTS</b>	<b>31</b>
2.1	Anal Continence Mechanisms	32
2.2	Anorectal Physiology and Investigations	48
2.2.1	Historical Perspective	49
2.2.2	Anal Manometry	50
2.2.3	Measurement of Pudendal Nerve Function	59
2.2.4	Perineometry	69

<b>Section</b>	<b>Title</b>	<b>Page</b>
<b>3</b>	<b>STATISTICAL ANALYSIS</b>	<b>75</b>
3.1	Statistical Terminology	75
3.2	Statistical Tests	77
3.3	Contingency Tables	79
3.4	Correlation and Linear Regression	81
3.5	Validity of Data Collection	82
<b>4</b>	<b>THE ANATOMY OF THE ANORECTAL MUSCLES</b>	<b>84</b>
4.1	Literature Review	86
4.2	<b><u>Study I:</u></b> Macroscopic and Microscopic Anatomy	97
4.3	<b><u>Study II:</u></b> Verification of Sonographic Images of the Anal Sphincter	117
4.4	<b><u>Study III:</u></b> Endosonography of the Anal Sphincters: Normal Anatomy and Comparison with Manometry	137
4.5	<b><u>Study IV:</u></b> The Effect of Pregnancy on Anal Sphincter Morphology and Function	158

<b>Section</b>	<b>Title</b>	<b>Page</b>
<b>5</b>	<b>THE VALIDATION OF SONOGRAPHIC SPHINCTER DEFECTS</b>	<b>166</b>
5.1	Introduction	166
5.2	<u>Study V:</u> The Accuracy of Anal Endosonography in the Diagnosis of External Sphincter Defects Identified by Ultrasound.	167
5.3	<u>Study VI:</u> Validation of Internal Sphincter Defects Detected by Anal Endosonography	179
<b>6</b>	<b>VAGINAL ENDOSONOGRAPHY AND THE ANAL SPHINCTERS</b>	<b>186</b>
6.1	Introduction	186
6.2	<u>Study VII:</u> A New Approach to Image the Undisturbed Anal Sphincter.	187

<b>Section</b>	<b>Title</b>	<b>Page</b>
<b>7</b>	<b>OBSTETRIC TRAUMA TO THE INNERVATION AND MUSCLES OF THE ANAL SPHINCTER.</b>	<b>195</b>
7.1	Literature Review	197
7.2	<b><u>Study VIII:</u></b> A Prospective Study of Anal Sphincter Disruption and Pudendal Nerve Damage During Childbirth.	203
7.3	<b><u>Study IX:</u></b> Third Degree Obstetric Anal Sphincter Tears: Risk Factors and Outcome of Primary Repair.	239
7.4	<b><u>Study X:</u></b> Anal Sphincter Trauma During Instrumental Delivery. A Comparison Between Forceps and Vacuum Extraction.	259
7.5	<b><u>Study XI:</u></b> Perineal Trauma at Delivery: An Audit of Training of Doctors and Midwives.	273

<b>Section</b>	<b>Title</b>	<b>Page</b>
<b>8</b>	<b>OVERVIEW AND CONCLUSIONS</b>	<b>283</b>
8.1	Anal Endosonography	283
8.2	Anal Sphincter Trauma at Childbirth	285
8.3	Recommendations	289
8.4	Conclusions	293
<b>9</b>	<b>BIBLIOGRAPHY</b>	<b>294</b>
<b>10</b>	<b>APPENDIX</b>	<b>318</b>
A	Protocol: The Effect of Childbirth on the Anal Sphincters	318
B	Anonymous Obstetric Questionnaire	320

## LIST OF FIGURES

Fig. No.	Title	Page
1.1	The Bruel and Kjaer (Type 1846) ultra-sound scanner	24
1.2	The Bruel & Kjaer (Type 1850) 7 MHz rotating endoprobe	24
1.3	A close-up view of the probe tip	25
1.4	The unassembled probe	28
1.5	The assembled rectal probe used for vaginal scanning	58
2.1	The Stryker 295-1 intracompartmental pressure monitor.	65
2.2	The disposable St. Mark's Pudendal Electrode	65
2.3	The Medelec MS 92A EMG Electrostimulator	65
2.4	Technique of measurement of PNTML	67
2.5	A typical recording of pudendal nerve motor latency	67
2.6	The St. Mark's Perineometer	71
4.1a	Schematic representation of the muscles of the anorectum.	100
4.1b&c	Longitudinal section through the anterior and right lateral aspect of the anal canal	102

4.1d&e	Longitudinal section through the posterior and left lateral aspect of the anal canal	103
4.1f	Longitudinal section of the lower anal canal	104
4.1g	Longitudinal section through the upper anal canal of a 22 week male foetus	107
4.1h	Longitudinal section through the upper anal canal of a 26 week female foetus	108
4.1i	Transverse section through the mid-anal canal of a 4 month male infant.	109
4.1j	Transverse section through the mid-anal canal of a 4 month male infant at a higher magnification.	110
4.1k	Longitudinal section through the mid anal canal of 26 week female foetus	112
4.1L	Longitudinal section of the lower anal canal of a 46 year old male	114
4.2a	In vitro underwater scanning of opened anorectal specimen.	119
4.2b	In vivo scanning performed intra-operatively	121
4.3a&b	Histological and sonographic cross section through the mid anal canal	125

4.4a&b	In vitro sonographic image of the opened anal canal	127
4.4c	In vitro sonographic image of the opened anal canal in a female	128
4.4d&e	In vitro sonographic image of the opened anal canal in a male	129
4.5a&b	In vivo (intra-operative) sonographic images	131
4.5c&d	In vivo (intra-operative) sonographic images	132
4.5e	Intra-operative scanning of a female patient	133
4.6a-e	Sites of measurement of anal sphincter muscle thicknesses.	144
4.6f	Anatomical and sonographic gender variations	146
4.6g&h	Images of the deep external sphincter in a female.	147
4.6i&j	Images of the deep and superficial external sphincter in a male	148
4.6k&L	The subcutaneous external anal sphincter	149
4.6m&n	Images of external sphincter variant and perineal muscles	150
5.1	Histological appearance of an external sphincter defect	171
5.2a&b	Histological appearance and corresponding sonographic image of an external sphincter defect	172

5.3	An image of an amorphous external sphincter defect	176
5.4	Appearance of a successful secondary sphincter repair	176
5.5a	Pre-operative scan of the normal mid anal canal in a female	182
5.5b&c	Images after lateral internal anal sphincterotomy in a female	183
5.5d&e	Images after lateral internal anal sphincterotomy in a male	184
6.1 & 6.2	Vaginal endosonographic images of the rectum and deep external sphincter	189
6.3	Vaginal endosonographic image of the deep external sphincter	190
6.4a&b	Anal and vaginal endosonographic images of the same external sphincter defect	192
7.1a&b	Anal endosonographic image before and after vaginal delivery demonstrating an external sphincter defect	209
7.2a&b	Anal endosonographic image before and after vaginal delivery demonstrating an internal sphincter defect	210
7.3a-d	PNTML measurements following childbirth	227
7.4a&b	Primary sphincter repair	248

7.5	Anal endosonographic image after forceps delivery	265
7.6	Schematic representation of the perineal muscles	279

## LIST OF TABLES

Table No.	Title	Page
I	Approximate velocities of sound in human media	12
II	Descriptions of the external anal sphincter	91
III	Sonographic echogenicity of the different layers of the anal sphincter complex.	122
IV	Differences in the endosonographic morphology of the external anal sphincter between males and females	140
V	Differences in sonographic identification of structures other than the sphincter muscles in males and females	141
VI	Mean lateral anal muscle thicknesses in males and females	141
VII	Anal sphincter muscle thicknesses and manometry before and after caesarean section	162
VIII	Comparison between histologically confirmed anal sphincter defects and different methods of pre-operative assessment	173
IX	Incidence of anal sphincter defects in women as detected by anal endosonography after vaginal delivery	216

X	Association between symptoms of faecal urgency or anal incontinence and the presence of any anal sphincter defect after vaginal delivery	216
XI	Anal manometry, perineometry and pudendal nerve motor function before and six weeks after vaginal delivery	217
XII	Relationship between anal manometry and the presence of sphincter defects six weeks after delivery	218
XIII	Antenatal perineal position and PNTML values from 74 healthy nulliparous women	219
XIV	Differences in PNTML measurements between the right and left sides	219
XV	The relationship between obstetric variables and the development of anal sphincter defects	222
XVI	Anal manometry, perineometry and pudendal nerve motor function before and six weeks after caesarean section	226
XVII	Relationship between obstetric factors and third degree tears	244

XVIII	Anal manometry and PNTML measurements in control women having a vaginal delivery without a third degree tear and women who sustained a third degree tear	250
XIX	Relationship between the method of instrumental delivery and the development of anal sphincter defects, defaecatory symptoms and abnormal perineal descent compared to control subjects	263
XX	Relationship between methods of instrumental delivery and measurements of anal manometry and PNTML	267
XXI	Responses of doctors and midwives regarding the definition of a third or fourth degree tear.	277
XXII	Number of doctors and midwives who considered their training to be of a good standard.	277

**GLOSSARY**

cm H<sub>2</sub>O = centimetres of water

CI = confidence interval

EAS = external anal sphincter

EMG = electromyography

IAS = internal anal sphincter

LM = longitudinal muscle

msec = milliseconds

mm Hg = millimetres of mercury

PNTML = pudendal nerve terminal motor latency

RAIR = Rectoanal inhibitory reflex

SD = standard deviation

## INTRODUCTION

Childbirth can have an important bearing on a woman's continence, both immediately after delivery and later on in life. As faecal incontinence carries a social stigma and causes considerable embarrassment, it is often under-reported. Consequently, the true magnitude of the problem is underestimated by clinicians.

Compartmentalisation of disorders of the pelvic floor and related structures into different specialities has led to a fragmented approach to these disorders. In general, primary sphincter repair following an anal sphincter tear during childbirth is performed by an obstetrician. However, women who present to general practitioners with symptoms of faecal incontinence tend to present late and are usually referred directly to a general or colorectal surgeon who may then perform a secondary sphincter repair. As presentation may be delayed many years after injury sustained at childbirth, many obstetricians are not made aware of the true incidence of anal incontinence following childbirth. Furthermore, as obstetric perineal tears and episiotomies appear to heal readily after repair, a minor degree of anal sphincter disruption in a young, healthy woman may not produce symptoms. However the process of ageing, the progression of pelvic denervation and the effects of the menopause may precipitate or aggravate symptoms of anal incontinence.

Obstetric trauma, neurologic or mechanical, remains a major cause of faecal incontinence in women. Until recently, the development of faecal incontinence has been attributed largely to pelvic nerve damage with subsequent denervation and

atrophy of striated muscles of the pelvic floor and anal sphincter. However the advent of anal endosonography has added a new dimension to understanding the pathophysiology of faecal incontinence. Many patients who had a previous diagnosis of pure "neurogenic" faecal incontinence have been shown to have unsuspected external anal sphincter muscle defects using anal endosonography. Furthermore, patients thought to have only an external sphincter defect demonstrated by electromyography (EMG) have been found to have associated sonographic evidence of internal sphincter damage. Although there are a few prospective studies of neurophysiologic trauma during childbirth, no study has addressed the relevance of both mechanical and neurologic trauma prospectively.

## **HYPOTHESES**

1. Endosonographic imaging of the anal sphincter is a reliable means of detecting mechanical damage.
2. Unrecognized mechanical trauma to the anal sphincter occurs at the time of vaginal delivery.
3. When recognized trauma occurs and is repaired, the outcome is often unsatisfactory.
4. Instrumental delivery is a major contributing factor to the development of such trauma.

5. The training of doctors and midwives in identification of the full extent of perineal trauma and subsequent repair may be inadequate.

### **AIMS OF STUDY**

1. To establish the incidence and significance of occult anal sphincter defects following childbirth using anal endosonography.

2. To relate this damage to defaecatory symptoms and any concomitant pelvic floor nerve damage.

3. To correlate such damage with obstetric variables associated with vaginal delivery.

4. To determine risk factors associated with third degree tears and to evaluate the outcome of primary sphincter repair.

5. To audit the opinions of trainee doctors and midwives regarding training in the management of obstetric perineal trauma.

### **OBJECTIVE**

Identification of specific risk factors which may enable changes to current obstetric practice, with a view to reducing anorectal morbidity.

## THESIS STRATEGY

In the first two sections I have provided a background and basic principles in ultrasonography and anorectal physiology. The investigations performed in this thesis have been described in detail. In Section 3 the statistical analyses performed in this thesis are described.

In Section 4, a literature review of the pelvic floor and anorectal musculature has been presented in which inconsistencies in the description of anal sphincter anatomy is noted. In the first study (Section 4.2) an attempt is made to understand and define the anatomy of the anal sphincter by dissection and microscopic examination. However as in vivo anatomy cannot always be reproduced by in vitro dissection, dynamic imaging techniques need to be exploited. Anal endosonography is one such technique that has only recently been pioneered at St. Mark's Hospital, London; however it has not yet been validated. In Section 4.2 anal endosonographic images have been clarified and validated by simultaneous in vivo and in vitro underwater scanning. In Section 4.3 the in vivo anal sphincter anatomy in both males and females is demonstrated by anal endosonography. A clear understanding of normal sphincter anatomy, normal variants and gender differences should enable precise diagnosis of abnormalities.

Anal sphincter muscle damage is implicated in the pathogenesis of faecal incontinence and anal endosonography has been used recently to detect anal sphincter muscle defects. However the sonographic appearance of defects had not been prospectively

validated. In Section 5.2 and 5.3 external and internal sphincter defects are verified prospectively and their sonographic appearance re-defined.

Although anal endosonography provides clear imaging of the anal sphincter, insertion of a probe may distort its anatomy. In Section 6, a new approach to image the undisturbed anal canal is described - vaginal endosonography. In Section 6.2 this novel approach has been compared to anal endosonography and its potential uses discussed.

In Section 7.2 the incidence and significance of unrecognised obstetric trauma to the anal sphincters and its innervation is studied prospectively. A surprising finding in this study was that two women who had primary repair of a third degree obstetric tear were still incontinent at their postnatal visit; both these women were found to have persistent anal sphincter sonographic defects. This prompted me to study the outcome of primary sphincter repair and to identify obstetric risk factors associated with third degree tears (Section 7.3). Furthermore, since both these studies (Sections 7.2 & 7.3) indicated that forceps delivery is a major contributing factor in anal sphincter damage I performed another study (Section 7.4) to compare the effects of forceps with the vacuum extractor.

Episiotomy and perineal repair form the most common operation in obstetrics. Although instrumental delivery particularly the use of the forceps is associated with anal sphincter damage, instrumental delivery accounts for less than ten percent of all deliveries. Therefore the causes of the unexpected frequent occurrence of anal sphincter trauma during vaginal delivery need further consideration. Are doctors and

midwives adequately familiarised with perineal anatomy before performing unsupervised perineal repair? Are we sufficiently trained to repair the perineum? Are we trained to recognise third and fourth degree tears and perform a primary sphincter repair? Could it be that trauma to the anal sphincter is recognised but not documented as a third degree tear? These issues have been addressed in an interview and completion of questionnaire involving 150 doctors and midwives described in Section 7.5).

In view of the findings described in this thesis a vital question needs to be addressed: can the incidence of obstetric trauma to the anal sphincter and its associated morbidity be prevented or at least minimised? Recommendations are made in Section 8.

## **ETHICAL COMMITTEE APPROVAL**

The studies in this thesis were approved by the Ethics Committee of the City and Hackney Health Authority. Informed written consent was obtained from each subject. Women who participated in the obstetric studies described in Section 7 volunteered after reading information leaflets distributed at the antenatal clinic. General Practitioners were also informed of the intended studies.

## SECTION 1: ULTRASONOGRAPHY

### 1.1 HISTORICAL BACKGROUND

Ultrasound has been used for navigation by animals such as bats for thousands of years. However, the production of ultrasound in the laboratory was only achieved in the last century. In 1847, Joule described magnetostriction (Wells 1978), a phenomenon by which ferromagnetic material within a magnetic field changes in dimension. This was followed by the discovery of the piezoelectric effect (the generation of an electric charge resulting from a perpendicular force applied to a quartz crystal) by the Curie brothers in 1880 (Wells 1978). Either or both phenomena are essential in the production of medical ultrasound transducers.

The Titanic disaster in 1912, and the threat to the Allied Powers by submarines during the First World War, stimulated the development of acoustic devices to detect submerged objects. In 1917, Paul Langevin, a former student of Pierre Curie succeeded in applying the pulse-echo method for detection of submarines, which formed the foundation of the invention of sonar (sound navigation and ranging), (Wells 1978).

Generation and detection of ultrasound at higher frequencies enabled the application of the pulse-echo system to detect flaws in metallic structures (Firestone 1946, Desch 1946).

Jaffe et al then made an important discovery in 1955: the piezoelectric properties of polarised solid solutions of lead zirconate titanate (Jaffe et al 1955). This, and other synthetic ferroelectric materials are now widely used in medical electronics.

The first attempt to use ultrasound as a medical diagnostic tool was in 1942 by Dussik (Holm et al 1976), who tried, unsuccessfully, to delineate brain tumours through the intact skull by transmitted ultrasound. Ludwig and Struthers (1949) were the first to publish the use of the pulse-echo technique for medical diagnosis and were able to detect gallstones and foreign bodies in tissue. However, Howry is credited for being the first to construct parts of the first pulse-echo system designed for medical use (Wells 1978). This was independent of the work done by Ludwig and Struthers (1949) and in 1951 he developed the first compound scanning system. After several attempts, he obtained a successful image of a metal object in water (Howry and Bliss 1952). At about the same time, Wild began a series of publications with particular reference to the use of ultrasound in brain and breast tumours (Wild 1990).

The clinical application of ultrasound flourished in many specialities including cardiology, obstetrics and ophthalmology. Ian Donald, an obstetrician from Glasgow, was a pioneer of abdominal ultrasound. He used direct contact scanning which was clinically less cumbersome than the waterbath immersion technique developed by Howry and Bliss (1952). In 1957, Donald with his colleague John MacVicar and Tom Brown, an engineer, developed the first two dimensional contact scanner (Donald et al 1958). A similar machine was built in the United States of America by Holmes et al (1965). However, it appears that Wells (1966) was the first to construct a scanner

with two articulated arms; such an arrangement has been in use for many years.

The next challenge in clinical ultrasonography was the sonographic differentiation of tissue structures. Donald and Abdullah (1968) demonstrated during obstetric scanning that the placenta "fills in" with echoes as the system sensitivity was increased, whereas the amniotic fluid remained almost anechoic. Using a similar technique, Kobayashi (1975) reported on the accuracy of ultrasound in the differential diagnosis of breast tumours. Recently, the grey-scale display re-introduced by Kossoff and Garrett (1972), has become popular and has increased the scope of qualitative tissue identification (vide infra).

## **1.2 BASIC PRINCIPLES OF ULTRASOUND**

Sound is the mechanical vibration of matter. The human ear can hear frequencies up to 20 000 cycles per second (Hz). Ultrasound is a form of energy which consists of mechanical vibrations above 20 000 Hz, usually in the range of 2.5 to 15 MHz. (Sutton 1980).

### **1.2.1 Generation of ultrasound**

Ultrasound is produced and detected by piezoelectric transducers which are substances that have the property of being able to convert one form of energy to another. When connected to ultrasound equipment, the transducer converts electric signals to acoustic pulses on transmission, and vice versa on reception.

Transducers are made of materials which can deform mechanically when an electric voltage is applied to them. Conversely, when deformed by mechanical pressure, they have the ability of producing a voltage. These phenomena are known as the "piezo-electric" effect and was first discovered in certain natural crystals such as quartz by Curie and Curie in 1880 (Wells 1978). Presently, the active element used in virtually all ultrasonic transducers is a synthetic ceramic material, eg. Barium titanate, lead metaniobate or lead zirconate titanate (commonly known as PZT). Ceramic elements have superior piezo-electric properties and a major advantage is that they do not have to be flat and may be ground to a curve prior to being polarized (Kossoff 1978).

The application of a voltage gradient to the transducer causes the elements within it to move in and out of synchronism. This movement sets the adjacent surface particles of the medium into motion and propagates an ultrasonic wave. A transducer will generate an ultrasonic wave at any frequency that corresponds to that of the applied voltage. However, a maximum output is obtained at resonance. The resonant thickness of most piezo-electric materials is such that an element that is 1 mm thick resonates at approximately 2 MHz.

### **1.2.2 Transmission of ultrasound**

Although ultrasound is transmitted through a medium by means of particle vibration, there is no net movement of the medium. Each activated particle vibrates around its position of rest and transmits the vibration through the whole medium. The frequency at which ultrasound is generated is inversely related to the wave length of the beam. The higher the frequency, the less the beam penetrates into tissue but the resulting

image will be sharp in outline. The converse also holds true.

The velocity 'c' of longitudinal sound waves in a bar shaped homogeneous medium is expressed as a function of elasticity and density by the equation:

$$c^2 = E/\rho$$

where E is the proper modulus of elasticity and  $\rho$  is the density of the medium.

The velocity of sound is almost constant in all soft tissues of the body at 1540 m/sec.

However, it is almost three times higher in bone (Table I).

**Table I**

**Approximate velocities of sound in human media  
(after Wells, 1971)**

<b>Material</b>	<b>Impedance Kg/m<sup>2</sup>/s x 10<sup>-6</sup></b>	<b>Velocity m/sec</b>
Air	0.0004	331
Fat	1.38	1450
Water	1.48	1480
Kidney	1.62	1561
Blood	1.61	1570
Muscle	1.70	1585
Bone	7.80	4080

An ultrasound pulse is only reflected when it reaches an interface. An interface is a boundary between 2 different media with different acoustic impedance values.

Acoustic impedance is defined as:

$$Z = \rho c$$

where Z is the acoustic impedance,  $\rho$  is the density of the medium, and c is the sound

velocity of the medium. The sound velocity is defined as:

$$c = \tau v$$

where  $\tau$  is the ultrasound wavelength and  $v$  is the frequency.

When an ultrasound pulse is confronted by an interface, part of the pulse is reflected back to the transducer while the remainder is transmitted through the second medium.

The amount of energy or, more precisely, sound pressure that is reflected will depend on the so called reflectivity coefficient (R) which is defined as:

$$R = \frac{Z_2 - Z_1}{Z_2 + Z_1}$$

### 1.2.2.1 Attenuation

The amplitude of the ultrasound beam is expressed in decibels. As the ultrasound beam propagates through a medium, it loses its intensity. This phenomenon is called attenuation and is the result of interactions with tissue in three ways: absorption, dispersion and reflection.

#### i) Absorption

Vibration of the particles in the medium caused by the ultrasound wave results in internal friction and some of the mechanical energy is converted into heat. The amount of energy absorbed by the medium depends on the characteristics of the material (elasticity and density) and the frequency of sound applied - the higher the frequency, the more the energy absorbed. Consequently, high frequency transducers improve resolution but at the expense of a decrease in the depth of penetration.

#### ii) Dispersion

Dispersion of sound energy may occur either because of divergence of the sound beam or by scattering away from the beam by small discontinuities in the medium.

### iii) Reflection

When an ultrasonic beam strikes an interface (a boundary between two media with different acoustic properties) some of the sound energy will be reflected off. The reflection may be specular or non-specular: specular reflections occur when the interface is wider than the ultrasound beam. The result is that the angle of reflection equals the angle of incidence of the beam to the interface. Therefore, the angle of incidence determines the intensity of the reflection back to the transducer. Non-specular or scattered reflections are seen when the ultrasound beam is wider than the interface. A rough interface or discontinuities in a medium can cause a scattered reflection.

The amount of energy reflected off an interface depends on the acoustic impedances of the two media (Table I). If there is a large difference in acoustic media (eg. tissue-air interface) virtually all the sound energy is reflected. Conversely, if the two media have the same acoustic impedance, there is no reflection, as there is no energy lost at this interface.

#### **1.2.2.2 Time gain control**

Time gain control is the electronic compensation for tissue attenuation. Since attenuation is exponential, time gain control is also exponential so that an echo that comes from twice the distance is given four times the amplification. As a beam penetrates tissue it is attenuated at approximately 1 dB/cm per MHz (Bartram and Burnett 1991). Therefore a 7MHz transducer used in studies pertaining to this thesis would lose 7 dB/cm. Considerable amplification would be necessary to compensate

for this as well as the time delay; the further away the reflection, the longer it takes to return to the transducer. The 'slope' also part of the time gain compensation changes the amplification with regard to depth; as the slope is made more acute, deeper echoes are selectively brightened.

### **1.2.2.3 Resolution**

The resolution of an ultrasound beam can be defined in both the axial and lateral plane. The axial plane is in the plane of the ultrasound beam and axial resolution depends on the pulse length of the beam; the shorter the pulse, the higher the resolution. The lateral resolution is largely dependent on beam width, and therefore varies at different distances from the transducer and with the frequency; if the beam is too wide (insufficient lateral resolution) an artifact can be created and therefore the ability to focus a beam and reduce its lateral dimensions is important. The focal length of a transducer indicates the distance of the focal zone from the transducer. Outside this focal zone the resolution can diminish rapidly. High frequency transducers have very short pulse lengths and hence a better resolution, but at the expense of a shorter focal zone and consequently a shorter depth of penetration.

### **1.2.3 Sonographic artifacts**

Interpretation of ultrasound images can be confounded by the presence of artifacts:

a) Reverberation

Reverberations are due to the relatively large impedance mismatch between tissues and the transducer. When an echo returns from these tissues, a proportion may be reflected back into the tissues instead of passing into the transducer. Since it represents bouncing back and forth between two surfaces, the configuration of the reverberation is the summation effect of the configuration of the two interfaces.

b) Refraction

When a sound beam strikes a smooth interface at an angle off the perpendicular, and the velocity of the sound changes at the interface, a deviation of the transmitted beam occurs. Bending of the beam (refraction) occurs because a portion of the wavefront travels at a different velocity in the second medium. In practice, this does not present a major problem because the velocity of sound in soft tissue is relatively constant.

c) Enhancement

Since the attenuation of fluid is so much lower than that of tissue, a beam passing through fluid will emerge at a higher amplitude and therefore echoes from beyond the fluid, eg. a cyst, will appear over-amplified or enhanced. This phenomenon is also referred to as "reverse shadowing". Conversely, when a beam passes through a region of high attenuation, eg. bone or air-filled bowel, the structures beyond appear darker.

## 1.2.4 Ultrasonic techniques and displays

### 1.2.4.1 Pulse Echo Technique

In this technique the transducer emits a short duration acoustic pulse at a repetition rate of 500 to 1000 pulses per second (Sutton 1980). The direction of propagation is determined by the orientation of the transducer and the velocity depends on the properties of the medium. Hence, the time delay between pulse propagation and echo signal detection can be used to determine the transducer to reflector distance. Between each pulse, the transducer rests for a sufficient period to ensure that the returning echo is registered before the next pulse is due to be generated.

### 1.2.4.2. Types of Display

There are four major types of display:

#### i) A-mode or A-scan

The simplest type of ultrasound equipment is the so-called "A-scope". The term 'A' may aptly stand for 'Amplitude scan'. The detection and display of echoes are performed by a horizontally sweeping trace across the oscilloscope screen commencing at the emission of an ultrasound pulse. This, therefore provides a one dimensional static display useful only for the measurement of distance and size. The height of the deflection produced by each echo is proportional to the intensity of the echo signal. The A-mode record is often difficult to interpret, since its appearance changes with small alterations in the transducer angle. It is therefore used only in determinations of the midline structure in the brain and in certain investigations of the eye (Hertz

1978).

ii) B-mode or B-scan

This is also known as the brightness modulation display and representation is two-dimensional. The echoes are displayed as bright dots along the baseline of the oscilloscope instead of vertical deflections used in the A-scan. A two-dimensional image of the inside of an object is obtained by storing and integrating the information gathered from scanning in multiple directions in a selected plane. Hence, echoes from many tissue interfaces are picked up.

The movement of the transducer is accurately sensed by three potentiometers which generate signals according to the position and angle of the transducer. This in turn alters the time-base on the screen of the visual display unit (VDU) so as to correspond to the direction and position of the transducer on the skin of the patient.

iii) M or TM-mode

This display enables a Motion or Time-Motion study of moving structures by ultrasound eg. cardiac and respiratory movements. On the A-scan moving structures may cause "line broadening" as the tissue interfaces are not at a fixed distance from the transducer. The TM-mode of display has found particular use in the field of echocardiography.

iv) Real-time scanning and grey scale imaging

Real time imaging systems have image frame rates which are sufficiently fast to allow

movement to be followed (Wells 1980).

However, the pictures are not in fact real-time or instantaneous; they are delayed by a time interval which varies with the picture frame rate and the depth of the structures. The degree of delay is small, usually about 1/40th second (Sutton 1980) and has no clinical significance.

There are essentially two techniques by which real-time, two-dimensional ultrasound images may be produced (Wells 1980). The first, is similar to conventional "static" two-dimensional scanners except that the transducer elements are mechanically driven at a rate high enough to form images in real-time. In the second technique, a static array of transducers is controlled electronically to sweep the ultrasonic beam in rapid sequence. At an optimum sweep rate, the movement between each sweep becomes imperceptible and a real-time image is obtained.

The size of a deflection in A-mode and B-mode is determined by the magnitude of individual echoes of size greater than a pre-determined threshold. These techniques therefore, while suitable for the delineation of tissue boundaries, provide little information about tissue structure. This limitation has been overcome by "grey-scale" display by which the range of brightness is converted to a fixed series of shades of grey. As a result strong echoes from organ boundaries as well as smaller echoes arising from within the tissue structure can be displayed (Wells 1980).

### 1.3 ENDOSONOGRAPHY

Imaging of deep structures by conventional transcutaneous ultrasonography is limited by the distance and intervening tissues between the transducer and target organ. Endosonography ie. the use of an ultrasound transducer inside a body cavity, enables the transducer to be placed at close proximity to the target organ. The advantage of this is that high frequency transducers which provide better tissue resolution could be used without tissue distortion caused by overlying structures. Although the improved resolution of high frequency transducers is at the expense of a reduction in the depth of field, this is usually of no consequence in endosonography as the transducer is close to the structures to be imaged.

The development of endosonography is attributed to the pioneering work of Wild and Reid which began in 1949 (Wild 1950, Wild and Reid 1955). Using a piece of World War II ultrasound radar training equipment at a frequency of 15 Mhz, images of dog bowel and fresh beef muscle and fat were obtained. An important finding during ultrasonic examination of a cube of beef steak was that no echoes were recorded when the sound beam was parallel to the muscle fibres (Wild and Reid 1955). However when the beam was perpendicular to the muscle fibres a pronounced echo pattern was observed. This phenomenon was termed anisotropy and is due to the increased number of interfaces which the ultrasound beam traverses.

The demonstration of tissue interfaces led to examination of human pathological specimens, particularly of the breast and this was followed by the development of

endosonographic instrumentation in 1951 (Wild 1990). The first radial time-base image taken at 30cm within the colon illustrating the histological layers of the bowel wall was produced in 1955 (Wild and Reid 1957). Further research by these workers led to the development of a flexible instrument in 1956 (Wild 1990) to image the colon and rectum and this enabled imaging of large bowel neoplasia. However, clinical imaging on a large scale for diagnostic and therapeutic purposes only became possible much later. Sonographic images of the prostate gland were first obtained using a chair-type scanner which permitted the prostate to be imaged in transaxial views at 5 mm intervals (Watanabe et al. 1971). In 1979, the application of grey scale imaging to transrectal ultrasonography improved the visualisation of intraprostatic structures (Harada et al 1980). This was followed by improvements in rectal wall scanning particularly in the imaging of rectal carcinoma (Dragsted and Gammelgaard 1983).

The rectal endoprobe used in this thesis (Bruel and Kjaer, Type 1850) was first described by Frenzel-Beyme et al (1982) for imaging the prostate gland. Using the same probe, Beynon et al. (1986a) clarified the interpretation of endosonic appearances of normal colon and rectum and demonstrated the accuracy of this technique in the staging of rectal carcinoma (Beynon 1986b).

Anal endosonography is a relatively recent development (Law and Bartram 1989) arising from a modification of the rectal probe and is described below.

## 1.4 INSTRUMENTATION

The ultrasound investigations reported in this thesis were carried out using the Bruel and Kjaer (Naerum, Denmark) ultrasound scanner (Type 1846) shown in Fig 1.1 and the 7 Mhz probe (Type 1850) shown in Figs 1.2 & 1.3.

### 1.4.1.1 Pre-processing of the image

Prior to commencement of scanning, a prompt on the screen enables input of patient data and transducer frequency. Selection of a transducer frequency results in the automatic selection of a suitable time-gain compensation curve. This determines the brightness of each image point as a function of the echo magnitude received from tissue and the depth of the various tissue boundaries. However manual adjustment of this function is also possible using the controls on the panel.

### 1.4.1.2 Post-processing of the image

Three methods of modifying the visual presentation of a "still" image are available: light image on a dark background (positive), dark image on a light background (negative) and a grey range (grey zoom). The first option (positive) was selected for images throughout this thesis.

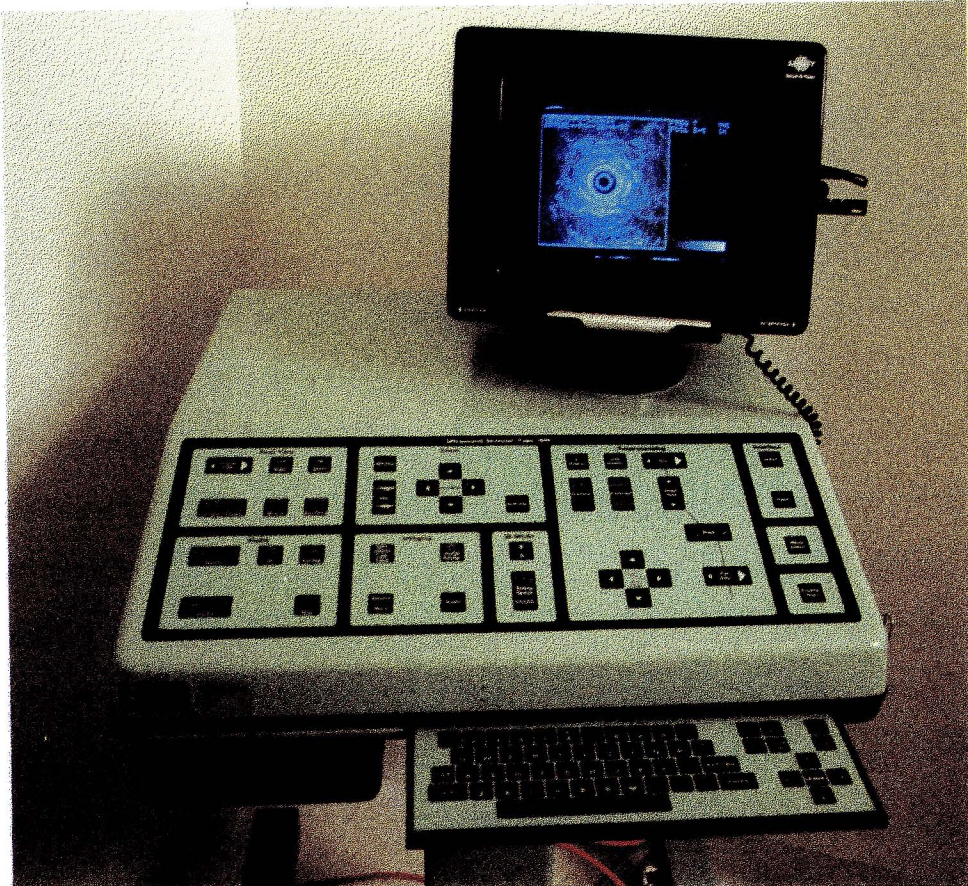
### 1.4.1.3 Screen Display

The 30 cm monitor (Fig 1.1) is powered directly from the scanner and has a 625 line display. Four display scales are available ranging from 5x5 to 20x20 cm. (Size 1 to 4). My personal preference was to start imaging in size 2 (10x10 cm) which provided an


overall view of structures between the coccyx and urethra. I then repeated scanning in size 1 (5x5 cm) and this was adequate to image the finer details particularly sphincter defects.

#### **1.4.2 The Endoprobe**


The Type 1850 Bruel and Kjaer rotating endoprobe (Figs 1.2, 1.3) produces a radial 360° image. It is 2 feet (59 cm) in length and connected to the scanner by a 2.5m long cable. The unassembled probe (Fig 1.4) consists of a motor housing (the handle of the probe) which is a sealed unit and contains a drive motor, gearbox, clutch, position encoder and noise suppressors. Attached to the electric motor at one end is a rod which can rotate at 1.9 -2.8 cycles per second. At the distal end of the rod is a push-fit connector to which the transducer can be attached. The rotating rod can be activated by the start/stop button at the base of the motor housing or by a separate switch on the scanner consol. As a built-in safety device, the power to the drive motor is automatically cut off if rotation is obstructed.



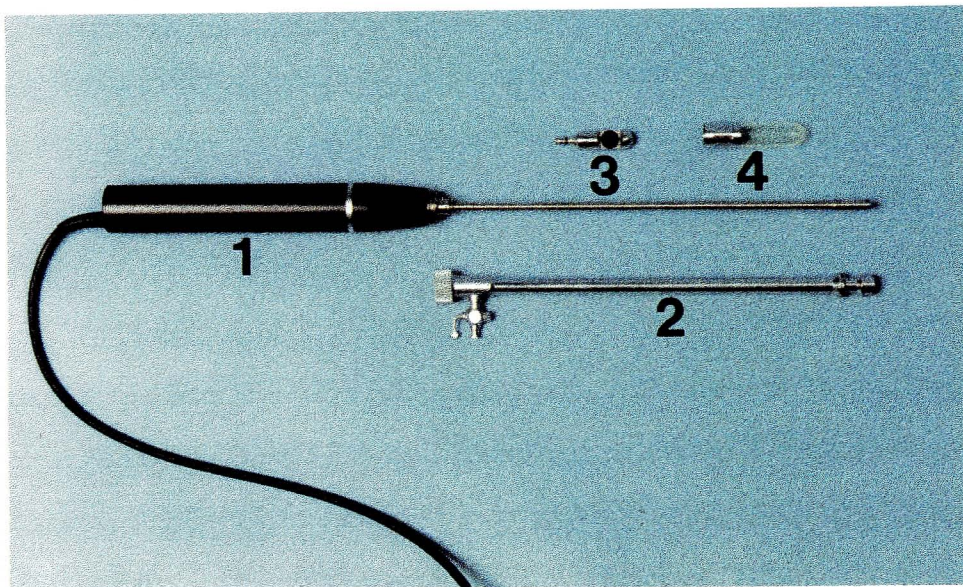
**Figure 1.1** The Bruel and Kjaer (Type 1846) ultrasound scanner



**Figure 1.2** The Bruel & Kjaer (Type 1850) 7 MHz rotating endoprobe



**Figure 1.3** A close-up view of the probe tip shown in Fig 1.2



**Figure 1.4** The unassembled probe shown in Fig 1.3

1. The handle housing the motor attached to the rotating rod.
2. The rectal tube (UA 0649) which fits over the rod. Water is injected with a syringe via the nozzle at the base of this tube.
3. The 7 MHz transducer (Type 8539) which fits at the tip of the rotating rod.
4. The TPX plastic cone (WA 0453) which fits over the transducer.

#### 1.4.2.1 Additional components and assembly:

##### i) Rectal Tube (UA 0649)

This consists of a metal tube with a tap at its base (Fig 1.4). The tube is slid over the rod and screwed fast onto the probe (Fig 1.2).

##### ii) Transducer (Type 8539)

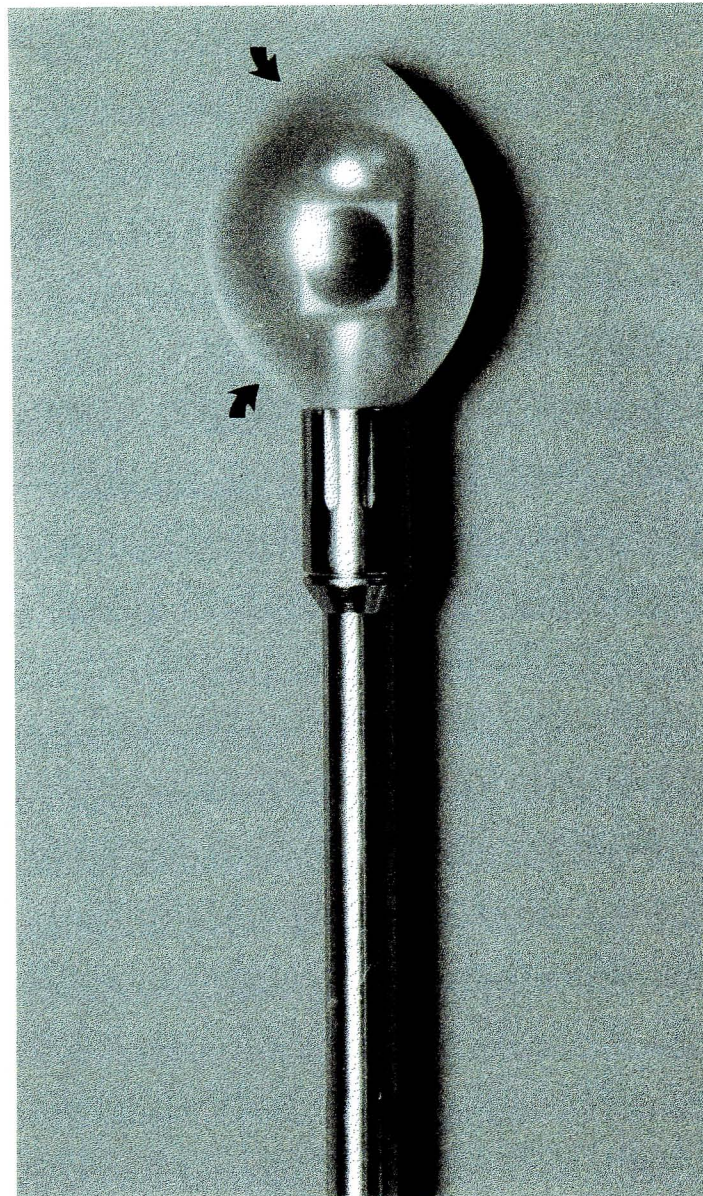
For the purposes of anorectal scanning a 4 MHz (Type 8531) and a 7 MHz (Type 8539) transducer are currently available. A 5 MHz transducer (Type 8523) originally designed for urethral scanning can also be used. Initially all three transducers were tried out independently during anal endosonography. The 4 MHz transducer has a focal range of 30 to 70 mm and the images produced were poorly defined. Although the 5 MHz transducer has a shorter focal range (10 to 40 mm) compared to the 7 MHz (10 to 45 mm), the 7 MHz transducer (Fig 1.3,1.4) provided a higher resolution and has been used throughout this thesis. The minimum ultrasonic beam width of the 7 MHz transducer is 1.1 mm and the beam is perpendicular to the transducer. The transducer is attached to the distal end of the rod.

##### iii) Latex balloon (Type UA 0799)

During rectal scanning a latex balloon is used to cover the transducer (Fig 1.5) and then secured to the distal end of the rectal tube by two retaining rings. After the probe is inserted into the rectum, the balloon is distended with degassed water via the tap at the base of the rectal tube. This provides acoustic coupling and also cushions the balloon from the rotating transducer. Some workers (Tjandra et al. 1992) have

used this system with the water-filled balloon for anal scanning. However, initial experiences revealed that as the probe is withdrawn from the rectum into the anal canal the water between the balloon and the rotating transducer is squeezed out. This posed three potential problems:

- i) The irregular surface of the rotating transducer can cause discomfort and possible injury to the patient.
- ii) The irregular shape of the transducer and may also result in anatomical distortion of the image.
- iii) Since the balloon is in direct contact with the rotating transducer, it is more likely to tear and obstruct rotation.



**Figure 1.5** The assembled rectal probe used for vaginal scanning (See Section 6)

For rectal or vaginal scanning, a balloon (arrows) is used instead of a cone (Figs 1.3&4). The balloon is distended with approximately 30 mls of water via the nozzle and tap at the base of the rectal tube (Fig 1.4).

(v) Cone (Type WA 0453)

Therefore, for the purposes of anal endosonography, the latex balloon was replaced with a plastic cone (Figs 1.3, 1.4). The hard, sonolucent cone is made of TPX plastic and has an outside diameter of 17 mm. The parallel walls of the cone minimise anatomical distortion of the anal canal. The plastic cone is screwed on to a metal collar which in turn can be screwed on to the distal end of the rectal tube. There is a tiny hole (0.5 mm in diameter) at the distal end of the cone.

When the probe is completely assembled, a syringe filled with degassed water is attached to the tap at the base of the rectal tube and with the probe held upright, the cone is slowly filled with water. The hole in the cone allows for the escape of air. It is important to remove all air bubbles as they can cause a reverberation echo artifact. Usually about 7-8 mls of water is sufficient to fill the cone. The tap is then closed and the syringe removed.

### **1.4.3 Technique of anal endosonography**

All patients were scanned in the left lateral position except for those scanned under general anaesthesia who were in the lithotomy position. The left lateral position appeared to be the least embarrassing for the patients.

The probe was rechecked for air bubbles. To avoid contamination a male condom was stretched over the probe tip after applying proprietary ultrasound gel to both sides of the condom. The probe was gently inserted into the anal canal with the tap pointing posteriorly in line with the natal cleft. In this way the images on the screen

corresponded anatomically to the patient in the left lateral position such that anterior was to the right and the right side of the patient was to the top of the picture (see Section 4.4). Abnormalities of the anal sphincter were described in hours like that of a 12 hour clock face with 12 o'clock anterior (ie. to the right of the picture). The probe was inserted until the "U" shaped puborectalis muscle was identified and then the probe was gently withdrawn down the anal canal. Insertion of the probe beyond the puborectalis and hence into the rectum, was readily recognised by a loss in acoustic coupling and the development of artifacts. The whole anal canal was imaged in 2 scales (10 x 10 and 5 x 5 cm). All images were recorded on to Sony U-matic video tapes. Edited hard copies on film or thermal images were made from the video tapes.

#### **1.4.4 Disinfection of the probe**

At the end of each working day, the entire probe assembly was dismantled, washed with soap and water and then immersed in Glutaraldehyde (Cidex) for 30 minutes. Thereafter the parts were removed, rinsed in water, and dried. As a condom was used to cover the probe tip, the probe was disinfected between cases with industrial spirit wipes. The probe was only immersed in Glutaraldehyde between cases if contamination was suspected eg. a broken condom or in high risk groups - HIV or Hepatitis B positive.

## SECTION 2

### ANAL CONTINENCE MECHANISMS AND ANORECTAL

#### PHYSIOLOGY TESTS

##### INTRODUCTION

Anal incontinence and faecal incontinence are terms that have been used synonymously to mean the involuntary loss of rectal contents. The term "faecal" in this context can be confusing because it is unclear whether it includes flatus. However incontinence to flatus, liquid or solid stool is all part of a common spectrum arising from defective mechanisms in bowel control. Therefore for the purposes of this thesis the term faecal incontinence will be used interchangeably with anal incontinence to include loss of flatus.

The estimated community prevalence of faecal incontinence is 4.2 per 1000 in men aged 15-64 years, 10.9 in men aged 65 or over, 1.7 per 1000 in women aged 15-64 and 13.3 per 1000 in women aged 65 or over (Thomas et al. 1984). In residential homes for the elderly the incidence was found to be 10.3% (Tobin and Brocklehurst 1986) but may approach 60% in the elderly (Brocklehurst 1975). In the USA, faecal incontinence is the second most common cause of institutionalisation in the elderly and it accounts for expenses over \$400 million per year for adult diapers (Cheskin and Schuster 1987, Lahr 1988). Although the incidence of faecal incontinence in 45 year old women is 8 times higher than men of the same age (Henry 1987), its prevalence has not been accurately assessed in the younger age groups. Even a minor degree of

faecal incontinence can be very distressing and is a cause of great embarrassment. Therefore very few admit to it (Leigh and Turnberg 1982) and few seek medical assistance (Thomas et al. 1984). Leigh and Turnberg (1982) found that half the patients referred to a gastro-intestinal clinic complaining of diarrhoea were incontinent but less than half of them volunteered this information. Moreover clinicians may also not inquire or document this symptom. Enck et al (1991) found that although 30 percent of patients with gastrointestinal disorders had symptoms of incontinence it was documented in only 5 percent of the patients' medical records. These are some of the reasons why the true prevalence of faecal incontinence can be grossly underestimated.

Anorectal physiology tests primarily study pelvic floor and anal sphincter function. These studies together with radiological imaging are ancillary investigations that enable an objective assessment of sphincter function.

In this section, the major mechanisms that maintain continence are described. The contribution of abnormal function of each mechanism to the development of faecal incontinence is critically analyzed. The methodology of anorectal physiology tests performed in studies pertaining to this thesis are described in detail. In addition, the clinical applications of each test, its reproducibility and its limitations are discussed.

## **2.1 ANAL CONTINENCE MECHANISMS**

The mechanism that maintains continence is complex and affected by various factors

such as mental function, lack of a compliant rectal reservoir, changes in stool consistency and volume, diminished anorectal sensation and enhanced colonic transit. However the ultimate barrier to rectal contents is provided by the puborectalis sling and anal sphincters. An increased volume of liquid stool coupled with rapid colonic transit may overwhelm the compliant rectal reservoir. Therefore if the rectum is able to function effectively as a rectal reservoir and in the presence of normal stool consistency, faecal incontinence can usually be attributed to defective function of the anal canal - sphincter complex. The physiological role of various components of this complex in maintaining continence will be considered individually:

### **2.1.1 The puborectalis muscle and the anorectal angle**

The anorectal angle is formed by the anteriorly directed pull of the puborectalis. The angle varies from 60 - 105° at rest and during defaecation the angle straightens allowing the rectum to empty.

Two theories have been proposed to explain how the anatomical angulation at the anorectal junction may contribute to maintain continence. Phillips and Edwards (1965) suggested that a 'flutter' valve is created as the rectum passes through the slit-like aperture in the pelvic floor caused by the forward pull of the puborectalis; in addition, they suggested that a rise in intra-abdominal pressure would create a high pressure zone and result in apposition of the rectal walls at the anorectal junction. Parks et al (1966) suggested the flap-valve theory; contraction of the puborectalis created an acute anorectal angle and intra-abdominal forces compressed the anterior rectal wall

against the upper anal canal. However both these theories have lost credibility; for a flutter valve to produce such a high pressure zone, intra-abdominal forces would have to be applied below the pelvic floor. Moreover, both theories would account for rectal pressures in excess of anal canal pressures without evacuation of rectal contents. As rectal pressures have been shown to be consistently lower than anal pressures in healthy subjects, Bartolo et al. (1986) concluded that continence was sphincteric and not valvular.

The puborectalis has been considered to be the most important muscle in maintaining continence (Parks 1966, Dickinson 1978). In children with congenital anomalies and absence of the anal sphincter a high degree of continence can be maintained with the puborectalis (Varma and Stephens 1972). However posterior division of the puborectalis in the treatment of chronic constipation made no difference to the anorectal angle and was not associated with incontinence of solid stool (Barnes et al 1985). Although five of the nine patients in this study were incontinent to flatus and liquids, this was related to the excess use of laxatives in four patients. In a further study (Kamm et al 1988) of 18 patients (15 with idiopathic constipation and 3 with megarectum) unilateral or bilateral division of the puborectalis was not associated with incontinence of solid stool and only three were incontinent to mucus.

Furthermore, following successful postanal repair for faecal incontinence no significant change was observed in the anorectal angle (Miller et al 1988a). The role of the anorectal angle in maintaining continence is therefore controversial.

The puborectalis muscle functions in concert with the external anal sphincter and it is probable that if damage occurs to one muscle the other may compensate functionally. Faecal incontinence may ensue if in addition, other factors in the continence mechanism (vide infra) are compromised, or if the remaining muscle cannot compensate adequately.

### 2.1.2 The internal anal sphincter (IAS)

Although the IAS is the distal thickened continuation of the circular smooth muscle of the bowel, it behaves differently. The thickness of the IAS is due to an increased number of muscle cells and not to cell hypertrophy (Penninckx 1992). The isolated IAS generates a constant spontaneous activity of slow rhythmic potentials referred to as slow waves (Wankling et al. 1968, Kerremans 1969). Unlike the slow waves of the bowel, they are never accompanied by spike potentials. Slow wave frequency of between 15 and 25/min is usually highest in the distal part of the anal canal. Superimposed on this, ultraslow waves of between 1.6 and 2.9/min have also been recorded in 70% of normal subjects (Wankling et al. 1968).

No correlation could be demonstrated between electrical activity in the IAS and anal pressures (Wankling et al. 1968). Slow and ultraslow waves are more common in patients with conditions characterised by higher than normal resting pressures such as haemorrhoids and fissure in ano; this is abolished by a reduction in pressure following anal dilatation (Hancock 1977; Gibbons and Read 1986).

The sympathetic and parasympathetic innervation and action is controversial (Speakman and Kamm 1991). The IAS receives its intrinsic innervation via the myenteric and possibly other gut wall plexuses. Extrinsic innervation comprises both a sympathetic supply which is believed to cause contraction and a parasympathetic supply which may be inhibitory. Although some studies have shown the sympathetic response to be excitatory (Frenckner and Ihre 1976, Gutierrez and Shah 1975, Carlstedt et al 1988), others have shown an inhibitory response (Shepherd and Wright 1968, Lubowski et al 1987). However this discrepancy may relate to different stimulation parameters used in these studies (Carlstedt et al. 1988).

The internal anal sphincter is in a state of continuous tonic contraction and contributes to most of the resting pressure in the anal canal. Duthie and Watts (1965) and Schweiger (1979) measured the reduction in resting anal pressure following general anaesthesia with muscle relaxation and concluded that the IAS contributed between 70% to 75% of the resting tone in the anal canal. Similarly, Frenckner and Euler (1975) measured the resting pressure after paralysis of the external sphincter by bilateral pudendal nerve blockade (mepivacain) and attributed 85% of the resting pressure to the IAS. Lestar et al.(1989) assessed the contributions of the different components of the anal canal to basal pressure and found that nerve induced internal sphincter activity contributed 45%, pure myogenic internal sphincter activity 10%, external sphincter 30% and the remaining 15% was attributed to expansion of the haemorrhoidal plexuses.

There are conflicting opinions on the role of the IAS in maintaining continence.

Gaston (1948) and Corman (1984) claimed that the IAS plays an insignificant role. However, other reports emphasised the importance of IAS tone in keeping the anal canal closed at rest for unimpaired continence (Duthie 1971, Ihre 1974, Frenckner and Euler 1975). This view is supported by the finding that symptoms of incontinence can develop following lateral internal anal sphincterotomy: Lewis et al (1988) 6.6%, Walker et al. (1985) 15%, Notaras (1971) 24%, Khubchandani and Reed (1989) 35%, Bennett and Duthie (1964) 40%. Faecal incontinence has also been reported following anal dilatation (Mac Donald et al. 1992) with sonographic evidence of internal sphincter disruption (Speakman et al 1991) and a reduced resting pressure (Snooks et al 1984, Speakman et al 1991).

Swash et al. (1988) identified ultrastructural changes in the morphology of the internal sphincter of patients suffering from neurogenic faecal incontinence. Although these changes are probably not the primary cause of faecal incontinence, they may have some relevance to IAS function. In addition, abnormalities of adrenergic innervation with a diminished sensitivity of the IAS to  $\alpha$  adrenergic agents in vitro have been demonstrated in patients with idiopathic faecal incontinence (Speakman et al. 1990). These changes could be attributed to an intrinsic degeneration of the muscle and its receptors or to simultaneous direct injury to the striated muscle of the pelvic floor.

Sun et al (1990a) found that the transient spontaneous IAS relaxation occurs in 17% of healthy subjects but also in a similar percentage of patients suffering from faecal incontinence. They suggested that this phenomenon may be an important factor in patients with a sensitive rectum especially as a compensatory increase in external

sphincter activity following IAS relaxation did not occur in 77% of the incontinent group compared to 17% of controls.

### **2.1.3 The rectoanal inhibitory reflex (RAIR)**

The RAIR or rectosphincteric reflex is a transient relaxation of the IAS when the rectum is distended with a bolus of air (Gowers 1877, Denny-Brown and Robertson 1935, Gaston 1948). This response has been shown to persist in patients with cauda equina lesions (Denny-Brown and Robertson 1935) and after complete transection of the spinal cord (Gaston 1948, Schuster et al. 1963) indicating that it occurs independent of central control. It appears that the RAIR is mediated by intramural myenteric neurones because topical anaesthesia of the rectal mucosa blocks the reflex (Gaston 1948) and it is absent in patients with Hirschsprung's disease (Callaghan and Nixon 1964).

The RAIR causes equalisation of rectal and upper canal resting pressures and allows rectal contents to enter the anal canal. The contents are then analyzed by the specialised sensory epithelium in the anal canal (Duthie and Bennett 1963). Duthie and Bennett (1963) called this the "sampling" reflex. This reflex is accompanied by a reflex contraction of the external sphincter and puborectalis, the so called "inflation reflex" which temporarily maintains the high pressure zone in the anal canal (Ihre 1974, Whitehead et al. 1982, Bannister et al. 1989) until evacuation occurs or the anal contents are emptied into the rectum. Sun et al (1989) found that in about 25% of patients with idiopathic faecal incontinence the rectoanal reflex was absent. However

both the resting and squeeze pressures were also low in these patients. Moreover the absence of this reflex as occurs in Hirschsprung's disease would be associated with obstructive defaecation rather than faecal incontinence. The absence of the reflex under these circumstances would therefore indicate a weakness of the IAS. Furthermore, Eckardt and Elmer (1991) have recently demonstrated that the RAIR may be difficult to elicit consistently even in healthy subjects.

#### **2.1.4 The external anal sphincter (EAS)**

The EAS is inseparable from the puborectalis posteriorly and both muscles appear to function as a single unit electro-physiologically (Kerremans 1969, Wunderlich and Swash 1983). Bannister et al (1989) have indicated that while contraction of the puborectalis accentuates the anorectal angle, it does not increase the intraluminal pressure of the anal canal.

The EAS, similar to the IAS, is in a state of tonic contraction even at rest and the activity is reflexly raised when intra-abdominal pressure is increased eg. when coughing, laughing, lifting and sitting up (Floyd and Walls 1953, Parks 1962, Kerremans 1969). Activity is maximally raised when the EAS is contracted voluntarily but contraction can only be maintained for 1 to 2 minutes (Parks 1962, Porter 1962, Kerremans 1969, Collier 1987). Stimulation of the perianal skin also results in a reflex EAS contraction via the pudendal nerve called the cutaneo-anal reflex (Melzak and Porter (1964).

Electrical activity usually decreases during straining and when defaecation is attempted, although Kerremans (1969) described a variable response in some subjects. A variable response to evacuation of different rectal contents has also been described (Finlay et al. 1986).

As already noted, the EAS contributes up to 30% of the resting pressure and the increment of the squeeze pressure above the resting pressure reflects predominantly EAS function. The maintenance of tone is, however, also dependent on a sensory input as it is lost if the sensory roots are destroyed eg. tabes dorsalis (Parks et al 1962). Furthermore, if the anal canal is anaesthetised, the maximum squeeze pressure is reduced (Read and Read 1982)

The response to changes in intra-abdominal pressure suggests that the EAS is actively involved in the preservation of continence. Although the first response of the EAS to rectal distension is usually one of contraction (inflation reflex), the tone of the EAS is inhibited if the rectum is distended by a balloon of a volume greater than 140 mls. (Floyd and Walls 1953, Melzak and Porter 1964). The phasic contraction of the EAS is considered to be more important in the maintenance of continence than the resting pressure alone (Schuster 1975). It maintains continence during reflex relaxation of the IAS allowing the sampling of rectal contents by the sensitive anal epithelium. If the time for evacuation is inappropriate, EAS contraction extends the period of continence to allow the compliance mechanisms within the colon to make adjustments in order to accommodate the increased rectal volume. Thereafter the stretch receptors are no longer activated and afferent stimuli are abolished together with the sensation

of faecal urgency (Schuster 1975).

The inherent tone of the external sphincter, its reflex activity and its voluntary response all contribute to continence.

Read et al (1984) studied 19 patients with incontinence to liquid stool and 15 who were incontinent to liquid and solid stool; both groups had a similar degree of neuropathy. They found that the only differences were that the maximum squeeze pressure and the peak pressure during saline infusion was significantly lower in patients who were incontinent to both solids and liquids. As both these pressures are produced by contraction of the EAS, and as the resting pressure was not significantly different between the groups they concluded that incontinence to solids is related to weakness of the EAS. Further support for this hypothesis is that division of the internal sphincter alone can be associated with minor degrees of incontinence to flatus and liquid stool but not usually to solid stool (Khubchandani and Reed 1989, Lewis et al 1988, Walker et al 1985). These properties of the EAS may be diminished either by denervation, mechanical trauma, or a combination of factors. Neurological diseases such as multiple sclerosis, Parkinson's disease and disorders of the spinal cord or cauda equina can be accompanied by incontinence because the central pathways which control sphincter function are located in the vicinity of the corticospinal tracts. Patients suffering with diabetes mellitus can have an autonomic neuropathy and this can also lead to faecal incontinence. Mechanical trauma to the sphincter muscles and nerves controlling continence is discussed separately in Section 7.

### **2.1.5 The anal cushions**

The anal cushions consisting of epithelium, subepithelium and the underlying haemorrhoidal plexuses can contribute up to 15% of resting pressure (Lestar et al. 1989). Gibbons et al (1986) pointed out that the anal sphincters cannot close sufficiently to obliterate the lumen completely and therefore the anal cushions may play a role in maintaining continence by closing this gap. They proposed that the thickened cushions accounted for the increased resting pressures seen in patients with haemorrhoids. A fall in resting pressure following haemorrhoidectomy (Read et al 1982) would support this view and may offer an explanation why haemorrhoidectomy occasionally results in minor incontinence (Bennett et al. 1963, Read et al 1982). However inadvertent damage during this procedure to the sphincter, particularly the internal sphincter, has been observed using anal endosonography (unpublished data).

### **2.1.6 Rectal compliance**

The rectum is more compliant than the colon and responds to increases in volume by an increase in pressure that falls exponentially with time and another exponential constant (Ahran et al 1976). A compliant rectal reservoir that can accommodate large volumes of stool without significant increases in pressure is an important pre-requisite for the effective function of barrier mechanisms of continence. Patients who have a reduction in rectal capacity as occurs in colitis (Buchman et al 1980) and radiation proctitis (Varma et al. 1985) often suffer from faecal urgency and incontinence (Hatcher et al 1984). However, there is evidence that dysfunction of the internal

sphincter is partly responsible for these symptoms (Varma and Smith 1984).

### **2.1.7 Anorectal sensation**

Apart from the anal canal, the rectum like the rest of the gastrointestinal tract is insensitive to painful stimuli. However, although it appears to be sensitive to balloon distension (Goligher and Hughes 1951), it is not clear whether this is due to reflex contraction of the bowel wall or to distortion of adjacent structures. The rectum is more sensitive to distension than the colon but specific sensory receptors have not been identified (Duthie and Gairns 1960). It is possible that stretch receptors in the puborectalis may subserve a sensory function as stretch receptors have been demonstrated in the levator ani (Winkler 1958). Goligher and Hughes (1951) demonstrated that following bilateral sympathectomy rectal sensation of distension was preserved but was abolished following spinal anaesthesia when the parasympathetic supply was blocked suggesting that rectal sensation of distension travels with the parasympathetic system to S2, S3 and S4.

The role of rectal sensation in continence is unclear. Sun et al. (1990a) demonstrated impaired rectal sensation to distension in 10% of patients referred with idiopathic faecal incontinence. None of these patients had evidence of a neuropathy and anal pressures were normal. Five patients leaked fluid during rectal distension but leakage was halted abruptly as soon as sensation was perceived and the external sphincter was contracted voluntarily. Lubowski and Nicholls (1988) also demonstrated an isolated disorder of rectal sensation in 8 patients with faecal incontinence. Buser and Miner

(1986) demonstrated success with retraining techniques in treating incontinent patients who had delayed rectal sensation; however there was also a significant improvement in both resting and squeeze anal pressures.

Although the above findings support a positive role of rectal sensation in maintaining continence, they also illustrate the importance of an intact external sphincter response in preventing incontinence.

Duthie and Gairns (1960) have shown that the epithelium of the anal canal is richly supplied with sensory nerve endings exquisitely sensitive to pain, heat and cold. The upper limit of the sensitive epithelium extends to a mean distance of 3.1 cm from the anal verge (Duthie and Bennett 1963). The afferent nerve pathways for anal canal sensation is via the posterior inferior haemorrhoidal branches of pudendal nerve and anterior haemorrhoidal branches of the perineal nerve to the sacral roots of S2, S3 and S4 but in addition direct anal and urethral branches arise from S4 and S5 (Lawson 1974). Gunterberg et al (1976) demonstrated that sacrifice to the sacral nerves below S2 during radical pelvic surgery resulted in impairment of discrimination of rectal contents and a disturbance of continence and defaecation.

The rectoanal reflex (*vide supra*) allows sampling of the rectal contents to take place in the upper anal canal. This has recently been confirmed using ambulatory manometry (Miller et al 1988b) and occurs as a normal physiological process about 7 times per hour. They also demonstrated a correlation between anorectal pressure changes and the awareness of rectal filling. Sampling has been shown to occur less

frequently in incontinent patients compared to controls (Miller et al. 1988c).

The mechanism of discriminating the nature of rectal contents is not clear. Miller et al. (1987) suggested that recognition of a change in temperature of rectal contents may enable discrimination between flatus, liquid and solid stool. In normal subjects the upper anal canal could detect changes in temperature of  $1.1^{\circ}\text{C}$  and the lower anal canal as little as  $0.6^{\circ}\text{C}$  (Miller et al. 1987). They also demonstrated that the sensitivity to temperature change in the anal canal was significantly reduced in patients with faecal incontinence. However Rogers et al. (1988a) challenged this hypothesis by demonstrating that in normal subjects the temperature gradient between the rectum and the anal canal is four times less than the temperature threshold necessary to appreciate a change in temperature and therefore it would not be possible to discriminate the nature of rectal contents during the sampling reflex by a change in temperature.

Roe et al (1986) were the first to measure anal sensation objectively using mucosal electrosensitivity and demonstrated that patients with neuropathic incontinence have a sensory deficit. Using a similar technique Bielefeldt et al (1990) concluded that sensory function of both the rectum and anal canal is an important and independent factor in the preservation of continence although motor nerve function was not assessed in their study. Rogers et al (1988b) studied 11 patients with primary neurogenic faecal incontinence and demonstrated a combined sensory and motor deficit.

However other investigators have disputed the role of anal sensation in the maintenance of continence. Read and Read (1982) performed saline continence tests on 9 healthy subjects before and after anaesthetizing the anal canal with lignocaine gel. They found no difference in the ability of subjects to retain rectally infused saline. In fact 2 subjects who were unable to retain 1500 ml of saline before were able to do so after the anal canal was anaesthetised. Keighley et al. (1987) used mucosal electro-stimulation to demonstrate that the maintenance of continence and the ability to discriminate the nature of rectal contents is no different whether the anal epithelium is excised or preserved at restorative proctocolectomy. A possible explanation for this is that afferent sensory fibres are also located in the external sphincter and the puborectalis muscle (Scharli and Keisewetter 1970).

### **2.1.8 Central control of continence**

The upper motor neurones for the voluntary sphincter muscles lie close to those of the lower limb musculature in the parasagittal motor cortex. They communicate by a fast conducting oligosymptomatic pathway with the Onuf nucleus situated in the sacral ventral grey matter mainly S2 and S3 (Merton 1982). The frontal cortex is important for the conscious awareness of the need to defaecate and appropriate social behaviour. Disease affecting the upper neurone motor pathway usually results in urgency and urge incontinence and provided the lower motor pathway is still intact reflex defaecation will still be possible (Williams 1991).

The lower motor neurones innervating the striated pelvic floor and urethral and anal

sphincters arise from the Onuf nucleus. The commonest cause of a lower motor neurone lesion in the adult is chronic stretching of the pudendal nerve usually as a result of chronic straining at stool and/or childbirth. Damage to the pudendal nerve results in progressive denervation and reinnervation of the pelvic floor - anal sphincter complex causing weakness and atrophy of these muscles. This process leads to faecal incontinence and is discussed in greater detail below (Section 2.3).

### **2.1.9 Summary: The role of continence mechanisms**

The foregoing discussion into the structures maintaining continence highlight the complexity and multifactorial input of various mechanisms. The anorectal angle appears to have less importance than previously assumed. The puborectalis functions largely in concert with the external sphincter. The internal sphincter plays a major role during anorectal sampling when intact sensation is important. The tonic contraction of both the external and internal sphincter is mainly responsible for maintenance of continence at rest. The external sphincter appears to have a reciprocal function with the internal sphincter during the sampling response and perhaps plays the most important role in the maintenance of continence because it has both a reflex and a voluntary response. However the effectiveness of these mechanisms is strongly modulated by other factors such as intact central nervous system function, rectal compliance and the consistency of stool. It would therefore seem unlikely that damage to one mechanism will lead to a major degree of incontinence. However it is probable that lesser degrees of damage may ultimately exhaust the compensatory potential of the remaining mechanisms and ultimately lead to incontinence. The role of ageing and

hormonal factors in the progressive deterioration of anorectal function also need consideration and are discussed in relevant sections in this thesis.

## 2.2 ANORECTAL PHYSIOLOGY AND INVESTIGATIONS

Anorectal pelvic floor physiology is the study of reflex or learned responses of the pelvic floor and sphincter muscles in relation to colonic and rectal stimuli leading to normal continence and defaecation. These responses are complex and therefore no single study can provide an objective diagnosis. As a result, it is normal practice to perform a battery of tests and this may include radiological investigations such as barium studies of small and large bowel, defaecography and anorectal endosonography. These investigations are complementary to one another and together with the history and clinical examination permit a final diagnosis.

Clinicians refer incontinent patients for anorectal physiology tests in order to determine whether the primary cause is neurological or mechanical. Frequently, it is a combination of the two and a concomitant pudendal neuropathy is associated with a less favourable surgical outcome (Laurberg et al 1988). Anorectal physiology tests enable the degree of impairment to be assessed objectively and this can be used as a baseline for assessing subsequent intervention, whether surgical or medical. A normal finding would alert the clinician to look for the primary cause of incontinence elsewhere.

The investigations to be described assess neurological and mechanical damage to the

pelvic floor and anal sphincters. Prior to description of the techniques, a historical perspective of anorectal physiology is given and also a descriptive background of the pathophysiology to explain the clinical relevance of each investigation.

### **2.2.1 Historical perspective**

Gowers (1877) was the first to document a scientific physiological study of the anal canal in which he described the rectoanal reflex; rectal distension with a bolus of air resulted in a transient relaxation of the internal anal sphincter. Manometric studies relating to the reflex responses of the internal anal sphincter and the regulation of defaecation by the central nervous system was described by Denny-Brown and Robertson (1935). The rectoanal reflex is absent in patients with Hirschsprung's disease (Schuster 1963) indicating a local pathway mediated through the myenteric and submucosal plexuses.

Studies of external anal sphincter function were first reported by Beck (1930) and later by Floyd and Walls (1953) who demonstrated by electromyography that the external sphincter muscles are in a state of tonic contraction even at rest. Taverner and Smiddy (1959) and Porter (1962) also used EMG to demonstrate that the external sphincter contracts reflexly when the intra-abdominal pressure is raised confirming other observations of Floyd and Walls (1953). This is a spinal reflex and persists in paraplegics if cord transection is above the level of S2 (Parks et al 1962).

Duthie (1960) also made major contributions to anorectal physiology and initiated

interest in the role of anorectal sensation in maintenance of continence. He named the sphincteric relaxation that resulted in equalisation of anal and rectal pressures "the sampling response".

Further progress in understanding the morphology and physiology of continence and defaecation was made by Kerremans (1969). Frenckner and Euler (1975) confirmed the work of Duthie and Watts (1965) in demonstrating that the internal sphincter contributes to 85% of the resting pressure of the anal canal.

However it was the late Sir Alan Parks, a surgeon at St. Mark's and The London Hospitals, who could be regarded as the "modern founder" of the anatomy and pathophysiology of the anorectal region bringing "a degree of surgical interest and respectability to this area that could not be envisaged 25 years ago" (Sir Alan Parks Symposium 1983). He and his co-workers have laid the foundation upon which much of the present knowledge and recent advances are based.

### **2.2.2 Anal manometry**

Several devices and techniques have been used to measure anal pressures; each method can influence the pressure being recorded and each has merits and limitations. Different centres continue to use their technique of preference because of familiarity, established normal values, and continuity particularly if long term longitudinal studies are contemplated. Perhaps this also reflects that no single method is ideal but in turn creates difficulties when comparisons are made of studies

conducted at different centres. Although there may be a good correlation between measurements using different techniques, not all methods are interchangeable.

An important consideration during manometric studies is that examination is carried under non-physiological conditions and findings may not totally represent the situation in "real life". Indeed, although refuted by some, two studies have shown that digital estimation was equally as good an assessment of anal sphincter function as manometry (Felt-Bersma et al. 1988, Hallan et al. 1989). However this assessment is dependent on the experience of the examiner and is not scientifically objective.

Ambulatory manometry is still in its infancy and will have much to offer in improving our understanding of anorectal physiology during normal activities (Miller et al 1988d, Roberts and Williams 1992). At present, while manometric assessment of sphincter function may provide some insight into pathophysiology, the aetiology may only become apparent when other complimentary tests are performed.

The different manometric techniques and intra- and inter-individual variations in pressure measurement will be discussed.

Finally, an air-filled microballoon system used for manometric measurements throughout this thesis will be described.

#### **2.2.2.1 Recording Devices:**

Pressure changes in the anal canal are detected by a pressure-sensitive device and

transmitted via an external transducer and amplifier to a pen recorder.

Various pressure-sensitive devices are used:

i) Water perfused catheters:

This type of catheter has a side port through which a continuous perfusion of fluid is maintained. The pressure recorded is an index of resistance to flow of fluid out of the catheter and is affected by the flow rate, the diameter of the catheter and its compliance. Modern catheters are multiluminal, have a narrow diameter and are of low compliance (Read and Sun 1992). It has been suggested that leaking of fluid on to the perianal skin may stimulate a contraction of the external sphincter and be a source of error (Kerremans 1969). The advantage of perfused systems is that multiple ports enable simultaneous radial and longitudinal focal pressure differences.

A sleeved catheter can also be used in conjunction with perfused side holes to measure the maximum pressure in the anal canal (Dent 1976). The pressure recorded will be the net pressure of the whole anal canal over which the sleeve is in contact and cannot be used to determine the exact site of pressure rise.

ii) Microballoons:

Air-filled or fluid-filled balloons provide a more sensitive index of the resistance to distension than perfusion systems (Read and Sun 1992). The size, shape and compliance of the balloon affects pressure readings and therefore microballoons of a fixed diameter (0.5-1 cm) and shape are used. As the pressure recorded represents the circumferential pressure along the length and diameter of the

microballoon, it overcomes radial pressure asymmetry and produces a single global measurement of pressure at that level. Furthermore this system is the least expensive and obviates the need for bulky and expensive low-compliance perfusion equipment. The method used throughout this thesis consists of an air-filled microballoon and is described at the end of this sub-section (2.2.2.4).

iii) Microtransducers:

Microtransducers (Vela and Rosenberg 1982) have the advantage of small size and avoid many of the problems encountered with balloons or perfused catheters (Miller et al. 1988d). However they are expensive and not very robust. Miller et al (1988d) found that microtransducers are not suitable for station pull through manometry (vide infra) unless error due to radial variation is taken into account.

#### **2.2.2.2 Manometric Technique**

The standard method of performing anorectal manometry is with the subject lying in the left lateral position. The catheter is introduced via the anal canal into the rectum (up to the 7 cm mark on the catheter). The station pullthrough technique involves gentle withdrawal of the catheter at intervals of 0.5 cm. until the cranial end of the anal canal is identified. This is recognised by a definite and sustained rise in pressure and the distance from this point to the anal verge is the manometric or functional anal length.

The catheter is then withdrawn at 1 cm stations and the resting pressure measured.

As movement of the catheter can stimulate the sphincter a stabilisation period of 30 seconds is allowed at each station. The highest recorded pressure is termed the maximum resting pressure and is a reflection predominantly of internal sphincter function. The same procedure is then repeated with the subject squeezing the sphincter tightly at each station and this is termed by some as the voluntary contraction pressure or squeeze pressure and the highest reading is termed the maximum voluntary contraction pressure. However as most of the resting pressure is contributed to by the internal sphincter (see above), the maximum voluntary contraction pressure may not be a true reflection of external sphincter function. Therefore throughout this thesis the maximum squeeze pressure (MRP) refers to the maximum increment of voluntary contraction pressure above the resting pressure (Felt-Bersma and Meuwissen 1990).

Profilometry or the continuous pull-through technique (McHugh and Diamant 1987b) involves recordings taken during slow controlled withdrawal of the pressure catheter. This method is unsuitable for microballoon systems because of the artifact produced by movement of the balloon (Felt-Bersma and Meuwissen 1990).

### **2.2.2.3 Normal variability in anal length and pressure**

Multiple perfused side hole and multiple force gauge systems have demonstrated that both longitudinal and radial variations of pressure exist in the anal canal (Collins et al. 1969, Taylor et al. 1984, Coller 1987, Williamson et al. 1990). There seems to be general agreement that proximally the resting and squeeze pressures are lower

anteriorly, approximately equal in all quadrants of the mid anal canal and in the distal anal canal the pressures are lower posteriorly. The resting and squeeze pressures are maximal in the region of the mid anal canal although Coller (1987) found the distal anal canal to be the site of maximum squeeze. Recent studies using pressure vector analysis have been at variance; Sakaniwa et al (1989) found no significant radial pressure differences whereas Perry et al (1990) did. Radial and longitudinal variation in pressures suggest that there is a forwardly directed top loop of muscle and backwardly directed bottom loop. This would support the double loop theory proposed by Oh and Kark (1972) rather than the triple loop theory suggested by Shafik (1975).

The maximum resting and squeeze pressure is lower in women compared to men (Loening-Bauke and Anuras 1985, McHugh and Diamant 1987a, Sun and Read 1989, Pedersen and Christiansen 1989, Enck et al 1989) and tends to decrease with age in both sexes (McHugh and Diamant 1987, Bannister et al 1987, Enck et al 1989).

The anal canal is significantly shorter in women compared to men (Nivatongs et al 1981, Taylor et al 1984, Sun and Read 1989, Felt-Bersma 1991) although two other studies failed to demonstrate this (Pedersen and Christiansen 1989, Eckardt and Elmer 1991); anal length correlates with the maximum resting pressure (Felt-Bersma 1991). The functional anal length is increased during conscious contraction of the sphincter (Sun and Read 1989) and reduced when the rectum is distended (Bannister et al 1989). Although intraindividual variation has been observed (Pedersen and Christiansen 1989), there is a high correlation between observers in measurement of manometric anal length (Eckardt and Elmer 1991, Rogers et al 1989).

Enck et al (1991) have shown that there is spontaneous variation of the resting pressure related to sleep and meals. Pedersen and Christiansen (1989) found that intraindividual variation in anal pressure may be explained by slow wave and ultraslow wave pressure changes and changes of approximately 20% must be considered within the normal physiological range. They concluded that as the variation between measurements in the same individual at different times was of the same magnitude as the intraindividual variation, day to day variation was insignificant. This finding was supported by Eckhardt and Elmer (1991).


Anal sphincter pressures have been shown to be reproducible and do not entail a significant interobserver variation (Eckhardt and Elmer 1991, Rogers et al 1989). Ideally if patients can act as their own controls and measurements are compared on a matched basis following intervention eg. surgery or childbirth, the element of interindividual variation would be minimised. Interobserver variability can be reduced if the same person performs the tests using the same method. These problems are particularly relevant to anal manometry as much confusion exists in the literature regarding normal values (Felt-Bersma et al. 1991). To overcome this problem at the outset, I established normal values with respect to age, sex and parity in a large group of women and compared matched data before and after delivery where appropriate.

#### **2.2.2.4 The Stryker 295-1 Air-Filled Pressure Monitor**

This system, first described by Orrom et al (1990a, 1990b) has been used to measure anal pressures throughout this thesis. Air-filled manometric systems have been used

successfully in investigations of the urinary tract (James 1979) and anal canal (Miller et al 1989). Water-filled systems require calibration and the system has to be "zeroed" at the anal verge; they are prone to artifacts with movement of the connecting tubing and readings can be affected by air bubbles in the system. Air-filled manometry avoids these problems and has been accepted by the working party on anorectal physiology measurement as "the most reliable method for routine manometry" (Keighley et al 1989). The microballoon used also has the advantage of recording a global pressure over 1 cm and minimising error due to radial and longitudinal variation in anal canal pressure (see above). The longer balloon used for this study compared to the shorter balloons used for water-filled manometry probably contributes to the superior reproducibility of measurements using the air-filled system (Murray and Miller 1990).

The hand held manometer (Fig 2.1) is a modification of the Stryker 295-1 intracompartmental pressure monitor (Stryker Corporation, Kalamazoo, Michigan, USA). A microballoon 10 mm long and 5 mm in diameter is connected to the transducer port via a 30 cm long capillary tubing, with an internal diameter of 0.7 mm and external diameter of 2 mm. (Miller et al 1989a). The catheter is non-distensible and the narrow inner diameter and short length minimises dead space in the system. The balloon is slightly deflated when used to prevent any increase in pressure due to warming and expansion of air within the balloon. Using the station pullthrough technique described above, anal pressures were recorded from the quartz readout on the monitor.



**Figure 2.1** The Stryker 295-1 intracompartmental pressure monitor.

This battery operated hand-held monitor is a modified air-filled system attached to a graduated, non-distensible catheter with a microballoon. A digital display of the readings in mm Hg can be seen on the monitor.

This air-filled system has been previously compared to the conventional water-filled system (Orrom et al 1990a, 1990b); the anal length, maximum resting and squeeze pressures showed an excellent correlation although the limits of agreement (two standard deviations of the mean differences between the two systems) revealed that the two systems are not interchangeable. This is of no consequence as the same system is used throughout this thesis. Orrom et al (1990a) also calibrated this system to 200 mmHg using a pressurised glass jar connected to a sphygmomanometer. They found nearly identical readings up to 160 mmHg between the measured and applied pressure. Thereafter the readings were less accurate but this was not a problem as most of the measurements were less than 160 mm Hg. During the course of studies in this thesis I have regularly calibrated the pressure monitor using the same technique and found consistent readings throughout.

### **2.2.3 Measurement of Pudendal Nerve Function**

#### **2.2.3.1 Innervation of the striated muscles of the pelvic floor**

The pelvic floor muscles are innervated by the pudendal nerve as well as direct branches from S3 and S4 motor roots. The pudendal nerve arises from the anterior primary rami of S2,S3,S4 (Last 1984). The pudendal nerve leaves the pelvis through the lower part of the greater sciatic notch, beneath the lower border of the piriformis muscle. It crosses the ischial spine at the point of insertion of the sacrospinous ligament, and then enters the ischio-rectal fossa by passing through the lesser sciatic notch via the pudendal canal. The pudendal canal (Alcocks's canal), is a thickening

of the perianal fascia enclosing the pudendal nerve and vessels and extending between the lesser sciatic foramen and the posterior edge of the perineal membrane. The pudendal nerve then subdivides into the inferior rectal nerve which runs alongside the anal canal innervating the external anal sphincter and the perianal skin. The terminal branches of the pudendal nerve are the perineal nerve which innervates the anterior perineal muscles and sphincter urethrae, and dorsal nerve of the penis (clitoris). Direct branches from S3 and S4 reach the pelvic floor via its visceral surface (Lawson 1974). Percy et al (1981) demonstrated by electrophysiological stimulation that the pudendal nerve innervates the ipsilateral external sphincter but not the puborectalis which is innervated by the sacral branches above the pelvic floor. Overlap in the pudendal innervation between the two sides of the external sphincter has been demonstrated experimentally in the monkey and this is attributed to interdigitation of muscle fascicles across the midline (Wunderlich and Swash 1983).

#### **2.2.3.2 Effects of denervation**

Studies of human striated muscle has identified 2 major muscle fibre types defined by their twitch and fatigue characteristics, and by their histochemical profiles (Dubowitz 1986, Swash and Swartz 1988). Type 1 muscle fibres have relatively slow twitch characteristics, are resistant to fatigue and therefore specialised for continued tonic activity. Type 2 twitch fibres have relatively fast twitch characteristics and are not resistant to fatigue but can be divided into subtypes a, b and c depending on the rate of fatigue. Therefore Type 2 fibres are suitable for phasic tasks such as weightlifting and sprinting. The relative proportion of each fibre type within a given muscle varies

from muscle to muscle. The striated pelvic floor muscles including the EAS and the periurethral muscles contain a marked predominance of Type 1 fibres (Beersiek et al 1979).

In cases of severe denervation of the puborectalis and external sphincter histological examination revealed a few scattered striated muscle fibres with fibrosis and fatty replacement (Beersiek et al 1979). In less abnormal biopsies, muscle fibres of uniform histological type were seen to be grouped together and separated by fibrous bands (Parks et al 1977). Fibre-type grouping is a feature of reinnervation but also occurs in muscles in which less marked destructive changes have occurred. It is likely that with severe muscle denervation and subsequent atrophy extensive muscle destruction makes it difficult to recognise histological features of reinnervation. Another recognised feature was an associated hypertrophy of the remaining muscle fibres especially in the puborectalis (Beersiek et al 1979). Examination of the nerves supplying the sphincter muscles showed a marked reduction in the myelinated nerve fibres with some proliferation of the Schwann cells but the unmyelinated nerve fibres were normal (Parks et al 1977).

### **2.2.3.3 EMG assessment of denervation**

Action potentials from motor units within contracting muscles can be measured using EMG. However denervated muscle cannot contract in response to voluntary activity and although spontaneous activity at rest (fibrillation and fasciculation) may be detected in large denervated muscles it is difficult to recognise in sphincter muscles.

Therefore assessment of denervation is inferred indirectly by detecting evidence of reinnervation. Reinnervation occurs when regrowth of the damaged axons or sprouting of neighbouring unaffected axons infiltrate the affected muscle. As fibre type is determined by specific innervation, sprouting of axons results in a change in the distribution of muscle type and hence small groups of muscle of the same type become clustered. This process is called fibre type grouping and forms the basis upon which the mean fibre density is calculated using single fibre needle EMG. The mean fibre density is defined as the mean number of single fibre action potentials of greater than 100 microvolts recorded within the uptake area of the electrode in 20 different positions within the muscle (Stalberg and Thiele 1975).

Reinnervation following denervation can also be measured by concentric needle EMG. Compared to single fibre EMG, the concentric needle has a larger surface area and hence a larger area of uptake. However similar results have been reported using either technique (Bartolo et al 1983a, Neil and Swash 1980).

In neurogenic faecal incontinence the mean fibre density is increased reflecting reinnervation following denervation (Neill and Swash 1980). Fibre density has also been shown to increase with age (Neill and Swash 1980, Laurberg and Swash 1989).

#### **2.2.3.4 Pudendal nerve terminal motor latencies (PNTML)**

Although EMG tests can identify evidence of reinnervation of the pelvic floor muscles, they do not define the site or cause of the abnormality. This has stimulated interest

in developing techniques to measure pudendal nerve motor conduction.

The motor latency is the time taken from the instant of stimulation of a motor nerve to the first detectable motor response. Henry and Swash (1978) used perianal electrical stimulation and measured the latency between stimulation and contraction of the EAS (cutaneo-anal reflex). Their results suggested that slowed pudendal nerve conduction occurs in idiopathic faecal incontinence. However subsequent work has shown that the cutaneo-anal reflex was an unreliable method of assessing pudendal neuropathy (Bartolo et al 1983). This led to the development of a more direct method of measuring pudendal nerve conduction based on the technique of electro-ejaculation used in patients suffering from impotence (Brindley 1981) following paraplegia. The device was first described by Kiff and Swash (1984a) and consisted of 2 stimulating electrodes situated at the tip of a rubber finger stall and 2 recording surface electrodes mounted 4 cm proximally at the base of the finger. The drawback of this glove was that it required disinfection in glutaraldehyde solution between patients and prolonged drying to prevent shorting of the electrodes. This was overcome by the development of a disposable and less bulky pudendal nerve stimulator (Rogers et al 1988c) known as The St. Mark's Pudendal Electrode (Dantec Elektronik, Skovlunde, Denmark).

#### **2.2.3.4.1 The St. Mark's Pudendal Electrode**

This disposable electrode was used to measure pudendal nerve motor conduction in the relevant studies of this thesis. The self-adhesive backing enabled secure mounting of the electrode onto the gloved index finger (Fig 2.2). It consisted of a bipolar

stimulating electrode (an anode, 5 mm in diameter and a cathode of less than 1 mm in diameter) at its tip and 2 surface recording electrodes at a fixed distance of 3 cm proximally. The smaller diameter of the cathode improved stimulus localisation.

#### **2.2.3.4.2 The Medelec MS92a EMG Electro-stimulator**

This equipment (Medelec MS 92A, Medelec, Surrey, England) shown in Fig 2.3 is a microprocessor-based system, designed to provide a simple method of acquiring and analyzing neurophysiological signals. A separate pre-amplifier minimises induced interference in the electrode connections. The amplifier within the main unit increased the size of the signal to a level at which it could be monitored on the display screen. The following settings were used:

Mode: set to "Acq" (stimuli produced only during acquisition)

Duration of stimulus: 0.1 msec

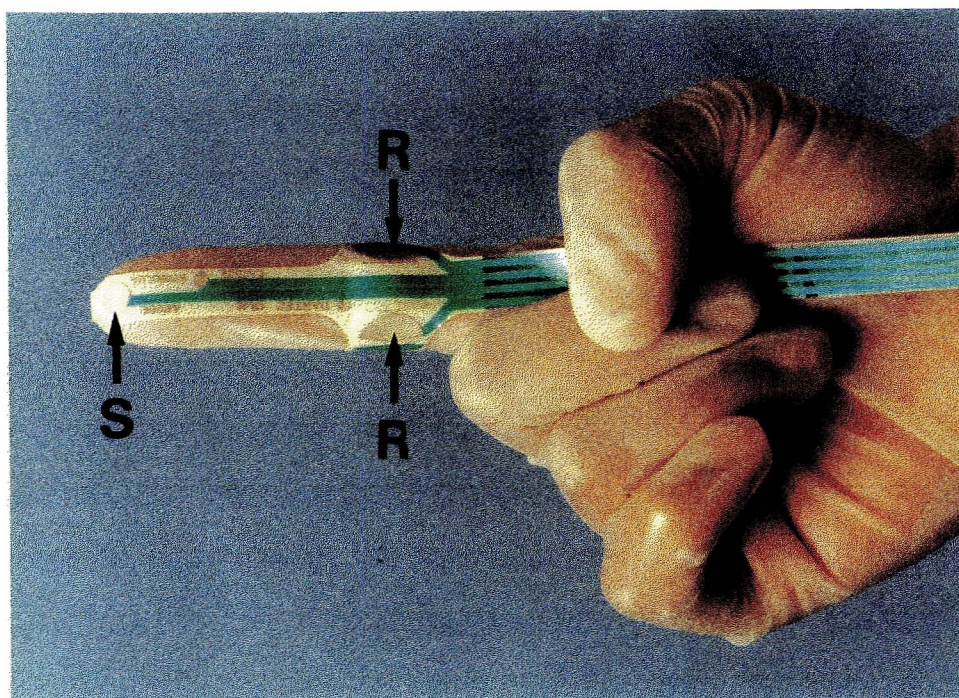
Repetition rate: 1 pps (1 Hz)

Filter: 2 kHz to 20 Hz

Amplitude of signal: 200 V


Maximum intensity: 50 V

At any one time, 2 signals could be stored on screen. Recordings of either trace can be made and this will automatically include information on all the important instrument parameters at the time the signal was acquired.



**Figure 2.2** The disposable St. Mark's Pudendal Electrode mounted on to the gloved index finger.

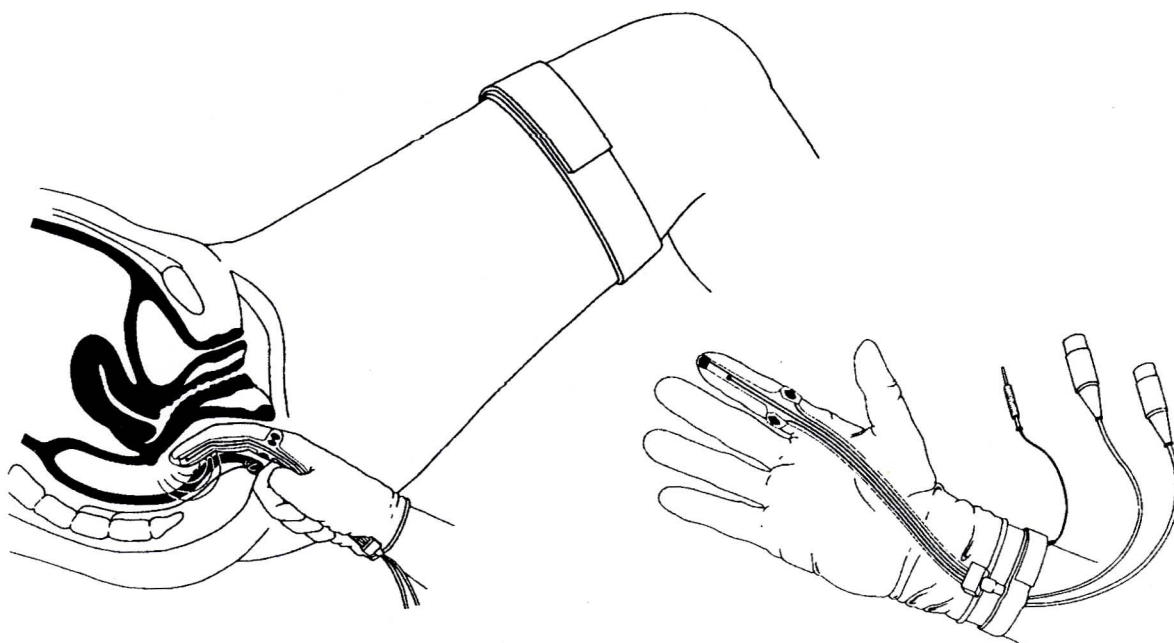
The electrode at the tip of the finger (S) transmits the stimulus to the pudendal nerve while the electrodes at the base (R) records the contraction of the external anal sphincter.



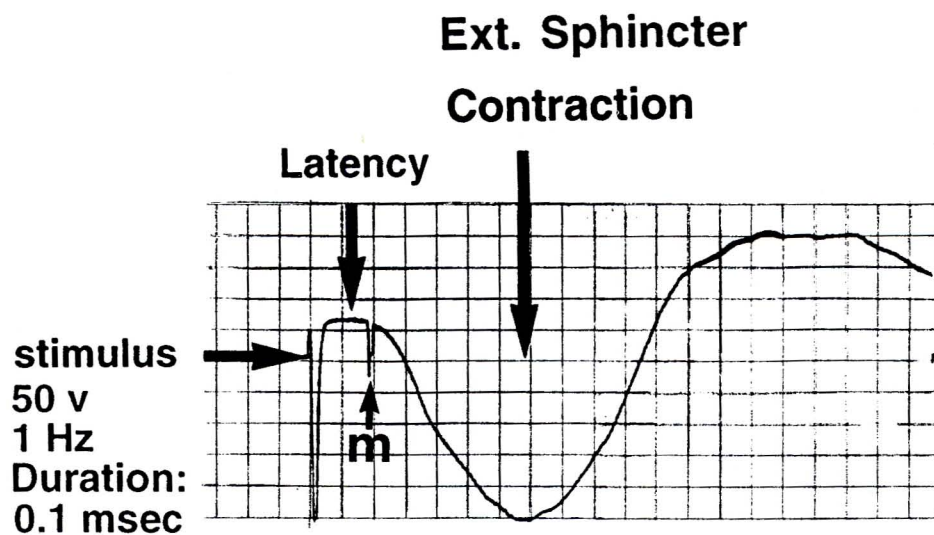
**Figure 2.3** The Medelec MS 92A EMG Electrostimulator

#### 2.2.3.4.3 Technique of measuring PNTML

The patient was placed in the left lateral position and a ground electrode was applied to the thigh. The St. Mark's electrode was mounted on to the gloved index finger and introduced into the rectum (Fig 2.4). The flexible printed circuit terminals of the electrode were connected to an EMG machine via a reusable lead which was attached to the proximal end of the electrode by a quick release clip. The ischial spine was then identified by the index finger in the rectum and a square wave stimulus of up to 50v was delivered. Stimulation of the pudendal nerve at this point resulted in contraction of the external anal sphincter and this was recorded by the electrodes at the base of the finger (Figs 2.2, 2.4). By minor adjustment of the index finger in the vicinity of the ischial spines, the optimum response recognised by a maximum amplitude of external sphincter contraction was obtained. A paper printout was obtained of all recordings. The shortest reproducible latency recording (Fig 2.5) was selected for analysis. The procedure was repeated on the opposite side of the pelvis.



**Figure 2.4** A diagrammatic representation of the technique of measurement of pudendal nerve terminal motor latency using the St. Mark's electrode.  
(Produced with permission from Dr. C Fowler. In *Methods in Clinical Neurophysiology* 1991;2(1):19)



**Figure 2.5** A typical recording of pudendal nerve motor latency

The marker (m) denotes onset of external sphincter contraction.

#### 2.2.3.4.2 Significance of prolonged PNTML measurements

The PNTML is a reflection of function of the fastest conducting fibres (usually myelinated) of the pudendal nerve (Jones et al. 1987). Therefore as damage to slow conducting fibres will not be identified by measurement of the shortest latency, it does not provide a quantitative estimation of the extent of nerve damage. However Parks et al. (1977) found that in patients with histologically proven neurogenic faecal incontinence the myelinated nerve fibres were reduced in number while the unmyelinated nerve fibres were unaffected. This would suggest that fast conducting myelinated nerve fibres may in fact be vulnerable to early damage.

Measurement of PNTML is the only test of nerve conduction that is widely recognised (Keighley et al 1989) and shown to be reproducible (Rogers 1989).

Kiff and Swash (1984a) found that patients with idiopathic faecal incontinence had slowing of motor conduction in the distal pudendal nerve compared to healthy controls. In another study (Kiff and Swash 1984b) they also measured the conduction velocity between L1 and L4 vertebral levels in 9 patients with idiopathic faecal incontinence and concluded that conduction delay in faecal incontinence occurs distally rather than in the spinal canal. Snooks et al (1985) supported this view although in their study they found that 23% of patients with idiopathic faecal incontinence also had proximal conduction delay in the cauda equina (between L1 and L4). It has been suggested that this may result from obstetric trauma, entrapment, or traction injury to the pudendal nerve. Direct compression injury may occur to the

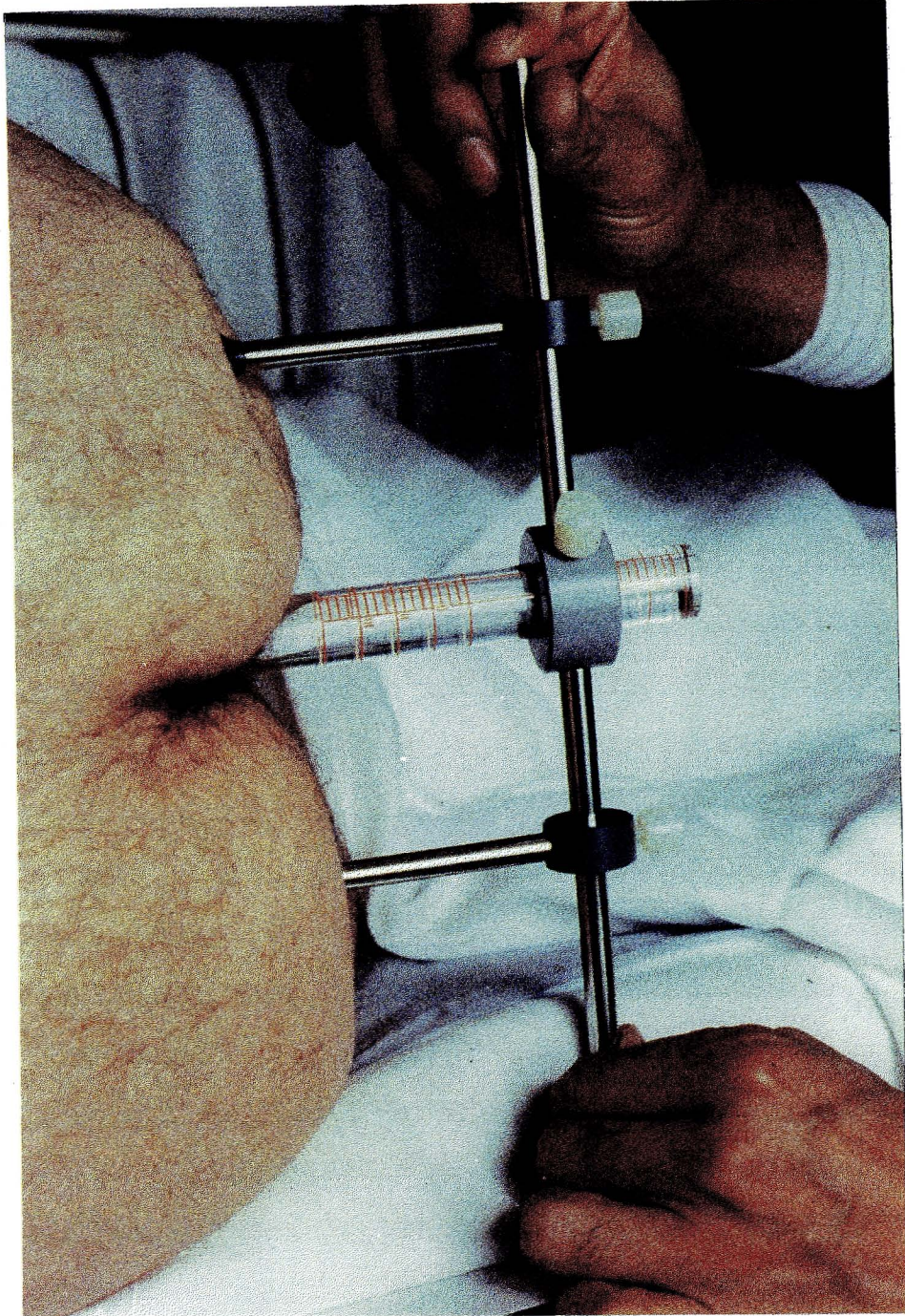
pudendal nerve during childbirth along its course in the pelvis. The nerve is tightly bound by connective tissue as it angulates around the ischial spine and enters the pudendal canal. This is a site of possible entrapment and would lead to a prolonged PNTML as shown to occur in the median nerve during carpal tunnel syndrome (Schwartz et al 1980). However it is generally believed that damage to the pudendal nerves is due mainly to a traction injury following straining and stretching of the nerve distal to the ischial spines (Parks et al 1977, Beersiek et al. 1979, Neill and Swash 1980, Neill et al. 1981, Henry et al 1981). Argument in favour of this theory is discussed further in subsection 2.2.4.2 below dealing with perineal descent.

#### **2.2.4 Perineometry**

Excessive perineal descent was first described by Parks (Parks et al. 1966) who noticed that about 10% of patients attending his anorectal clinic had excessive perineal descent on straining. Hardcastle and Parks (1970) then defined the relationship of the anorectal angle to the pubococcygeal line by taking lateral radiographs of the pelvis after outlining the anorectum with strips of barium-impregnated Ivalon sponge. By this method they demonstrated that, compared to healthy controls, in many patients with faecal incontinence the pelvic floor occupied a lower position in relation to the bony plane. This led to the development of a simple device, The St. Mark's Perineometer, which provided an objective measurement of the plane of the perineum (Henry et al 1982).

#### 2.2.4.1 The St. Mark's Perineometer

This device (Fig 2.6) consists of a freely mobile graduated (0.2 cm increments) perspex rod within a steel frame. The patient is placed in the left lateral position. The vertical limbs of the frame are adjustable so that they can be pressed against the ischial tuberosities. The mobile perspex cylinder is then brought to lie on the anal verge and the plane of the perineum at rest in relation to the ischial tuberosities is documented. The patient is then asked to strain maximally and the plane of the perineum documented. The difference between the plane of the perineum at rest and during a straining effort is actual perineal descent. Perineal descent is regarded as abnormal when the perineum descends below the level of ischial tuberosities (ie. any negative reading) at rest or during straining (Henry et al.1982).



**Figure 2.6 The St. Mark's Perineometer**

The graduated plastic mobile rod slides on the anal verge freely within the metal frame. The limbs of the frame are pressed against both ischial tuberosities and the plane of the perineum measured at rest and during a straining effort.

#### 2.2.4.2 Significance of abnormal perineal descent:

In normal subjects there is little or no perineal descent during straining (Henry et al. 1982). Chronic straining or an abnormal pattern of defaecation can result in tissue stretching and weakness of the pelvic floor resulting in a traction injury to the pudendal nerve. However it is equally possible that direct pudendal nerve injury and resultant denervation could occur as a primary event and lead to atrophy and weakness of the striated muscle of the pelvic floor. It is debatable as to which occurs first; in any event it is likely that a vicious circle is created leading to progressive denervation and weakness of the pelvic floor muscles. In patients with abnormal perineal descent of 2 cm below the ischial tuberosities it is estimated that a stretch of the pudendal nerves of 20 % over the normal length occurs (Henry et al 1980). Since irreversible damage occurs when nerves are stretched by as little as 12% (Sunderland 1978), it is conceivable that perineal descent would lead to pudendal nerve damage.

Direct evidence in support of the hypothesis that perineal descent causes pudendal nerve damage was put forward by Lubowski et al. (1988a). They measured the PNTML before and after a straining effort and found a significant positive correlation between change in the mean PNTML and the amount of descent. Four minutes after the straining effort the PNTML again approached the pre-straining value. This would suggest that the acute stretch-induced injury to the pudendal nerve is in the form of a neuropraxia. Interestingly, straining had much less effect on the PNTML in patients without abnormal perineal descent (Lubowski et al 1988a). Jones et al. (1987) studied

60 patients with idiopathic faecal incontinence and found a significant positive correlation between the mean PNTML and the extent of perineal descent during straining. Lubowski et al (1988b) also highlighted that damage to the pudendal nerves is often asymmetrical. Patients who have a normal mean PNTML of the right and left sides can have abnormally prolonged PNTML unilaterally and this is believed to be clinically relevant (Lubowski et al 1988b).

Conditions associated with chronic straining at stool such as intractable constipation (Kiff et al 1984c), rectal prolapse (Snooks et al 1985a) and solitary rectal ulcer syndrome (Jones et al 1987) have also been shown to be associated with abnormal PNTML. However an increase in PNTML and perineal descent has also been demonstrated with ageing (Laurberg et al. 1989). As these changes have been shown to occur abruptly in the 5th decade and a similar change was not seen in men of the same age (Laurberg et al 1989), the contribution of hormonal changes of the menopause need to be considered. PNTML have also been shown to be increased when measured within 48 hours after vaginal delivery but recovered in the majority by 2 months after delivery (Snooks et al 1984). This is discussed in greater detail in Section 7 relating to obstetric related faecal incontinence.

Oettle et al. (1985) compared measurements of the plane of the perineum as measured by the perineometer to that defined radiologically and found that the perineometer underestimated movement of the pelvic floor by nearly 60%. They commented that since the anal canal shortens dramatically during straining the pelvic floor descends much further than the anal verge which is the plane that is measured

by the perineometer. However the good correlation between the plane of the perineum as measured by the perineometer and PNTML (Jones et al. 1987, Lubowski et al. 1988) would imply that measurements using The St. Mark's Perineometer do have clinical relevance.

## SECTION 3

### STATISTICAL ANALYSIS

Statistics is the science of collection, summarization, presentation, analysis and interpretation of data which can be used to test hypotheses. By plotting the values of a variable the general frequency distribution can be illustrated.

In this section, statistical terminology and tests performed in studies pertaining to this thesis will be described.

#### 3.1 Statistical terminology

**Mean** The sum of the values divided by the number of values.

**Median** The value that divides the distribution in half.

**Mode** The value that occurs most often.

**Range** The difference between the largest and smallest values.

**Variance** The average of the squares of the differences from the mean.

**Standard Deviation (SD)** is a measure of scatter of the data and is the square root of the variance ie.  $SD = \sqrt{[\Sigma(x-x_1)^2 / (n-1)]}$

where  $\Sigma$ =the sum of,  $x_1$ =mean,  $x$ =data point,  $n$ =number. It defines the level of dispersion from the mean of normally distributed data.

**Standard Error of the Mean (SEM)** is a measure of how accurately the overall population mean is estimated by the sample mean. it is determined both by the SD and the number of data points:  $SEM = SD / \sqrt{n}$ . Therefore the larger the sample size, the smaller the SEM.

### **Computer Programme Analysis**

Unless specified otherwise below, Minitab Data Analysis Statistical Software, Release 8.0 (Minitab Inc., University of Pennsylvania, USA) was used.

### **Statistical significance**

A 'P' value of less than 0.05 was considered significant and this is based on an arbitrary convention of the 5% level of statistical significance (Gardner and Altman 1989). The P value is the probability of randomly obtaining a mean difference as large (or larger) than the one observed, when in fact there is no such difference in the overall population. A two-tailed P value as opposed to a one-tailed P value is the probability that chance alone would generate a difference as large as one observed or an equally large difference in the opposite direction and has been applied to the analyses in this thesis.

### **95% Confidence Interval (95% CI)**

While a significant P value suggests that the finding is unlikely to be due to chance, it conveys no information regarding the magnitude of difference between study groups. Assuming that data points are representative of a larger population then it can be deduced with 95% certainty that the mean of the population lies within the 95% confidence interval. The width of the confidence interval is determined both by the scatter of the data (quantitated with the SD) and the number of data points. Wide confidence intervals emphasize the unreliability of conclusions based on small samples

(Gardner and Altman 1989). Where appropriate, 95% confidence intervals of the difference are presented together with P values.

## **3.2 Statistical Tests**

### **3.2.1 Parametric tests**

Normally distributed data is symmetrical about the mean and bell-shaped (Gaussian distribution) with approximately two-thirds of the data lying within one standard deviation of the mean and 95% within two standard deviations of the mean. To determine if data was normally distributed (a pre-requisite for using parametric tests) a normal probability plot was drawn and a normal score was calculated using Minitab Data Analysis (Minitab Pennsylvania). A t test was performed when data was confirmed to be normally distributed. When data was found to deviate from the normal distribution it was logarithmically transformed and a normal score calculated to check normality before analysis.

#### **3.2.1.1 Paired t test**

This tests whether the difference between a pair of measurements of the same variable on each individual is, on average, zero. The paired t test has been used in this thesis to test for a statistical significant difference between similar measurements taken in the same woman before and after delivery.

### **3.2.1.2 Two sample t tests**

A variable measured in 2 different groups was tested to determine whether the mean values are significantly different.

### **3.2.2 Non-parametric tests**

These tests are used when t tests would be inappropriate ie. when data is not normally distributed and cannot be corrected by transformation. The results are expressed as median and range.

#### **3.2.2.1 Wilcoxon signed rank test**

This is the non-parametric equivalent of the paired t test and uses the signs and magnitudes of the data instead of their actual values.

#### **3.2.2.2 Mann-Whitney U test or Wilcoxon rank sum test**

These non-parametric tests are the equivalent of the parametric two-sample t test.

### 3.3 Contingency Tables

When there are two qualitative variables, the data are arranged in contingency tables. A contingency table is also used for discrete quantitative variables or for continuous quantitative variables whose values have been grouped. The categories for one variable define the rows and the categories for the other variable define the columns.

#### 3.3.1 Chi-square ( $X^2$ ) Test

A  $X^2$  statistic is used to quantitate the association between columns and rows. Based on the null hypothesis (data in columns are not related to data in rows) the "expected" value for each cell is calculated and the observed (O) and expected (E) values of each cell compared.

$$X^2 = \sum (O-E)^2/E$$

degrees of freedom = 1 for a 2x2 table.

However the  $X^2$  test can be improved by using the Yates' continuity correction.

$$X^2 = \sum ([O-E] - \frac{1}{2})^2/E$$

where  $[O-E]$  represents the absolute value of  $O-E$ .

The larger the difference the larger the  $X^2$  statistic. From this statistic and taking into account the number of rows and columns, the P value is determined.

#### 3.3.2 Fisher's exact test

When the expected numbers are small the  $x^2$  test is inappropriate and the alternative

exact test has been used. Cochran (1954) recommends the use of the exact test if the overall total of the table is less than 20 or the overall total is between 20 and 40 and the smallest of the four expected numbers is less than 5.

### 3.3.3 Odd's ratio

If there are only two rows and columns, the association between rows and columns can be expressed as the Odd's ratio if the top row contains the numbers A and B and the bottom row C and D then the odd's ratio is defined as  $(A/B)/(C/D)$ . If there is no association between rows and columns the odd's ratio will equal one. If the association between rows and columns is strong, the odd's ratio will either be much greater or much less than one.

### 3.3.4 Relative Risk

Relative Risk = incidence among exposed/incidence among non-exposed.

When there is no association between risk factor and the disease a relative risk of 1 occurs. A relative risk of greater than 1 occurs when the risk of the disease is higher among those exposed to the factor than among the non-exposed. The computer programme used for this purpose in Section 7.3 was Confidence Interval Analysis (British Medical Association).

### 3.4 Correlation and linear regression

**3.4.1 Correlation** measures the closeness of the association between two continuous variables, while linear regression gives the equation of the straight line that best describes it and enables the prediction of one variable from the other. The association is measured by the correlation coefficient 'r'.

$$r = \frac{\Sigma(x-x_1)(y-y_1)}{\sqrt{[\Sigma(x-x_1)^2 \Sigma(y-y_1)^2]}}$$

where  $x$  = values on the  $x$ -axis,  $y$  = values on the  $y$  axis, and  $x_1$  and  $y_1$  the corresponding means.

The correlation coefficient always lies between -1 and +1 and equals zero if the variables are not linearly associated.

A correlation between two variables shows that they are associated but do not necessarily imply a 'cause and effect' relationship. A  $t$  test may be used to determine whether the observed correlation could be due to chance.

**3.4.2 Linear regression** gives the equation of a straight line that describes how the  $y$  variable (dependent variable) changes with an increase in the  $x$  variable (independent variable).

$$y = a+bx$$

where  $a$  is the intercept, and  $b$  the slope of the line (regression coefficient)

### 3.4.3 Multiple regression

For a quantitative response, multiple regression is the most common method of statistical adjustment and analyses the relationship between a single quantitative dependent variable and many quantitative explanatory variables. For a qualitative response, where each patient is classified as achieving a response or not, one can use a multiple logistic regression model as being equivalent to multiple regression for a quantitative response. Multiple regression can be used both to determine the joint effect of the explanatory variables on the dependent variable, and to determine the association between the dependent variable and a single explanatory one corrected for the confounding effects of the remaining factors. Logistic regression entails using the odds ratio as the measure of association and 95 percent confidence intervals for the odds ratio can be obtained by taking the regression coefficient plus or minus 1.96 times its standard error and taking the exponential of the result. The computer programme used for this analysis was SAS statistical software (SAS Institute, Cary, N Carolina, USA).

### 3.5 Validity of data collection

**Sensitivity** is the proportion of true positives that are correctly identified ie. the probability of a test being positive in patients with the condition (detection rate).  $[TP/TP+FN]$  where TP = true positive, TN = true negative, FP = false positive, FN = false negative.

**Specificity** is the probability of a negative result in cases without the condition.

$$[TN/TN+FP]$$

**Positive predictive value** is the proportion of cases with an abnormal result who have a clinical abnormality.  $[TP/TP+FP]$

**Negative predictive value** is the proportion of cases with a normal test result who do not have the clinical abnormality.

$$[TN/TN+FN]$$

**Accuracy** is the sensitivity + specificity

**Relative Risk** of greater than one suggests an increased risk as a consequence of a positive test and a risk less than one suggests that a positive test indicates reduced risk.

## SECTION 4

### THE ANATOMY OF THE ANORECTAL MUSCLES

#### 4.0 INTRODUCTION

In this section, the anorectal anatomy is reviewed with emphasis on the anal sphincter mechanism. The interpretation of images produced by anal endosonography is validated by simultaneous in vitro and also in vivo dissections. The normal anatomical appearance of the anorectal musculature in both the male and female is described and differences between in vivo and in vitro anatomy discussed.

Since the first description of the anal sphincters by Galen in 170 AD, there has been a notable inconsistency in the literature regarding their anatomical relationship and physiological function. To date, this controversy remains largely unresolved. Perhaps the single most important reason behind this is that there is a considerable degree of individual variation not only because of differences in gender but also because of intra-individual asymmetry in muscle distribution. Differences in nomenclature of the same structure and the desire by investigators to subdivide and rename these structures further perpetuated the confusion. To this effect, Gorsch (1941 p.61) made this statement about the external anal sphincter, "Anatomic dissections...will depend very much on a preconception ...and 'wishful' anatomy may unwittingly confuse the actual anatomic arrangement to hand".

Previous descriptions of the anorectal musculature have been based largely on dissections of elderly embalmed cadavers and less frequently on fresh post mortem specimens, neonates and fresh post-surgical specimens. The muscles of the external anal sphincter and levator ani complex are in a state of tonic contraction even at rest. It is therefore not surprising that in vivo anatomy may be difficult to reproduce in its entirety from dissected specimens that have lost their tone. Therefore imaging techniques such as ultrasound and magnetic resonance imaging need to be exploited so that the knowledge obtained from anatomical dissections can be correlated with in vivo findings. This in turn should enable a more precise diagnosis of abnormalities using minimally invasive techniques.

This section of the thesis includes a literature review of the anatomy of the pelvic floor and anal sphincter, a study to demonstrate the macroscopic and microscopic anatomy of the anal sphincter, two studies which describe the in vitro and in vivo endosonographic anatomy in the male and female and lastly a study to determine the effect of pregnancy per se on the morphology and function of the anal sphincter.

## SECTION 4.1

### LITERATURE REVIEW OF THE ANATOMY OF THE PELVIC FLOOR AND ANAL SPHINCTER

#### 4.1.1 The Levator Ani

Andreas Vesalius (1543) is regarded as the first to describe the levator ani as consisting of a group of muscles. Thompson (1899) subdivided this group of striated muscles into three, namely, the pubococcygeus, ileococcygeus and coccygeus. The pubococcygeus arises anteriorly from the posterior aspect of the pubic bone and from the anterior portion of the arcus tendineus (white line) which is a condensation of the obturator internus fascia. The medial fibres of the pubococcygeus merge with the fibres of the prostate, vagina and perineal body and have been given various names such as levator prostaticus, pubourethralis, rectourethralis and pubovaginalis. The ileococcygeus arises from the remainder of the arcus tendineus partly overlapping the pubococcygeus on its perineal surface and extending to the medial surface of the ischial spine. The coccygeus or ischiococcygeus is a rudimentary muscle arising from the tip of the ischial spine and quite often constitutes only a few muscle fibres on the sacrospinous ligament. The development of the coccygeus varies reciprocally with that of the ligament (Wendell-Smith 1967). Posteriorly, the muscles of the levator ani or pelvic diaphragm insert into the sides of the coccyx and the anococcygeal raphe which is formed by the interdigitation of muscle fibres from either side. Courtney (1950) maintains that the term "anococcygeal raphe" is a misnomer because at no point does

this tendinous raphe attach to the anus. It terminates anteriorly attaching to the superior surface of the puborectalis, and he refers to it as the "coccygeal muscular raphe". The most medial fibres of the pubococcygeus that pass round the rectum at the anorectal junction form the puborectalis muscle. Defects in the downward and forward sloping levator ani allow the urethra, vagina and rectum to pass.

Parks (1958) referred to the 'twin levatores ani' dividing the levator into an upper lamella which contributes to the conjoined longitudinal muscle and a lower lamella which is divided into the ileococcygeus and pubococcygeus. More recently, Bustami (1989) described the levator ani as having two parts, a fleshy anterior portion and an aponeurotic posterior portion. He further subdivided the anterior portion into a superficial perineal layer and a deep pelvic layer, each having a different innervation. The puborectalis muscle has an intimate but debatable association with the external anal sphincter and these two will therefore be discussed together.

#### **4.1.2 The Anal Sphincter Mechanism**

Proximally the external anal sphincter lies in contiguity with the puborectalis (at least posteriorly); distally it merges with the perianal skin. Like the levator ani it is primarily composed of striated muscle. Medial to the external sphincter lies the longitudinal muscle which is a continuation of the longitudinal smooth muscle of the rectum but also has contributions from adjacent muscle and hence it is often known as the conjoined longitudinal muscle. The internal anal sphincter is a thickened extension of the circular smooth muscle of the bowel and lies medial to the

longitudinal muscle. Between the anal canal and the internal anal sphincter lies the muscularis submucosae ani and the anal epithelium.

#### 4.1.2.1 Embryological considerations

The levator ani muscles develop separately from the anal musculature, arising together with the pelvic bones and urogenital viscera (Gorsch 1955 p.25). The anal canal develops from the anterior aspect of the cloacal membrane overlying the post-allantoic gut. The proctodeum, which is an invagination of the ectoderm in this region, becomes encircled by a developing ridge of anal musculature derived from the lateral mesoderm. As development proceeds this primitive sphincter cloacae becomes divided by fusion of the anal tubercles; this separates the urogenital sphincter anteriorly from the anal sphincter posteriorly. The sphincteric muscle can first be recognised as a distinct entity in an eight week old embryo (Power 1948). The common development of the perineal musculature may easily lead to developmental variations and perhaps explains the confusion encountered during anatomical dissection. Once invagination is complete, the anal canal is separated from the primitive rectum by the anal membrane or proctodeal plate which is lined by endoderm above and ectoderm below. The levator ani muscles and external sphincter muscles are clearly delineated by the end of the second month although connected in the mesenchymal space interposed between the anal canal and urogenital sinus. The time of appearance of these two groups of muscle is also different (the sphincter formed by promyoblasts that are less differentiated than the myoblasts of the levator ani) supporting the opinion that these

muscles have different origins (Levi et al 1991). The inner circular and outer longitudinal muscle and the muscularis mucosa of the rectum develops from the surrounding mesoderm. These become enveloped by the advancing external anal sphincter at the ano-rectal junction. The line of continuity is by not abrupt; hence there is an irregular "transition" zone at the dentate line which has alternating areas of squamous and columnar epithelium.

#### **4.1.2.2 The Puborectalis and the External Anal Sphincter (EAS)**

A uniform consensus of opinion regarding the structural subdivisions of the EAS is lacking in the literature. It has been described by some authors as one structure while others have subdivided it into two or even three components (Table II). In 1543 Andreas Versalius and the artist John Calcar of Clive (Vesalius, 1543) produced the first illustration of the anorectal musculature depicting the EAS as a single tubular structure. As far as can be established, Santorini (1710) was the first to divide the EAS into three parts but it was Holl (1897) and Thompson (1899) who gave the EAS its present tripartite nomenclature: subcutaneous, superficial and deep EAS. Prior to this, important contributions to the literature were also made by Kohlrausch (1854), Rudinger (1878), Robin and Cadiat (1874) and Laimer (1884). However, it was only after Milligan and Morgan (1934) and Gorsch (1941,1955) supported this tripartite concept that it was accepted into textbooks (Gray 1954, Last 1954, Grant 1952). Milligan and Morgan (1934) described the subcutaneous and deep EAS as annular muscles not attached to the coccyx and the superficial EAS (middle layer) as being elliptical with fibres running antero-posteriorly from the perineal body to the coccyx

and the ano-coccygeal raphe. The deep EAS, also known as the "sphincter ani externus profundus", has anterior fibres which cross over to the opposite side and combine with the superficial transverse perinei attaching to the ascending ramus of the ischium. Gorsch (1955) and Uhlenhuth (1953) endorsed this arrangement of muscle fibres in their illustrations. Gorsch, however, pointed out that, in the female most of the fibres of the superficial EAS diverge anteriorly and fuse into the bulbocavernosus. In the male, by contrast, the fibres converge into the central tendinous raphe. More recently, Shafik (1975a) in his attempt to provide a "new concept" of the anatomy of the anal sphincter mechanism described the "triple loop". The top loop he considered as including the puborectalis muscle and the deep portion of the EAS; the intermediate loop (equivalent to the superficial EAS) attaching to the pubis and the base loop (equivalent to the subcutaneous EAS) attaching to the perineal skin. Shafik (1982) claimed that "the anal canal does not exist, neither embryologically nor anatomically, and that the rectum extends down to the perineal skin". He also maintained that the puborectalis is part of the EAS (Shafik 1975b) and that each loop has a different nerve supply. This concept, in addition to the identification of new structures such as the 'anal suspensory sling', 'hiatal ligament' and 'central space', has not gained widespread acceptance (Haas and Haas, 1988). Ayoub (1979), in total contradiction to Shafik's descriptions, demonstrated a fibrous cleft between the deep EAS and the levator ani muscles. Bustami (1988) was also sceptical about Shafik's proposition; he demonstrated by anatomical dissection of the pelvic floor muscles and micro-dissection of the pelvic nerves that the puborectalis belongs to the deep pelvic layer of the anterior portion of the levator ani. Levi et al (1991) dissected 18 human embryos and foetuses ranging from 6 to 16 weeks and

**Table II** Descriptions of the external anal sphincter given by various authors as one, two or three parts.

<b>THREE COMPONENTS</b>	<b>TWO COMPONENTS</b>	<b>ONE COMPONENT</b>
Santorini 1715	Galen 170 A.D.	Vesalius 1543
Holl 1897	Hiller 1931	Cowper 1694
Milligan & Morgan 1934	Courtney 1950	Goligher 1984
Levy 1936	Fowler 1957	Bassett 1961
Eaton 1942	Walls 1963	Ayoub 1979
Gorsch 1941,1955	Wilson 1967	Dalley 1987
Wilde 1949	Kerremans 1969	
Uhlenhuth 1953	Oh & Kark 1972	
Hughes 1956	Lawson 1974b	
Stonesifer et al 1960	Parks 1958	
Morgan & Thompson 1956	Levi et al 1991	
Shafik 1975a		
Stelzner 1981		
Wendell Smith 1986		

demonstrated that both the external anal sphincter and the urogenital sphincter originate from the cloacal sphincter and have no connection with the puborectalis which they considered to be part of the levator ani muscle.

Lawson (1974a) divided the puborectalis into two sections: the 'puboanalis' which is part of the levator ani; the 'puboanal sphincteric sling' which blends with the posterior third of the deep EAS. Each has a unique innervation. Using electro-physiological techniques Percy et al (1980) demonstrated that the motor supply of the puborectalis is via direct branches of the sacral nerves (S3 and S4) and that of the EAS is via the pudendal nerve (S2,S3,S4). The consensus of opinion is therefore in support of the original description given by Holl (1897) and Thompson (1899) in which the puborectalis is regarded as part of the levator ani. Nevertheless, close cohesion between these muscles would seem to be essential because without it peristalsis would pull the rectum upwards and over its contents without expelling them through the anus (Morgan 1948).

Courtney (1950) and Fowler (1957) were unable to reproduce the 'tripartite' EAS described above. They proposed a two part classification: superficial (equivalent to the subcutaneous component of the trilaminar classification); and deep EAS (equivalent to the superficial and deep components of the trilaminar classification). It is interesting to note that Milligan and Morgan (1934), the so called "modern founders" of the trilaminar EAS, state that only "in its most differentiated form three portions are distinguishable" and that sometimes only two separate portions can be identified. Oh and Kark (1972) noted that the subcutaneous and superficial EAS were more closely related posteriorly than laterally, yielding a bilaminar arrangement in one

plane and a trilaminar in another. They decided to adhere to the bilaminar classification used by Courtney (1950) and Fowler (1957) but to add to the confusion their "superficial" layer included the subcutaneous and superficial layer as described by Milligan and Morgan (1934) and their "deep" layer included the puborectalis and the deep EAS. Other authors supporting the two part classification are listed in Table II.

Frustration in attempts to identify these subdivisions of the EAS led some authors to propose that the EAS is in fact a single structure with no real sub-components ie. as described by Vesalius (1543) and Cowper (1694). The detailed illustrations given by Bassett (1961) demonstrate no subdivisions. Goligher et al (1955) in their critical review of previous descriptions of the anatomy of the anal canal could not identify in their own dissections any clear divisions within the EAS. They could, however, recognise that the lowermost or subcutaneous portion of the EAS differed in that it was traversed by longitudinal muscle fibres which split this part of the EAS into numerous discrete bundles. This description has also been incorporated into the regularly revised surgical textbook "Surgery of the Anus Rectum and Colon" (Goligher, 1984 p 10). Dalley (1987) in his review of the literature on this subject reflected his strong condemnation of the confusion created by others in attempts to partition the EAS and recommended that "the three part external anal sphincter be removed from gross anatomy texts, dissectors and atlases and be relegated to the junkyard of anatomic trivia where it may languish for the sake of the historical anatomist ...".

### 4.1.3 The Longitudinal Muscle (LM)

Despite its first description in the last century (Cruveillier, 1843; Kohlrausch, 1854; Rudinger, 1873; Robin and Cadiat, 1874; Roux, 1881; Laimer, 1884; Holl 1897), the functional significance and anatomical distribution of the longitudinal muscle remains enigmatic. The LM of the anal canal is a direct continuation of the LM of the rectum. Abel (1932) described the LM as passing down the anal canal in two parts; firstly as passing through the EAS and dividing it into superficial and deep parts; and secondly passing laterally to it and forming an external capsule for the muscle. Milligan and Morgan (1934) describe the LM as passing down from the anorectal ring blending with fibres of the puborectalis and enveloping the internal anal sphincter (IAS). Between the lower border of the IAS and the upper border of the EAS it attaches to the anal skin to form the anal intermuscular septum. Laterally, some LM fibres pass into the ischiorectal fossa and divide it into a superficial perianal space and a deep compartment (Milligan 1943). Many of the fibres then pass outwards traversing the subcutaneous EAS to insert into the perianal skin. Wilde (1949) points out that these final ramifications form the 'corrugator cutis ani' which was inappropriately named as a separate entity by Ellis (1878 p.420). Shafik (1976) considers the LM to consist of three layers, each having a different origin and separated by fascial septa. Morgan and Thompson (1956) called it the 'conjoint LM' because of the contributions it receives from the puborectalis muscle and Levy (1936) described the LM as a fibro-elastic structure (conjoined LM) terminating as a series of slips of varying thicknesses. This might explain the elusive nature of this structure during intra-operative dissections. Further medial and lateral extensions of the LM are described in a recent review by Lunniss and Phillips (1992).

#### 4.1.4 The Internal Anal Sphincter (IAS)

Less disagreement surrounds the anatomy of the IAS. It is continuous with the inner circular muscle of the rectum and an increase in the muscular component makes it a discrete and well defined structure. As it approaches the skin it becomes fibro-elastic (Gorsch 1955 p.67) but terminates in a sharply defined and rounded lower margin, separated from the subcutaneous EAS by the anal intermuscular septum. The IAS measures about 3 mm. in length and 5 mm. in thickness (Wilde 1949; Eisenhammer 1953; Stonesifer et al 1960). The muscle fibres are grouped into discrete elliptical bundles which in the proximal part of the IAS lie obliquely with their axes running medially and downwards. Distally this obliquity becomes progressively less. Eventually, the muscle bundles lie horizontally and some of the lowermost fibres even incline upwards (Goligher et al 1955; Lawson 1974b). The question of whether longitudinal muscle fibres traverse the IAS is unsettled. Some propose that traversing fibres originate in the submucosal layer (Rudinger 1878), some have identified fibres originating in the longitudinal muscle layer (Roux 1881; Hughes 1956), some have attributed the origin of the longitudinal muscle fibres to the IAS itself (Lawson 1974b; Kerremans 1969; Hughes 1956) while others maintain that no longitudinal muscle fibres cross the IAS (Gorsch 1955 p. 74).

#### 4.1.5 Muscularis Submucosae Ani / Submucosa (SM)

Scanty reference is made to this layer in the literature. Unlike bowel mucosa, anal mucosa is devoid of muscle and hence by definition, the subepithelial layer is not a true submucosa. Fine and Lawes (1940) demonstrated continuity between the superficial layer of anal subepithelium and the muscularis mucosae of the rectum and proposed the term 'muscularis submucosae ani'. However to avoid confusion the commonly used nomenclature 'submucosa' will be adopted throughout this thesis.

Wilde (1949) confirmed the findings of Fine and Lawes (1940) and demonstrated that the proximal fibres of the submucosa were derived from two sources. The more superficial fibres were continuous with the muscularis mucosae of the rectum while the deeper fibres were derived from the outer longitudinal muscle with fibres traversing the IAS. Both these strata fuse distally at the lower border of the IAS and become continuous with the most medial septum of the longitudinal muscle coat.

## SECTION 4.2

### MACROSCOPIC AND MICROSCOPIC ANATOMY OF THE ANAL SPHINCTER COMPLEX

#### 4.2.1 INTRODUCTION

A lack of consistency in the description of anal sphincter anatomy in the literature (Section 4.1) has led to confusion amongst anatomists and clinicians. Accurate interpretation of sonographic images of the anal sphincter requires a clear understanding of the normal anatomy. In the absence of clear anatomical definition, the precise interpretation of sonographic images of the anal sphincter will not be possible. The study aimed to examine the anal sphincter complex both macroscopically and microscopically, looking specifically at the subdivisions and configuration of the external anal sphincter, the internal sphincter and the relationship of these sphincter muscles to the longitudinal muscle.

#### 4.2.2 MATERIALS AND METHODS

Informed written consent, to excise tissue at autopsy for research purposes was obtained from the next of kin. There were 9 premature stillborn fetal or neonatal, and 6 adult specimens. Fresh tissue from a further 4 patients was obtained from post-surgical specimens during abdomino-perineal excision of the anorectum. The excised specimen was either opened longitudinally in the mid-anterior plane (for longitudinal sections) or left intact (for transverse sections) before being pinned onto a cork board

and fixed in formalin. A diagram of each specimen was made to ensure correct orientation. One foetal specimen and 3 adult specimens were dissected fresh in order to assess adherence of adjacent tissues; one fetal specimen could not be dissected because of autolysis.

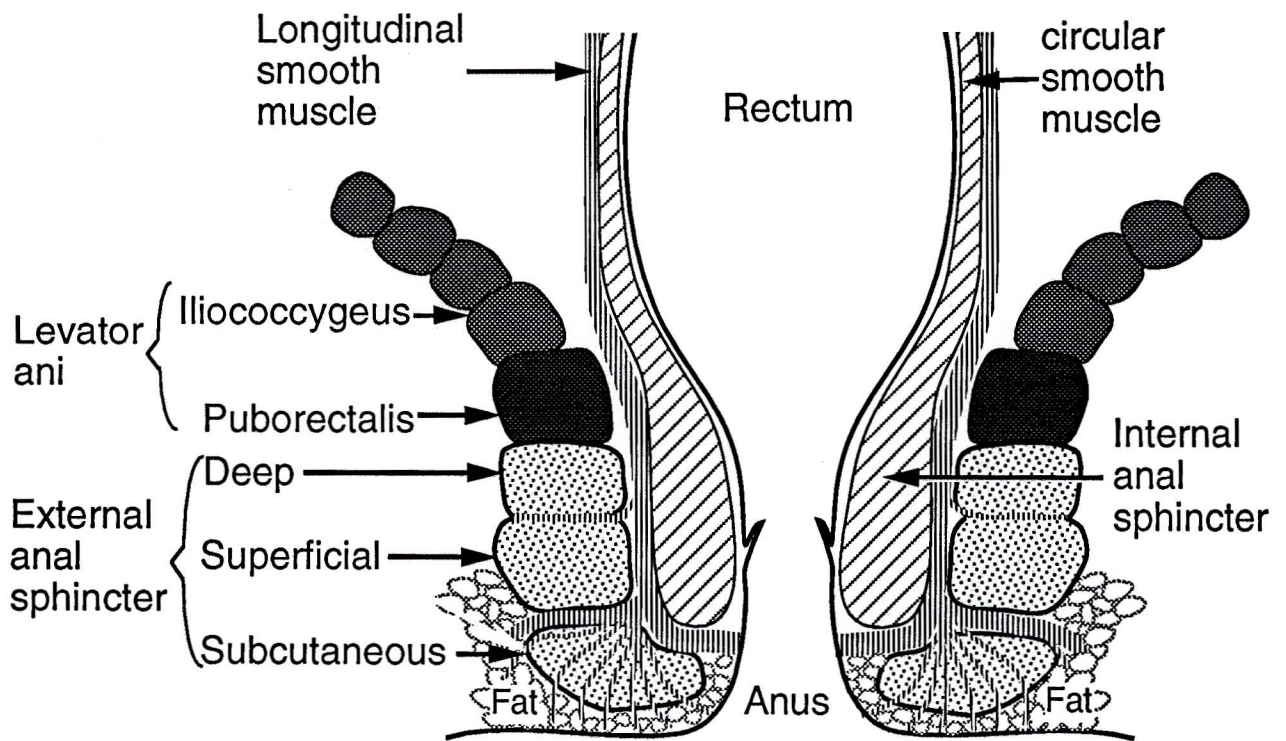
Fresh specimens were examined with the aid of a dissecting microscope. The remainder were left in formal saline for 24 hours before embedding in wax, and multiple 4 $\mu$ m sections prepared. These were stained with Haematoxylin & Eosin and van Gieson stains. Multiple longitudinal sections were taken from all 4 quadrants, and transverse sections from 4 levels: anal verge; region of the dentate line, above the dentate line but below anorectal junction, and rectum.

### **4.2.3 RESULTS**

#### **4.2.3.1 Macroscopic dissections**

The epithelium, internal sphincter, longitudinal muscle, external sphincter and fat were easily distinguishable macroscopically in both foetal and adult specimens (Fig 4.1a). However there was a considerable degree of adherence between adjacent layers. In particular adherence between the internal and external sphincter muscles and the interposed intersphincteric tissue which was most evident anteriorly and posteriorly. Proximally, muscle fibres from the posterior aspect of the external sphincter attached to the coccyx; this was not evident distally. Fibrous bands crossed the internal anal sphincter from the medial border of the intersphincteric space to the submucosal

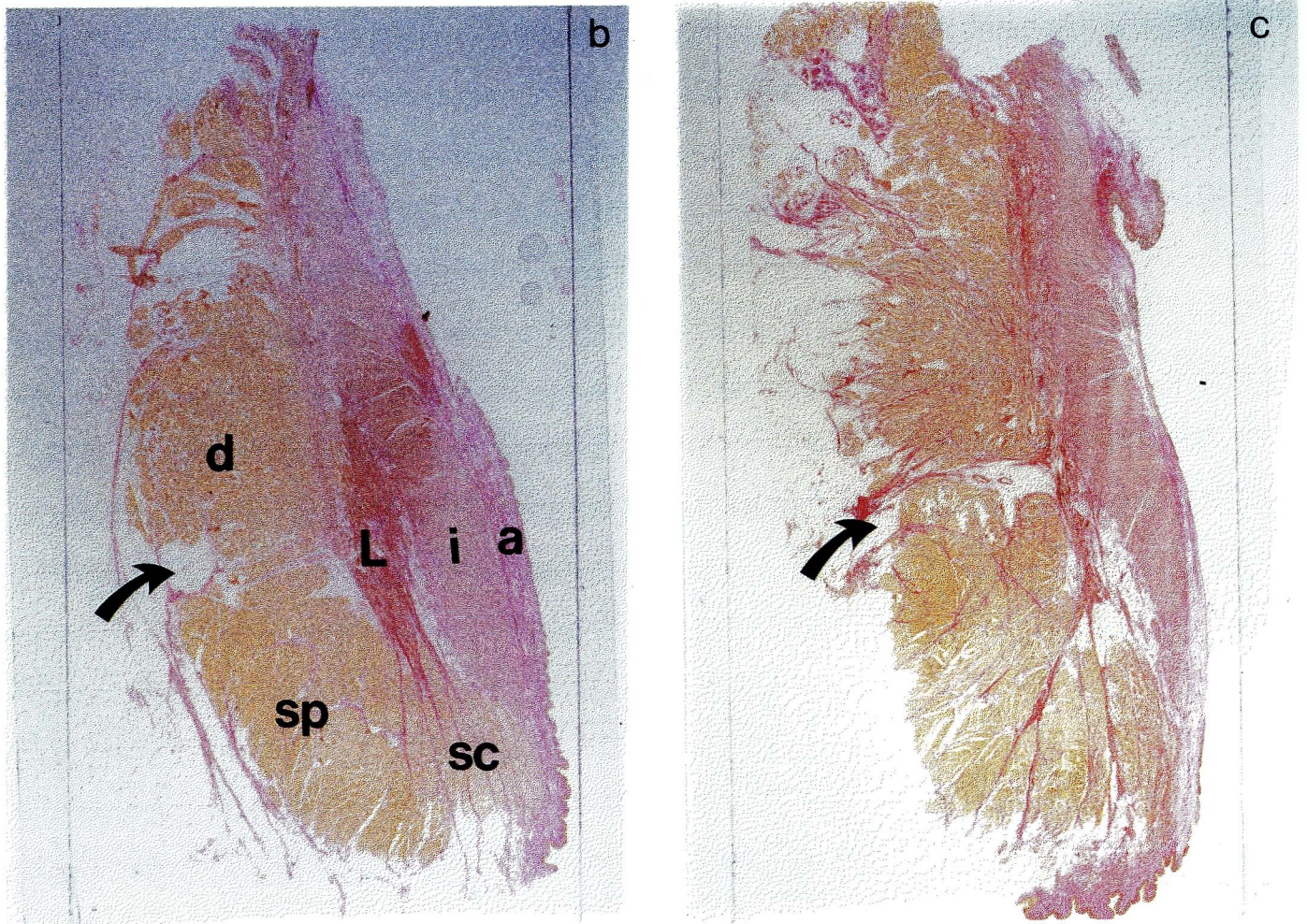
connective tissue, and fibres traversed the inferior border of the internal sphincter. There were no distinguishing features between the deep and superficial external sphincter. However the subcutaneous part of the external sphincter could not be separated from the intersphincteric fibres without sharp dissection. Fibres from the intersphincteric space ramified within the subcutaneous external sphincter and terminated by attaching to the perianal skin. Although detachment from the coccyx and perineal body during excision caused some distortion, the superficial external sphincter appeared widest in the antero-posterior plane. No obvious line of demarcation was seen between the deep and superficial external sphincter nor was there any obvious distinction between external sphincter and puborectalis.



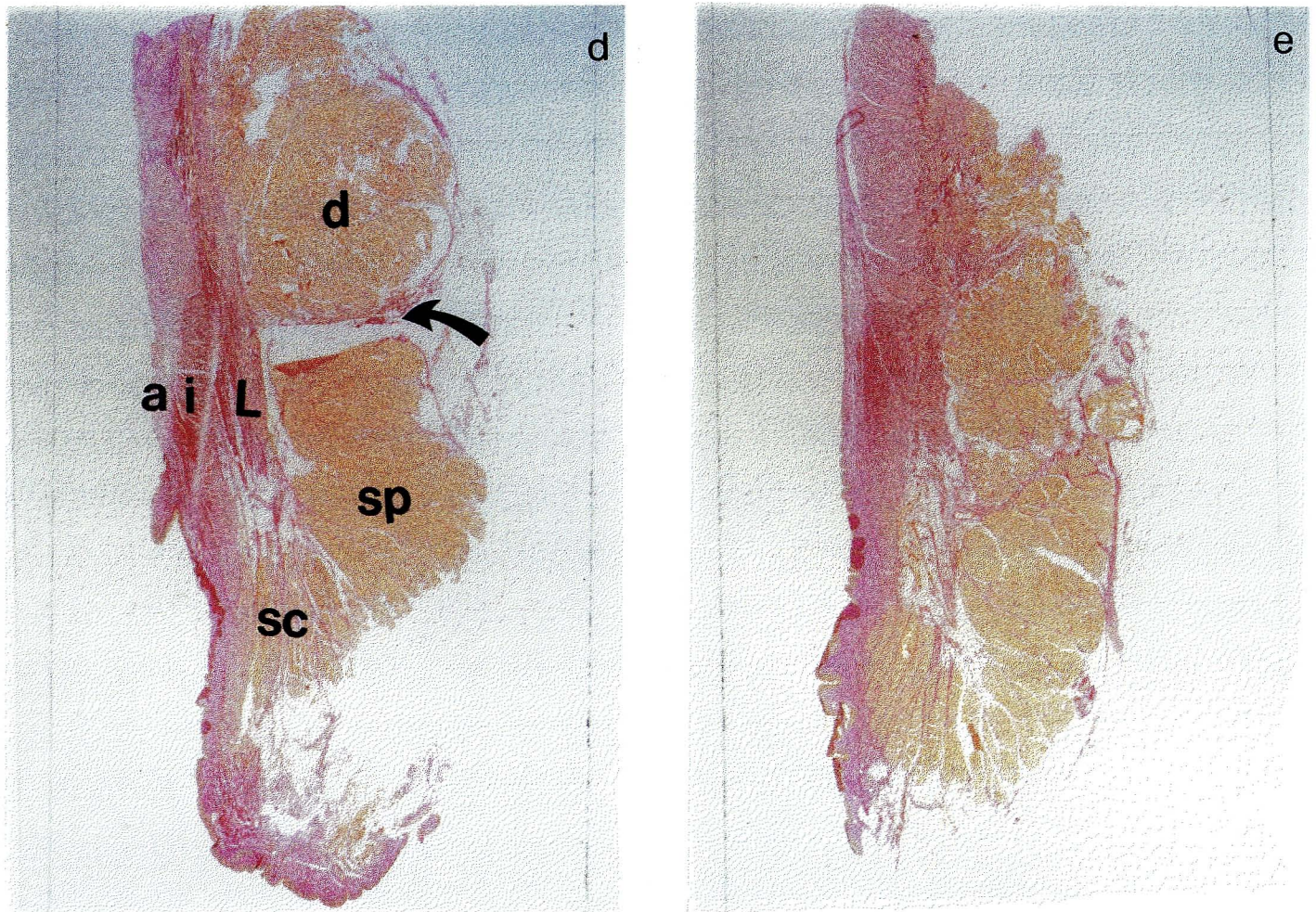
**Figure 4.1a Schematic representation of the muscles of the anorectum.**

#### 4.2.3.2 Histological examination

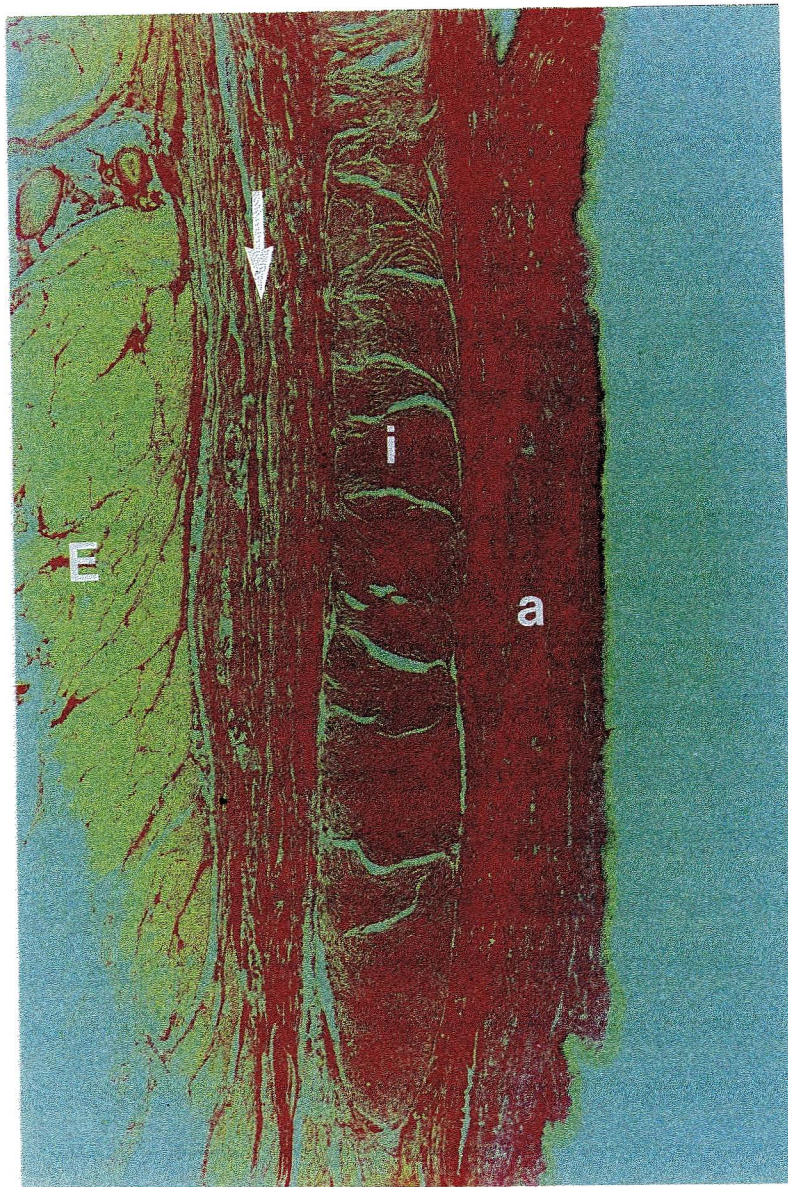
In several longitudinal sections of adult anal canals the external sphincter appeared to be split by a variable number of connective tissue bands running laterally from the intersphincteric space towards the ischiorectal fossa. Therefore in some sections, three components of the external sphincter could be separately identified, namely the subcutaneous, superficial and deep (Figs 4.1b,c,d) whilst in others the superficial and deep components were indistinguishable (Fig 4.1e). However, the subcutaneous component was identified consistently in all specimens by the distinct terminal ramifications of the intersphincteric fibres traversing the external sphincter (Figs 4.1 a-f). An important observation was that there were both inter and intra-individual differences in the subdivisions of the external sphincter. In no specimen were 3 subdivisions of the external sphincter seen consistently in all four quadrants (Figs 4.1 b-e).



**Figure 4.1 b,c.** Longitudinal section through the anterior (b) and right lateral (c) aspect of the anal canal of a 56 year old male (post mortem specimen). a = anal epithelium, i = internal sphincter, L = longitudinal muscle. The subcutaneous (sc), superficial (sp) and deep (d) components of the external anal sphincter are demonstrated. The arrow indicates a possible line of cleavage between the superficial and deep external sphincter. (van Gieson stain, x4).



**Figure 4.1 d,e.** Longitudinal section through the posterior (d) and left lateral (e) aspect of the anal canal of the same specimen shown in Figs 4.2 b&c). a = anal epithelium, i = internal sphincter, L = longitudinal muscle. The subcutaneous (sc), superficial (sp) and deep (d) components of the external anal sphincter are easily identifiable in Fig 4.1d despite an artifact created during preparation of the slide. By contrast in Fig 4.1 e the demarkation between the superficial and deep component is barely discernible.




**Figure 4.1f** Longitudinal section of the lower anal canal of a 46 year old male (post-operative specimen) demonstrating the replacement of brown staining smooth muscle fibres in the intersphincteric space (arrowed) by pink staining connective tissue. a=anal epithelium and sub-epithelium, i=internal sphincter, E=external sphincter. (van Gieson x4).

#### 4.2.3.2.1 The Intersphincteric Space

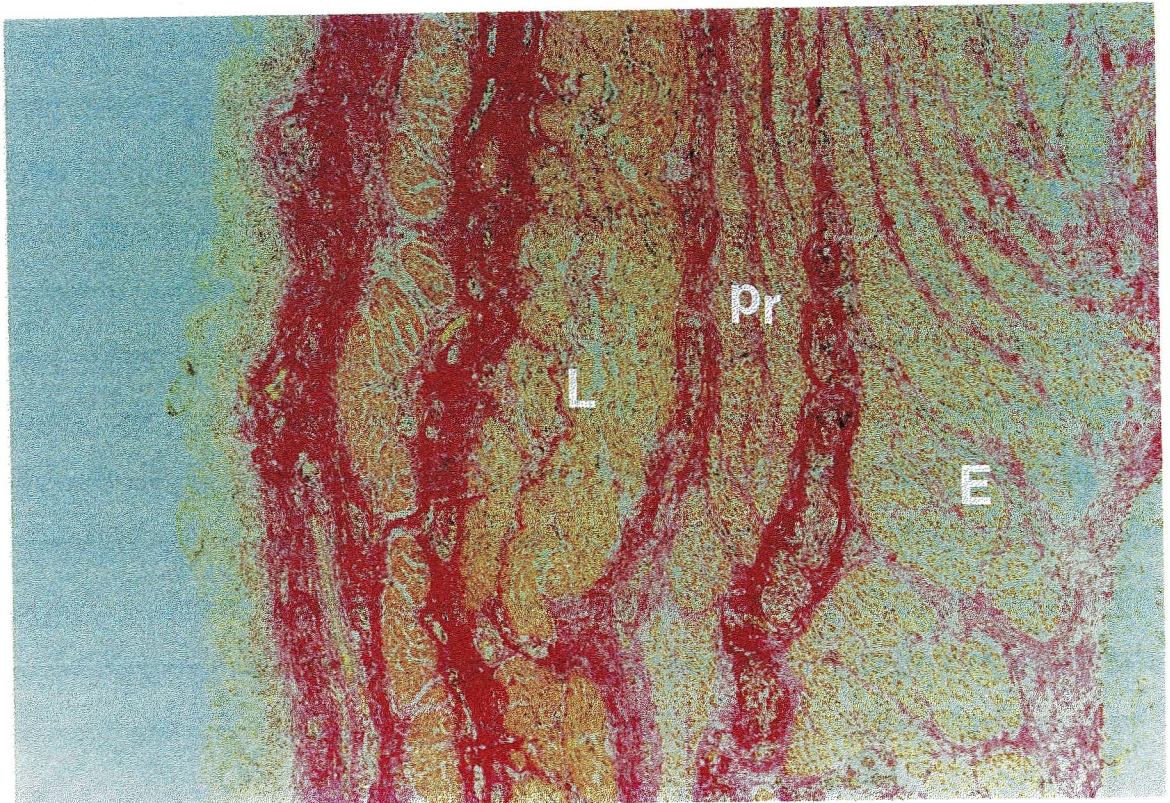
In the foetal specimens, the intersphincteric space throughout the length of the anal canal was filled predominantly by the smooth muscle continuation of the longitudinal muscle coat of the rectum (Figure 4.1g). There was also a contribution from the puborectalis muscle passing inferomedially down the lateral aspect of the intersphincteric space between the longitudinal muscle proper and the medial aspect of the external anal sphincter (Figure 4.1h). The amount of muscle from the puborectalis component diminished distally, such that by the mid-anal level, it had been virtually replaced by connective tissue running down alongside the connective tissue on the lateral aspect of the longitudinal muscle. Muscle fibres occupied at least 80% of the thickness of the space at the upper end of the canal, falling to 50-60% at the lower border of the internal anal sphincter, there being relatively more connective tissue distally. In longitudinal sections, connective tissue (running in the same direction as the longitudinal muscle) appeared to be restricted to either side of the main muscle mass, being thicker medially (between internal sphincter and longitudinal muscle) than laterally (between longitudinal muscle and external sphincter). On transverse sections, however, connective tissue bands were seen to cross between the longitudinal muscle bundles in much the same way as are seen within the internal sphincter on longitudinal sections (Fig4.1i,j). The width of the intersphincteric space was similar to that of the internal sphincter at all levels. A separate muscular contribution from the external sphincter to the intersphincteric space was not identified.

The most striking difference between foetal and adult intersphincteric space was the relative paucity of smooth muscle in the adult sections. Although the width of the

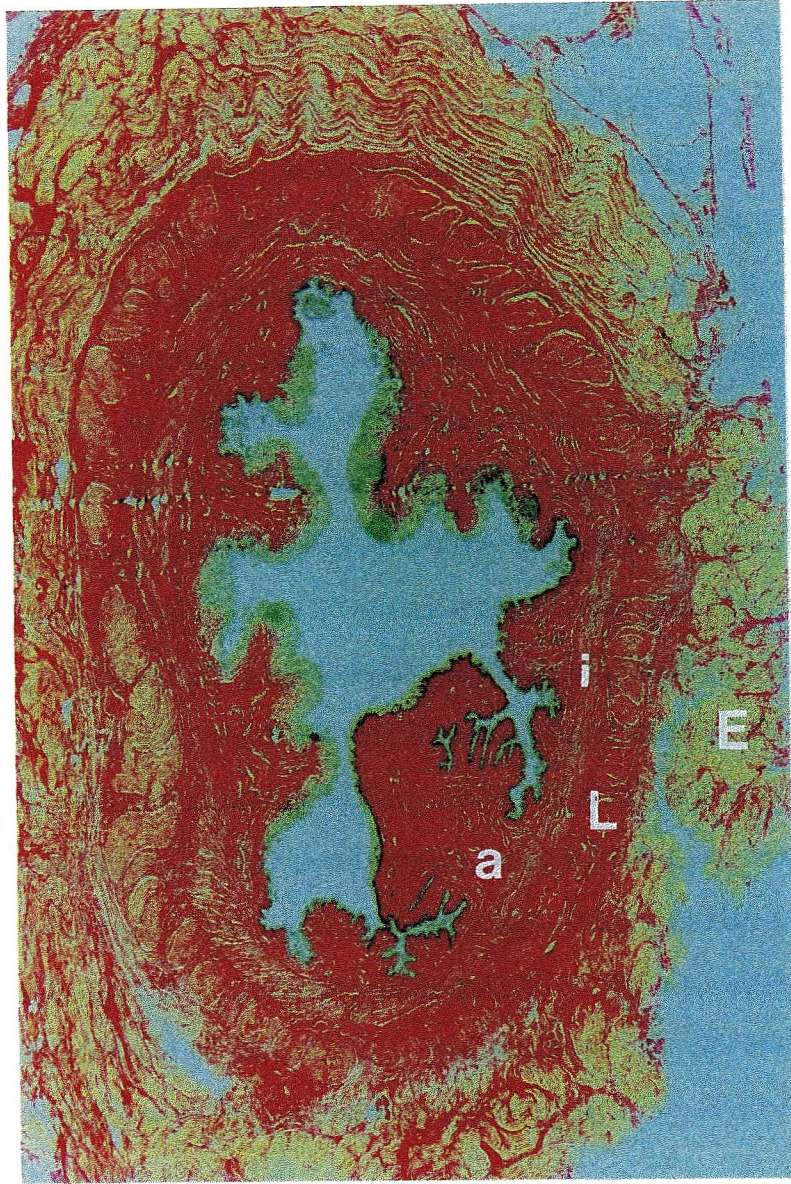
space was similar to that of the internal sphincter, as in the fetal specimens, a much larger proportion of the space was occupied by fibrous tissue, with variable amounts of smooth muscle fibres interspersed between the fibrous strands (Fig 4.1f). Very little smooth muscle was seen in the adult specimens particularly in those over the age of 60.



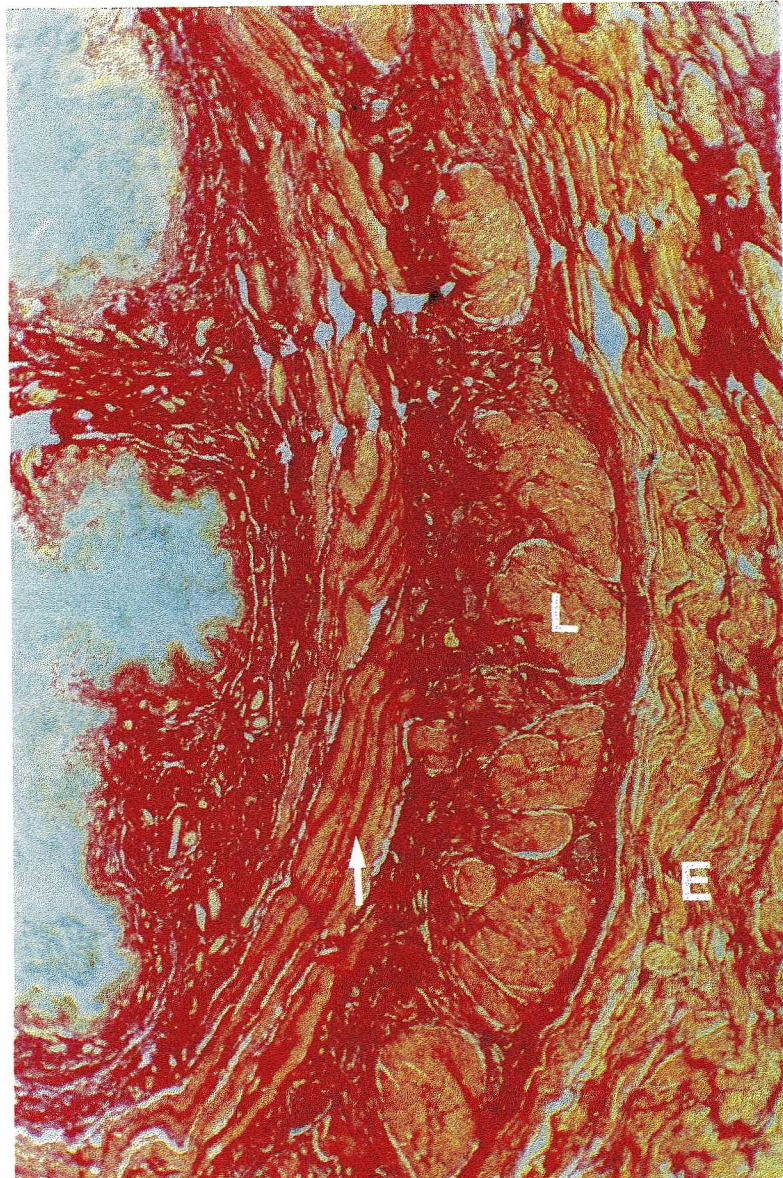
**Figure 4.1g** Longitudinal section through the upper anal canal of a 22 week male foetus showing the intersphincteric space filled predominantly by the continuation of the longitudinal smooth muscle layer (L) of the rectum. Connective tissue (bright pink) can be seen on either side of the longitudinal muscle, separating it from the circular smooth muscle of the internal sphincter (i) medially and striated muscle laterally (E). van Gieson, x50.



**Figure 4.1h** Longitudinal section through the upper anal canal of a 26 week female foetus demonstrating the distal continuation of puborectalis (Pr) running between the longitudinal muscle (L) medially and external sphincter (E) laterally. (van Gieson, x50).



**Figure 4.1i** Transverse section through the mid-anal canal of a 4 month male infant. Connective tissue enmeshes the subepithelium (a), internal sphincter (i), longitudinal muscle (L) and external sphincter (E). (van Gieson x4).

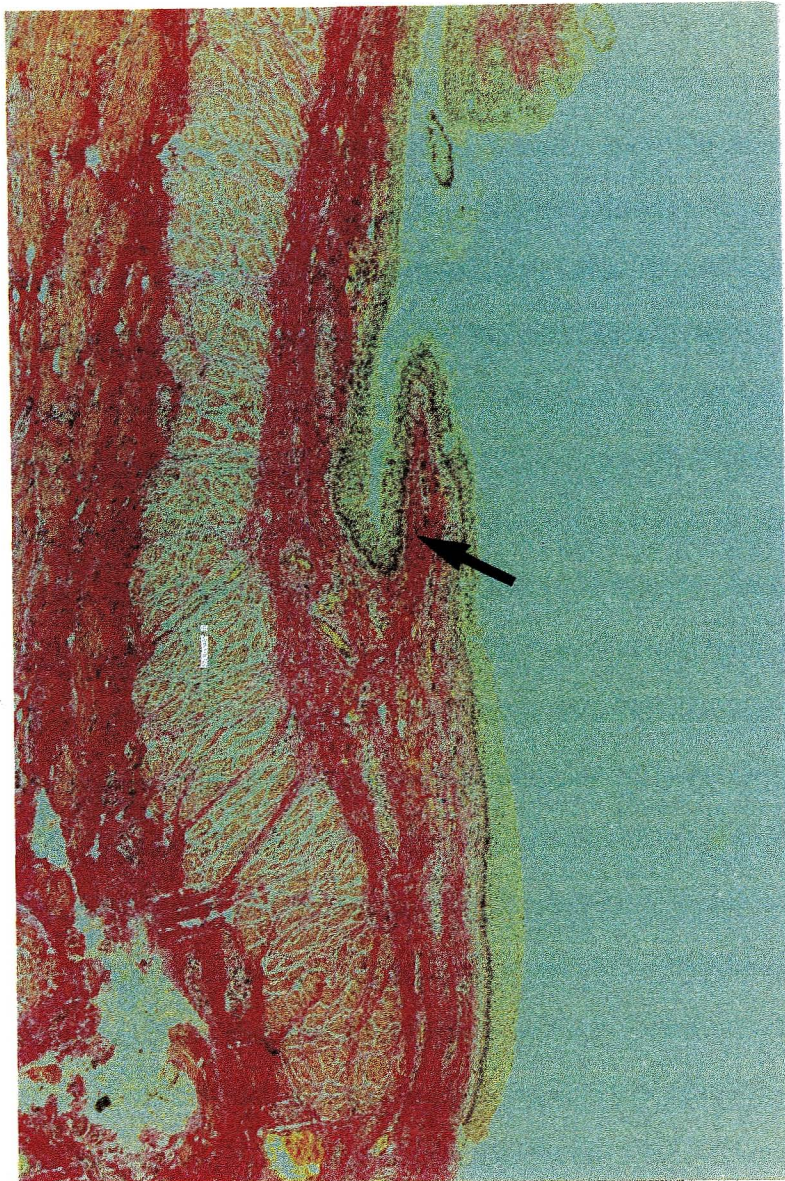


**Figure 4.1j** The same section as Figure 4.1i at higher magnification (x 10). The longitudinal muscle (L) is clearly seen as bundles enclosed within a connective tissue framework. Connective tissue is seen crossing the internal sphincter in an oblique direction (arrow). The connective tissue is thicker on the medial aspect of the intersphincteric space than on the lateral aspect, beyond which lies the external sphincter (E).

### Medial Extensions

The foetal internal sphincter was less well developed than in adult specimens, but was encapsulated by connective tissue which ran cranio-caudally in the deep submucosa medially, and medial to the longitudinal muscle laterally; connective tissue strands from this capsule crossed the circular muscle in an infero-medial direction in the upper canal, and in a medial or supero-medial direction in its lowermost part (Fig 4.1k). In no specimen were smooth muscle fibres derived from the longitudinal muscle layer seen to cross the internal sphincter: only connective tissue, derived from the medial aspect of the intersphincteric space traversed the muscle, grouping fibres into bundles in a similar manner to the longitudinal muscle in transverse section. In transverse sections, the connective tissue traversed the circular obliquely (Fig 4.1i).

The connective tissue of the medial intersphincteric space was continuous around the lower border of the internal sphincter with the connective tissue of the submucosa. In two specimens, submucosal connective tissue fibres were seen running medially (away from the cranio-caudal direction of the main connective tissue mass) from the medial border of the internal sphincter capsule towards the crypts to attach to the mucosa in the region of the dentate line (Figure 4.1j). This extension was named by Parks (1954) as "the mucosal suspensory ligament".




**Figure 4.1k** Longitudinal section through the mid anal canal of 26 week female foetus demonstrating the orientation of connective tissue fibres crossing the internal sphincter (i). The mucosal suspensory ligament of Parks (arrowed) appears to support the mucosa at the anal crypt. (van Gieson x50).

No structure was sufficiently pronounced to be separately identifiable as the "anal intermuscular septum", described by Milligan and Morgan (1934) as a thickened band of connective tissue separating the inferior border of the internal sphincter from the most medial part of the subcutaneous external sphincter and inserting into the mucosa to create the intersphincteric groove.

The adult arrangement of the internal sphincter and its traversing connective tissue fibres was similar to that seen in the foetal specimens; no smooth muscle derived from the intersphincteric space was seen crossing the circular muscle.

#### **Lateral and Terminal Extensions**

The foetal external anal sphincter was not as well developed as in adults. Connective tissue extensions from the distal aspect of the intersphincteric space appeared to subdivide the superficial external sphincter into a number of components, akin to the subcutaneous external sphincter of adults (Fig 4.1L). Histologically there was no distinguishing feature between the superficial and deep external sphincter.



**Figure 4.1L** Longitudinal section through the distal anal canal of a 46 year old male demonstrating the terminal inferior ramifications from the distal intersphincteric space (arrowed) separating the bundles of the subcutaneous external sphincter. (van Gieson x3).

## Discussion

Dissection of the fresh cadaveric specimens revealed findings similar to those observed during post anal repair or intersphincteric excision of the rectum: the need for sharp dissection to divide the inferior extensions which surround the bundles of subcutaneous external sphincter in order to gain access to the intersphincteric plane; the variable adherence of adjacent structures around the circumference; and the relative ease of separating internal and external sphincters if the (surgically correct) plane between longitudinal muscle and external sphincter, rather than that between internal sphincter and longitudinal muscle, is developed. The histological study has confirmed the anatomical prominence of the connective tissue ramifications derived from the intersphincteric space. In the fetal upper anal canal, in longitudinal section, the connective tissue within the space appeared to be confined to either aspect of the longitudinal muscle proper and lateral to the downward prolongation of puborectalis fibres, medial to the external sphincter, in a way similar to that described by Shafik (1976). Transverse sections reveal, however, that the connective tissue component is equally prominent between the bundles of longitudinal muscle fibres. Distally the striated muscle within the space is replaced by connective tissue, just as the smooth muscle is replaced by connective tissue with age.

This connective tissue forms a dense meshwork around the smooth muscle both in the intersphincteric space and in the circular muscle plane. The crossing of the internal sphincter by connective tissue fibres is not only oblique as seen on longitudinal sections, but also oblique circumferentially, which must give the internal sphincter a

spiral configuration rather than truly circular. The orientation of fibres in longitudinal section, inferomedially at the upper end of the internal sphincter and superomedially at its distal end means also that the axis of the spiral must change. Extrapolation of this anatomical arrangement to function means that contraction of the internal sphincter shortens the anal canal from both its proximal and distal ends.

The lowest portion of the external sphincter is similarly split up by downward extensions of this meshwork; the deeper components of the sphincter are also crossed by lateral extensions but these are less dense than inferiorly or medially and are also less constant. The presence of this meshwork which involves all parts of the sphincter complex would suggest that contraction of muscle fibres in one plane results in the transmission of forces across the whole width and length of the sphincter.

The inconsistent identification of well defined fibrous subdivisions of the external sphincter particularly between the subcutaneous and superficial external sphincter may explain the discrepancy in descriptions of external sphincter anatomy (Table II). The lack of any obvious histological differences between the subcomponents of the external sphincter when identified would suggest that these subdivisions are of little importance. Furthermore, anatomical subdivisions are virtually indistinguishable during surgery and therefore has little relevance. However functionally and also in terms of clinical imaging the anatomical arrangement of the external sphincter may be important and this is discussed in Sections 2.2.2, 4.3, 4.4 and 4.5.

## SECTION 4.3

### VERIFICATION OF SONOGRAPHIC IMAGES OF THE ANAL SPHINCTER

#### 4.3.1 INTRODUCTION

Endosonography of the anal canal is a relatively new technique (Law and Bartram 1989) providing detailed images of sphincter defects (Law et al. 1990, Burnett et al. 1991a, Law et al. 1991, Cuesta et al 1992, Nielsen et al 1992) and anorectal sepsis, especially fistula-in-ano (Law et al 1989, Choen et al 1991).

Interpretation must depend on understanding the normal sonographic anatomy of the anal sphincters. This has been difficult to establish as initial attempts to correlate sonography with anatomical dissection (Law and Bartram 1989) proved technically unsatisfactory, and despite considerable research the gross anatomy of the anal sphincters remains controversial.

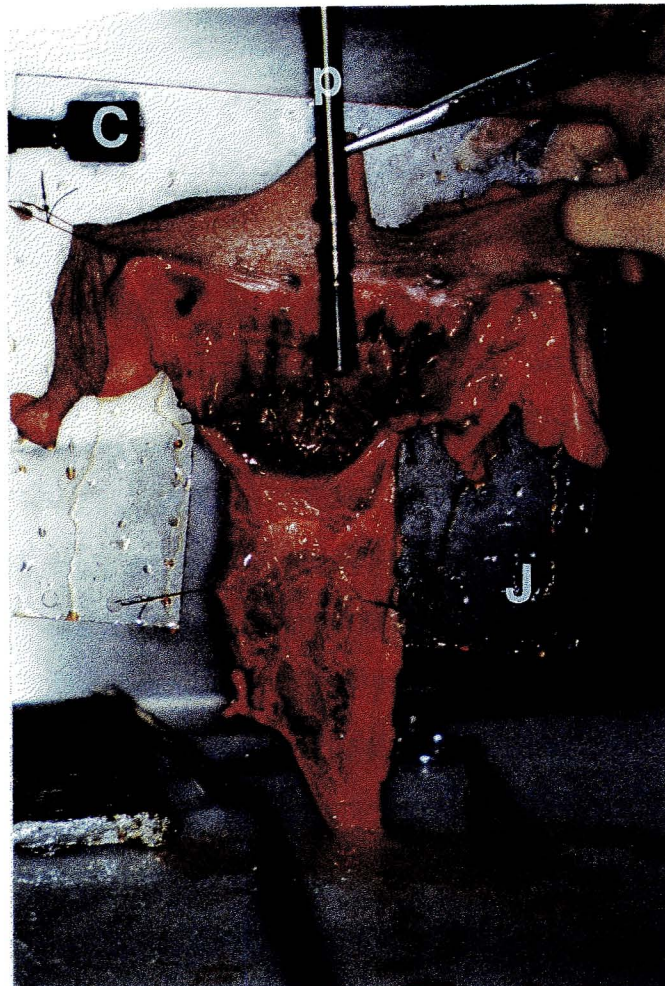
The purpose of this study was to define the sonographic anatomy of the anal canal musculature. Resected surgical and post mortem specimens were used to compare sonographic images with macroscopic dissection. This was combined with histological verification of the different layers. In addition, in vivo surgical dissection during routine anorectal operations was correlated with simultaneous intra-operative endosonography.

## 4.3.2 MATERIALS AND METHODS

### 4.3.2.1 Surgically resected and post mortem specimens:

Eight abdomino-perineal resections (4 female and 4 male; age range 46-87 years) and 6 fresh post mortem specimens (3 female and 3 males; age range 64-89 years) were examined. In-vitro scanning (Brüel & Kjær 7 MHz probe described in Section 1) was performed in a water-bath for acoustic coupling, using a modification of the technique described by Beynon et al (1986a). The intact specimens were first scanned in a water-bath. Four of the surgical and two of the post-mortem specimens were scanned after the anal canal had been opened posteriorly and mounted onto a jig (Fig 4.2a). This was made of plastic, measuring 20 x 20 cm, with a 10 x 10 cm section cut out from one side, creating a "U" shaped former. The specimens were sutured to this via small holes drilled in the plastic. The jig was clamped upright in a water bath with a second clamp used to hold the ultrasound probe close to the specimen (Fig 4.2a).

The echogenic pattern produced by the different layers of the anal canal was determined by scanning after dissection and removal of each layer in sequence; starting with the mucosa and muscularis submucosae ani, the internal anal sphincter, the longitudinal muscle layer and then the external anal sphincter. A biopsy of each layer was taken for histological confirmation. Three of the surgical specimens had been scanned in vivo prior to abdomino-perineal resection. These and one post-mortem specimen were scanned in the water-bath without dividing the anal canal posteriorly. Transverse sections were taken at serial levels along the anal canal to compare histological appearances to corresponding sonographic images.



**Figure 4.2a** In vitro underwater scanning of opened anorectal specimen

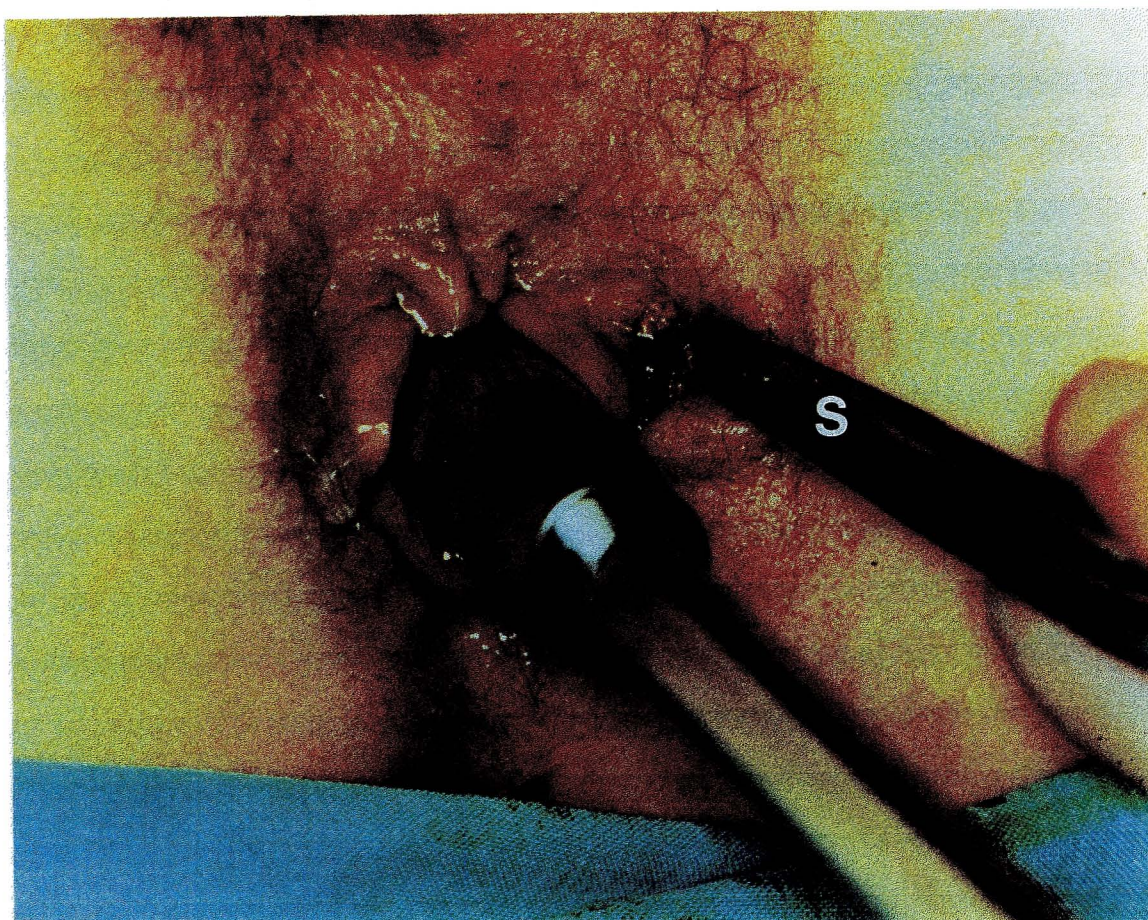
The specimen has been opened anteriorly and fixed on to a plastic jig (J). The jig is clamped (C) upright with the ultrasound probe held 2 cm away from the specimen. Scanning is performed with the probe (P) and specimen immersed in water.

#### 4.3.2.2 Intra-operative studies:

Anal endosonography was performed in 12 patients (7 male, 5 female, age range 32-58 years) undergoing surgery for haemorrhoids (4), fissures (4), sphincter repair (3) and recto-vaginal fistula repair (1). The entire probe was sterilized, to allow handling during surgery without risk of contamination.

Following the skin incision, the lower border of the external sphincter was identified, and its lower lateral aspect within the ischioanal (ischioanal) fossa dissected proximally for a short distance. The probe was then inserted and a stable image of the canal obtained. A pair of flat scissors was placed on the lateral border of the external sphincter (Fig 4.2b) and the image recorded, using the acoustic reflection from the scissors for localization. The procedure was repeated for the medial aspect of the external sphincter and the outer border of the internal sphincter.

The thickness of individual muscle layers was not measured as there were too many variables in the nature of specimens and examination conditions to ensure consistency of muscle tone.



**Figure 4.2b** In vivo scanning performed intra-operatively.

This patient undergoing a lateral anal sphincterotomy under general anaesthesia is lying in the lithotomy position. The tip of the scissors (S) has been inserted lateral to the internal anal sphincter with simultaneous anal endosonography.

### 4.3.3 RESULTS

#### 4.3.3.1 Resected specimens:

The dissected layers namely, the subepithelial tissues, internal sphincter, longitudinal muscle, external sphincter and ischioanal fat, were confirmed histologically. The histological appearance of a cross section of the mid-anal canal is shown in Fig 4.3a. Sonographically bright reflections were seen from interfaces either side of the plastic cone, creating a well defined hyperechoic double ring (Fig 4.3b). The sonographic patterns produced by the different anatomical layers in both the opened and intact specimens were as follows (Table III; Fig 4.3b), starting from the mucosa and working outwards:-

**Table III Sonographic echogenicity of the different layers of the anal sphincter complex.**

<b>LAYER</b>	<b>ECHOGENICITY</b>
Subepithelial	hyperechoic
Internal anal sphincter	hypoechoic
Longitudinal muscle	hyperechoic
External anal sphincter	hyperechoic / mixed
Ischioanal fat	striated inhomogeneous

1. An inner hyperechoic layer which represented the mucosa and subepithelial tissues (Fig 4.3b).
2. Outside the subepithelial tissues there was a well-defined, uniform, hypoechoic ring which corresponded to the internal sphincter (Fig 4.3b, 4.4a).
3. Surrounding the internal sphincter was a hyperechoic layer, which was thicker than the internal sphincter, and represented the longitudinal muscle and external sphincter (Fig 4.3b, 4.4b)

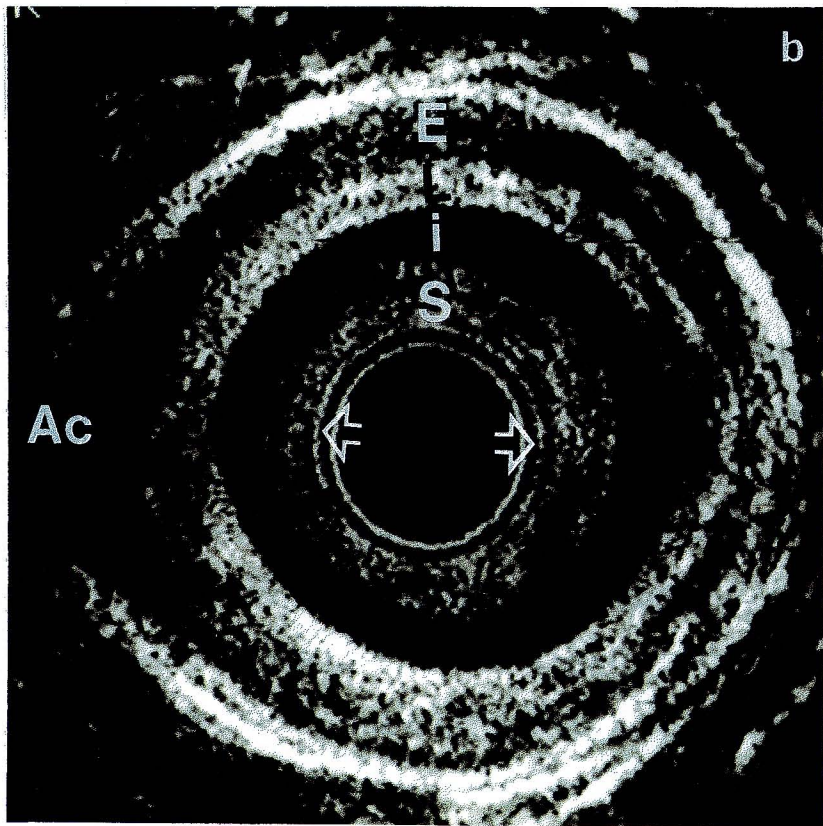
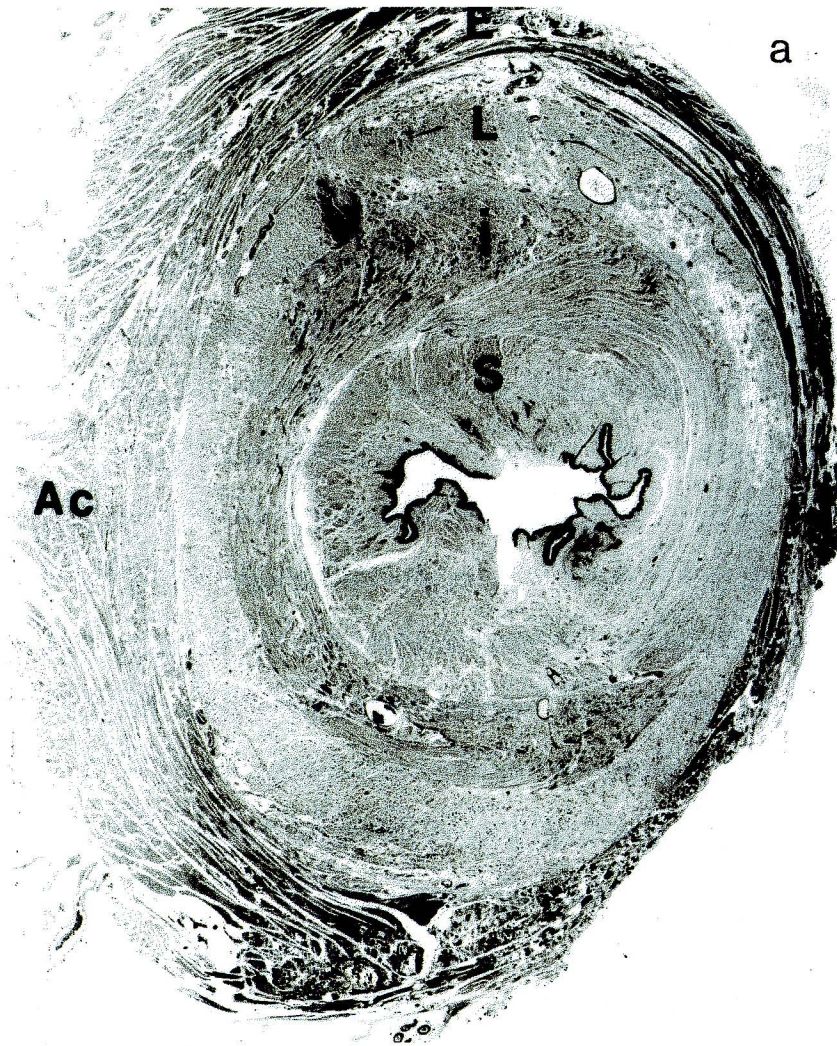
The female in vitro specimens studied were from elderly subjects. The longitudinal muscle was macroscopically a rather thin fibrous layer closely adherent to external sphincter (Fig 4.4c) and on ultrasound similarly hyperechoic. Removal of the longitudinal muscle layer made no discernible difference to the echogenicity of the external sphincter layer. In male specimens, the longitudinal muscle layer was thicker though of similar echogenicity.

4. The external sphincter in male specimens was however, hypoechoic relative to the longitudinal muscle, so that these two layers could be easily distinguished sonographically (Fig 4.4d). During dissection of these specimens, many of external sphincter muscle fibres were observed to run obliquely, a feature not seen in the thinner female specimens dissected. To establish if this made any difference to the sonographic appearance of the muscle, a segment of the external sphincter was

dissected and aligned such that its fibres were orientated to lie parallel to the ultrasound beam (Fig 4.4e). Compared to Fig 4.4b, it can be seen that the difference in echogenicity between the longitudinal muscle and the external sphincter disappears and both layers appear hyperechoic.

During in vitro water bath dissection the longitudinal muscle was identified sonographically as a separate layer in 6 of 7 males but in none of the females, although its presence was confirmed histologically.

5. Outside the external sphincter irregular linear reflections were seen from the fibrous septa within the adipose tissue of the ischioanal fossa (Fig 4.3b, 4.4b).



Figures 4.3 a & b

**Figure 4.3a** represents a cross-section through the mid anal canal in a male. Anterior (Ant) is to the right of the picture.

S = muscularis submucosae ani (subepithelium); E = External anal sphincter; L = longitudinal muscle; i = internal anal sphincter; Ac = anococcygeal ligament; The fatty layer peripheral to the external sphincter has disintegrated during preparation of the slide.

**Figure 4.3b** is the anal endosonographic image at the corresponding level. The arrows indicate the reflections of the probe cone which appears as a double ring.

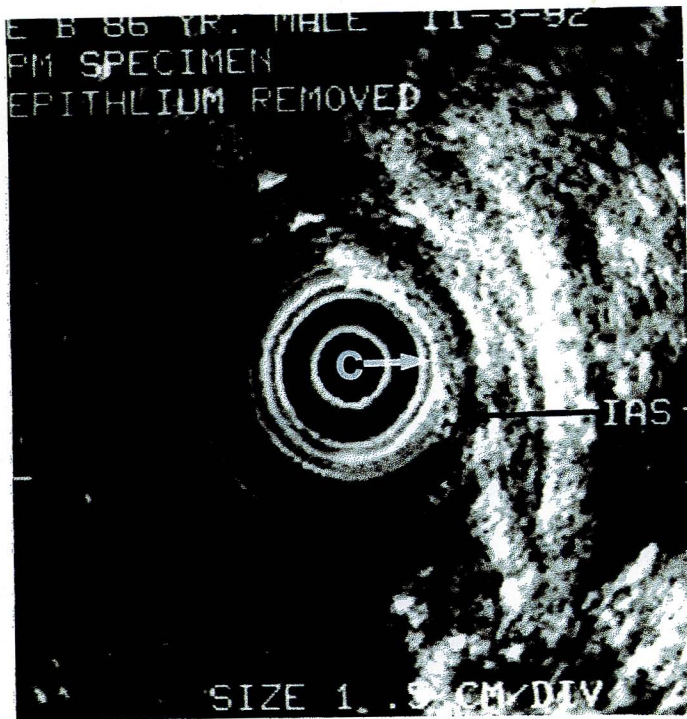


Figure 4.4a

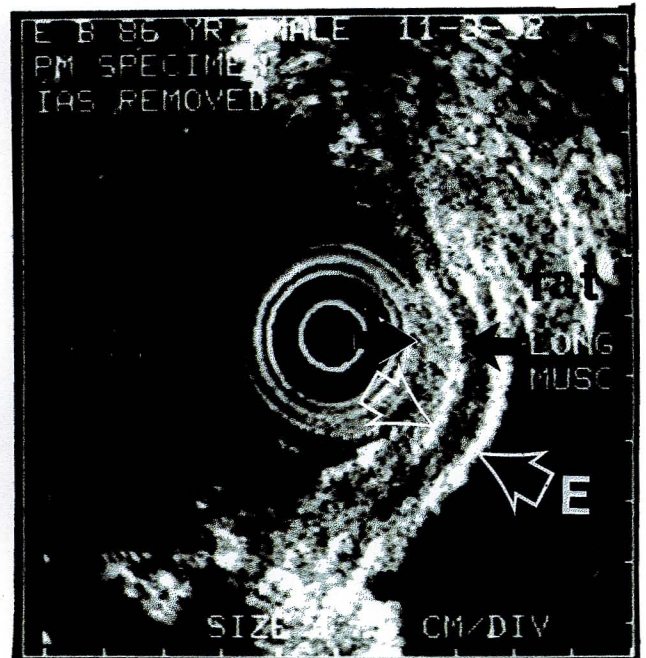
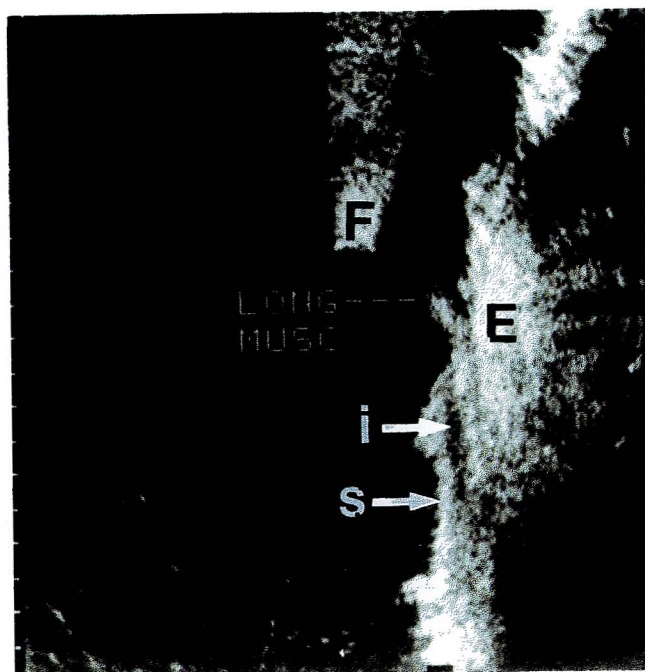


Figure 4.4b

**Figs 4.4a & b. In vitro sonographic image of the opened anal canal in a male specimen**

In Fig 4.4a the epithelial and subepithelial layer has been removed. The bright double ring is the reflection of the cone probe (C). The internal sphincter (IAS) appears hypoechoic (black).

In Fig 4.4b The internal sphincter has been removed, and the probe is closely applied to the longitudinal muscle (between closed arrows). In this specimen the hyperechoic longitudinal muscle layer is clearly distinguishable from the relatively hypoechoic external sphincter (E, between open arrows). Peripheral to the external sphincter is the fat layer.



**Figure 4.4c** In vitro sonographic image of the opened anal canal from an elderly female.

The longitudinal muscle (LONG MUSC) is held elevated by forceps (F) from the external sphincter muscle layer (E). Note that both layers are of similar echogenicity, in contrast to the hypoechoic external sphincter in Figure 4.4b. The internal sphincter (i) is hypoechoic and the subepithelium (s) is hyperechoic.

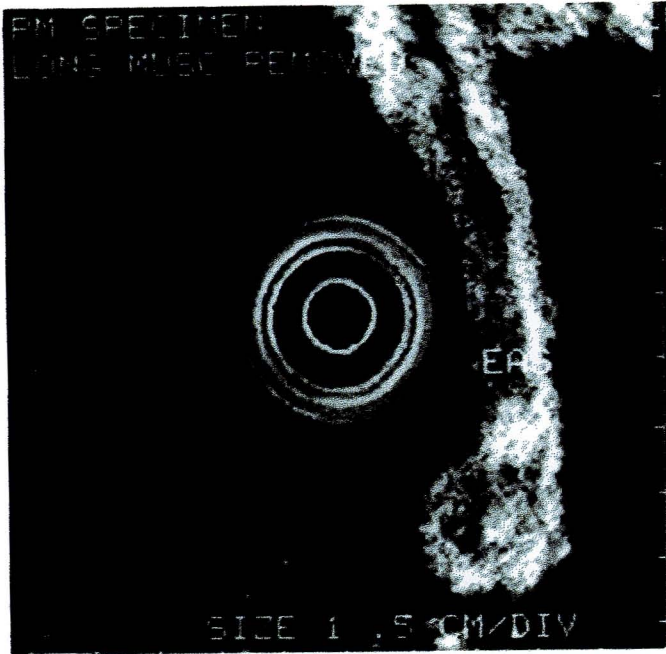

Figure 4.4d

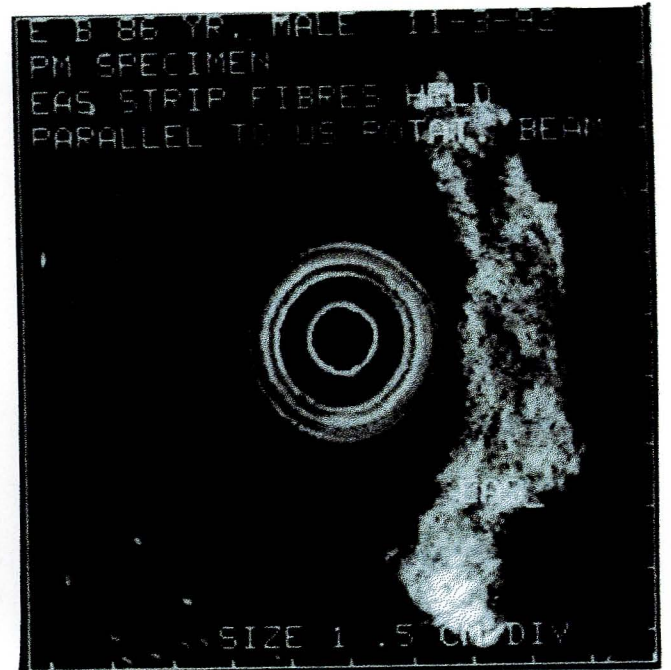


Figure 4.4e

**Figures 4.4d & e. In vitro sonographic image of the opened anal canal in a male specimen**

In Fig 4d the epithelial, internal sphincter, longitudinal muscle layer and fatty layer has been removed. The external sphincter (EAS) is not in contact with the probe but as in Fig 4b appears relatively hypoechoic. Macroscopically the external sphincter muscle fibres in this male specimen are running in an oblique fashion (see text). Note the change in echogenicity in Fig 4e when the specimen in Fig 4d is rotated such that the external sphincter fibres lie parallel to the ultrasound beam. The external sphincter can no longer be distinguished from the longitudinal muscle layer suggesting that a change in the orientation of muscle fibres in relation to the ultrasound beam may account for differences noted in the echogenic pattern of the external sphincter.

#### 4.3.3.2 Intra-operative studies:

The reverberation echo from the flat scissors was clearly visible in every patient. These in vivo studies confirmed the in vitro findings described above. In six of seven men the external sphincter was hypoechoic (Figs 4.5a-e). Dissection of the intersphincteric space and insertion of the scissors for a very short distance confirmed that the outer hypoechoic ring was the external sphincter, and that the inner hyperechoic ring was due to the longitudinal muscle (Figs 4.5c,d). In four of five women the external sphincter appeared hyperechoic (Fig 4.5e). The internal sphincter was hypoechoic in all twelve patients.

As with the in vitro studies, four layers of varying echogenicity were identified. During the in vivo operative dissection studies the longitudinal muscle layer was identified sonographically in 6 of 7 men, and 1 of 5 women. As with the dissection specimens the longitudinal muscle was identified only when the external sphincter was relatively hypoechoic. Where the external sphincter was hyperechoic, it was impossible to distinguish the layers.

The perineal body was not identified as a distinct sonographic structure in either in vitro or in vivo studies.

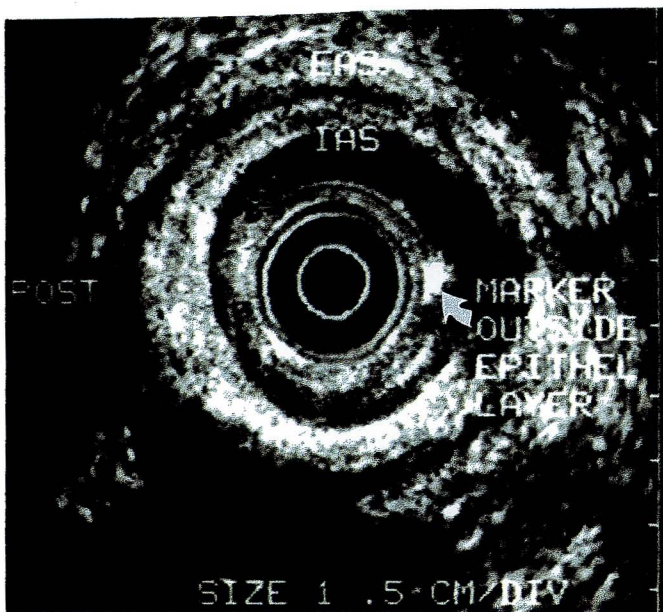


Figure 4.5a

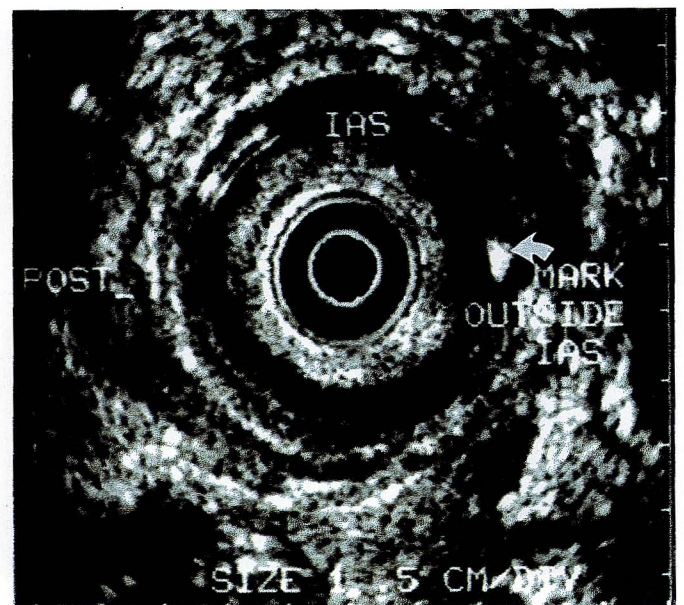


Figure 4.5b

Figures 4.5 a & b. In vivo (intra-operative) sonographic images.

In Fig 4.5a the scissors tip (arrow) has been placed lateral to the hyperechoic subepithelium. The internal sphincter (IAS) appears hypoechoic (black).

In Fig 4.5b the scissors tip (arrow) has been placed lateral to the IAS margin.

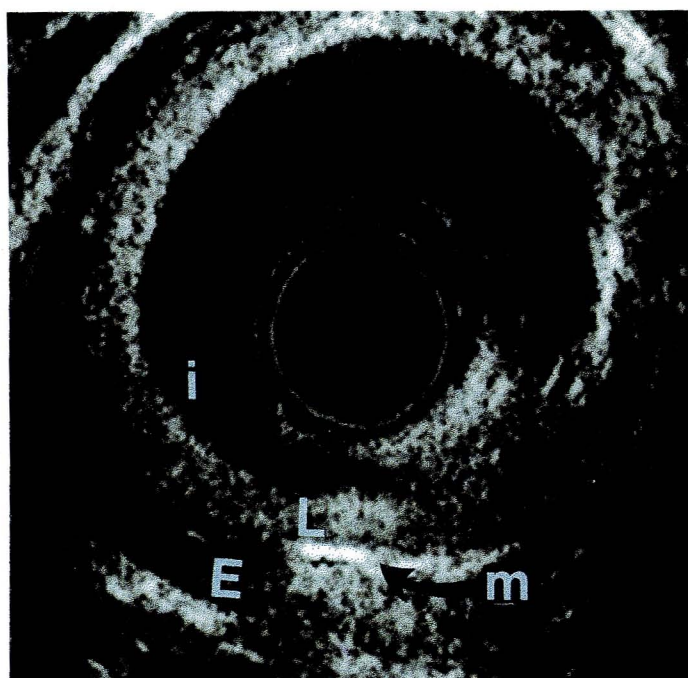

Figure 4.5c

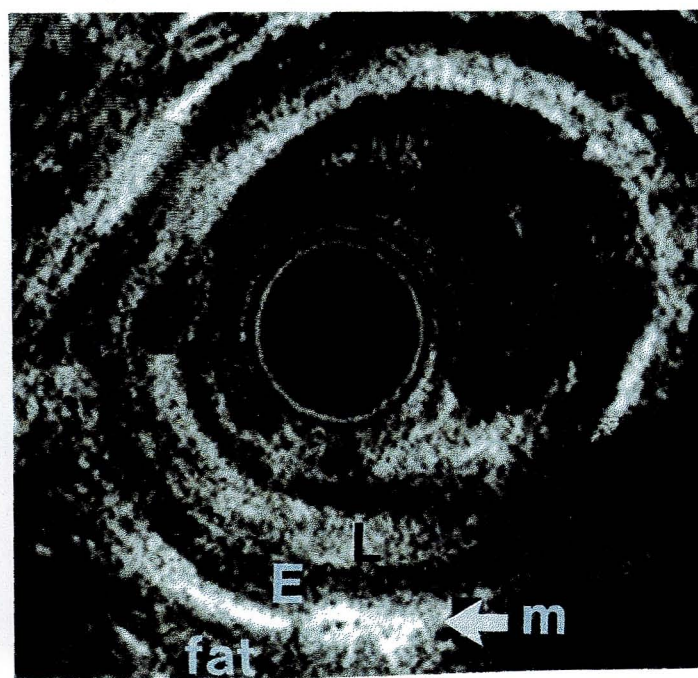
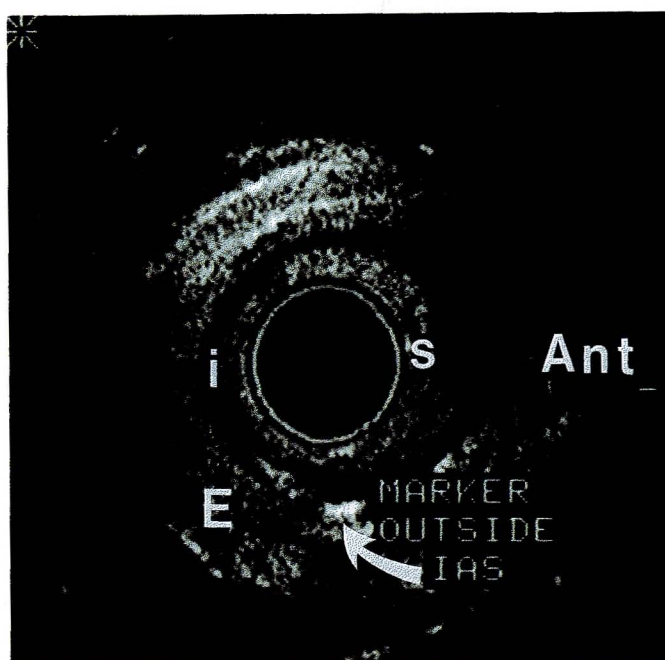


Figure 4.5d

**Figures 4.5 c & d. In vivo (intra-operative) sonographic images.**

In Fig 4.5c the reflection (m) from the scissors placed on the inner aspect of the external sphincter, shows that the hyperechoic longitudinal muscle (L) lies medially and the hypoechoic external sphincter (E) laterally. Internal sphincter (i).

In Fig 4.5d the scissors have now been placed on the outer border of the external sphincter demarcating the external sphincter/fat interface.



**Figure 4.5e** Intra-operative scanning of a female patient

Ant = anterior. (s) subepithelium. The arrow points to the reflection of the scissors tip on the lateral border of the internal anal sphincter (i). The longitudinal muscle layer in this patient is of similar echogenicity to the surrounding external sphincter (E) and is not distinguishable from it.

#### 4.3.4 DISCUSSION

This is the first study to validate the interpretation of anal endosonographic images by in vitro and in vivo dissection and with confirmatory histological evidence.

There is no muscularis mucosae in the anal canal to separate mucosa from submucosa, hence the term "subepithelial" to describe these tissues. Anatomical dissection has suggested (Fine et al. 1940) that there is continuity between the muscularis mucosae of the rectum and superficial fibres of the subepithelial layer in the anal canal, and the term "muscularis submucosae ani" has been proposed. However as the term 'submucosa' is in common usage it would be retained throughout this thesis. The mucosa could not be separated from the muscularis submucosae by dissection and was not differentiated as layers endosonographically. Beynon et al. (1986a) were also unable to define the mucosal layer during rectal endosonography. The thickness and echogenic nature of this layer would appear to be below the resolution of the equipment used.

The subepithelial layer (Fig 4.3b, 4.4c) and internal sphincter (Fig 4.3b, 4.5b, 4.5e) demonstrated a consistent echogenicity. Smooth muscle is generally of low echogenicity and therefore the circular internal sphincter appears hypoechoic. In contrast, the longitudinal muscle was hyperechoic (Fig 4.3b, 4.5c), but this layer could only be defined sonographically when the external sphincter was relatively hypoechoic (Fig 4.3b, 4.5d,e). This was common in males, but in most of the females studied the external sphincter was hyperechoic merging inseparably with the longitudinal muscle

(Fig 4.4c, 4.5e). These differences in echogenicity could be accounted for by a change in direction of fibres as well as an increase in the fibrous stroma. A similar phenomenon has been demonstrated during ultrasonography of the Achilles tendon where a change in echogenicity occurs depending on the orientation of fibres in relation to the ultrasound beam (Fornage 1986). This is likely to explain the differences in the echogenicity of the external sphincter found in this study, particularly between the sexes. During dissections when the anal muscles were well developed, as frequently seen in male specimens, many of the circular fibres of the external sphincter adopted a more oblique course. This resulted in a change in echogenicity of the external sphincter and hence the hypoechoic appearance relative to the hyperechoic longitudinal muscle (Fig 4.4b,d). Confirmation of this phenomenon was demonstrated by changing the orientation of the dissected external sphincter layer in relation to the ultrasound beam (Fig 4.4d,e).

The original description of the endosonographic anatomy (Law and Bartram 1989) of the anal canal confused the intersphincteric space with the longitudinal muscle and the longitudinal muscle with the outer hypoechoic ring of the external sphincter. It is now recognised that the outer border of the external sphincter is clearly separated from the irregular striated appearance of the septa within the ischioanal fossae (Fig 4.3b).

A recent study (Nielson et al. 1991) of anal endosonography combined with simultaneous EMG studies confirmed the location of the external anal sphincter, although the longitudinal muscle was not defined. The sphincters have also been

imaged using magnetic resonance imaging (Aronson et al. 1990) and the overall appearance of the external sphincter confirmed. Although it was claimed that the longitudinal muscle layer was identified, measurements of the internal sphincter, the subepithelial and longitudinal muscle layers were combined and it is difficult to differentiate the inner layers from the illustrations.

It is evident from this study that a basic echogenic pattern of the anal canal layers has been defined, with some individual variation and sex difference in the echogenicity of the external sphincter. The inaccuracies in the original description of the sonographic anatomy (Law and Bartram 1989, Law et al. 1989) have now been rectified, and abnormalities may now be interpreted with greater precision and confidence.

## SECTION 4.4

### ENDOSONOGRAPHY OF THE ANAL SPHINCTERS: NORMAL ANATOMY AND COMPARISON WITH MANOMETRY

#### 4.4.1 INTRODUCTION

The external anal sphincter has been considered by some to be a single unit while others have subdivided it into two or three components (Section 4.1). The conjoint longitudinal muscle is also a complex structure (Lunniss and Phillips 1992), and its sonographic anatomy has been defined for the first time in Section 4.3.

The endosonographic anatomy of the anal sphincters has been validated and clarified (Section 4.3) since the original description (Law and Bartram 1989), but there has been only limited quantification of the endosonographic findings in normals, and of the relationship of sonographic to manometric findings (Nielsen et al 1992a). The aim of this study was to illustrate the normal in vivo sonographic anatomy in both the male and female, to identify gender differences and to relate muscle thickness to anal pressure measurements.

#### 4.4.2 SUBJECTS AND METHODS

One hundred and fourteen healthy volunteers, comprising 93 females of reproductive age without previous vaginal delivery (median age 27 years, range 18-41) and 21 males

(median age 35 years, range 22-67) were studied. None had previous anorectal disease or abnormal bowel habit. Forty females and 13 males were white, 50 females and 6 males black, and the remaining 6 belonged to other racial groups. The mean weight of the male subjects was 73 kg (range 65-90) and that of the female subjects 65 kg (range 45-105).

#### **4.4.2.1 Anal endosonography (described in Section 1.4.2)**

As the Bruel & Kjaer 7 MHz probe was withdrawn down the anal canal, images of the puborectalis muscle, external anal sphincter, internal anal sphincter, longitudinal muscle, superficial transverse perineal muscle and ischiocavernosus muscles were recorded. The presence of other structures, such the central point of perineum and the anococcygeal ligament were also documented. Prints were made of the images at 4 levels (Fig 4.6a) and the thicknesses of the puborectalis, longitudinal muscle, internal and external anal sphincter measured in the mid-coronal plane on both sides using a vernier calliper with 0.1 mm increments. The external sphincter measurements were made from the outer border of the internal sphincter to the outer edge of the external sphincter and included the longitudinal muscle, as in many females these structures could not be separated sonographically. The longitudinal muscle was also measured only when identified separately.

#### **4.4.2.2 Anal Manometry**

The Stryker 295 air-filled microballoon system is described in Section 2.2.2.4

#### **4.4.2.3 Statistical Analysis (described in section 3)**

Muscle thickness measurements are presented as the mean and standard deviation. The difference between males and females was compared with the two sample t-test. Linear regression analysis was performed to correlate sets of continuous data.

### **4.4.3 RESULTS**

#### **4.4.3.1 Anal endosonographic anatomy**

The subepithelial tissues and internal sphincter were clearly defined in all patients. The longitudinal muscle was hyperechoic relative to the external sphincter in all males, and so identifiable as a separate structure. The same applied to 37/93 (40%) of females, but in the remainder the longitudinal muscle and external sphincter were of similar echogenicity and therefore indistinguishable. The differences in morphology of the external sphincter are listed in Table IV. The frequency with which related structures, such as the superficial transverse perineal muscle, central point of the perineum and anococcygeal ligament, were visualized is given in Table V. Measurements of the muscle thicknesses is given in Table VI.

**TABLE IV Differences in the endosonographic morphology of the external anal sphincter between males and females.**

	<b>FEMALES (n=93)</b>	<b>MALES (n=21)</b>
<b>External anal sphincter (EAS) shape</b>		
<u>Deep (proximal) EAS</u>		
annular	67 (72%)	16 (76%)
conical	26 (28%)	5 (24%)
<u>Superficial (mid) EAS</u>		
annular	22 (24%)	3 (14%)
elliptical	68 (76%)	18 (86%)
<u>Subcutaneous (distal) EAS</u>		
annular	41 (44%)	9 (43%)
conical	52 (56%)	12 (57%)
<b>Deep EAS variant</b>	12 (13%)	3 (14%)

The superficial EAS could not be delineated in 3 females

**TABLE V** Differences in sonographic identification of structures other than the sphincter muscles in males and females.

	<b>FEMALES (n=93)</b>	<b>MALES (n=21)</b>
Longitudinal muscle	37 (40%)	21 (100%)
Superficial transverse perinei	35 (38%)	16 (76%)
Ischiocavernous muscle	0	9 (43%)
Central point of perineum	29 (31%)	13 (62%)
Anococcygeal ligament	46 (49%)	16 (76%)

**Table VI** Mean lateral anal muscle thicknesses in males and females

	<b>FEMALES (n=93)</b>	<b>MALES (n=21)</b>	<b>P values</b>	<b>95% CI of difference</b>
Puborectalis muscle	7.3 (1.4)	8.8 (1.3)	P=0.0001*	0.8 to 2.1
deep EAS	7.1 (1.3)	8.5 (1.2)	P=0.0001*	0.7 to 1.9
superficial EAS	7.1 (1.2)	7.8 (1.3)	P=0.03*	0.1 to 1.4
subcutaneous EAS	9.3 (1.6)	9.1 (1.3)	P=0.47	-0.4 to 0.9
mid IAS	1.8 (0.5)	1.9 (0.6)	P=0.34	-0.4 to 0.2
distal IAS	1.5 (0.4)	1.6 (0.6)	P=0.34	-0.4 to 0.2
Longitudinal muscle (maximum thickness)	2.5 (0.6)	2.9 (0.6)	P=0.06	-0.7 to 0.01

EAS = external anal sphincter; IAS = internal anal sphincter.

The measurements represent the mean (SD) muscle thicknesses of the right and left sides.

The superficial EAS was delineated in 90 females.

The longitudinal muscle layer was identified sonographically in all males but in only 37 females. The EAS measurements include the longitudinal muscle.

\* = statistically significant difference

The morphology of the external sphincter at the 4 levels was as follows:

(i) Puborectalis muscle

The puborectalis was seen consistently as a hyperechoic diverging "U" shaped muscle in all male and female patients (Fig 4.6b).

(ii) External anal sphincter (EAS)

The deep aspect of the EAS was in continuity with the puborectalis posteriorly in both sexes. The anterior part differed between males and females. In females, unlike males, the EAS is shorter anteriorly because postero-lateral muscle bundles slope infero-medially to unite anteriorly at a slightly lower level (Fig 4.6f). Therefore in females, the proximal deep external sphincter (level 2, Fig 4.6a) showed an apparent "anterior defect" (Fig 4.6g). This defect which was seen in all but one female disappeared with gradual withdrawal of the probe down the anal canal (Fig 4.6h). By contrast in males, the EAS was of the same length both anteriorly and posteriorly and hence no "defect" was seen (Figs 4.6f,i).

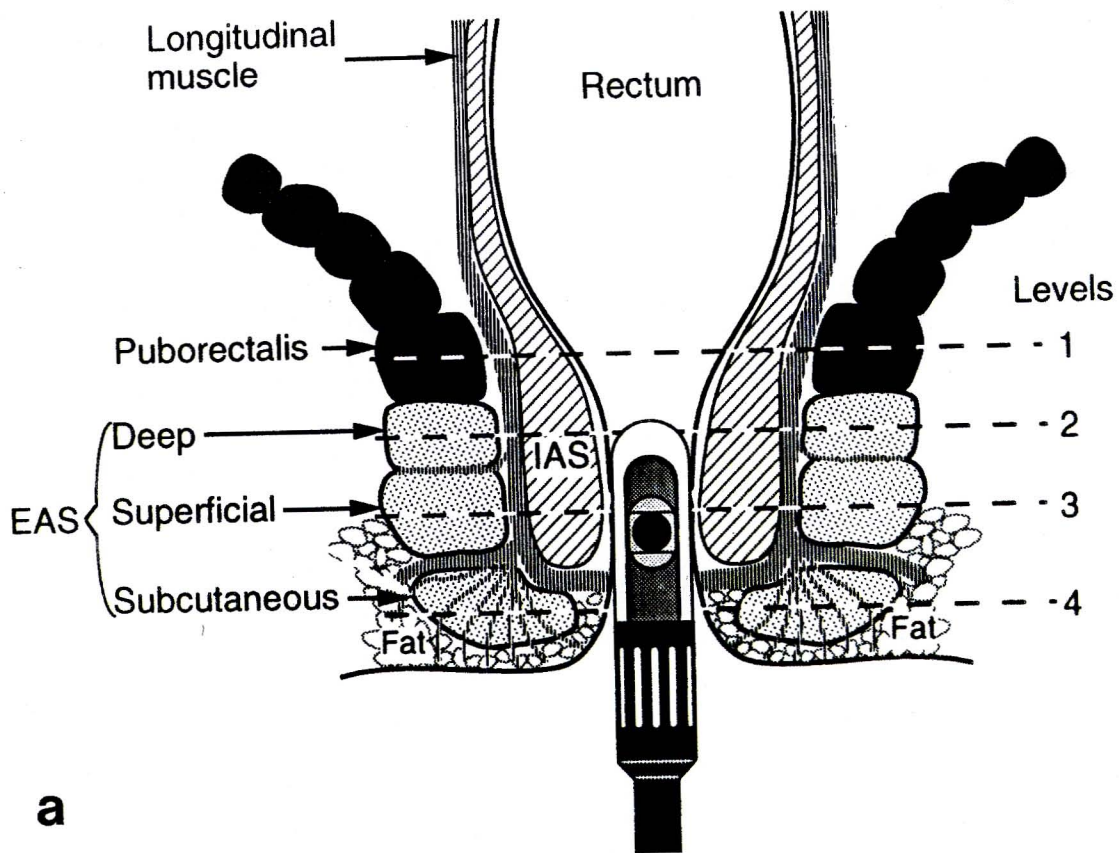
Overall the deep EAS was annular (Fig 4.6b,h,i 4.2L) in both sexes (Table IV), otherwise it was conical, tapering posteriorly to insert into the anococcygeal ligament.

The deep EAS merged into the superficial EAS without a clear demarcation on anal endosonography. In the majority of females and in all males the superficial EAS was elliptical (Table IV) (Figs 4.6d,j), attaching anteriorly to the perineal body and posteriorly into the anococcygeal ligament. In 3 females, the superficial EAS was very short anteriorly and merged directly into the subcutaneous EAS. In most subjects

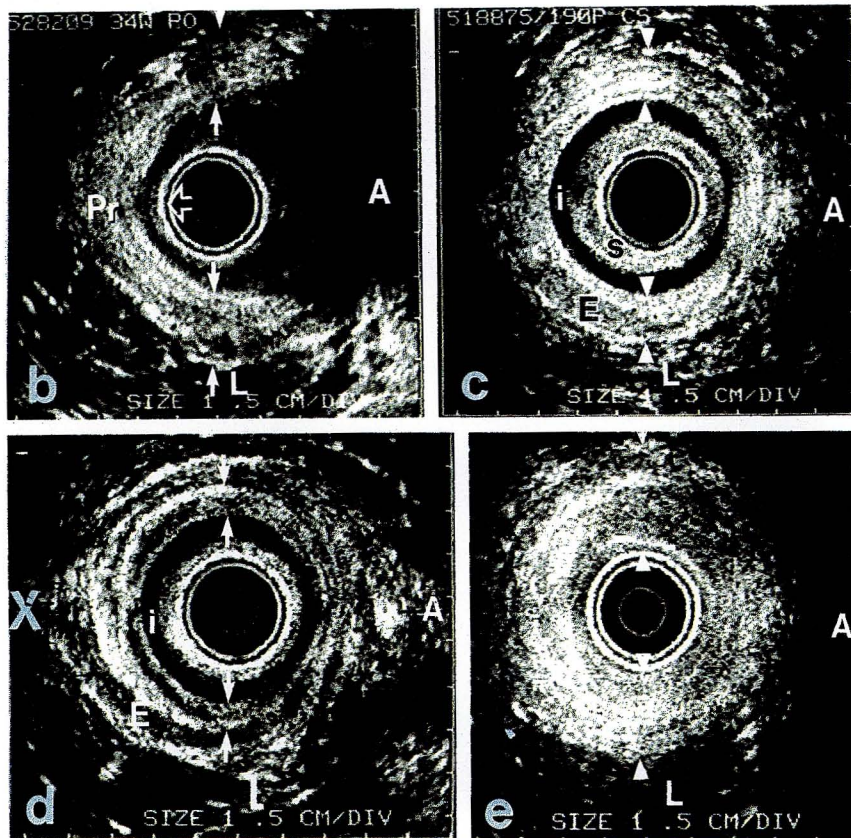
however it was possible to recognise the transition between the annular deep EAS and the more elliptical superficial EAS. The elliptical shape was more pronounced in male subjects (Fig 4.6j).

Compared to the deeper parts of the EAS, the subcutaneous EAS appeared more densely hyperechoic (Fig 4.6e), due to the increased reflections from the fibrous terminations of the conjoint longitudinal muscle (Fig 4.6a). It was more clearly delineated by ultrasound than the deeper components because its proximal margin began at the lower limit of the hypoechoic internal anal sphincter (Figs 4.6 a-e) and formed a concentric ring of muscle down to the anal verge. The subcutaneous EAS was conical (Fig 4.6k) with contributions to the anococcygeal ligament in 66% of females and 57% of males (Table IV), whilst in the remainder it was circular (Fig 4.6e,L).

The EAS was not always symmetrical. In 13% of females and 14% of males there was a muscle variant consisting of a bundle of the deep EAS merging anteriorly with the superficial transverse perineal muscle on the left (Fig 4.6m) to insert into ischial tuberosity. This change in direction of the EAS muscle fibres resulted in a change in echogenicity (Section 4.2) and the presence of hypoechoic area that could be misinterpreted as an EAS defect (Fig 4.6m).



a



Figures 4.6 a-e. Sites of measurement of anal sphincter muscle thicknesses.

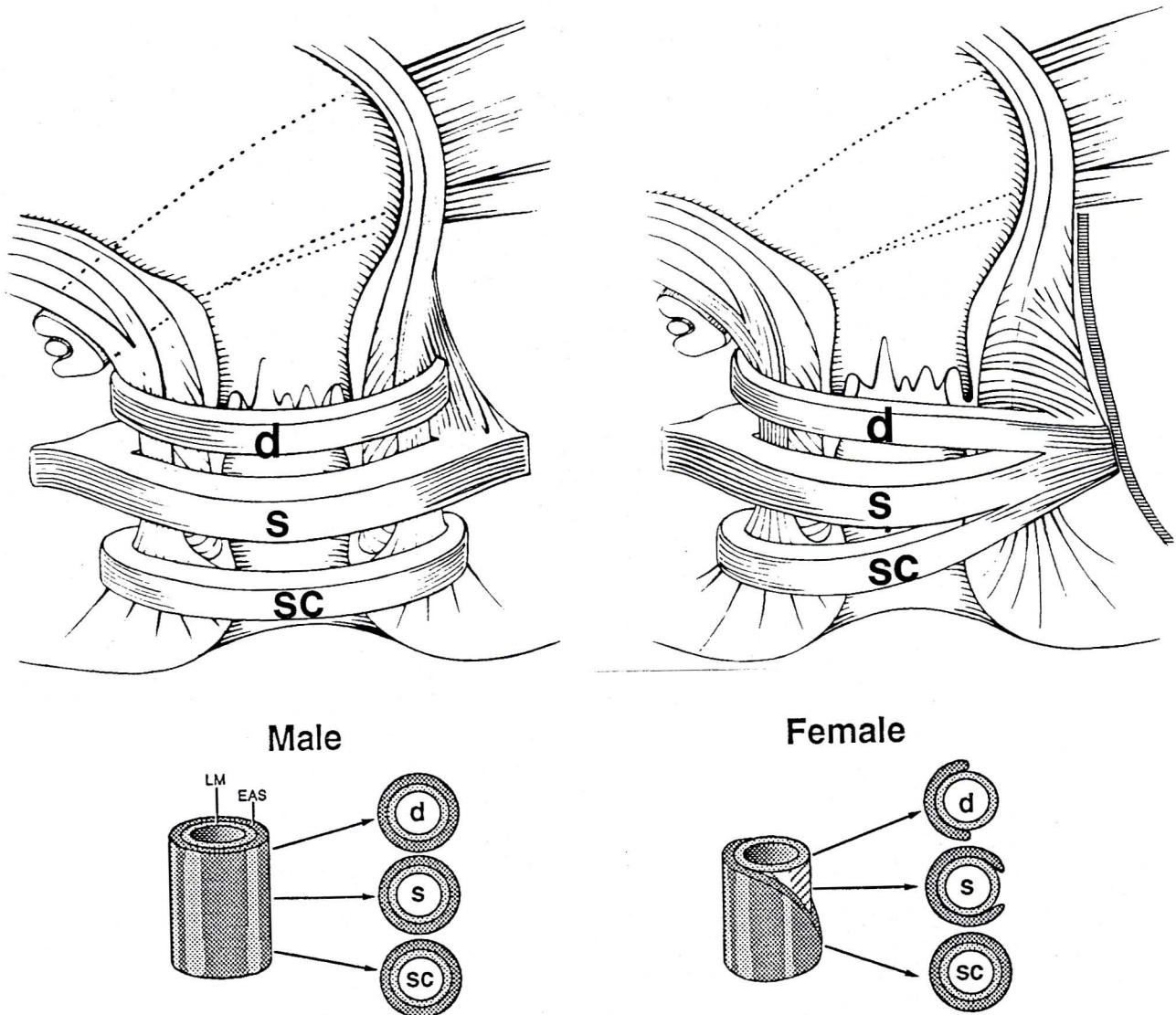
**Figures 4.6 a-e. Sites of measurement of anal sphincter muscle thicknesses.**

Fig 4.6a. Schematic representation of the anal canal with a probe in- situ illustrating the various levels at which measurements of muscle thicknesses were taken. Level 1 = puborectalis muscle (Pr); level 2 = deep (proximal) external anal sphincter (EAS); level 3 = superficial (mid) EAS; level 4 = subcutaneous (distal) EAS. Internal anal sphincter (IAS). The endosonographic images b-e correspond to Levels 1-4 respectively.

A = anterior; L = left; s = subepithelium; i = internal sphincter; E = external sphincter; X = anococcygeal ligament). All subsequent images are orientated and labelled similarly where necessary.

The bright double ring (open arrows) is the reflection of the probe cone. The closed arrows indicate the sites of measurement of muscle thickness (puborectalis in Fig 4.6b, the different components of the external sphincter in Figs 4.6c,e and the longitudinal muscle in Fig 4.6d). The internal sphincter measurements were taken in the same coronal plane adjacent to the arrows.

Note the change in configuration of the components of the external sphincter at the different levels from annular in Fig 4.6c to elliptical in Fig 4.6d to annular in Fig 4.6e



**Figure 4.6f Anatomical and sonographic gender variations.**

The top two figures demonstrate the anatomical layout of the 3 components of the EAS as described by Stelzner (1981): deep (d), superficial (s) and subcutaneous (sc). Anterior is to the right.

The two images at the bottom represent sonographic images at the respective levels. The apparent "defect" in the anterior EAS seen in the female is due to the shorter EAS demonstrated in the bottom right figure. LM = longitudinal muscle, Pr = puborectalis. The superficial EAS is just beginning to form a complete ring.

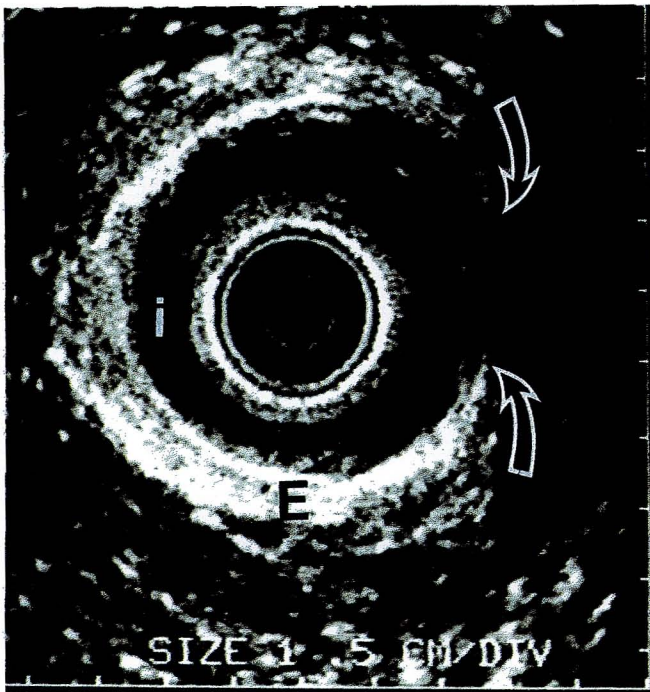


Figure 4.6g

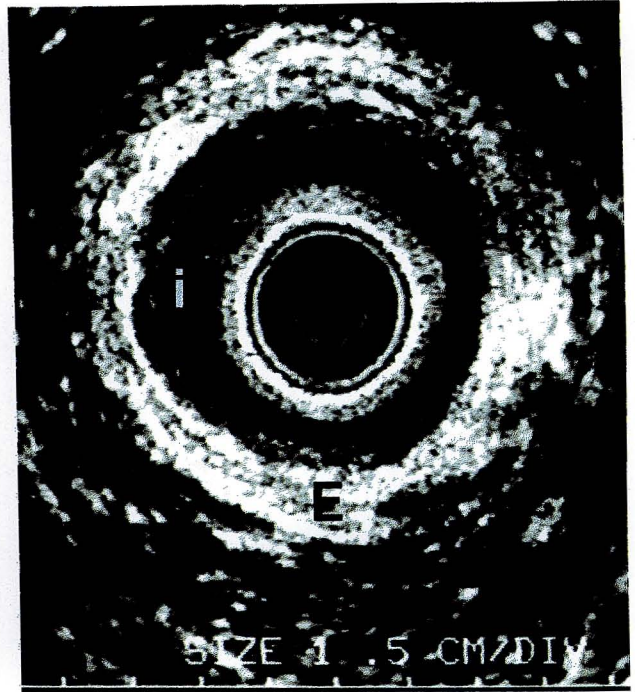

Figure 4.6h

**Figures 4.6g & h. Images of the deep external sphincter in a female.**

Fig 4.6g. The deep external anal sphincter (E) just above level 2 in Fig 4.6a. The internal anal sphincter (i) appears as a complete hypoechoic ring. The small anterior gap (open arrows) is due to the section cutting through the sloping external sphincter resulting in a shorter external sphincter anteriorly (see Fig 4.6f).

Fig 4.6h. The same woman as in Fig 4.6g but at a slightly lower level. The anterior ring of the external sphincter is now complete.

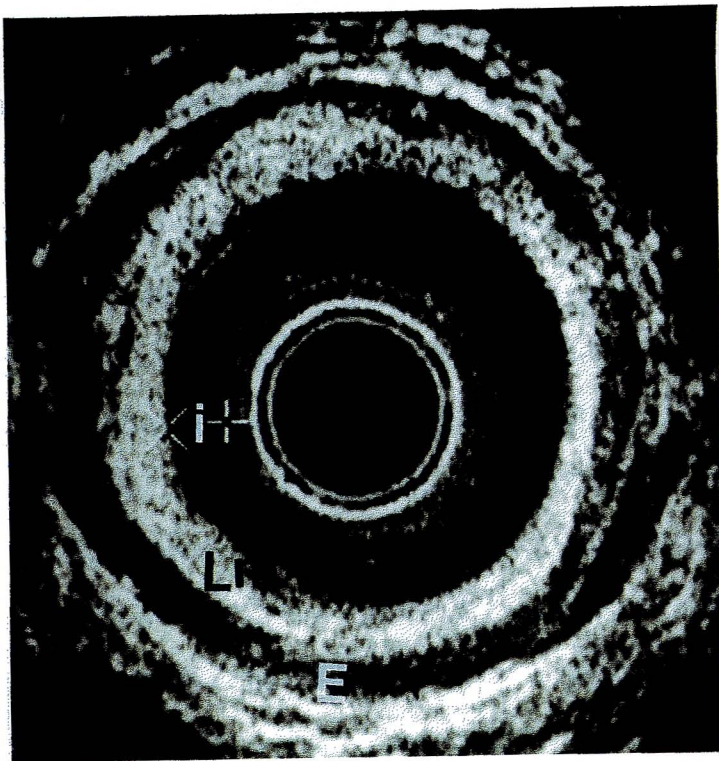


Figure 4.6i

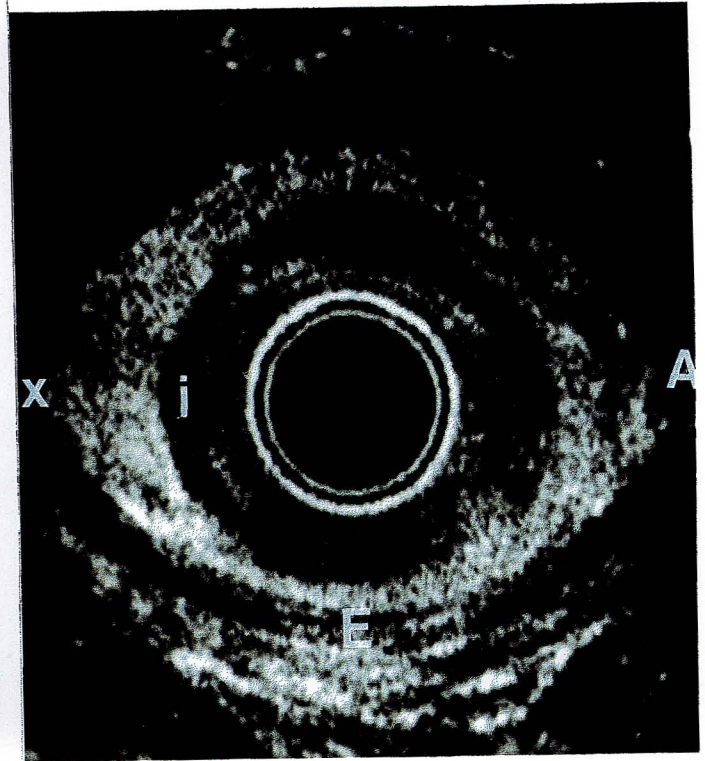

Figure 4.6j

**Figures 4.6i & j. Images of the deep and superficial external sphincter in a male.**

Images at levels and 2 and 3 representing the deep (Fig 4.6i) and superficial (Fig 4.6j) external sphincter in a male. Note the hyperechoic longitudinal muscle (Lm) encircling the internal sphincter (i) with its borders outlined by markers. The EAS (E) appears relatively hypoechoic.

Note the change from an annular deep EAS (Fig 4.6i) to the elliptical superficial EAS (Fig 4.6j). The ellipse is created by anterior (A) attachments to the perineal body and posteriorly to the anococcygeal ligament (X).

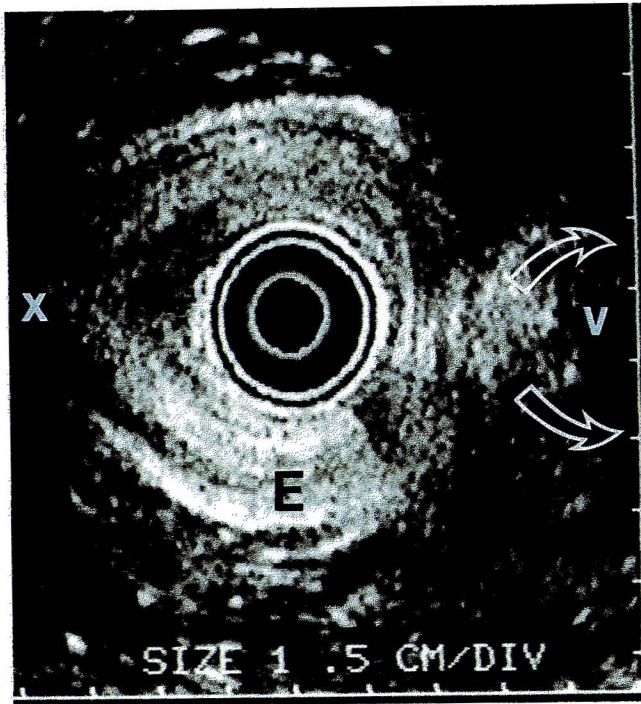


Figure 4.6k

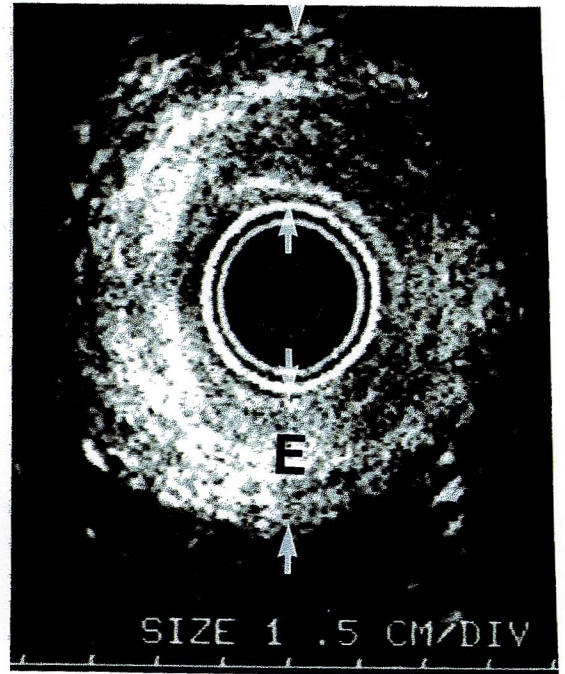
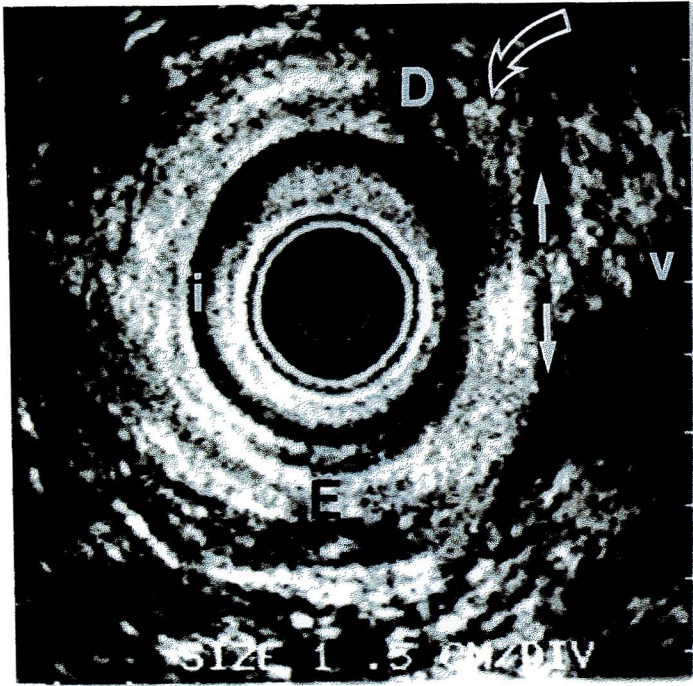


Figure 4.6L

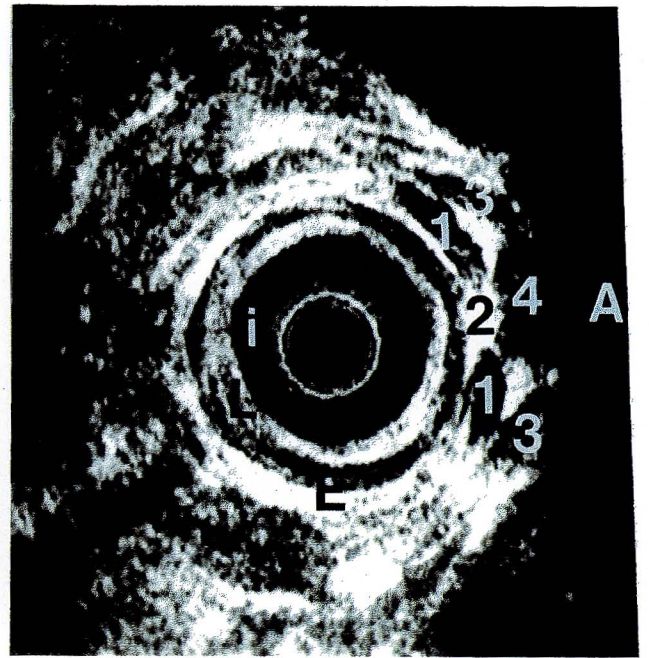
**Figures 4.6k & L. The subcutaneous external anal sphincter.**

Fig 4.6k Image at level 4 demonstrating a conical subcutaneous external sphincter (E). Note that the internal sphincter is absent and that the external sphincter tapers posteriorly contributing to the anococcygeal ligament (X). Anteriorly, the bulbospongiosus muscle (open arrows) encircles the vagina.

Compare this to Fig 4.6L where the subcutaneous external sphincter (E) is annular with little antero-posterior attachment.



**Figure 4.6m**



**Figure 4.6n**

**Figures 4.6 m & n. Images of external sphincter variant and perineal muscles.**

**Fig 4.6m.** Image at level 3 in a female showing an external sphincter (E) variant. A bundle of E fibres (open arrow) is running together with the right superficial transverse perineal muscle (right and left muscles shown by closed arrows). The change in orientation of the muscle fibres created by this ectopic insertion leaves a hypoechoic segment (D) that could be wrongly interpreted as a sphincter defect. Vagina = v.

**Fig 4.6n.** Image at Level 2 in a male to illustrate the perineal muscles. Anteriorly (A), the (hypoechoic) superficial transverse perineal muscles (1) can be seen on either side of the central point of the perineum (2). The ischio-cavernosus muscles (3) can be seen on the medial aspect of the pubic rami merging anteriorly with the bulbospongiosus muscle (bulb of the penis) (4). The hyperechoic longitudinal muscle (LM) can be distinguished from the relatively hypoechoic EAS (E) and internal sphincter (i).

(iii) Longitudinal muscle

When the EAS was relatively hypoechoic, the longitudinal muscle layer (Figs 4.6d,i,m) was clearly distinguishable as a hyperechoic layer (Section 4.2). This pattern of echogenicity was present in all males but in only 40% of the females (Table 4.3). The longitudinal muscle was thicker postero-laterally and less prominent anteriorly (Fig 4.6j). In 3 females the longitudinal muscle layer was of mixed echogenicity with only the interfaces appearing brightly hyperechoic, while the middle appeared hypoechoic creating a "tram-line" effect.

(iv) Internal anal sphincter (IAS)

This layer appeared homogeneously hypoechoic and was identified in all subjects (Figs 4.6). In 1 female the IAS appeared fragmented circumferentially and in 9 (10%) poorly delineated anteriorly (in 4 this affected the full length and in 5 only the distal IAS was affected). The distal IAS was poorly delineated in one male.

(v) Mucosa and Subepithelial tissues

The hyperechoic submucosa (subepithelium) was seen in all subjects (Figs 4.6). The mucosa was not distinguishable as a separate sonographic structure.

(vi) Anococcygeal ligament

This ligamentous insertion into the coccyx is formed predominantly by fibrous contributions from the posterior terminations of the EAS particularly the superficial EAS the apex of which merged into a posterior conical deformity of the EAS (Figs 4.6d,j,m). It was seen more prominently and more often in males (76%) (Figs 4.6j)

than in the females (49%) (Figs 4.6d).

(vii) Perineal body

The perineal body was not a clearly defined sonographic structure. However, the central point of the perineum (Fig 4.6m) where the superficial transverse perinei, deep external sphincter and bulbospongiosus (previously known as the bulbocavernosus) muscles appeared to meet was seen in some subjects particularly in males (Table V; Fig 4.6m).

(viii) Ischiocavernosus muscle

The ischiocavernosus muscle was not identified in the female but was seen in 43% of males as a hypoechoic structure parallel to the pubic rami (Fig 4.6m; Table V).

#### 4.4.3.2 Muscle thicknesses

The puborectalis and deep and superficial external sphincter was significantly thicker in males (Table VI). A similar trend was seen with the subcutaneous external sphincter but this was not statistically significant. Overall, the mean thickness of all three subdivisions of the EAS combined was significantly thicker in the 21 males [8.6 (1.0) mm, mean(SD)] compared to the 93 females [7.7 (1.1)],  $P=0.001$ . The males however were significantly heavier than the females [73 (7) v 65 (11) kg,  $P< 0.0001$ ] with a significant positive correlation between body weight and the mean thickness of the combined components of the external sphincter ( $P< 0.0001$ ,  $r=0.39$ ), as well as the mean thickness of the puborectalis muscle ( $P< 0.0001$ ,  $r=0.39$ ).

The mean internal sphincter and mean longitudinal muscle thicknesses were not significantly different between males and females (Table VI).

#### 4.4.3.3 Anal manometry

In the females the maximum resting pressure was 63 (11) and the maximum squeeze pressure 92 (40)mmHg [mean (SD)]. On linear regression analysis there was no significant correlation between the mean lateral thickness of the internal sphincter and the maximum resting pressure (a reflection predominantly of internal sphincter function). Nor was there a significant correlation between the mean lateral thickness of the external anal sphincter and the maximum squeeze pressure (a reflection of external sphincter function).

#### 4.4.4 DISCUSSION

Previous anatomical descriptions of the anal sphincters have been based mainly on small numbers of dissections of elderly cadaveric or surgical specimens. There is no description in the literature of the *in vivo* anatomy of the anorectal muscles in a large number of subjects. In the present study only nulliparous women were studied as the anal sphincters are frequently damaged during vaginal delivery (See Section 7). In addition we have studied 21 healthy males to identify gender differences in anorectal anatomy.

Anatomic dissection studies have demonstrated that in the female the external anal

sphincter is shorter anteriorly (Gorsch 1955, Oh and Kark 1972, Stelzner 1981). Aronson et al (1990) disputed this finding in their study of 5 nulliparous women using magnetic resonance imaging and claimed that the anal muscles formed an ellipsoidal cylinder with an anterior length almost equal to its posterior length. From personal observations using MRI (unpublished data) I could not reproduce their finding. My present study has indicated that unlike males, 98% of women have a shorter external sphincter anteriorly than posteriorly. In cross sectional imaging the sloping fibres produce an apparent anterior defect. This must be distinguished from a true defect in the sphincter. As the probe is withdrawn it is easy to appreciate the configuration of these sloping muscle bundles, that rapidly merge into an intact anterior ring. Pathological defects extend into this ring. The deficiency in the external sphincter at this level may explain the vulnerability of the internal anal sphincter to obstetric damage even in the presence of an intact external sphincter (Section 7.1).

Normal variants of the external sphincter have previously been identified during anatomical dissections (Hiller 1931, Ayoub 1979, Gorsch 1955). Serial radial sonographic images of the anal canal can outline the direction of muscle bundles. In the present study a deep external sphincter variant in which muscle fibres extend laterally with the superficial transverse perineal muscle to attach to the ischial ramus (Gorsch 1955, Ayoub 1979) was identified by anal endosonography in 13% of females and 14% of males. The significance of this variant is uncertain. However its attachment to the ischial ramus implies that it could serve as an anchoring support for the anal sphincter complex. It is very likely that this attachment would be severed during a postero-lateral episiotomy. Moreover if the presence of this variant is not

recognised during anal endosonography it could be erroneously interpreted as an external sphincter defect (Fig 4.6m).

Subdivisions of the external sphincter into 2 or 3 parts (Section 4.1) have been previously proposed although no consistent histological separation or difference could be demonstrated between them (Fowler et al 1957). In the present sonographic study, there was no anatomical demarcation subdividing the external sphincter; nor was there a distinct cleavage between the puborectalis muscle and deep external sphincter. However in most subjects three parts were discernible by a change in the configuration of the external sphincter. The annular deep external sphincter became tapered antero-posteriorly at the level of the superficial external sphincter, where there was an attachment anteriorly into the perineal body and condensation posteriorly into the anococcygeal ligament. The subcutaneous external sphincter, located distal to the inferior edge of the internal anal sphincter, was annular in shape, tapering posteriorly into the anococcygeal ligament in about half the patients. This finding is contrary to the triple loop theory suggested by Shafik (1975) in which he described the base loop to be directed anteriorly. Instead, my findings support the double loop theory of Oh and Kark (1972) with the puborectalis directed anteriorly, and most of the external sphincter directed posteriorly.

The anococcygeal ligament was identified sonographically in 49% of females and 76% of males arising mainly from the superficial component of the external sphincter but contributions from the deep and subcutaneous components were also recognised. This structure has also been inconsistently identified during anatomical dissection

(Courtney 1950).

The sonographic appearance of the longitudinal muscle has only been verified recently (Section 4.3), and although visible in all males was only discernible in 40% of females. During *in vitro* and *in vivo* dissections it has been shown that in females, particularly the elderly with reduced muscle mass, the longitudinal muscle although present histologically could not be distinguished sonographically with the 7 MHz probe, as it was of the same echogenicity and pattern as the external sphincter. The longitudinal muscle seemed to vary in thickness both in the circumferential and longitudinal axis. Although implicated to have a role in defaecation (Shafik 1976), its exact function is unknown. In the present study I have shown that there is a significant correlation between anal striated muscle thickness and body weight. This could explain the differences in striated muscle thickness between males and females.

In this study of healthy nulliparous females no relationship was identified between sphincter muscle thickness and manometric measurements, in keeping with another endosonographic study (Nielsen et al 1992a). However these subjects belonged to a uniform age group and this finding may not apply to older patients with anorectal disease. In a study (Law et al 1991) of 7 patients with idiopathic faecal incontinence a linear correlation was demonstrated between internal sphincter thickness and the maximum resting pressure. Another study (Sun et al 1992) found no difference between the mean internal sphincter thickness in patients suffering from haemorrhoids and controls and suggested that the higher resting pressure in patients suffering from haemorrhoids is therefore of vascular origin. The present study casts doubts on their

deductions as we found no correlation between muscle thicknesses of either the puborectalis, the longitudinal muscle, the internal or external sphincter and anal pressures (maximum resting and squeeze pressures) in healthy nulliparous women.

In summary, the in vivo endosonographic anal anatomy, including muscle thicknesses in both sexes has been established in a large series of men and women. Pitfalls in imaging such as the recognition of anatomical gender differences and normal muscle variants have been highlighted. A better understanding of the normal sonographic anatomy of the anal sphincter should lead to more precise diagnosis of abnormalities.

## SECTION 4.5

### EFFECT OF PREGNANCY ON ANAL SPHINCTER MORPHOLOGY AND FUNCTION

#### 4.5.1 INTRODUCTION

Changes in gastro-intestinal motility during pregnancy are well documented (Kamm 1991). Heartburn and constipation are common symptoms (Fagan 1989) and changes in lower oesophageal sphincter function, (Van Thiel et al.1977) gastric emptying (Davidson et al. 1970) and oro-caecal transit (Wald et al 1982) have been reported.

These motility changes are thought to be due to the marked changes which occur in circulating steroid sex hormones. During pregnancy the serum progesterone concentration is increased 60 to 100 fold (West and McNeilly 1979, Juniper et al. 1989, O'leary et al 1991, Donaldson et al 1991) and the oestrogen concentration 20 to 80 fold (West and McNeilly 1979, Juniper et al. 1989, O'leary et al 1991) when compared with normal fluctuations occurring during the menstrual cycle (Kamm et al 1989).

Although oestrogen receptors have been identified in the external anal sphincter (Haadem et al 1991) and progesterone has been shown to relax gastro-intestinal smooth muscle (Kumar 1962), the effect of hormonal changes in pregnancy on the anal sphincter is unknown. Vaginal delivery has a major effect on the sphincters, with

up to 13 percent of women having their first vaginal delivery developing new defaecatory symptoms (Section 7.1) attributed to mechanical trauma. The aim of this prospective study was to establish whether pregnancy itself (when concentrations of oestrogens and progesterone have been previously shown to be consistently elevated (West and McNeilly 1979, Juniper et al. 1989, Kamm et al 1989, O'leary et al 1991, Donaldson et al 1991) has any effect on anal sphincter morphology and function in the absence of mechanical trauma.

#### **4.5.2 SUBJECTS AND METHODS:**

Twenty pregnant women (18 nulliparous and 2 multiparous) had anal endosonography and manometry performed during the last 6 weeks of pregnancy and repeated 6 weeks after caesarean section. The mean age of the women was 28 years (range 21 to 38). Seven women were white and 13 black. None suffered from diabetes, neurological or anorectal diseases.

##### **4.5.2.1 Anal endosonography (Described in Section 1.4.2)**

Serial endosonographic images were taken at 4 levels (Fig 4.6a): Level 1 = puborectalis muscle; Level 2 = deep (proximal) external anal sphincter (DEAS); Level 3 = superficial (mid) external sphincter (MEAS); Level 4 = subcutaneous (distal) external sphincter (SEAS). The same location for measurements was achieved using anatomical landmarks as previously described in Section 4.4 at levels shown in Fig 4.6a.

The thicknesses of the puborectalis muscle (Fig 4.6b), different components of the external anal sphincter (EAS) (Figs 4.6c-e), longitudinal muscle (LM) (Fig 4.6d) and internal anal sphincter (IAS) (Fig 4.6c,d) were measured in the mid-coronal plane on both the right and left sides. As the longitudinal muscle layer is not always distinguishable from the EAS sonographically, particularly in females (Section 4.1), it was included in the measurements of the EAS. When the longitudinal muscle was recognisable as a separate layer (Fig 4.6d) its maximum thickness was measured in the same lateral plane as the other muscle layers. The IAS was measured only at levels 2 and 3 (Fig 4.6a) ie. at the level of the deep (Fig 4.6c) and the superficial (Fig 4.6d) EAS as the IAS is absent at the level of the subcutaneous EAS (Figs 4.6e).

Muscle thicknesses on the prints were measured bilaterally using a Baty calliper (RS Components Ltd, London UK) which has graduations in 0.1 mm increments in contrast to the electronic calliper incorporated in the scanner which can only measure in 1 mm increments. These measurements from prints were multiplied by a conversion factor of 0.8 (magnified scale on prints) to obtain the final corrected measurements.

#### **4.5.2.2 Anal manometry**

The Stryker 295 air-filled pressure system is described in Section 2.1

#### **4.5.2.3 Statistical Analysis**

Paired comparisons between antenatal and postnatal measurements were performed using the Wilcoxon test. A correlation coefficient was calculated as a measure of the degree of association between 2 continuous variables.

### 4.5.3 RESULTS:

At follow up (mean time 46 days; range 35 to 67 days) none of the 20 women reported any change in bowel function following caesarean section. Fifteen women were still breastfeeding. Apart from 3 women who had just begun taking a low dose progestagen contraceptive, none of the women were on medication.

Successful endosonographic measurements were made in all women except one in whom measurements of the IAS and EAS at level 3 (superficial EAS) at both the antenatal and postnatal examination were not possible because this segment of the anal canal was very short and the deep and subcutaneous EAS could not be separately identified. No defects were found in either the IAS or EAS before or after delivery of any of the subjects.

The longitudinal muscle layer could only be identified in 10 of the 20 women and its prominence and thickness varied both in the circumferential and longitudinal axis of the anal canal. In these ten women only the maximum thickness was recorded, on each side.

The puborectalis muscle, EAS, IAS and longitudinal muscle layer thicknesses on both sides did not change significantly following delivery (Table VII).

**Table VII Anal sphincter muscle thicknesses and manometry before and after caesarean section**

<b>SITE</b>	<b>No.</b>	<b>ANTENATAL</b>		<b>POSTNATAL</b>		<b>P VALUE</b>
		<b>median</b>	<b>range</b>	<b>median</b>	<b>range</b>	
<b>Anal Muscle Thicknesses (mm)</b>						
PR (R)	20	8.0	5.0-11.8	8.1	3.3-9.9	0.42
PR (L)	20	7.7	3.7-11.1	7.3	2.6-9.1	0.44
DEAS (R)	20	7.3	5.3-40.1	7.3	5.5-10.1	0.95
DEAS (L)	20	6.8	4.8-10.2	6.6	4.4-9.9	0.11
MEAS (R)	19	7.0	5.1-9.3	7.1	4.9-8.9	0.46
MEAS (L)	19	7.0	4.9-9.8	7.0	4.8-9.2	0.52
SEAS (R)	20	10	5.8-12.2	10.2	6.1-12.5	0.35
SEAS (L)	20	9.1	5.3-11.7	9.2	5.0-11.0	0.13
LM (R)	10	3.0	1.7-3.5	2.7	1.8-4.2	0.40
LM (L)	10	2.5	1.7-3.5	2.5	1.9-3.4	0.64
DIAS (R)	20	1.7	0.7-3.7	1.7	0.7-2.5	0.10
DIAS (L)	20	1.2	0.5-2.1	1.3	0.6-2.1	0.13
MIAS (R)	19	1.5	0.5-2.3	1.5	0.6-2.5	1.00
MIAS (L)	19	1.0	0.5-1.8	0.9	0.5-2.0	0.43
<b>Anal Manometry (mmHg)</b>						
MRP	20	61	42-85	60	36-81	0.09
MSP	20	62	19-133	70	19-132	0.74

PR = puborectalis muscle; EAS = external anal sphincter; DEAS = Deep EAS; MEAS = mid (superficial) EAS; SEAS = Subcutaneous (distal) EAS; LM = longitudinal muscle; IAS = internal anal sphincter; DIAS = Deep IAS; MIAS = mid IAS; (R) = right; (L) = left. MRP = maximum resting pressure; MSP = maximum squeeze pressure.

The maximum resting pressure and maximum squeeze pressure were not significantly different between antenatal and postnatal measurements (Table VII).

There was no significant correlation between any of the muscle thicknesses and either the maximum resting or squeeze pressures. The subcutaneous EAS formed the thickest part of the EAS and correlated poorly with the maximum squeeze pressure ( $r=0.1$ ). The thickest part of the IAS varied (between levels 2 and 3 in Fig 4.6a) but the median maximum overall lateral thickness was 1.5 mm and range 0.6 to 2.3 ( $r=0.35$ ,  $P=0.13$ ).

#### 4.5.4 DISCUSSION

The effects of pregnancy or sex hormones on the morphology and function of the anal sphincters have not been reported in the literature. In this study 20 women were studied prospectively before and after caesarean section, as vaginal delivery can affect anal pressures (Snooks et al. 1984) and is associated with a high incidence of occult sphincter defects (Section 7.1). Pregnancy did not appear to affect the muscle thickness nor pressure activity of either smooth or striated sphincter muscles. It can therefore be concluded that any sphincter changes related to vaginal delivery are due to mechanical, rather than the hormonal changes in pregnancy.

However as the probe distends the anal canal it slightly under-estimates the true muscle thickness and this has been verified by sphincter muscle measurements in the resting state using vaginal endosonography (Section 6.2). However as the measurements in this study were made prospectively in the same patients by the same

examiner and using the same technique the overall results should not be affected. Furthermore sonographic measurements have been shown to be reproducible and my measurements are similar to that reported (Nielsen et al 1992).

In this study sex hormone levels were not measured because of the known marked elevation which occurs consistently during pregnancy (West and McNeilly 1979, Juniper et al. 1989, O'leary et al 1991, Donaldson et al 1991). The serum levels of progesterone and oestradiol fall to non-pregnant levels by 72 hours after delivery (West and McNeilly 1979). Some women in this study were breast feeding and some had commenced taking a low dose progestagen contraceptive, but the impact of these factors on the hormonal status would be negligible when compared with the major changes seen in pregnancy (Glasier et al. 1983).

Substantial evidence exists for a direct effect of sex hormones on gastro-intestinal function (Kamm 1991). Oestrogen and progesterone receptors have been demonstrated in intestinal smooth muscle (Singh et al. 1992), and in pelvic floor striated muscles (Haadem et al. 1991, Knudsen et al. 1991). Progesterone relaxes gastrointestinal muscle in vitro (Kumar 1962). Animal studies have shown that administered oestradiol and progesterone will slow intestinal transit (Ganiban et al. 1985). However, in vivo studies have provided inconsistent evidence about the importance of these hormones in modifying gut function. Studies on the effects of pregnancy on the lower oesophageal sphincter are contradictory, some showing a lower resting pressure (Nagler and Spiro 1961), a rise (Lind et al 1968), or no change (Hey et al 1987). Studies of oro-caecal transit (Wald et al 1982) and whole gut transit

(Kamm et al 1989) have also provided conflicting evidence on the effects of hormonal changes during the menstrual cycle. This study adds further weight to evidence suggesting that major hormonal changes do not substantially affect gut muscle function in vivo.

Although the maximum resting pressure reflects predominantly internal sphincter function and the maximum squeeze pressure is a function of the external sphincter (Frenckner et al 1975), in keeping with another study (Nielsen et al 1992a) no relationship between sphincter muscle thickness and manometric measurements was found. In a small study of 7 patients with idiopathic faecal incontinence a linear correlation was demonstrated between internal sphincter thickness and the maximum resting pressure (Law et al. 1991). However the subjects in the present study belonged to a uniform age group and this finding may not apply to patients with anorectal disease.

In summary, the high steroid hormone concentrations found in pregnancy do not appear to have a substantial effect on anal sphincter morphology or function. There is no relationship between anal muscle thicknesses and anal pressures in young healthy females.

## SECTION 5

### VALIDATION OF SONOGRAPHIC ANAL SPHINCTER DEFECTS

#### 5.1 INTRODUCTION

Prior to the advent of anal endosonography the clinical suspicion of an external sphincter defect could only be confirmed by concentric needle electromyography (EMG) "mapping" (Kiff and Swash 1983, Swash 1992a) and defects in the smooth muscle of the internal anal sphincter could only be inferred indirectly by a low maximum resting anal pressure (Sun et al 1989, Read and Sun 1992). However, needle EMG is a blind procedure and accurate delineation of a defect would require multiple and painful needle insertions through the sensitive perianal tissues.

In this section, two original studies are described. The first, prospectively validates the sonographic interpretation of external sphincter defects by histological analysis. The second, prospectively validates the interpretation of internal sphincter defects following surgical division of the internal sphincter.

## SECTION 5.2

# THE ACCURACY OF ANAL ENDOSONOGRAPHY IN THE DIAGNOSIS OF EXTERNAL ANAL SPHINCTER DEFECTS.

### 5.2.1 INTRODUCTION

Defects of the external anal sphincter are usually diagnosed by palpation, and confirmed by either supportive evidence from manometry or more directly by EMG. Anal endosonography has provided an alternative technique by which to identify sphincter defects. The normal sonographic anatomy of the anal sphincter has been previously validated by *in vitro* and *in vivo* dissections (Section 4.3), but proof of sphincter defects remains indirect. Endosonographic abnormalities have been shown to correlate with electrical defects on EMG (Law et al 1990, Cuesta et al 1992, Nielsen et al 1992b), but exact surgical documentation and histological verification is lacking. In this study the accuracy of sonography has been established by comparison to macroscopic surgical findings supported by histological examination and compared to clinical, EMG and manometric findings.

### 5.2.2 SUBJECTS AND METHODS

Twelve unselected, consecutive patients (mean age 46 years; range 30-64) with faecal incontinence having a sphincter repair were recruited into the study. They comprised 1 male and 11 female patients. All 11 females were parous (3 primiparous) and apart

from 4 women who recalled having a primary sphincter repair following a third degree obstetric tear, none had previous anorectal surgery. The median duration of symptoms was 6 years (range 1 - 33). The single male patient became incontinent after fistula surgery 2 years previously. All 12 patients were incontinent to liquid stool; in addition 10 were also incontinent to flatus, 6 to solids and 6 also suffered with faecal urgency.

All patients had anorectal physiology tests performed before surgery.

Digital examination was performed in the out-patient clinic by a senior registrar or consultant. The decision to perform a sphincter repair was based on the patient's symptoms, clinical examination and the results of anorectal physiology tests.

Anal manometry was performed using a closed water-filled system with a 4 mm microballoon connected via a 2 mm non-compliant catheter to a pressure transducer (Medex MX-848, Rossendale, UK) and a chart recorder (Devices MX4-73). The maximum resting pressure and maximum squeeze pressure (increment above the resting pressure) were measured using the station pull-through technique (Henry et al 1985).

External sphincter defects were localised by concentric needle EMG mapping. Multiple insertion of the needle identified a defect when electrical muscle activity diminished (Lubowski et al 1988c).

Anal endosonography was performed as described in Section 1. and I was blinded to the history of the patient and anorectal physiology test results.

The surgeon who performed each sphincter repair was unaware of the scan findings. After dissection, the full extent of any defect was documented. The whole or most of the suspected defect along the full length of the sphincter was excised and examined histologically. The size of the biopsy depended on the extent of the defect as well as the technique of repair adopted. Some surgeons utilised most of the scar tissue to perform an overlap repair, whilst others excised most of the scar tissue.

The specimens were orientated in their correct anatomical position before fixation and processing. Van Giesen staining for fibrous tissue as well as a haematoxylin and eosin stain were performed on all resulting paraffin sections. The pathologist was unaware of the scan or operative findings at the time of reporting.

### **5.2.3 RESULTS**

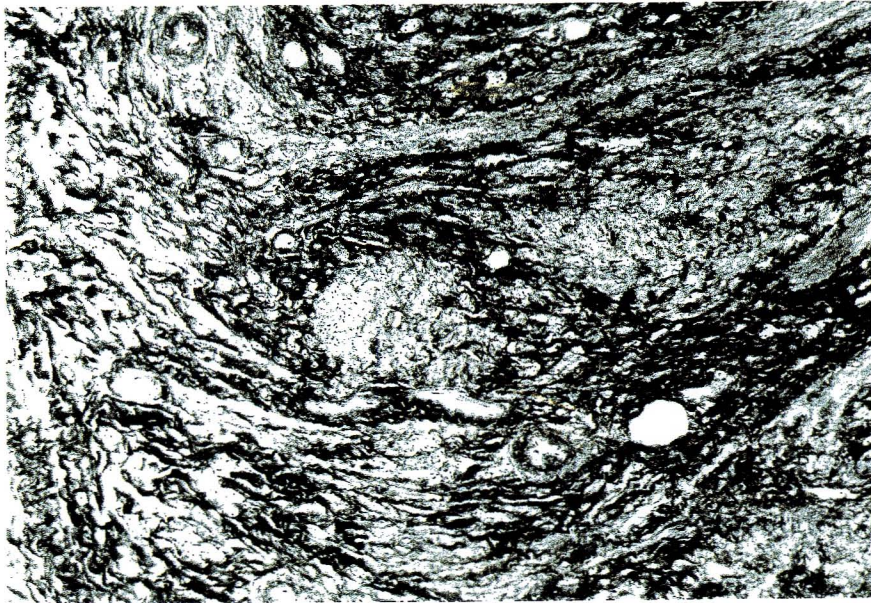
#### **5.2.3.1 Operative and histological findings**

Nine of the 12 patients were found to have an external sphincter defect during surgery and confirmed by histopathology. In 6 of the nine the defect was excised in full and in 3 most of the defect was excised.

In the remaining 3 of the 12 patients no external sphincter defect was identified after dissection and division. In 2 of these patients the sphincter muscle was obviously normal and a biopsy was not taken. The remaining case had an intact but thin external sphincter; a biopsy was taken which confirmed intact muscle.

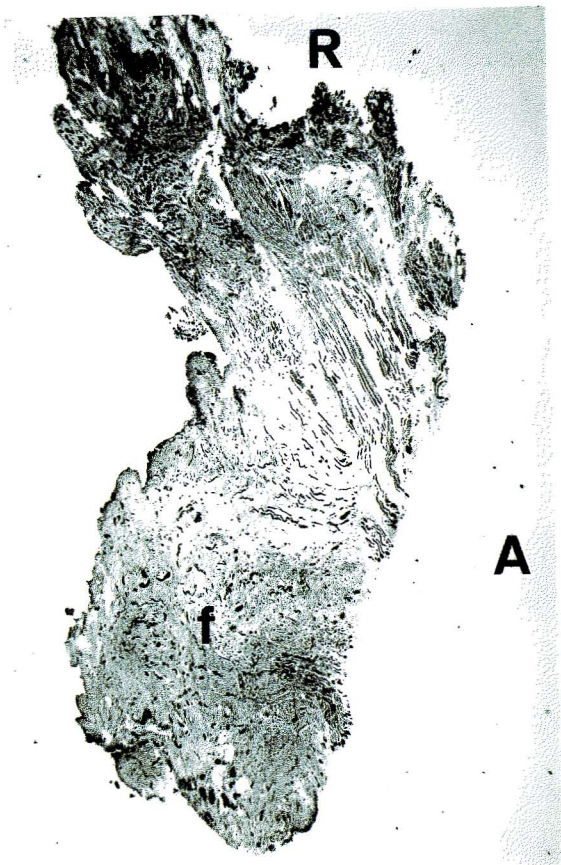
Histological appearance of a defect

There was a significant reduction in the number of muscle fibres with replacement by poorly vascularised fibrous tissue (Fig 5.1,5.2a). These features were present in a variable area of each of the abnormal biopsies. There was usually a margin of residual apparently normal external sphincter muscle also included in the biopsy, which formed a useful internal control tissue (Fig 5.2a).

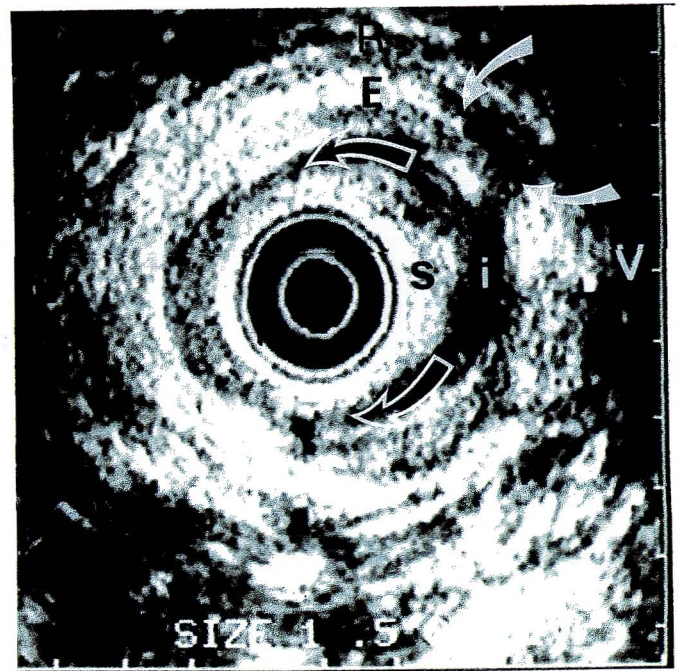


**Figure 5.1** Histological appearance of an external sphincter defect.

Van Giesen stain (x 100) of an external sphincter defect. The dark fibres are collagen and the pale linear areas between them are residual striated muscle fibres.



**Figure 5.2a**



**Figure 5.2b**

**Figures 5.2a & b. Histological appearance and corresponding sonographic image of an external sphincter defect.**

**Fig. 5.2a.** H & E stain of excised defect (magnified x 12) of the same patient in Fig 5.2b. A = anterior. R = right. There is fibrous tissue replacement (f) with a few residual striated muscle fibres in the pale area in the centre and to the right of the specimen. At the right edge of the defect normal striated muscle fibres can be seen.

**Fig 5.2b.** Anal endosonographic image of a 28 year old woman suffering from faecal incontinence following an anal stretch procedure. The vagina (V) is anterior; R = right; s = subepithelium. i = internal sphincter; E = external sphincter. An internal sphincter defect is indicated by open arrows and an external sphincter defect by closed arrows. The histological appearance of this excised defect between the arrows and in the same orientation is shown in Fig 5.2a.

### 5.2.3.2 Pre-operative diagnosis of sphincter defects

The sensitivity, predictive value and accuracy of each method for diagnosing histologically proven defects is presented in Table VIII.

**TABLE VIII Comparison between histologically confirmed anal sphincter defects and different methods of pre-operative assessment.**

	<b>Clinical Assessment</b>	<b>Maximum Squeeze Pressure</b>	<b>Concentric Needle EMG</b>	<b>Anal Endosono- graphy</b>
<b>Sensitivity</b>	5/9 (56%)	6/9 (67%)	8/9 (89%)	9/9 (100%)
<b>Positive Predictive Value</b>	5/7 (71%)	6/7 (86%)	8/10 (80%)	9/9 (100%)
<b>Accuracy</b>	6/12 (50%)	9/12 (75%)	9/12 (75%)	12/12 (100%)

A incremental maximum squeeze pressure of less than 40 cm H<sub>2</sub>O above the maximum resting pressure was considered as abnormal. The numbers are insufficient to accurately reflect the specificity and negative predictive value of each test.

### **5.2.3.3 Clinical assessment**

Clinical examination correctly identified a defect in 5 of the 9 patients with a histologically proven defect. Three were incorrectly reported as normal and 2 were equivocal (1 with a proven defect and 1 without).

### **5.2.3.4 Anal manometry**

The maximum squeeze pressure was lower than 40 cm H<sub>2</sub>O, which is the lower limit of the normal range in The St Mark's Laboratory, in 6 (67%) of the 9 patients with histological defects and in 1 of the 3 patients with an intact external sphincter. However 3 patients who had a normal squeeze pressure were subsequently found to have histologically proven external sphincter defects.

### **5.2.3.5 EMG mapping**

EMG defects were reported in 8 of 9 patients who had a histological EAS defect. In 2 of these 8, a defect was suspected but confirmation was not possible because the patient could not tolerate multiple needle insertions. In two patients an anterior defect was suggested by EMG but not confirmed at surgery.

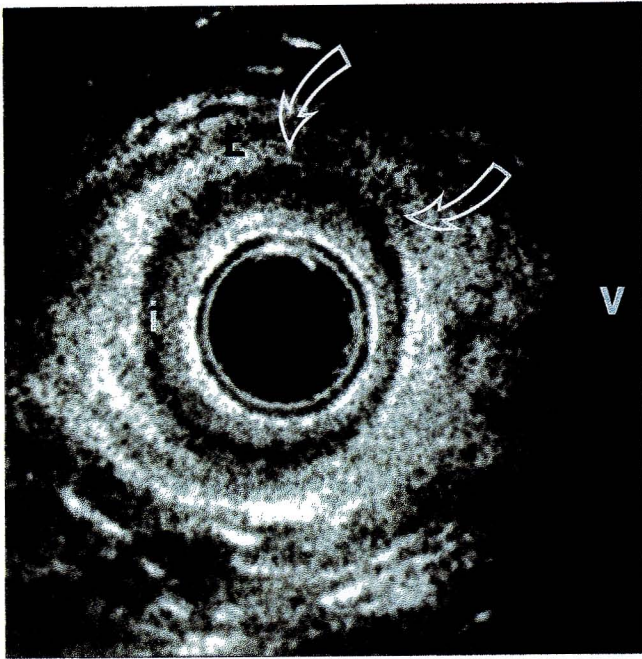
### **5.2.3.6 Anal endosonography**

Anal endosonography correctly detected an external sphincter defect in all the 9

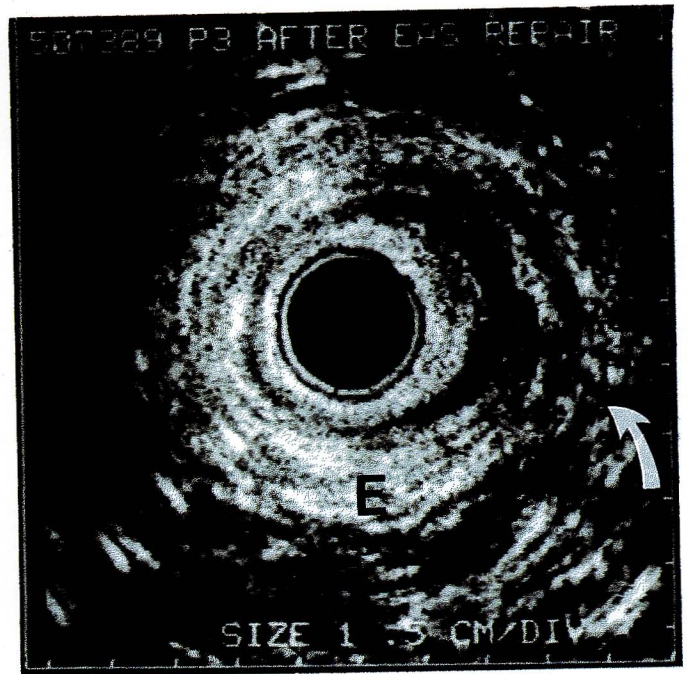
patients with a histologically confirmed defect. The sonographic criterion for the diagnosis of an external sphincter defect was the detection of a distinct change in sonographic appearance from the remaining external sphincter ring. These defects appeared clearly hypoechoic in 2 (Fig 5.2b) patients but in the remaining 7 appeared amorphous and of mixed echogenicity (Fig 5.3). Although amorphous defects appeared to have more fibrous tissue replacement than hypoechoic defects, histological grading according to sonographic appearance proved difficult.

The remaining 3 cases that were found to have normal sphincters at surgery were correctly identified pre-operatively by anal endosonography. The one case in which a defect was missed by EMG, but detected by ultrasound was found to have a small defect at surgery and this was confirmed by histology (Fig 5.2a). In order to assess the adequacy of repair this patient also had anal endosonography repeated 6 months after secondary sphincter repair (Fig 5.4).

In 8 of the 9 patients with an external sphincter defect, an internal sphincter defect was also identified by anal endosonography. A low maximum resting pressure (< 40 H<sub>2</sub>O) was identified in only 4 (50%) of these 8 patients with an IAS defect.



**Figure 5.3**



**Figure 5.4**

**Fig 5.3** An image of an amorphous external sphincter defect.

Anal endosonographic image of a 64 year old woman suffering from faecal incontinence. V = vagina. E = External sphincter. i = internal sphincter. An amorphous external sphincter defect of mixed echogenicity is delineated by arrows.

**Fig 5.4** Appearance of a successful secondary sphincter repair.

Image taken 6 months after secondary sphincter repair of the same patient described in Fig 5.2b. The overlap repair (arrow) of the external sphincter (E) is complete. The internal sphincter defect remains unchanged.

#### 5.2.4 DISCUSSION

Although the sonographic diagnosis of anal sphincter defects has been previously compared to concentric needle EMG mapping (Law et al 1990, Cuesta et al 1992, Nielsen et al 1992b), the presence and appearance of defects has not previously been verified histologically and compared to clinical or manometric assessment. In this blinded study, the accuracy of defining the presence or absence of an external sphincter defect was 50% for clinical examination, 75% for manometry, 75% for EMG and 100% for anal endosonography when compared to operative and histological findings. Although these findings are based on 12 patients studied, the histological validation of the ultrasound image emerged from this study as uniformly consistent. As a result, anal endosonography is now routinely performed at St. Mark's Hospital in virtually all patients suffering from faecal incontinence prior to sphincter repair.

EMG mapping is a blind procedure; loss of electrical muscular activity may occur as a result of needle placement either outside the external sphincter or within the internal sphincter, particularly when the external sphincter is attenuated anteriorly. Patient discomfort from multiple needle insertions may also limit accurate mapping. In contrast, anal endosonography causes no more discomfort than a digital examination and in addition enables visualisation of the internal sphincter. In the present study 75% of patients with an external sphincter defect also had an internal sphincter defect and the maximum resting pressure (an indirect method of detecting internal sphincter damage) had an accuracy in detecting this of only 50%.

In previous reports, external anal sphincter defects have been recognised by their hypoechogenicity (Law et al 1990, Nielsen et al 1992b). In vitro and in vivo studies (Section 4.1) have shown that the normal external sphincter can appear hypoechoic, particularly in male subjects. Moreover, erroneous diagnosis of sphincter defects can be made if normal muscle variants are not recognised (Section 4.4). This study has demonstrated that external sphincter defects can appear hypoechoic, or amorphous and of mixed echogenicity. Therefore a more reliable criterion for the diagnosis of external sphincter defects is recognition of a loss of the normal sonographic texture compared to the rest of the external sphincter ring. Histologically this corresponded to a loss of the normal muscle tissue with fibrous tissue replacement. This is in keeping with muscle injury elsewhere in the body in which dense scar tissue formation can result in denervation of the affected area with subsequent reduction in the ability of that muscle to produce tension (Jarvinen et al 1983).

This study demonstrates that anal endosonography is the most accurate means of detecting an external sphincter defect. Clinical examination alone is unreliable in determining the presence of a defect. Anal manometry and EMG may give complimentary physiological information but cannot be relied on to consistently define the presence or absence of a defect. Although these tests may to some extent be operator dependent, given adequate expertise anal endosonography is the investigation of choice.

## SECTION 5.3

### VALIDATION OF INTERNAL SPHINCTER DEFECTS DETECTED BY ANAL ENDOSONOGRAPHY

#### 5.3.1 INTRODUCTION

Lateral internal anal sphincterotomy (LIAS) is a commonly performed operation for the surgical treatment of anal fissure (Eisenhammer 1951, Parks 1967, Notaras 1971, Hawley 1969, Abcarian 1980, Olsen 1989). Eisenhammer first described this procedure in 1951, and advocated the division of almost the full length of the internal anal sphincter. However in current practice, the objective of this procedure is to divide the distal third to one half of the internal anal sphincter (up to the dentate line)(Parks 1967, Hawley 1969, Notaras 1971, Abcarian 1980, Olsen 1989). Although successful in relieving symptoms (Hawley 1969, Walker 1985, Khubchandani and Reed 1989), incontinence to flatus or liquids following LIAS has been reported to occur in 5% (Ravikumar et al. 1982) to 38% (Khubchandani and Reed 1989) of patients.

This study aimed to verify prospectively the sonographic appearance of an internal sphincter defect following deliberate division of the internal sphincter. In addition, the prevalence of symptoms of anal incontinence and the extent of disruption to the IAS following LAIS were also investigated.

### **5.3.2 SUBJECTS AND METHODS**

Fifteen patients (10 females and 5 males) with chronic anal fissure (mean age 39 years; range 26-67) having a LIAS were recruited into this study. Two of the females were nulliparous. A detailed history of bowel habit was taken.

Anal endosonography was performed as described in Section 1.4. In seven patients who had severe anal spasm, anal endosonography was performed during general anaesthesia pre-operatively.

All patients had a LIAS performed by the open technique (13 on the left side and 2 on the right) (Parks 1967). A 2 cm circumferential incision was made at the anal verge and the anal epithelium was elevated. The IAS was then divided with scissors up to the dentate line and the skin incision closed with interrupted skin sutures.

At the 2 month post-operative follow-up visit a detailed history of bowel habit was taken and anal endosonography repeated.

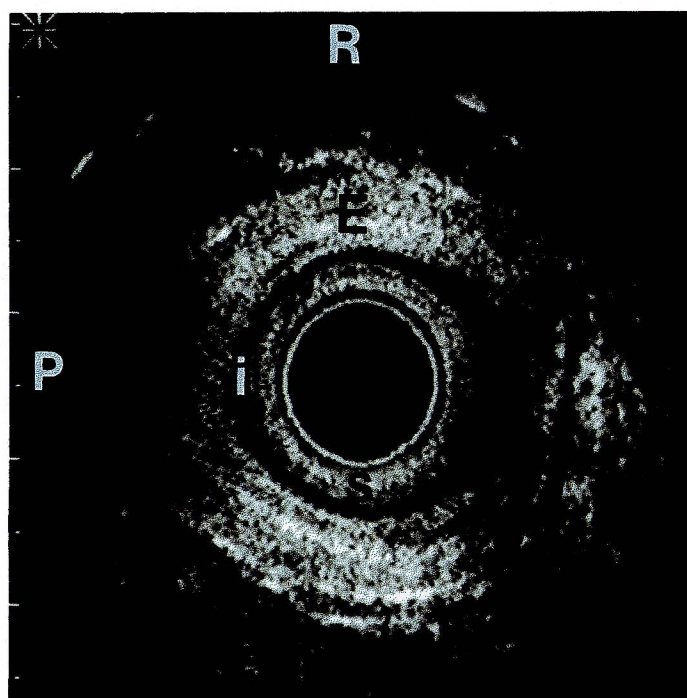
### **5.3.3 RESULTS**

#### **5.3.3.1 Symptoms**

Pre-operatively none of the patients had previous anorectal disease or suffered from anal incontinence. Two months post-operatively, none of the males were symptomatic but 3 of the females became incontinent to flatus only.

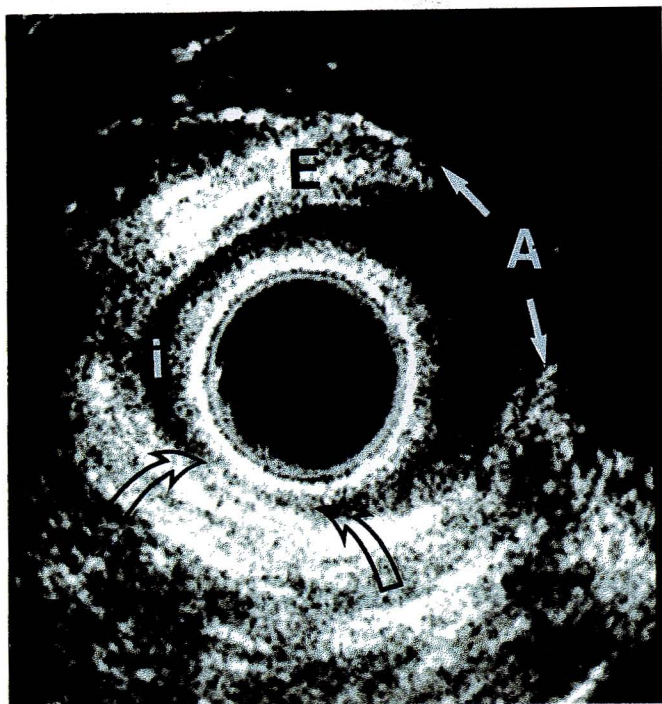
### 5.3.3.2 Anal endosonography

Pre-operatively, both the internal and external anal sphincter were intact in the male patients. However in 2 parous women an external sphincter defect was identified anteriorly. Post-operatively, an internal anal sphincter defect corresponding to the site of surgical division was identified in all patients except one male. The defect usually involved approximately 20% to 30% of the circumference of the internal sphincter. In 9 of the 10 females the defect involved the whole length of the internal sphincter (Fig 5.5b,c). In 4 males only the distal third of the internal sphincter (Fig 5.5d,e) was disrupted and in 1 male there was no apparent disruption of the internal sphincter. In 2 of the 3 women with incontinence to flatus an external sphincter defect was identified pre-operatively. Post-operatively their external sphincter defect was unchanged but their internal sphincter was disrupted along its entire length. The other incontinent patient was a 55 year old nulliparous women with a long history of straining at stool. Her post-operative scan also showed division of the internal sphincter along its entire length with an intact external sphincter. However further investigation revealed evidence of a bilateral pudendal neuropathy.

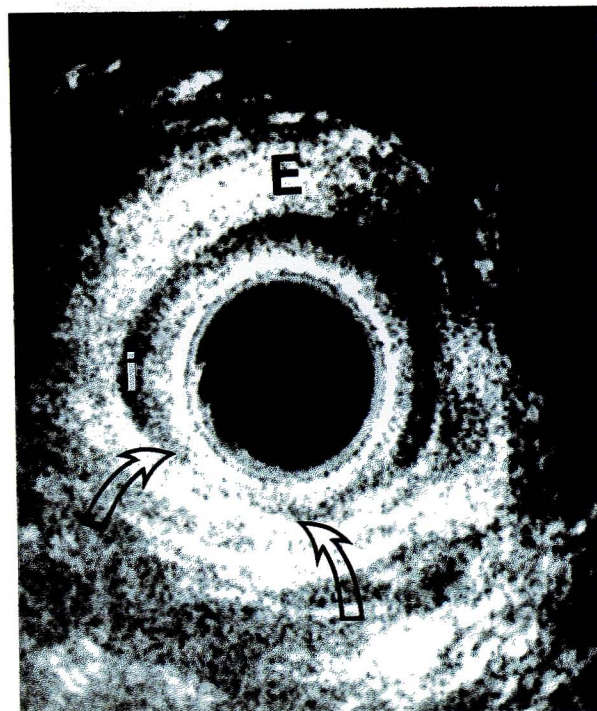


**Figure 5.5a** Pre-operative scan of the normal mid anal canal in a 29-year-old nulliparous female.

Posterior (P); right (R); submucosa (s); both the hypoechoic internal sphincter (i) and the hyperechoic external sphincter (E) are intact.



**Figure 5.5b**



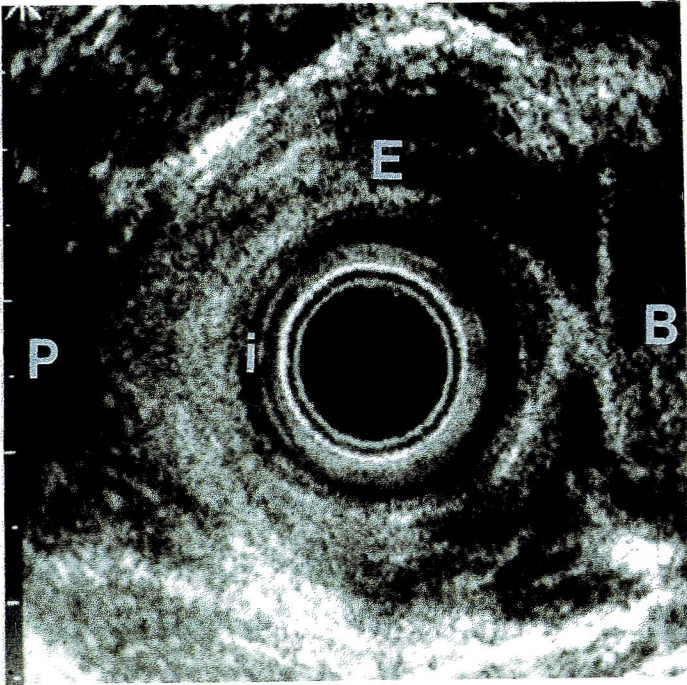
**Figure 5.5c**

**Figures 5.5b & c** Images after lateral internal anal sphincterotomy in a female.

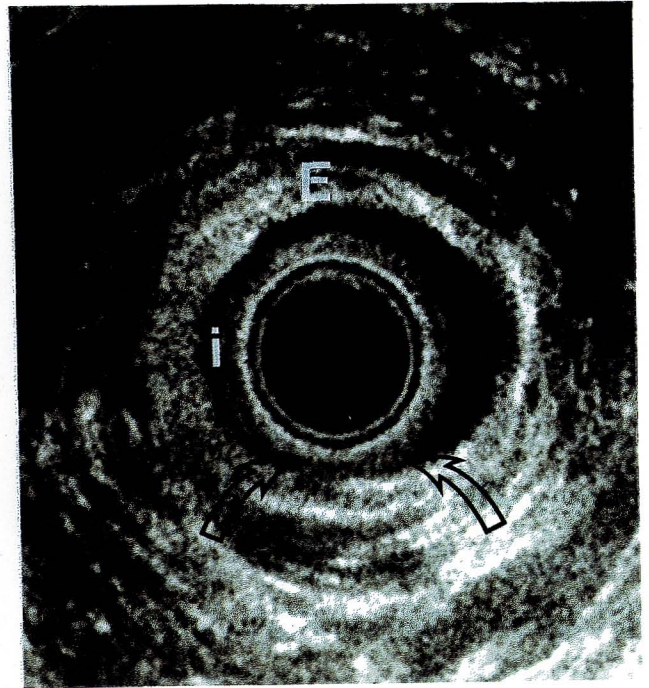
**Fig 5.5b** Scan of the proximal anal canal of the same patient shown in Fig 5.5a, two months after a left internal anal sphincterotomy. The hypoechoic area in the external sphincter anteriorly (A) is the normal appearance of the proximal external sphincter in females as described in Section 4.4. The internal sphincter (i) defect is demonstrated by open arrows.

**Figure 5.5c** Scan of the lower anal canal at the level of the distal internal sphincter of the same patient as in Figs. 5.5a&b. The internal sphincter (i) defect is demonstrated by open arrows.

Thus contrary to the intention of the procedure, the internal sphincter is divided along its entire length.



**Figure 5.5d**



**Figure 5.5e**

**Figures 5.5d & e Images after lateral internal anal sphincterotomy in a male.**

**Fig 5.5d** Anal endosonographic image of the proximal anal canal at the level of the deep external sphincter (E) in a 27 year old male 2 months after lateral internal anal sphincterotomy. The bulbospongiosus muscle (B) can be seen anteriorly. P = posterior. Note that the internal sphincter is intact.

**Fig 5.5e** Scan of the lower anal canal at the level of the distal internal sphincter and superficial external sphincter (E) of the same patient as in Fig 5.5d. The internal sphincter (i) defect is demonstrated by open arrows.

### 5.3.4 DISCUSSION

In contrast to males lateral internal anal sphincterotomy in females appears to result in a more extensive disruption than intended. This is likely to relate to the shorter anal canal in females (Taylor et al 1984, Felt-Bersma 1991). Patients with previous obstetric trauma may also be at increased risk of incontinence following such a procedure. In a previous prospective study described in Section 7.1, occult external sphincter defects were identified in 19% of primiparae and 29% of multiparae. In the present study 3 out of 10 females developed flatus incontinence following internal anal sphincterotomy, 2 of whom had a pre-existing external anal sphincter defect and a third had evidence of a pudendal neuropathy.

The recommendation from this study is that care should be exercised during sphincterotomy in women, as sphincter division, particularly in the presence of previous obstetric trauma, may further compromise sphincter function. The options of non-operative treatment (Frezza et al. 1992, Loder et al 1993) or a deliberate limited surgical division of the internal sphincter below the dentate line should be considered.

## SECTION 6

### VAGINAL ENDOSONOGRAPHY AND THE ANAL SPHINCTER

#### 6.1 INTRODUCTION

Anal endosonography is now a well established technique for imaging both the internal and external sphincters (Section 4.4, Law and Bartram 1989, Nielsen et al 1991, Cuesta et al 1992). It clearly demonstrates defects in these muscles (Sections 5.2, 5.3, Tjandra et al 1993) and has therefore proven invaluable in assessing patients with faecal incontinence (Law et al 1991, Cuesta et al 1992).

However it is possible that the anal probe may distort the anatomical arrangement of epithelial structures and the sphincter muscles. The frequency of the probe also precludes accurate imaging of mucosal and submucosal structures. Compression of sphincter muscles by the anal probe may also lead to inappropriate assessment of sphincter muscle thicknesses.

The purpose of this study was to image the anal canal and the surrounding muscles in their normal resting state using vaginal endosonography and to compare the accuracy of anal and vaginal endosonography in identifying sphincter defects.

## SECTION 6.2

### VAGINAL ENDOSONOGRAPHY: A NEW APPROACH TO IMAGE THE UNDISTURBED ANAL SPHINCTER

#### MATERIALS AND METHODS

Ten healthy, sexually active women (mean age 43 years; range 27 to 67) with no previous anorectal surgery and 10 women complaining of faecal incontinence (mean age 48 years; range 29 to 64) were studied. Informed consent was obtained from each patient.

Anal and vaginal endosonography was performed with the Bruel and Kjaer (Naerum, Denmark) 7 MHz probe described in Section 1.4.

Vaginal endosonography was performed with a balloon covering the transducer (Fig 1.5) as used for rectal scanning (Beynon et al 1986b). All scans were performed with the women lying in the left lateral position. The probe was inserted 3 cm into the vagina and the balloon was distended with 30 ml of water for acoustic coupling. Gradual withdrawal of the probe provided serial cross-sectional images of the anal canal. Anal endosonography was performed using the same probe with a hard sonolucent plastic cone covering the transducer instead of the balloon (Fig 1.3).

Hard copies were made of the images and the mean maximum lateral thickness of the internal sphincter was measured in both the anal and vaginal sonographic images. A vernier calliper with 0.1 mm graduations was used instead of the electronic calliper incorporated in the scanner which measures in 1 mm increments. These measurements

from the hard copies were multiplied by a conversion factor of 0.8 (magnified scale on prints) to obtain the final corrected measurements.

## **6.3 RESULTS**

### **6.3.1 Normal females**

On VES the rectum appeared collapsed and easily flattened antero-posteriorly (Fig 6.1) by the distended balloon in the vagina. By gradual withdrawal of the probe the puborectalis muscle sling was identified (Fig 6.2). At this level the anorectal junction was easily recognisable by a change from the larger flattened rectum to a well defined annular anal canal (Fig 6.2). Posteriorly the deep external sphincter was inseparable from the puborectalis (Fig 6.2). However as the external anal sphincter is shorter anteriorly in the female, the muscle slopes infero-medially and a "defect" was identified anteriorly (Fig 6.2). At this level, where the external anal sphincter appeared to be deficient anteriorly, the distance between the vagina and the internal anal sphincter was less than 5 mm (Fig 6.2). As the probe was withdrawn the external anal sphincter appeared as a complete ring (Fig 6.3). The anal canal appeared symmetrically rounded and both the internal and external sphincter were clearly visualised (Fig 6.3).

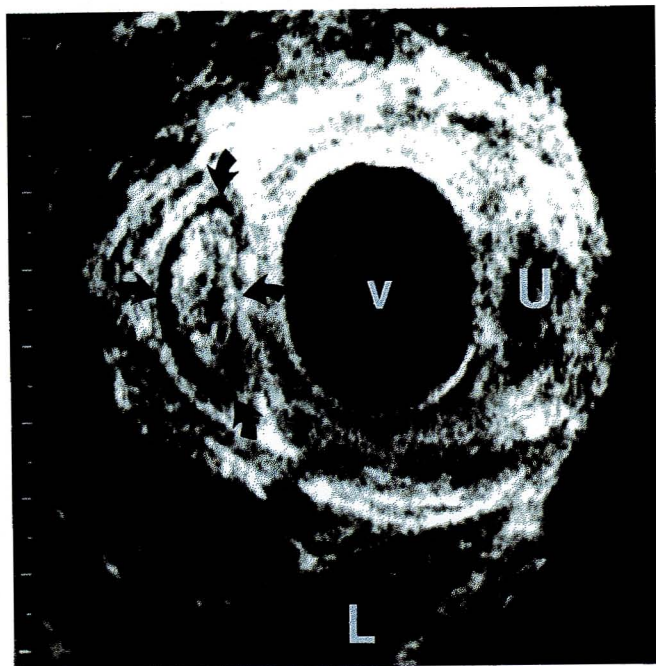


Figure 6.1

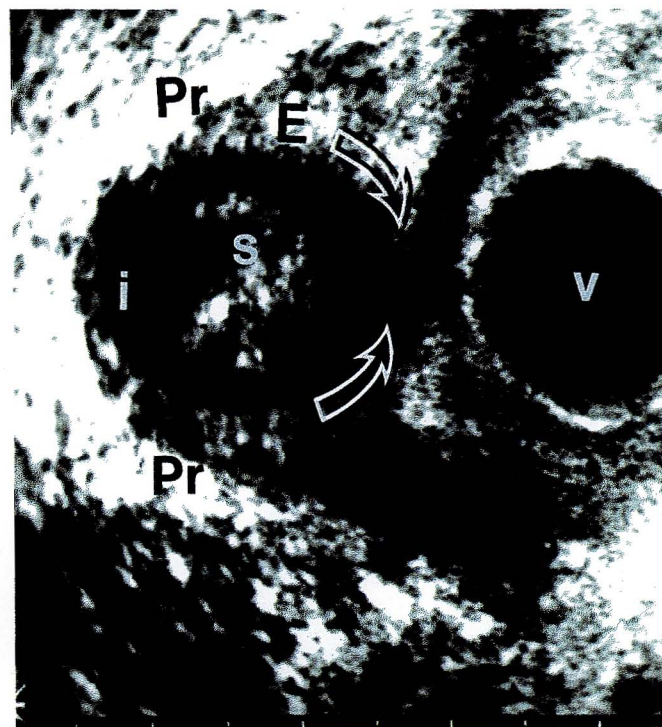
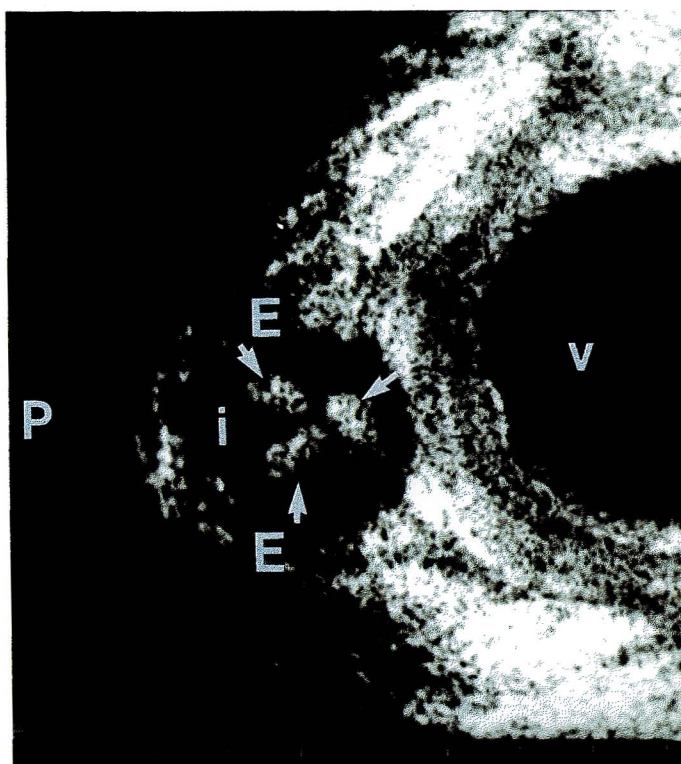


Figure 6.2

**Figures 6.1 and 6.2** Vaginal endosonographic images of the rectum and deep external sphincter.

**Fig 6.1** Vaginal endosonographic image demonstrating the collapsed rectum (arrows) at rest. All images are orientated exactly as it would appear anatomically scanning the woman in the left lateral position with anterior to the right of the images, L = left). The urethra (U) lies anterior to the distended balloon probe in the vagina (V).

**Fig 6.2** Vaginal endosonographic image at the level of the deep external anal sphincter (E). V = Probe in vagina, i = internal anal sphincter, s = anal epithelium at rest. Posteriorly (P), the external anal sphincter is inseparable from the puborectalis muscle and anteriorly a "defect" (arrows) is created by of the infero-medial sloping of the muscle.



**Fig 6.3 Vaginal endosonographic image of the deep external sphincter.**

Vaginal endosonographic image at a slightly lower level to that shown in Fig 6.2. V = Probe in vagina, i = internal anal sphincter, P = posterior. Note that the external anal sphincter (E) now appears as a complete ring. The anal cushions (arrows) can be seen at the classical 3, 7 and 11 o'clock positions.

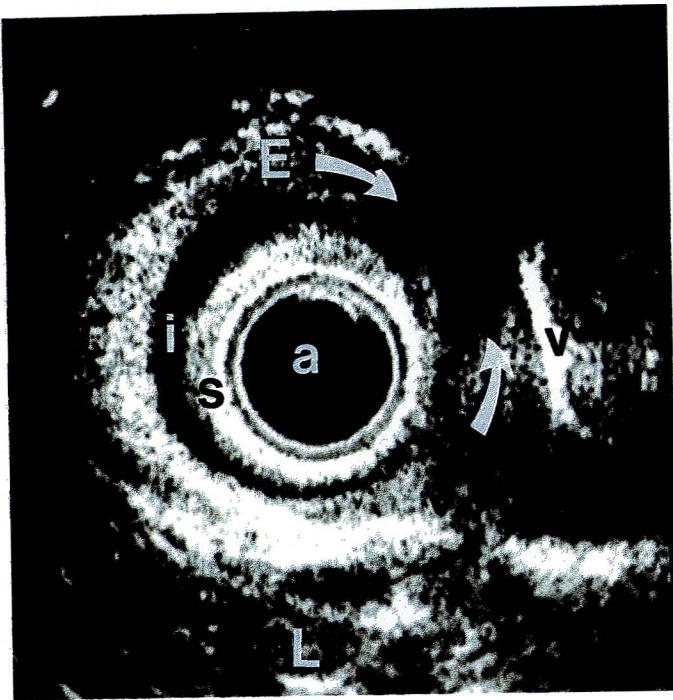
The undisturbed anal canal, submucosa, anal cushions, internal and external sphincter were clearly imaged by vaginal endosonography (Fig 6.3). The anal cushions appeared in the classical 3, 7 and 11 o'clock positions in only 6 of the 10 women (Fig 6.3). The mean lateral diameter of the epithelium and subepithelial layer (submucosa) was  $6.21 \pm 1.6$  mm (mean  $\pm$  SD). In 9 of the 10 women the anal canal was completely obliterated by the anal cushions and in the remaining one, internal haemorrhoids (large fluid filled cavities) distended the anal canal.

Although anal and vaginal endosonographic measurements of internal anal sphincter thickness correlated ( $r=0.83$ ,  $P=0.01$ ), anal endosonography consistently underestimated the thickness (anal endosonography  $2.3 \pm 0.5$  mm, vaginal endosonography  $3.2 \pm 1.2$ , mean  $\pm$  SD).

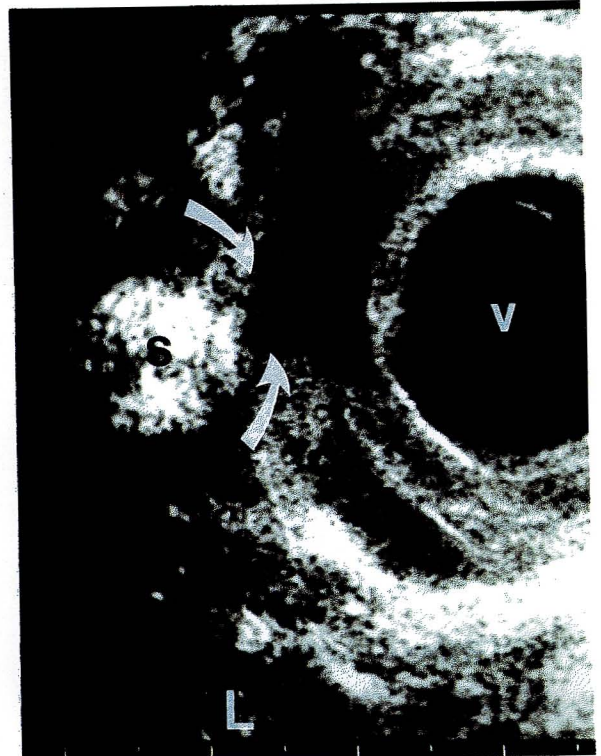
None of the 10 healthy women (4 nulliparous) had sphincter defects identified by anal endosonography.

### **6.3.2 Incontinent females (n=10)**

Anal endosonography identified 8 external and 7 internal sphincter defects. Using vaginal endosonography all these sphincter defects were identified (Fig 6.4a,b). One internal sphincter defect was found to affect the full length of the internal sphincter by vaginal endosonography but appeared to involve only the distal part by anal endosonography.



**Figure 6.4a**



**Figure 6.4b**

**Figures 6.4a & b.** Anal and vaginal endosonographic images of the same external sphincter defect.

**Fig 6.4a** Anal endosonographic image of the mid-anal canal of a woman suffering from faecal incontinence. L = left, the vagina (v) is anterior, a = anal probe in the anal canal, s = sub-epithelium, i = internal anal sphincter, E = external anal sphincter. A large external sphincter defect is demonstrated between the arrows.

**Fig 6.4b** Vaginal endosonographic image of the same woman as in Fig 6.4a. P = posterior, L = left, s = anal epithelium, v = vaginal probe. The same external sphincter defect demonstrated with anal endosonography (Fig 6.4a) can be imaged with vaginal endosonography (between the arrows).

## 6.4 DISCUSSION

This study describes a new technique of imaging anal structures by vaginal endosonography. The anal mucosa and the anal sphincter mechanism can be imaged in detail at rest.

Vaginal endosonography clearly demonstrates the close proximity of the anal sphincters to the posterior vaginal wall. During childbirth the volume of distension of the vagina by the fetal head is over 10 times the volume used in this study. It is therefore apparent why a large proportion of women can sustain damage to the anal sphincters during vaginal delivery (Section 7.1). The shorter anterior external anal sphincter in females (Stelzner 1981), confirmed by vaginal endosonography, may explain the vulnerability of the internal sphincter to damage even in the presence of an intact external sphincter (Section 7.1).

Aronson et al. (1990) performed MRI of the anal sphincter muscles in 5 females and indicated that the anal sphincter is of the same length in both the anterior and posterior plane. However I have shown both by anal (Section 4.4) and vaginal endosonography that the external anal sphincter is shorter anteriorly and this is in keeping with anatomical studies (Stelzner 1981). Furthermore, it appears that Aronson et al. (1990) have grossly overestimated the thickness of the internal sphincter. Measurements obtained by vaginal endosonography (range 2 to 4.4mm) are in keeping with fresh anatomical dissections (0.5 to 3mm) (Hiller 1931) as well as with anal endosonographic measurements from other studies (0.5 to 3.7mm) (Nielsen et al

1991). This is in contrast to MRI measurements of 10 mm given by Aronson et al. (1990).

This study has demonstrated that vaginal endosonography compares favourably to anal endosonography in identifying anal sphincter defects. The advantage of one technique over the other in the diagnosis of sphincter defects needs further evaluation. Other potential applications for this technique include evaluation of the pathogenesis of anal fissure and haemorrhoids and investigation of perineal sepsis and anovaginal malignancy.

**SECTION 7**  
**OBSTETRIC TRAUMA TO THE ANAL SPHINCTERS AND THEIR**  
**INNERVATION**

**INTRODUCTION**

The incidence of faecal incontinence in middle-aged women is 8 times higher than men of the same age (Henry 1987). This discordance in sex distribution is attributed largely to obstetric trauma which is now regarded as the commonest cause of faecal incontinence.

In this section the main hypothesis outlined in the introduction of this thesis is challenged. In addition, the causes and mechanisms of obstetric related faecal incontinence, the role of various obstetric factors during labour and the effects of obstetric intervention are critically analyzed. Finally recommendations are made to modify aspects of obstetric practice with a view to reducing anorectal morbidity.

Four separate studies are presented:

- i) **Section 7.2** This study prospectively investigates the incidence and significance of occult damage to the pudendal nerves and anal sphincter.
  
- ii) **Section 7.3** The risk factors associated with recognised damage (third or fourth degree obstetric tears) and also, the outcome of primary sphincter repair are

evaluated.

iii) **Section 7.4** The incidence of defaecatory symptoms, occult anal sphincter defects and pudendal nerve damage during forceps and vacuum delivery is compared.

iv) **Section 7.5** The results of a questionnaire to midwives and hospital trainee doctors actively involved in obstetric care are analyzed. The perceptions of these practitioners incising and repairing the perineum were assessed and deficiencies in training highlighted.

## SECTION 7.1

### OBSTETRIC TRAUMA TO THE INNERVATION AND MUSCLES OF THE ANAL SPHINCTER

The complex and multifactorial nature of the mechanisms that maintain incontinence have been described in Section 2. Obstetric related damage to the anal sphincter complex may be either due to direct mechanical trauma or indirect following damage to the pelvic nerves and consequent atrophy and weakness of the striated muscles. Mechanical disruption and neurogenic damage may also co-exist in the same patient.

#### 7.1.1 Neurogenic trauma

In about 80% of women with idiopathic anorectal incontinence there is histological evidence of denervation of the striated pelvic floor muscles, particularly the puborectalis and external sphincter (Parks et al.1977, Beersiek et al. 1979, Neil and Swash 1980). This feature has also been demonstrated electro-physiologically (see Section 2.3.3) by means of an increased fibre density in patients with idiopathic faecal incontinence indicating re-innervation following denervation (Neill and Swash 1980). Another finding in these patients is a conduction delay in pudendal nerves (Kiff and Swash 1984) as measured by pudendal nerve terminal motor latencies (PNTML)(see Section 2.3.4).

The aetiology of this denervating process is attributed to direct compression or traction injury of the pudendal nerve as it curves around the ischial spine and enters

the fibrous sheath of the pudendal canal (see Section 2.3.5). In support of this theory, prolonged PNTML have been identified in patients with a history of chronic straining eg. chronic constipation (Kiff et al 1984c) abnormal perineal descent (Henry et al 1982) and vaginal delivery (Snooks et al 1984).

In 1909, Hertz suggested that pelvic floor damage may result from a normal vaginal delivery (Hertz 1909). However, preliminary objective scientific evidence for this was only produced in 1984 by Snooks et al.(1984), a completed report in 1986 (Snooks et al 1986) and a follow-up of 14 patients 5 years later (Snooks et al 1990). They studied 122 women (71 after delivery with manometry, perineometry, PNTML and EMG, and 51 before and after delivery with EMG). This study demonstrated an increase in anal sphincter striated muscle fibre density in the vaginal delivery group at 2 months post-partum indicating evidence of re-innervation following denervation. The fibre density was not altered following elective Caesarean section. An abnormal degree of perineal descent on straining occurred in all women delivered vaginally and this persisted at 2 months after delivery. The maximum resting pressures (indicative of internal sphincter function) were within normal limits after delivery but the maximum squeeze pressures were still reduced at 2 months after delivery indicating persistent weakness of the external sphincter. Thirty three percent of primiparae and 50% of multiparae had prolonged PNTML within 48 hours of delivery. However by 2 months, the PNTML had returned to normal in 60% of these women, indicating that damage to pudendal nerve conduction is reversible. In the analysis of obstetric factors, multiparity, forceps delivery, increased duration of the second stage of labour, third degree perineal tears and high birth weight were important factors leading to

pudendal nerve damage. In the 5 year follow-up study of 14 women, only multiparae who did not have a forceps delivery were selected; the denervating process was found to be progressive in the majority of women and 5 women suffered from stress incontinence of urine, 3 of whom were also incontinent to flatus. In the group as a whole, the maximum squeeze pressures remained as low as that measured 48 hours after delivery but measurements of the resting pressure were not reported. Surprisingly, despite an increase in fibre density and prolonged PNTML, the plane of the perineum on straining had returned to antenatal values.

In another neurophysiological prospective study, Allen et al (1990) studied 96 nulliparous women with EMG, PNTML and vaginal pressure measurements during pelvic floor contraction. They found evidence of re-innervation in the pelvic floor muscles of 80% of primiparae 2 months after vaginal delivery. Vaginal pressure was significantly lower than antenatal values. In contrast to the Snooks et al. (1984, 1986) study the PNTML was within normal limits at 48 hours after delivery and there was no change in PNTML between 48 hours and 2 months after delivery. Moreover, the only obstetric factors associated with re-innervation was a high birth weight and a longer active stage of labour.

A third prospective study (Small and Wynne 1990) measured anal pressures, anal sensation and the perineal plane in 72 subjects. These measurements were performed antenatally and 72 hours after delivery. In 41 women the measurements were also performed 2 months after delivery. Anal sensation was unchanged following vaginal delivery and at 2 months after delivery the only abnormality was an abnormal squeeze

pressure.

The role of anal sensation in the maintenance of incontinence is discussed in Section 2.1.7. Apart from the study by Small and Wynne (1990), anal sensation in relation to childbirth was measured in 1 other study (Cornes et al 1991) although this was not measured prospectively during pregnancy. They measured anal pressures and sensation in 96 primiparae within 10 days after delivery and measurements were repeated in 74 women 6 months after delivery. Similar to previous studies (Snooks et al. 1984, Small and Wynne 1990), only the squeeze pressures remained persistently low at 6 months when compared to controls. Their results of anal sensation measurements however are more difficult to interpret. They found that at 10 days postpartum anal sensation was significantly impaired after normal vaginal and forceps delivery at all levels of the anal canal but only in the mid anal canal after vacuum delivery; at 6 months anal sensation had returned to normal. Anal sensation remained unchanged after Caesarean section. In women who had a torn external sphincter, only impairment of sensation in the upper anal canal persisted at 6 months. More than half the women who admitted to persistent anal incontinence had normal anal sensation. One can conclude from this study that transient impairment of anal sensation can occur after vaginal delivery and instrumental delivery does not result in any greater impairment. Furthermore anal sensation in isolation plays a minor role in the development of obstetric related faecal incontinence.

### 7.1.2 Mechanical trauma

Primary sphincter repairs of third degree obstetric tears (a tear involving the anal sphincter) are usually repaired by obstetricians. Historically, the immediate outcome of primary sphincter repair has been considered to be good. In 5 separate older studies (Ingraham et al. 1949; Flemming 1959; Barter et al. 1960; Seiber and Kroon 1961; O'leary and O'Leary 1964) in a total of 2195 repaired third degree tears, no case of anal incontinence was reported at 6 weeks postpartum. However, most of these studies were conducted retrospectively. More recently, 3 Scandinavian studies (Haadem et al. 1988; Sorensen et al. 1988; Neilsen et al. 1992b) involving a total of 70 patients reported symptoms of anal incontinence in 29 to 48% of women 3 months to 3 years after primary sphincter repair.

Until recently, mechanical trauma to the anal sphincters was only suspected when there was a history of difficult childbirth, particularly a third degree tear. Delineation of defects in the external anal sphincter relied on electromyographic needle "mapping" (Kiff and Swash 1983, Swash 1992) and defects in the smooth muscle of the internal anal sphincter could only be inferred indirectly by a low maximum resting anal pressure (Sun et al 1989, Read and Sun 1992). However the introduction of anal endosonography has allowed for imaging of both components of the anal sphincter (Law and Bartram 1989). As a result, unsuspected external anal sphincter defects have been discovered in patients thought to have purely "neurogenic" faecal incontinence (Law et al 1991). Furthermore, patients thought to have only an external sphincter defect have been found to have associated internal sphincter damage (Law et al 1991).

In 62 consecutive patients referred with faecal incontinence following obstetric sphincter trauma, anal endosonography revealed that 90 percent had an external sphincter defect, and 65% an internal sphincter defect (Burnett et al 1991).

### **7.1.3 Combined mechanical and neurogenic trauma**

In some situations eg. prolonged labour and difficult delivery, it is conceivable that both direct muscle trauma and damage to the pudendal nerve may occur. Snooks et al (1985) studied 20 women with a history faecal incontinence following a third degree obstetric tear (range 1 to 20 years). They found that 60% of these patients had evidence of pudendal nerve damage in addition to an anterior sphincter defect demonstrated by EMG studies (40% had abnormal PNTML). Although the presence of pudendal nerve damage has been found to be a poor prognostic factor in secondary or delayed sphincter repair (Browning and Motson 1983, Laurberg et al 1988, Jacobs et al 1990) its clinical relevance to primary sphincter repair has not been evaluated.

## SECTION 7.2

### A PROSPECTIVE STUDY OF ANAL SPHINCTER DISRUPTION AND PUDENDAL NERVE DAMAGE DURING CHILDBIRTH

#### 7.2.1 INTRODUCTION

Two studies described above (Snooks et al. 1984, Allen et al 1990) have prospectively demonstrated that up to 80% of women develop some degree of nerve damage during vaginal delivery (Section 7.1). They hypothesise that for some women this damage is the first step in a pathway leading to incontinence later in life. However although this hypothesis seems feasible, the possibility of occult mechanical trauma to the anal sphincters as a potential cause of faecal incontinence has not been investigated in both these studies. This present study aimed to establish prospectively the incidence of both occult anatomical and neurophysiological damage to the anal sphincters in a large consecutive series of women before and after delivery. The findings have been related to defaecatory symptoms and manometric measurements; in addition, the relationship between sphincter damage and the mode of delivery was evaluated and obstetric variables associated with sphincter damage identified.

#### 7.2.2 SUBJECTS AND METHODS

##### 7.2.2.1 Subjects

Two hundred and two unselected, consecutive consenting pregnant women attending the antenatal clinic (median age 28, range 18 - 43 years) beyond 34 weeks of gestation

were studied. Among these were 135 women with no previous vaginal delivery (2 of whom had a previous Caesarean section), and 67 women with one or more previous vaginal deliveries.

#### 7.2.2.2 Methods

All subjects were examined during the last 6 weeks of pregnancy, and asked to return for reassessment 6-8 weeks after delivery.

At each assessment a detailed questionnaire (Appendix A) was completed that included symptoms of faecal urgency (the inability to defer defecation for more than five minutes) and anal incontinence. Anal endosonography, manometry, pudendal nerve motor latency studies and perineometry were then performed. Each woman's labour and delivery were recorded from the hospital records.

The women's deliveries were managed as deemed appropriate by the attending obstetrician. All episiotomies were postero-lateral. Uncomplicated episiotomies were repaired by senior house officers and qualified midwives whereas complicated episiotomies were repaired by more senior doctors. With respect to the deliveries, first degree tears involving only vaginal epithelium were included in the no laceration group. Tears that involved the perineal body but not the external sphincter were considered second degree tears. Tears that involved the external sphincter were considered third degree tears and those that also involved the anal epithelium were considered fourth degree tears.

Women with ultrasonographic defects or prolonged pudendal nerve motor latencies six weeks after delivery were asked to return for reassessment 6 months postpartum.

i) Anal Endosonography

The Bruel and Kjaer 7 MHz rotating endoprobe was used (described in Section 1.4). The images were all recorded on to video tapes and to avoid bias in the reporting of sphincter defects, the tapes were reviewed independently by a clinically blinded experienced radiologist. Only when there was agreement between both observers about the presence of defects were they included as such.

ii) Anal Manometry

The Stryker 295-1 pressure monitor attached to an air-filled microballoon was used as described in Section 2.2.2.4.

iii) Pudendal nerve terminal motor latency (PNTML) measurement

The PNTML was measured using the St. Mark's pudendal nerve electrode described in Section 2.2.3.4.

iv) Perineometry

The plane of the perineum was measured with the St. Mark's perineometer described in Section 2.2.4.1.

#### **7.2.4 Statistical Analyses**

Details of the methods used are described in Section 3.

For data pertaining to anal manometry, perineometry and PNTML measurements the antenatal and postnatal results in the same subjects were compared using a paired t

test. Statistical significance of associations between categorical variables was assessed using the Chi-square or Fisher's exact test and for continuous variables a comparison between 2 independent groups was performed by a two-sample t-test. All measurements are reported as mean $\pm$ SD. All variables which demonstrated significant univariate associations with sphincter defects were then considered in a multiple logistic regression analysis. The variables were entered stepwise into the model to determine the combination of variables which best predicted damage. An odds ratio was also calculated.

## **7.2.5 RESULTS**

Of the 202 women who had antenatal examinations, 150 (100 primiparae and 50 multiparae) returned for the postnatal examination at a median time of 49 days (range 35 - 105 days). This represents a return rate of 74%. Twenty three women (21 primiparae and 2 multiparae) were delivered by caesarean section and 127 by vaginal delivery. Two multiparous women in the vaginal delivery group had their previous single delivery by caesarean section and for the purposes of analysis were included as primiparae. Hence 79 primiparae and 48 multiparae had a vaginal delivery. Seventy three women were white, 71 black and 6 belonged to other racial groups.

### **7.2.5.1 VAGINAL DELIVERY (n=127)**

There were 79 were primiparous vaginal deliveries, and 48 multiparous in whom 38 (80%) had only one previous vaginal delivery.

### **7.2.5.1.1 Defaecatory symptoms**

None of the 79 primiparous women had diabetes mellitus, neurological or anorectal disease. Postnatally 10 (13 percent) reported one or more new defaecatory symptoms; 8 (10 percent) faecal urgency and 4 (5 percent) anal incontinence (3 to flatus and 1 to flatus and liquid stool). Two women had temporary incontinence of flatus lasting less than three weeks postpartum. Among the 48 multiparous women, 9 (19 percent) had one or more bowel symptoms antenatally. These symptoms began after a previous vaginal delivery (urgency 7 women, incontinent to flatus 3 women, and incontinent to liquids 5 women). Postnatally 3 (6 percent) had new symptoms: 2 urgency plus flatus incontinence and 1 urgency alone. One woman with liquid incontinence antenatally was asymptomatic postnatally. Therefore, after delivery 11 (23 percent) multiparous women were symptomatic.

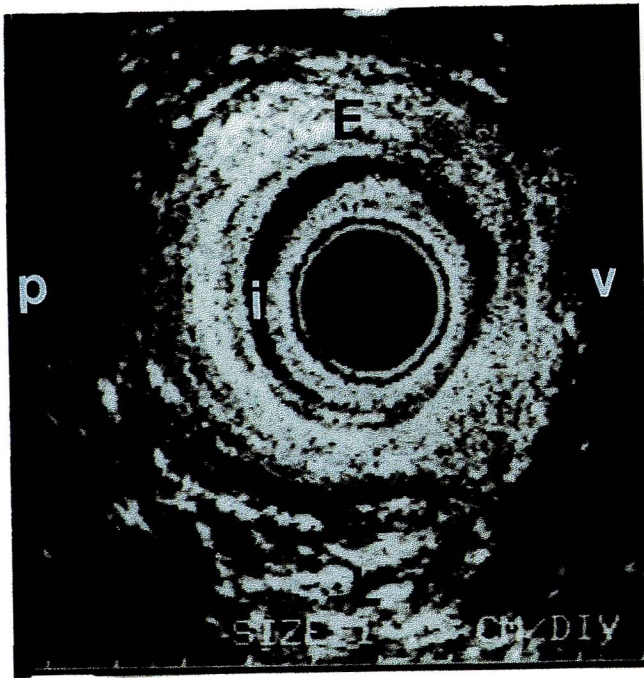
Altogether among the 127 women in the vaginal delivery group 13 (10 percent) developed either or both defaecatory symptoms after delivery.

### **7.2.5.1.2 Anal endosonography**

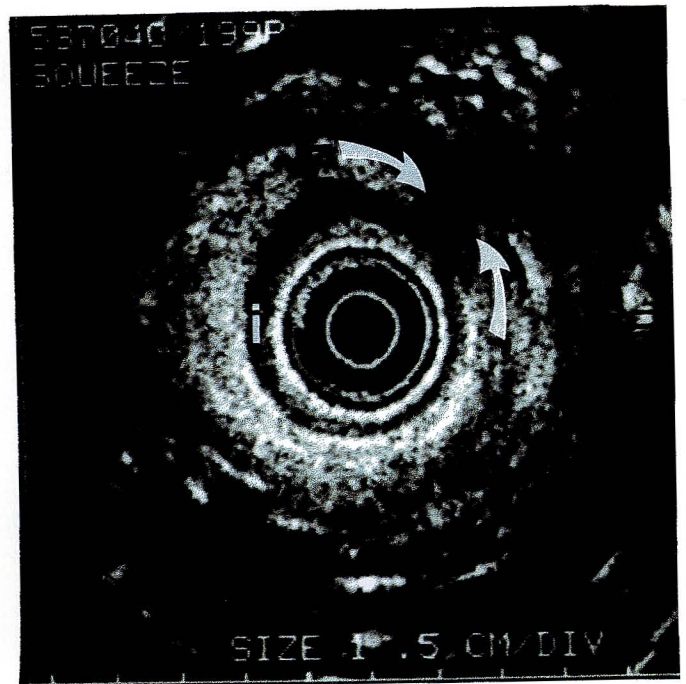
No sphincter defect was detected antenatally in any primiparous women. Six weeks postnatally, 28 (35 percent) had defects (Table IX) of either the external sphincter (Figs. 7.1a,b), internal sphincter (Figs. 7.1c,d), or both. Twenty three (29 percent) had an internal sphincter defect involving the entire length of the internal sphincter in 14 women and the distal portion in 9 women. Of the 15 women (19 percent) with external sphincter defects, the defects were full length in 11 women, proximal in 2

women and distal in two women. Nine women had only partial thickness defects and 6 had complete defects. Ten of the 15 women (13 percent) with an external sphincter defect also had an internal sphincter defect (Table IX).

Nineteen (40 percent) multiparous women had a sphincter defect antenatally and 21 (44 percent) postnatally (Table IX). Two women developed a new defect and 2 women with internal sphincter defects antenatally developed new external sphincter defects. All 3 multiparous women who reported new defaecatory symptoms after delivery had combined sphincter defects which were new in 2 women. All of these defects occurred anteriorly.



**Figure 7.1a**

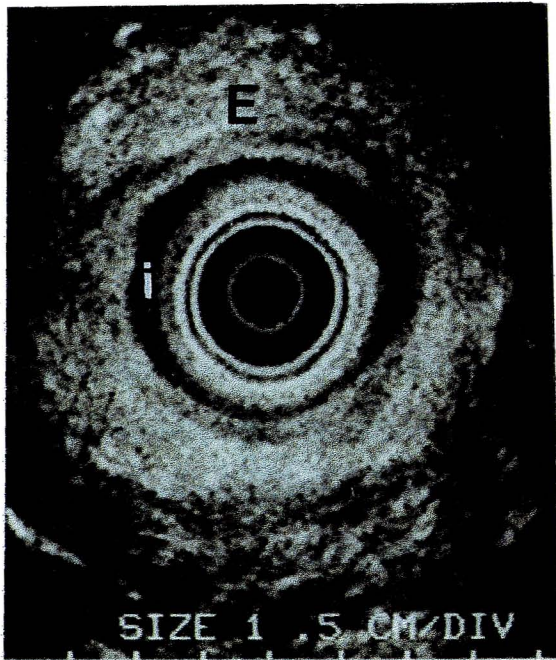


**Figure 7.1b**

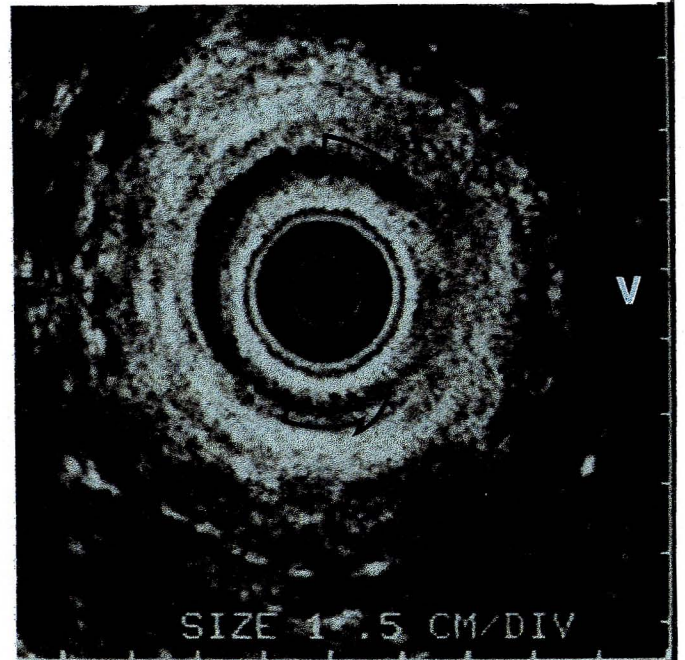
**Figures 7.1a & b** Anal endosonographic image before and after vaginal delivery demonstrating an external defect.

**Fig 7.1a** The normal anal endosonographic image of the mid-anal canal in a 32 year old primigravida at 34 weeks gestation. Post = posterior; L = left; E = external anal sphincter; v = vagina; i = internal anal sphincter.

**Figure 7.1b** Image of the same patient shown in Fig 7.1a six weeks after delivery. This patient suffered from incontinence to flatus following a forceps delivery with an episiotomy. The hypoechoic defect in the external anal sphincter is demonstrated between arrows. Damage to the anal sphincter was not recognised during repair of the episiotomy.



**Figure 7.2a**



**Figure 7.2b**

**Figures 7.2a & b** Anal endosonographic image before and after vaginal delivery demonstrating an internal sphincter defect.

**Fig 7.2a** Anal endosonographic image of the mid anal canal in a 24 year old primipara at 34 weeks gestation. The vagina (v) lies to the right of the images; E = external anal sphincter; i = internal anal sphincter.

**Fig 7.2b** Image of the same patient shown in Figure 2b six weeks after delivery. This woman was asymptomatic following a spontaneous vaginal delivery but sustained a second degree tear (not involving the anal sphincter). The hyperechoic internal anal sphincter defect is demonstrated between the open arrows.

#### 7.2.5.1.2.1 Relationship between defects and symptoms

All except one primiparous woman who developed either defaecatory symptom had a sphincter defect. There was a strong association between the development of incontinence ( $P < 0.001$ ; odds ratio, 20) or faecal urgency ( $P < 0.001$ ) and sphincter defects (Table X).

#### 7.2.5.1.3 Anal manometry

The maximum resting anal pressure fell significantly after delivery in both the primiparous and multiparous women (Table XI). It was also significantly lower in those with an internal sphincter defect as compared with those without such a defect (Table XII). The decrement (postnatal - antenatal values) in resting pressure after delivery was significantly greater in women with an internal sphincter defect than in those without (Table XII). The relationship between resting pressure and external sphincter defects was not statistically significant (Table XII).

The squeeze pressure fell significantly after delivery in both the primiparous and multiparous women (Table XI). It was also lower in those with an external sphincter defect as compared with those without (Table XII). The decrement in squeeze pressure after delivery was greater in those with an external sphincter defect than those without (Table XII). There was no relationship between squeeze pressure and internal sphincter defects (Table XII).

The 23 women who developed an internal sphincter defect had a significantly ( $P=0.01$ ) shorter antenatal anal canal length than the 56 women who did not develop a defect ( $36\pm 5$  v  $39\pm 5$  mm). No such relationship was found with external sphincter defects.

#### **7.2.5.1.4 Pudendal Nerve Terminal Motor Latencies (PNTML)**

PNTML were measured in 128 of the 202 antenatal women, of which 105 returned for the postnatal investigation. Fifty seven primiparae (mean age 27 years; range 19-35) and 32 multiparae (mean age 30; range 21-41) had a vaginal delivery. In 2 primiparae and 4 multiparae the PNTML were obtainable only on one side. Antenatal and postnatal comparisons in these women were made only on one side.

To obtain a normal range of physiological measurements, data from only antenatal nulliparous women without bowel symptoms ( $n=74$ ) were analyzed (Table XIII). One woman with a history of long standing constipation (less than two bowel motions a week) and three with excessive straining at stool were excluded from the normal value data (Table XIII).

##### **7.2.5.1.4.1 Primiparae (n=57)**

The PNTML was increased bilaterally following vaginal delivery (Table XI). When compared to the antenatal PNTML measurements only the postnatal readings showed a small and marginally significant difference between the right and left sides (Table XIV).

#### 7.2.5.1.4.2 Multiparae (n=32)

Five multiparae (16%) were incontinent at the time of their postnatal examination. The PNTML increased bilaterally following vaginal delivery (Table XI) and the asymmetrical difference in PNTML was similar to that found in primiparae (Table XIV).

#### 7.2.5.1.4.3 Primiparae and Multiparae (n=89)

In the vaginal delivery group as a whole, there was no significant difference between the mean PNTML measurements of the 8 incontinent women and the 77 asymptomatic women in whom PNTML were measured (Fig 7.3a). There was also no relationship between abnormal perineal descent and symptoms of anal incontinence. Nine primiparae (16%) and 5 multiparae (16%) had abnormal postnatal PNTML (above 2 SD from the antenatal mean) on either or both sides. In only half of these women was the PNTML raised on both sides. One primipara and 2 multiparae had abnormal PNTML antenatally and these worsened after delivery.

Twenty four (75%) of the 32 multiparae studied had had one previous vaginal delivery. In order to establish whether PNTML recovers with time, antenatal PNTML measurements of these 24 women (right:  $1.92 \pm 0.17$ ), left:  $1.99 \pm 0.17$ ) were also compared to the postnatal measurements of the 57 primiparae (Table XI). Although the difference was not significant ( $P=0.1$ ) there was a trend towards recovery.

Two (3.5 percent) primiparous and 1 (3 percent) multiparous women had abnormal latencies antenatally.

At 6 weeks post-partum PNTML were prolonged beyond the antenatal normal range in 9 primiparous women (14 percent) and 5 multiparous women (16 percent) at 6 weeks post-partum.

There was no association between the mean PNTML measurements of 10 women who had longstanding mild urinary stress incontinence [right  $2\pm 0.24$ ), left  $2.03\pm 0.27$ )] and the 77 that did not [right  $2\pm 0.21$ ), left  $2.08\pm 0.23$ )].

#### 7.2.5.1.5 Perineometry

Perineal descent increased significantly after vaginal delivery in both groups (Table XI).

##### 7.2.1.5.1 Primiparae (n=57)

The perineal plane at rest and straining was lower following delivery and the degree of descent increased significantly (Table XI). Twenty eight women who demonstrated abnormal perineal descent at their postnatal examination (perineal plane below the ischial tuberosities on straining) had significantly longer mean PNTML compared to the 28 women without abnormal perineal descent, (right:  $2.06\pm 0.26$ ) vs  $1.94\pm 0.21$ ) msec.,  $p<0.05$ ; left:  $2.13\pm 0.26$ ) vs  $2.0\pm 0.21$ ),  $p<0.05$ ). A simple linear regression analysis of the incremental difference (postnatal - antenatal values) in perineal descent against PNTML showed a significant relationship, particularly on the left side. For every unit increase in perineal descent the left PNTML increased by 1.4 msec ( $R^2=12.2\%$ ,  $p=0.008$ ) and the right PNTML by 0.91 msec ( $R^2=6.7\%$ ,  $p=0.05$ ).

There was no relationship between the change in the PNTML and the development of symptoms or anal manometric measurements. However there was a significant association ( $P=0.02$ ) between abnormal PNTML ( $n=10$ ) and the development of a sphincter defect in primiparous women.

#### **7.2.1.5.2 Multiparae (n=32)**

Although the perineal plane at rest in the multiparous group did not change significantly, the plane on straining and the degree of descent was increased at the postnatal examination (Table XI). All but 7 women showed abnormal perineal descent on straining.

**TABLE IX. Incidence of anal sphincter defects in women as detected by anal endosonography after vaginal delivery**

	NUMBER (percent) OF ANAL SPHINCTER DEFECTS			
	IAS ONLY	EAS ONLY	IAS & EAS	TOTAL
<b>PRIMIPAROUS WOMEN (n=79)</b>				
Antenatal	0	0	0	0
Postnatal	13 (16%)	5 (6%)	10 (13%)	28 (35%)
<b>MULTIPAROUS WOMEN (n=48)</b>				
Antenatal	8 (17%)	2 (4%)	9 (19%)	19 (40%)
Postnatal	7 (15%)	2 (4%)	12 (20%)	21 (44%)

IAS = internal anal sphincter; EAS = external anal sphincter

**Table X Association between symptoms of faecal urgency or anal incontinence and the presence of any anal sphincter defect after vaginal delivery in 127 women**

	INCONTINENT (n=11)	NOT INCONTINENT (n=116)	URGENCY (n=18)	NO URGENCY (n=109)
<b>Defect (n=49)</b>	10	39	18	31
<b>No defect (n=78)</b>	1	77	0	78
<b>Fisher's exact test</b>	P < 0.001		P < 0.001	

Both symptoms of faecal urgency and incontinence were strongly associated with the presence of a sphincter defect.

**TABLE XI. Anal manometry, perineometry and pudendal nerve motor function before and six weeks after vaginal delivery**

	ANTENATAL mean $\pm$ SD	POSTNATAL mean $\pm$ SD	P VALUE	95% CI OF DIFFERENCE
<b>Primiparae (n=79)</b>				
<u>Manometry (mm Hg)</u>				
Maximum resting pressure	61 $\pm$ 10	57 $\pm$ 12	<0.001*	1.7 to 6.4
Maximum squeeze pressure	88 $\pm$ 41	64 $\pm$ 36	<0.001*	17.3 to 30.1
<u>Perineal plane (cm)</u>				
At rest	1.8 $\pm$ 0.7	1.5 $\pm$ 0.7	<0.001*	0.18 to 0.50
At straining	0.6 $\pm$ 1.1	-0.2 $\pm$ 1.2	<0.001*	0.53 to 1.02
Descent	1.3 $\pm$ 0.7	1.7 $\pm$ 0.7	<0.001*	0.24 to 0.54
<u>Pudendal nerve terminal motor latency (msec)</u>				
Right (n=56)	1.91 $\pm$ 0.19	2.0 $\pm$ 0.22	<0.001*	0.04 to 0.13
Left (n=56)	1.96 $\pm$ 0.21	2.06 $\pm$ 0.24	<0.001*	0.06 to 0.13
<b>Multiparae (n=48)</b>				
<u>Manometry (mm Hg)</u>				
Maximum resting pressure	57 $\pm$ 12	53 $\pm$ 14	0.004*	1.3 to 6.5
Maximum squeeze pressure	60 $\pm$ 31	52 $\pm$ 22	0.006*	2.7 to 14.8
<u>Perineal plane (cm)</u>				
At rest	1.1 $\pm$ 1.0	1.0 $\pm$ 1.0	0.23	-0.08 to 0.33
At straining	-0.2 $\pm$ 1.2	-0.7 $\pm$ 1.0	0.001*	0.23 to 0.85
Descent	1.6 $\pm$ 0.6	1.8 $\pm$ 0.7	0.006*	0.08 to 0.42
<u>Pudendal nerve terminal motor latency (msec)</u>				
Right PNTML (msec) (n=30)	1.93 $\pm$ 0.16	2.01 $\pm$ 0.19	0.004*	0.03 to 0.13
Left PNTML (msec) (n=30)	1.99 $\pm$ 0.16	2.09 $\pm$ 0.23	0.006*	0.03 to 0.17

The maximum squeeze pressure is the maximum incremental rise in anal pressure above resting pressure.

Perineal descent is the difference between the plane of the perineum at rest and during a straining effort in relation to the ischial tuberosities. 95% CI = 95% confidence interval of the difference between antenatal and postnatal values. \* = Statistically significant difference.

**Table XII Relationship between anal manometry and the presence of sphincter defects six weeks after delivery in 79 primiparae**

<b>ANAL PRESSURES in mm Hg</b>	<b>IAS DEFECT (n=23)</b>	<b>IAS INTACT (n=56)</b>	<b>P VALUE</b>	<b>95% CI OF DIFFERENCE</b>
MRP (postnatal)	48 ± 10	61 ± 11	<0.001*	-18 to -7.1
▲ MRP	-9 ± 9	-2 ± 11	0.01*	-11.5 to -1.5
MSP (postnatal)	61 ± 32	66 ± 37	0.49	-11.0 to 22.6
▲ MSP	-29 ± 36	-21 ± 25	0.37	-9.4 to 24.4
	<b>EAS DEFECT (n=15)</b>	<b>EAS INTACT (n=64)</b>	<b>P VALUE</b>	<b>95% CI OF DIFFERENCE</b>
MRP (postnatal)	52 ± 13	59 ± 12	0.07	-13.3 to 0.6
▲ MRP	-8 ± 8	-3 ± 11	0.15	-10.3 to 1.6
MSP (postnatal)	44 ± 13	70 ± 38	<0.001*	14.3 to 37.3
▲ MSP	-47 ± 27	-18 ± 26	<0.001*	13.3 to 46.7

IAS = internal anal sphincter; EAS = external anal sphincter.

MRP = maximum resting pressure; MSP = maximum squeeze pressure.

▲, change between postnatal and antenatal values.

\* = statistically significant difference (P<0.05).

Figures are presented as means±SD and 95% confidence interval of the difference between values of women having an intact sphincter and those having a defect.

Women with an internal sphincter defect had a significant fall in their maximum resting pressure and women with an external sphincter defect had a significant fall in their maximum squeeze pressure.

**TABLE XIII** Antenatal perineal position and pudendal nerve terminal motor values from 74 healthy nulliparous women without altered bowel habit.

<b>Perineal Plane (cm. above ischial tuberosities)</b>	
At rest	1.9 ± 0.9
At straining	0.8 ± 1.1
Descent	1.1 ± 0.5
<b>Pudendal Nerve Terminal Motor Latency (msec)</b>	
Right	1.91 ± 0.19
Left	1.95 ± 0.20

Values represent mean ± SD

**TABLE XIV** Differences in pudendal nerve terminal motor latency measurements between the right and left sides (msec.)

	<b>RIGHT mean (SD)</b>	<b>LEFT mean (SD)</b>	<b>P VALUE</b>	<b>95% CI OF THE DIFFERENCE</b>
<b>Primiparae (n=55)</b>				
Antenatal	1.91 (0.22)	1.96 (0.22)	0.07	-0.09 to 0.01
Postnatal	2.00 (0.22)	2.06 (0.22)	0.03*	0.01 to 0.09
<b>Multiparae (n=28)</b>				
Antenatal	1.93 (0.16)	1.99 (0.16)	0.13	-0.02 to 0.14
Postnatal	2.01 (0.16)	2.09 (0.21)	0.03*	0.01 to 0.16

95% CI refers to the 95% confidence interval of the difference between right and left values. \* = significant.

### 7.2.5.1.6 Obstetric variables

#### 7.2.5.1.6.1 Relationship Between Defects and Obstetric Variables (Table XV)

A defect involving at least one of the sphincter muscles occurred in 8 (80 percent) of 10 women who had forceps deliveries (9 outlet and 1 rotational), but none of the 5 who had vacuum deliveries. All instrumental deliveries were carried out when the presenting part was below the ischial spines.

Two deliveries were complicated by shoulder dystocia, one of which was delivered by forceps; this latter woman developed an external sphincter defect. In addition, there was a twin delivery (no defects), a breech delivery (internal and external sphincter defect) and an occipito-posterior delivery (external sphincter defect).

Despite an intact perineum following delivery, 3 women still developed an internal sphincter defect. External sphincter defects were only detected in women who had an episiotomy or sustained a spontaneous perineal tear.

On univariate analysis, internal sphincter defects were significantly associated with forceps delivery ( $P=0.004$ ), epidural analgesia ( $P=0.005$ ) and the presence of an episiotomy ( $P=0.04$ ). With stepwise logistic regression analysis forceps delivery was associated with a statistically significant risk of developing an internal sphincter defect (odds ratio, 7). After controlling for this factor epidural analgesia did not contribute to the development of an internal sphincter defect.

External sphincter defects were univariately associated with augmentation of labour ( $P=0.03$ ), epidural analgesia ( $P=0.03$ ), postero-lateral episiotomy ( $P=0.02$ ) and forceps delivery ( $P=0.001$ ). On stepwise logistic regression analysis the single independent factor associated with the development of an external sphincter defect was forceps delivery (odds ratio, 11.1)

Infant weight, infant head circumference, induction of labour, the length of the different stages of labour, spontaneous perineal tears, maternal age and race were not significantly related to the development of sphincter defects.

As all normal deliveries apart from four were performed in the supine position the effect of various maternal positions on the development of anal sphincter damage could not be assessed. Furthermore all normal deliveries were conducted by midwives (apart from four delivered by medical students) and the more difficult and complicated ones by doctors. It would therefore be misleading to determine if more sphincter defects were associated with either group. For the same reason the experience of the operator repairing episiotomies and perineal tears was not analysed.

There was considerable discrepancy amongst women as to what constituted proper pelvic floor exercises and as this was not objectively assessed or randomised, this data was not analysed.

**TABLE XV The relationship between obstetric variables and the development of anal sphincter defects in 79 primiparae following vaginal delivery**

OBSTETRIC VARIABLE	NO OF WOMEN	NO OF WOMEN WITH SPHINCTER DEFECTS			
		IAS ONLY	EAS ONLY	IAS & EAS	TOTAL
<b>Non-instrumental vaginal deliveries (n=64)</b>					
Induction	6 (9%)	2	0	0	2
Augmentation	20 (31%)	4	2	2	8
Epidural	16 (25%)	5	1	2	8
Episiotomy	22 (34%)	4	2	3	9
2nd degree tears	24 (38%)	4	2	0	6
3rd degree tears	2 (3%)	0	0	2	2
No laceration	17 (27%)	3	0	0	3
<b>Instrumental vaginal deliveries (n=15)</b>					
Forceps	10 (67%)	2	1	5	8
Vacuum extractions	5 (33%)	0	0	0	0
Induction	8 (53%)	0	1	4	5
Augmentation	8 (53%)	1	1	4	6
Epidural	10 (67%)	1	1	5	7
Episiotomy	14 (93%)	2	1	5	8

IAS, internal anal sphincter; EAS, external anal sphincter.

All episiotomies were postero-lateral.

In both the instrumental and non-instrumental groups there is overlap between the obstetric variables, some women having more than one procedure.

#### 7.2.5.1.6.2 Relationship between obstetric variables and PNTML/ perineal descent

The following obstetric variables, when analyzed separately (by comparison of postnatal values and by assessment of the postnatal minus antenatal incremental change) were found not to be significantly associated with prolongation of PNTML or abnormal perineal descent in primiparae or multiparae: (1) age, height and weight; (2) induction of labour; (3) augmentation of labour; (4) epidural analgesia or pudendal block; (5) length of first, passive phase of second stage or third stage of labour; (6) episiotomy or perineal tears; (7) infant head circumference; (8) pelvic floor exercises (antenatal or postnatal); (9) instrumental vaginal delivery.

Five women in the primiparous group delivered babies of birthweight greater than 4 kg. The mean PNTML was significantly ( $P=0.03$ ) prolonged in these women compared to the 51 women who delivered babies of less than 4kg (Fig 7.3b).

The PNTML were also prolonged to a marginally significant degree ( $P=0.04$ ) in the 39 primiparae with an active second stage of labour greater than 30 minutes compared to the 17 primiparae with a shorter second stage (Fig 7.3c).

The duration of active pushing during the second stage of labour correlated significantly with the plane of the perineum at rest ( $P=0.04$ ,  $R=0.23$ ) and during straining ( $P=0.008$ ,  $R=0.30$ ), those women with a longer active second stage demonstrating greater descent.

Multiparae had a shorter second stage, but showed a similar detrimental effect on the

PNTML measurements when pushing was prolonged. The incremental increase in the right mean PNTML in the 9 multiparae who had been pushing for more than 15 minutes was significantly greater than in the 21 with a shorter second stage [0.2 (SD 0.15) v 0.03 (SD 0.09),  $P=0.01$ , 95% CI = 0.05 - 0.29].

There were 9 forceps and 6 vacuum deliveries in the vaginal delivery group as a whole. No significant differences were found in the incremental increase in mean PNTML measurements between the 15 instrumental deliveries (right,  $0.15\pm0.22$ , left  $0.11\pm0.09$ ) and the 74 spontaneous vaginal deliveries (right,  $0.07\pm0.13$ , left  $0.10\pm0.16$ ). These incremental differences were also not significant when the 6 vacuum deliveries (right,  $0.06\pm0.16$ , left  $0.09\pm0.09$ ) were compared to the 9 forceps deliveries (right  $0.20\pm0.24$ , left  $0.13\pm0.10$ ).

#### **7.2.5.2 CAESAREAN SECTION GROUP (n=23)**

No woman developed any defaecatory symptom following delivery. There were no new anal sphincter defects and manometry measurements did not change (Table XVI) following caesarean delivery.

Sixteen women in the caesarean section group (7 elective and 9 after the onset of labour) had PNTML measured. No significant change occurred in the elective caesarean section group. Two women belonging to the elective caesarean section group were multiparous and had had prior vaginal delivery.

#### **7.2.5.2.1 Elective caesarean section (n=7)**

There was no significant change in PNTML measurements or perineal descent (Table XVI) following delivery.

#### **7.2.5.2.2 Caesarean section after onset of labour (n=9):**

The mean PNTML was increased significantly only on the left although the trend on the right was similar (Fig 7.3d). In this group three women had abnormally prolonged latencies postnatally (2.4, 2.48; 2.32, 2.56; 2.24, 2.32; msec. right, and left sides respectively). These 3 labours were unique in that all were in labour for longer than 20 hours and the foetal head was engaged prior to delivery.

The plane of the perineum on straining was lowered following delivery (Table XVI).

**TABLE XVI** Anal manometry, perineometry and pudendal nerve motor function before and six weeks after caesarean section

	ANTENATAL mean±SD	POSTNATAL mean±SD	P VALUE	95% CI OF DIFFERENCE
<b>CAESAREANSECTION (n=23)</b>				
<u>Manometry (mm Hg)</u>				
Maximum resting pressure	62 ± 12	61 ± 13	0.29	-0.9 to 2.8
Maximum squeeze pressure	72 ± 32	71 ± 32	0.69	-4.5 to 6.7
<b>Elective caesarean section (n=7)</b>				
<u>Perineal plane (cm)</u>				
At rest	2.4 ± 0.7	2.3 ± 0.7	0.72	-0.09 to 0.13
At straining	1.4 ± 1.4	1.4 ± 0.7	0.47	-0.11 to 0.22
Descent	0.9 ± 0.2	1.0 ± 0.2	0.19	-0.14 to 0.13
<u>Pudendal nerve terminal motor latency (msec)</u>				
Right	1.97± 0.2	1.97± 0.2	1.00	-0.04 to 0.04
Left	1.92± 0.2	1.95± 0.2	0.08	-0.01 to 0.07
<b>Caesarean section after the onset of labour (n=9)</b>				
<u>Perineal plane (cm)</u>				
At rest	2.0 ± 0.9	1.8 ± 1.0	0.11	-0.04 to 0.38
At straining	0.9 ± 1.2	0.7 ± 1.3	0.05*	0.01 to 0.43
Descent	1.1 ± 0.6	1.2 ± 0.5	0.39	-0.17 to 0.07
<u>Pudendal nerve terminal motor latency (msec)</u>				
Right	1.94± 0.1	2.04± 0.2	0.12	-0.03 to 0.23
Left	1.94± 0.1	2.08± 0.3	0.01*	0.04 to 0.3

The 95% confidence interval of the difference between antenatal and postnatal values.

\* = Statistically significant difference.

Figure 7.3a

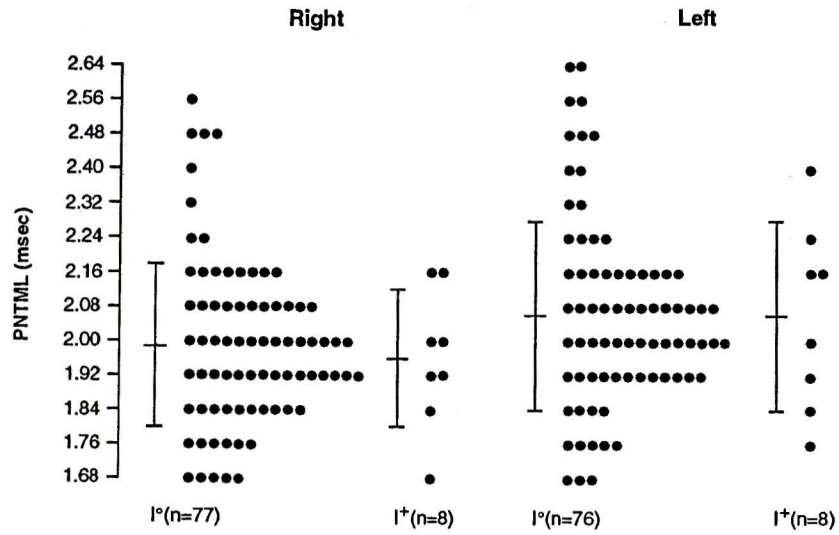


Figure 7.3b

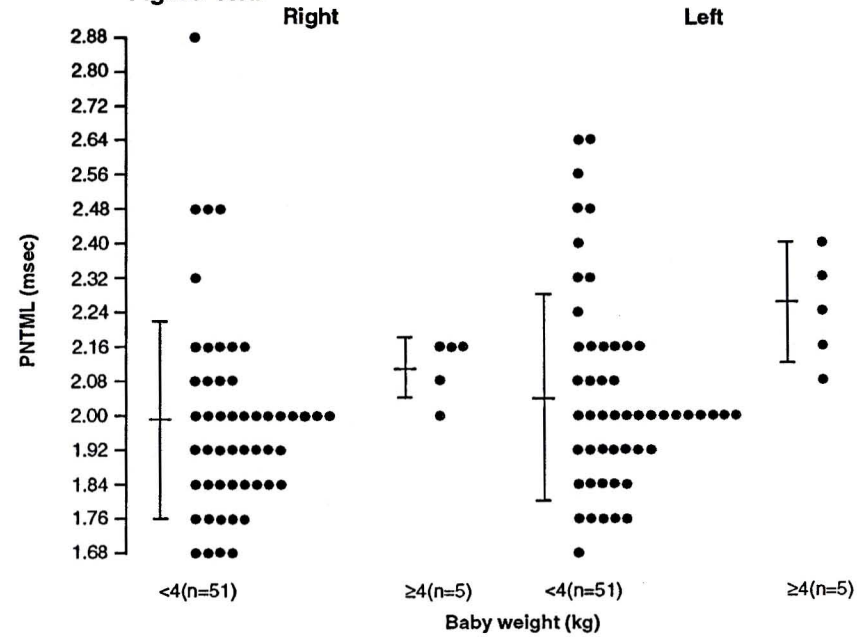


Figure 7.3c

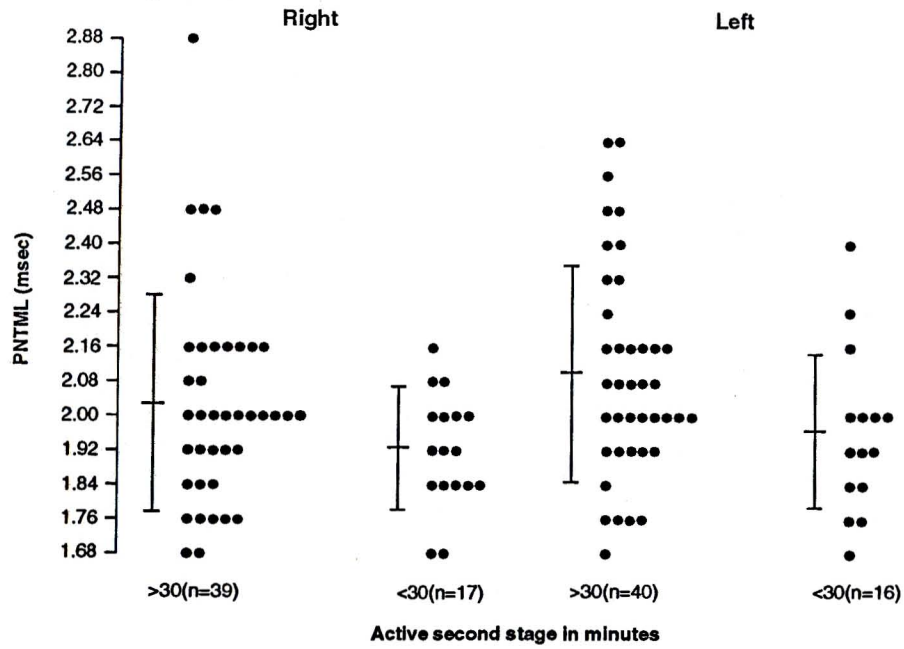
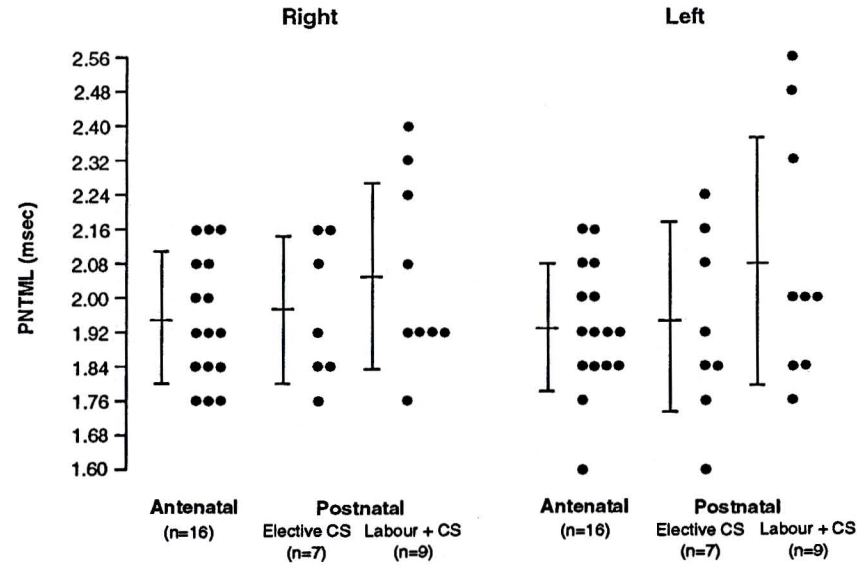


Figure 7.3d



**Figures 7.3a-d**

**Figs 7.3a Pudendal nerve terminal motor latency (PNTML) measurements in incontinent (I<sup>o</sup>) and continent women (I<sup>+</sup>).**

**Fig 7.3b PNTML measurements in women who had delivered babies weighing greater than and less than 4 kg.**

**Figure 7.3c PNTML measurements in women whose active second stage of labour lasted greater than and less than 30 minutes.**

**Figure 7.3d PNTML measurements in women (antenatal and postnatal) delivered by caesarean section. The postnatal measurements of those women who were delivered electively and those who had undergone labour before caesarean section was performed is shown separately**

### 7.2.5.3 Evaluation at Six months after delivery

Thirty two women returned at a mean time of 6 months after delivery for a third assessment. This group included 10 women with faecal urgency and 7 with anal incontinence at 6 weeks postnatally. In 4 of the 10 women, faecal urgency was no longer a problem but a further 2 women had developed the symptom. Two of the 7 women with anal incontinence had improved and another 1 (with no sphincter defect) had no further episodes of incontinence.

In all women with sphincter defects 6 weeks postnatally who had anal endosonography repeated at 6 months, the defects were unchanged.

Anal manometry did not significantly change from the readings taken at 6 weeks post-partum.

The pudendal nerve motor latencies were repeated in 22 women. There was a significant improvement in both the right ( $2.19 \pm 0.028$  vs  $2.06 \pm 0.028$  msec, 95 percent confidence interval, -0.2 to -0.05, 6 weeks vs 6 months postnatal,  $P=0.002$ ; and left ( $2.21 \pm 0.028$  vs  $2.17 \pm 0.028$ , 95 percent confidence interval, -0.24 to 0.01,  $P=0.04$ ) PNTML.

The PNTML had returned to normal in 8 of the 12 women who had abnormal measurements 6 weeks post-partum.

## 7.2.6 DISCUSSION

### 7.2.6.1 Anal sphincter defects

This study has indicated that vaginal delivery is frequently associated with mechanical disruption to the anal sphincters. Retrospective studies (Burnett et al 1991, Law et al 1990) have suggested that such damage is common in women presenting with faecal incontinence, but this is the first prospective study to document the true incidence of sphincter trauma in relation to childbirth, and establish associated clinical, neurological and physiological changes.

Two and a half percent of primiparae, but no multiparae had injury to the anal sphincters during delivery that was clinically apparent, i.e. a third degree tear. Endosonography however revealed sphincter damage in 35% and 44% respectively. The incidence of sphincter defects in primiparae postnatally was comparable to that in the multiparae antenatally, most of whom had only one previous vaginal delivery. There was only a slight increase in the multiparous group postnatally (4%), suggesting that the risk of sphincter damage does not follow a stepwise progression with each delivery, but is mainly associated with the first vaginal delivery.

Internal sphincter disruption was more frequent than external sphincter involvement (33% v 22%), and sometimes occurred when the perineum remained intact. The external sphincter by contrast was involved only in the presence of a tear or episiotomy. It is therefore possible that different mechanisms are involved. External sphincter damage occurs as part of a direct continuation of perineal disruption, in

contrast to the internal sphincter which can be damaged in isolation by shearing forces produced by descent of the baby's head. The increased vulnerability of the internal sphincter to sustain damage during vaginal delivery particularly when the external sphincter is intact can be explained by differences in the anterior anatomy of the external anal sphincter. As demonstrated in Section 4.4, the external sphincter in the female is shorter anteriorly and as the deep EAS slopes infero-medially to unite anteriorly, the IAS at this level is not covered by the EAS and therefore directly exposed to the descending presenting part of the foetus during childbirth. However as defects occurred more frequently in the distal anterior aspect of the internal sphincter, it would appear that most of the shearing postero-inferior force exerted by the baby's head during crowning is directed distally. Women with a shorter anal canal may be more prone to this trauma as there was a positive relationship between internal sphincter disruption and a shorter antenatal anal canal length.

The evidence from endosonographic examination suggests that the structural damage to the sphincters is permanent. There was no change at the 6 month re-assessment, and the incidence of defects in the postnatal primiparous group was similar to that in the antenatal multiparous group.

Identification of internal sphincter defects has become possible only with the application of endosonography to this region, prior to which no other means for detailed imaging existed. The nature of sonographic external sphincter defects has been verified using concentric needle EMG mapping (Sorensen et al 1988, Law et al 1990, Burnett et al 1991) and by histological confirmation (Section 5.2); the nature of

internal sphincter defects has been validated in patients having a lateral internal sphincterotomy for chronic anal fissure (Section 5.3).

A definite relationship has been demonstrated between the presence of an internal sphincter defect and a lower maximum resting pressure, and between the presence of an external sphincter defect and a lower maximum squeeze pressure. There was also a significant association between the presence of a defect and the development of defaecatory symptoms (Table X). These sphincter defects, based on endosonographic description, therefore appear to have true physiological and clinical significance.

However, the presence of a sphincter defect was not always associated with symptoms. In asymptomatic patients with a defect there may be enough residual intact sphincter to maintain continence. Long term follow up of these patients would be necessary to determine if they are at greater risk of developing incontinence later in life. As the peak incidence of faecal incontinence in women is in the fifth and sixth decade (Laurberg and Swash 1989), it could be that the cumulative effect of subsequent deliveries, the effects of ageing (Mc Hugh and Diamant 1987, Laurberg et al 1989, Haadem et al 1991), the menopause (Laurberg et al 1989, Haadem et al 1991) and the progression of a neuropathy (Snooks et al 1990) contribute to sphincter weakness in the long term. Those with an occult sphincter defect may be at greater risk.

Eight out of 10 primiparae who had a forceps delivery but none of the 5 delivered by the vacuum extractor (ventouse), developed a sphincter defect. These findings are consistent with other reports indicating that vacuum extraction is associated with less

maternal perineal trauma compared to forceps (Chalmers and Chalmers 1989, Johanson 1991). In a meta-analysis involving five randomised controlled studies of vacuum and forceps deliveries (Vacca and Kierse 1989), ventouse extraction was associated with a threefold decrease in the incidence of maternal injury.

#### **7.2.6.2 Defaecatory symptoms**

None of the women who developed any defaecatory disturbance had spontaneously complained of their symptom or sought medical attention. Under-reporting of such symptoms is well known (Browning and Motson 1983) and may explain why these problems are not widely appreciated in obstetric practice.

A sensation of faecal urgency usually relates to disturbed large bowel function. The cause for the increase in this symptom is not clear, although it was associated significantly with the presence of a sphincter defect (a sphincter defect was identified in every woman who admitted to urgency). Those women who sustain most trauma to the sphincter may also sustain interference with the nerves supplying the distal bowel, or with the distal bowel itself. However a more likely explanation for faecal urgency in women who sustain a sphincter defect would be the resultant sphincter weakness; under normal circumstances rectal distension by stool or flatus is accompanied by relaxation of the internal sphincter (recto-anal sphincter reflex). This allows for sampling of rectal contents by the sensitive anal epithelium (see Section 2.1.3). If the time is not appropriate, defaecation can be deferred by voluntary contraction of the external sphincter and displacement of the sample in a cephalad

direction. It is possible that in women with a sphincter defect, the consequent sphincter weakness and reduced sphincter tone allows the rectal contents to persist in the anal canal and stimulate the sensitive nerve endings. This could result in a sensation of faecal urgency.

### **7.2.6.3 Pudendal nerve damage and perineal descent**

This is the first prospective study that has measured the extent of perineal descent and PNTML prolongation before and after delivery, in both primiparae and multiparae. In previous studies (Snooks et al 1986, Allen et al 1990) PNTML were not measured antenatally and in one study (Snooks et al 1986) postnatal values were compared to control subjects. Neither of these studies demonstrated an increase in PNTML 2 months after delivery. In the present prospective study, commencing during pregnancy, we have shown that vaginal delivery, particularly the first, is associated with a significant increase in the PNTML at 6 weeks post-delivery. Two thirds of the women with an abnormally prolonged PNTML at 6 weeks post delivery had a PNTML within the normal range when restudied after 6 months; this suggests that the nerve damage is permanent in only a proportion of women.

The degree of perineal descent on straining increased after vaginal delivery in both primiparae and multiparae, but the plane of the perineum at rest in multiparae did not change significantly after delivery. This would suggest that most of the pelvic floor stretching and weakness occurs with the first vaginal delivery. Jones et al (1987) demonstrated a relationship between PNTML and perineal descent during straining

in patients with idiopathic faecal incontinence. In the present study a relationship was demonstrated between the incremental difference (postnatal - antenatal values) in perineal descent on straining and the incremental change in PNTML, particularly on the left side. This is the first direct evidence to suggest that perineal descent related to vaginal delivery is associated with prolongation of the PNTML, supporting the concept that perineal descent can cause pudendal nerve damage (Lubowski et al. 1988a).

Snooks et al (1986) reported a significantly greater increase in the PNTML 48 hours after forceps delivery compared to women delivered vaginally without forceps. These were all postnatal measurements. In this study, we analyzed the incremental difference between antenatal and postnatal PNTML measurements; although the vaginal delivery group as a whole demonstrated an increase in the PNTML after delivery, no significant difference was found between the normal delivery and forceps delivery group. Similarly, there was no significant difference between PNTML increments in women who were delivered by forceps compared to the vacuum extractor. These two methods of assisted vaginal delivery although small in number have not been compared previously in relation to the pelvic floor damage with which they may be associated.

The finding of an association between prolonged PNTML and a large baby (> 4kg) as well as a longer active second stage of labour confirms the important contribution of these factors to pelvic floor nerve damage (Snooks et al. 1986; Allen et al. 1990).

Previous short term studies (Snooks et al. 1986, Allen et al. 1990) have evaluated pelvic nerve damage using the mean PNTML (mean of right and left PNTML). This method of analysis does not take into consideration the possibility of asymmetrical involvement of the pudendal nerves, as demonstrated by Lubowski et al (1988b). Although we found no difference between each side in antenatal PNTML measurements, there was a small but significant difference postnatally. Snooks et al (1990) in their 5-year follow-up of multiparous women also noted a similar asymmetrical extent of prolongation of the PNTML. In the present study the antenatal PNTML values for multiparae did not show a significant difference between each side. The reason for asymmetric damage to the pudendal nerves is unknown, but probably relates to unequal traction on the two pudendal nerves as the fetal head descends through the pelvis. It is unknown whether nerve damage on one side is as likely as bilateral damage to produce long term muscle pathology, although even a unilateral pudendal neuropathy can be associated with faecal incontinence (Lubowski et al 1988b).

If the mean bilateral PNTML had been the basis for my calculations, rather than separate analysis on each side, at least one third of prolonged PNTML measurements would have been missed. This is in keeping with the findings of Lubowski et al (1988b).

Although 16 women in the caesarean section group had PNTML measurements, the smaller numbers following subdivision into an elective and labour group would suggest that interpretation of the results must remain tentative. I found no difference in the

PNTML following an elective caesarean section, in keeping with earlier findings by Snooks et al (1986). This indicates that pregnancy per se is not the cause of pudendal nerve damage. However, it has not been previously shown that the PNTML can be prolonged in women having a caesarean section after the onset of established labour as shown in this study. Although none of these women with pudendal neuropathy had begun active pushing, all had been in labour for more than 20 hours and the fetal head had been engaged (below the level of the ischial spines) prior to being delivered by caesarean section. It would therefore appear that obstetric related pudendal nerve damage can occur as a result of vaginal delivery or during the process of labour, and women who have a caesarean section after the onset of labour can also be at risk of developing pudendal nerve damage. Allen et al (1990) demonstrated greater denervation and re-innervation of the external anal sphincter in 5 women who had a caesarean section in labour compared to 3 women who had an elective caesarean section. Although a larger number of women having a caesarean section during labour need to be studied prospectively to confirm these findings, it is impossible to predict which patients will proceed to have a caesarean section after the onset of labour.

In this study there was no association between a prolonged PNTML or abnormal perineal descent and symptoms of anal incontinence at 6 weeks post-partum. This would lend support to the hypothesis that neurogenic faecal incontinence is usually the end result of a long standing or progressive pudendal neuropathy rather than the consequence of an acute event. The prolongation of PNTML in association with a sphincter defect probably reflects a common traumatic aetiology rather than a causal

relationship. The development of symptoms of anal incontinence in the short term is therefore more likely to be due to mechanical trauma to the anal sphincters. The onset of symptoms later in life is probably due to the combined effects of occult trauma to the anal sphincters and the progression of neuropathy. These women need to be studied over many years to establish the clinical relevance of obstetric related pelvic floor nerve damage.

In conclusion, vaginal delivery causes bowel symptoms, mechanical sphincter trauma, and nerve damage in many women. An increased awareness of these changes is needed, as altered bowel function is usually not recognised clinically and women rarely complain about it voluntarily. The use of the obstetric forceps is particularly associated with a high risk of sphincter damage.

## SECTION 7.3

### THIRD DEGREE OBSTETRIC ANAL SPHINCTER TEARS: RISK FACTORS AND OUTCOME OF PRIMARY REPAIR

#### 7.3.1 INTRODUCTION

The incidence of recognised anal sphincter disruption following vaginal delivery appears to be related in part to the method of episiotomy. In a detailed review of the English literature between 1860 and 1980, Thacker and Banta (1983) reported an incidence of third degree tears of between 0 and 6.4% when no episiotomy was performed, 0.2 and 23.9% after a midline episiotomy, and 0 and 9% following mediolateral episiotomy.

Primary repair of the sphincter is usually conducted by obstetricians and the immediate outcome has been previously reported as good. In 5 separate older studies (Ingraham et al. 1949; Flemming 1959; Barter et al. 1960; Seiber and Kroon 1961; O'leary and O'Leary 1964) no case of anal incontinence was reported at 6 weeks postpartum in a total of 2195 repaired third degree tears. However, most of these studies were retrospective. More recently, 3 Scandinavian studies (Haadem et al. 1988; Sorensen et al. 1988; Neilsen et al. 1992) involving a total of 70 patients reported symptoms of anal incontinence in 29 to 48% of women 3 months to 3 years after primary sphincter repair.

This study aimed to determine the risk factors associated with the development of third degree tears, and the success of primary sphincter repair with respect to defaecatory symptoms and anal sphincter function.

## **7.3.2 METHODS:**

A tear was classified as third degree if the anal sphincter was torn, with or without a breach of the anal epithelium.

### **7.3.2.1 Risk factors for third degree tear**

During a 31 month period between 1989 and 1992 there were 8553 vaginal deliveries of which 50 (0.6%) women sustained a third degree tear (as documented in the labour ward delivery book and computer records). Thirty two women were white, 15 black and 3 were of Asian origin.

The details of all 8553 deliveries were analyzed retrospectively with respect to parity, induction of labour, use of epidural analgesia, foetal position and presentation, instrumental delivery, shoulder dystocia, and birth weight.

### **7.3.2.2 Outcome of primary sphincter repair**

#### **7.3.2.2.1 Subjects**

Thirty four of these 50 women who had sustained a third degree tear agreed to be interviewed and investigated. Two of the remaining 16 women were pregnant at the time of the study and declined participation, while the other 14 women could not be traced. The obstetric factors in these 16 women were similar to those of the 34 women who participated in the study. The 34 women comprised 30 primiparae (88%) and 4

multiparae (12%) all of whom had 2 previous vaginal deliveries. Eighteen women were white, 14 black and 2 were of Asian origin and had a mean age of 26 years (range 18-37).

The women were assessed at a median time of 49 days (range 42-651 days) after delivery. Six women who were investigated less than 2 months after delivery were re-examined 6 months after delivery. A questionnaire was completed at each visit (Appendix B). The frequency of bowel motions, the presence of straining of more than 25% of the time at stool, faecal urgency (inability to defer a bowel action for more than 5 minutes), and incontinence to flatus, liquids or solids were recorded. The type of anaesthesia and suture material used for the repair, and the use of post-operative antibiotics, were also noted.

#### **7.3.2.2.2 Controls**

Seventy seven (88%) consecutive consenting primiparae who had one vaginal delivery and 11 (12%) multiparae who had 2 previous vaginal deliveries formed the control group (Section 7.2). None of these women sustained a third degree tear. Women in the study group and control group were matched for parity, age and ethnicity, and were not significantly different with respect to age or time from delivery to assessment. They were studied at a median time of 49 days (range 36 - 630) after their first vaginal delivery.

#### **7.3.2.2.3 Investigations**

The following investigations (similar to that used in the previous study in 7.2) anal

manometry, anal endosonography, pudendal nerve terminal motor nerve latency studies and perineometry were performed. To overcome any bias, the stored sonographic images were also reported independently by a consultant radiologist who was unaware of the patients' obstetric history or symptoms.

#### **7.3.2.2.4 Statistical analysis**

Continuous and categorical data in the study and control group were compared using the two sample t test and Fisher's exact test respectively.

### **7.3.3 RESULTS**

#### **7.3.3.1 Risk factors for third degree tear**

All 50 women with a third degree tear had delivered beyond 36 weeks gestation and all had had a cephalic presentation. None of the 95 vaginal breech deliveries during the same period had sustained a third degree tear. Forceps delivery (Relative Risk, 13.3), primiparity (Relative Risk, 7), a birth weight of greater than 4 kg. (Relative Risk, 2.9) and an occipito-posterior position at delivery (Relative Risk, 4.4) were all significantly more common in women who sustained a third degree tear compared to those women who did not (Table XVII).

It is possible to sustain a third degree tear without any of the mentioned risk factors. Of the 50 women who sustained a third degree tear 3 had none of the risk factors, 17 had one risk factor, 24 had two risk factors and 6 had three risk factors. Ninety-four percent

of women with a third degree tear had at least one risk factor. However, it may still not be possible to predict who will sustain a tear, as they occur in less than one percent of all vaginal deliveries.

Although 35 of the 50 (70%) women who developed a third degree tear had had a postero-lateral episiotomy, the majority of these were associated with forceps delivery. Delivery was achieved with forceps (Simpsons 23, Kiellands 2) in 25 (50%) women. Sixteen of these women were delivered by a registrar and 9 by a senior house officer under supervision. All women had had a postero-lateral episiotomy performed prior to forceps delivery. The anorectal mucosa was involved more frequently during forceps delivery (12 of 25, ie. 48%) than in non-instrumental deliveries (8 of 25, ie 32%) but this difference was not statistically significant.

In contrast no third degree tear occurred during 351 vacuum extractions (4% of all vaginal deliveries).

Sixteen of the 25 women in the non-instrumental delivery group were delivered by qualified midwives, and 9 by student midwives under supervision. In 11 of these 25 (44%) women an episiotomy had been performed, and the remaining 14 (56%) sustained a spontaneous third degree tear; the obstetric risk factors did not differ in frequency between these two groups.

Table XVII Relationship between obstetric factors and third degree tears.

OBSTETRIC VARIABLE	THIRD DEGREE TEARS (n=50)	P VALUE	RELATIVE RISK ESTIMATES (95% Confidence Intervals)
Forceps delivery (n=600)	25 (4.2%)	0.00001*	13.3 (7.7 to 23)
Non-Forceps delivery (n=8003)	25 (0.3%)		
Primiparae (n=3698)	42 (1.1%)	0.00001*	7 (3.3 to 14.8)
Multiparae (n=4905)	8 (0.2%)		
Baby weight $\geq$ 4kg (n=681)	11 (1.6%)	0.00002*	2.9 (1.5 to 5.8)
Baby weight < 4kg (n=7922)	39 (0.5%)		
Persistent occipito-posterior position (n=170)	5 (2.9%)	0.003*	4.4 (1.6 to 12.2)
Non occipito-posterior position (n=8443)	45 (0.5%)		
Induction of labour (n=1157)	11 (1%)	0.07	1.8 (0.9 to 3.5)
Spontaneous labour (n=7446)	39 (0.5%)		
Shoulder dystocia (n=162)	2 (1.2%)	0.24	2.2 (0.5 to 8.6)
No Shoulder dystocia (n=8441)	48 (0.6%)		
Epidural analgesia during labour (n=1871)	11 (0.6%)	1.00	1 (0.5 to 2)
No epidural (n=6732)	39 (0.6%)		

\* denotes statistically significant difference between those who sustained a third degree tear and those that did not (Fisher's exact test).

### **7.3.3.2 Outcome of primary sphincter repair**

#### **7.3.3.2.1 Details of sphincter repair**

The primary sphincter repair was performed by a registrar or senior registrar in all cases. Twenty two of the 34 women had a sphincter repair performed under regional (spinal, epidural or caudal) or general anaesthesia. The remaining 12 were repaired under local anaesthesia (pudendal block).

Repair usually involved inserting 2 or 3 "figure of eight" sutures to approximate the torn ends of the sphincter. Chromic catgut was used in 23 women and polyglycolic acid (Vicryl) or polyglactin sutures (Dexon) in 11 women. Repair of torn anal epithelium was performed separately by means of interrupted sutures, with the knots in the anal canal. All women who sustained a third degree tear which involved the anal epithelium were prescribed a 1 week course of a broad spectrum antibiotic following repair. A stool softener (lactulose) was also prescribed for 7 to 14 days.

Wound infection requiring antibiotics occurred in 6 women, 3 of whom had already taken a course of prophylactic antibiotics. Two of these women developed fistulae (1 anovaginal and 1 rectovaginal). There was no significant association between the use of antibiotics, occurrence of wound infection, form of anaesthesia for repair, or the type of suture material used and the outcome in terms of the later development of symptoms, anal manometry measurements or the development of sphincter defects.

### 7.3.3.2.2 Defaecatory symptoms

Sixteen (47%) women with a third degree tear had defaecatory symptoms at the time of examination: 14 (41%) anal incontinence (11 to flatus only and 3 to flatus and liquid) and 9 (26%) faecal urgency (7 of these 9 women also suffered from anal incontinence). One of these women with incontinence also had a rectovaginal fistula, and another had an anovaginal fistula (Fig 7.4b). A further 3 women admitted to temporary symptoms lasting for a few weeks after delivery.

Among the controls 11 (13%) women had defaecatory symptoms: anal incontinence in 5 (flatus 3, flatus and liquid stool 2, faecal urgency 8 of whom 2 also had anal incontinence).

### 7.3.3.2.3 Anal endosonography

Twenty nine (85%) of the 34 women with a third degree tear had sonographic sphincter defects (1 involving the internal sphincter alone, 5 involving the external sphincter and 23 involving both anal sphincter muscles). All 19 symptomatic women, in addition to the 3 with temporary symptoms, had combined internal sphincter and external sphincter defects (Fig 7.4a). There was a significant association between incontinence and both internal sphincter defects ( $p < 0.01$ ) and external sphincter defects ( $p < 0.025$ ).

Twenty nine (33%) of the 88 controls were found to have sphincter defects (14 internal sphincter alone, 5 external sphincter alone, and 10 both).

In the women who had experienced a third degree tear the sphincter defects were

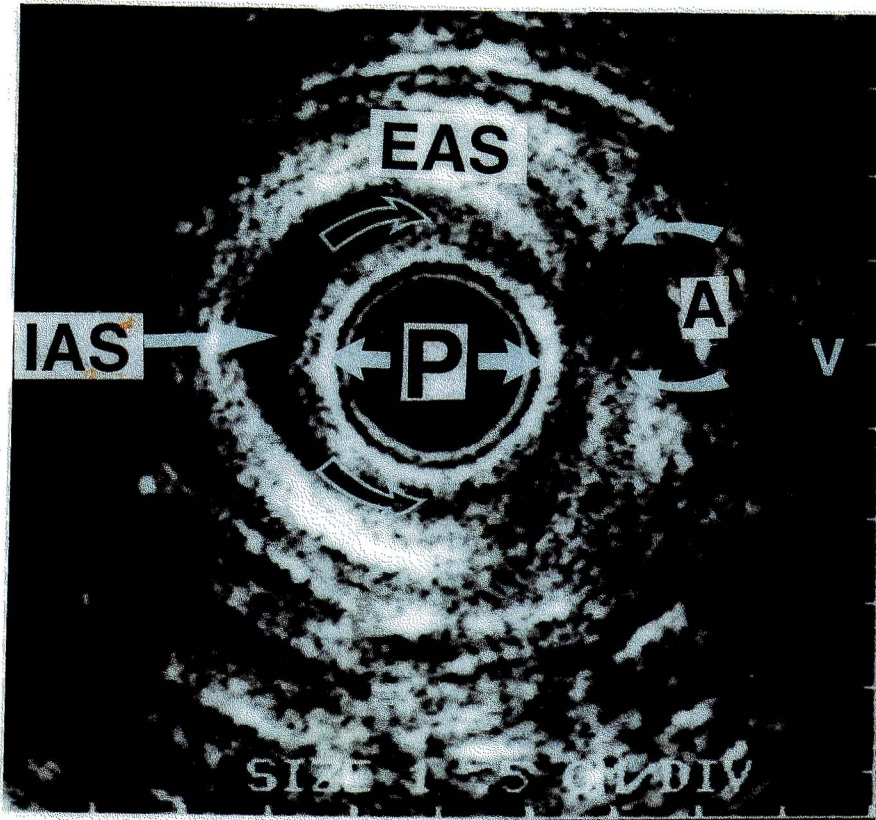
usually along the full length of the sphincter, in contrast to the control women who usually had a defect involving only a part of the sphincter length.

Figs 7.4a and 7.4b

# Primary Sphincter Repair

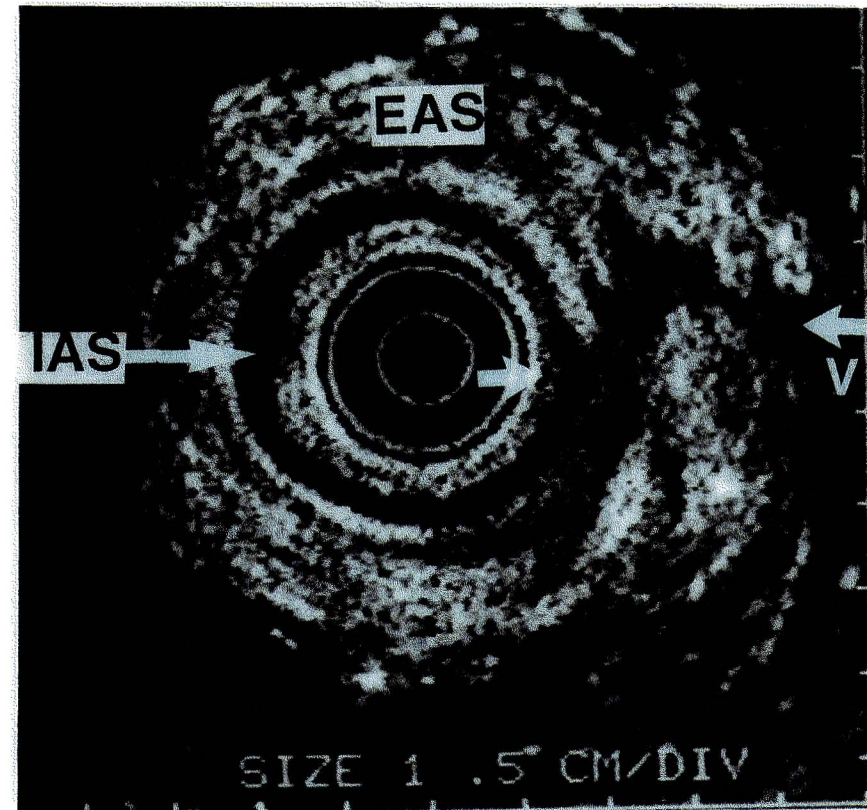
Anal endosonographic appearance 6 weeks after delivery

## EAS & IAS Defect



IAS Defect between open arrows. A = EAS Defect

## Anovaginal Fistula



Fistula track shown between arrows

Scans performed in the left lateral position. Anterior is to the right of the image. EAS= External Anal Sphincter; IAS= Internal Anal Sphincter; V= Vagina; P= Probe

#### 7.3.3.2.4 Anal manometry

Compared to the control group the women who experienced a third degree tear had a significantly lower maximum resting pressure, maximum squeeze pressure and a shorter anal canal length (Table XVIII). The maximum resting pressure was significantly lower in the 14 women complaining of faecal incontinence compared to the 20 who were continent [ $35\pm 10$  v  $50\pm 15$  mmHg, mean $\pm$ SD,  $P=0.002$ , 95% CI of the difference, 6 to 24]. No significant difference was observed in relation to the maximum squeeze pressure.

The 24 women with an internal sphincter defect had a lower maximum resting pressure compared to the 10 in whom it was intact [ $40\pm 12$  v  $53\pm 18$ ,  $P= 0.05$ , 95% CI, 0.3 to 27]. There was no significant relationship between anal pressures and the presence of an external sphincter defect.

#### 7.3.3.2.5 Pudendal nerve terminal motor latency (PNTML)

Thirty one of the 34 women who sustained a third degree tear and 79 of the control group had PNTML measurements performed. No significant differences were found between the third degree tear and control groups (Table XVIII).

**Table XVIII Anal manometry and pudendal nerve terminal motor latency (PNTML) measurements in control women having a vaginal delivery without a third degree tear and women who sustained a third degree tear (TDT).**

	<b>CONTROLS (n=88)</b>	<b>THIRD DEGREE TEARS (n=34)</b>	<b>P VALUE</b>	<b>95% CONFIDENCE INTERVAL OF DIFFERENCE</b>
<b>Anal manometry</b>				
Anal length (cm)	3.8 (0.5)	3.3 (0.5)	0.0001*	0.2 to 0.6
Resting pressure (mmHg)	58 (13)	44 (15)	0.0001*	8 to 20
Squeeze Pressure (mmHg)	63 (35)	34 (15)	0.0001*	20 to 38
<b>PNTML (msec)</b>				
Right	2 (0.2)	1.9 (0.2)	0.17	0 to 0.2
Left	2.1 (0.2)	2 (0.2)	0.06	0 to 0.2
<b>Perineal plane (mm)</b>				
At rest	14 (1)	14 (1.1)	0.82	-0.4 to 0.5
At straining	-0.2(1.3)	0 (1.3)	0.54	-0.4 to 0.7)
Descent	16 (0.7)	14 (0.8)	0.4	-0.4 to 0.2

Values represent mean (SD)

\* denotes statistical significance.

PNTML was measured in 79 women in the control group and 31 women in the third degree tear group.

#### 7.3.3.2.6 Perineometry

The plane of the perineum both at rest and on straining as well as the degree of descent did not differ significantly from the control group (Table XVIII). There was no association between defaecatory symptoms and the degree of perineal descent. However the plane of the perineum was lower ( $P=0.01$ ) both at rest and on straining in women who developed internal or external sphincter defects.

No association was demonstrated between perineometry and anal manometry measurements by linear regression analysis.

However, for every unit increase in perineal descent, there was an increase in PNTML of 0.1 msec. on both the right and left side ( $SD=0.05$ ;  $p=0.03$ ).

#### 7.3.3.2.7 Six month follow-up

Six women who were initially studied prior to two months after delivery had anal endosonography performed again 6 months after delivery. The sphincter defects were found to be unchanged.

### 7.3.4 DISCUSSION

Third degree tears are an uncommon complication of childbirth, occurring in 0.6% of vaginal deliveries in this study, a similar incidence to that reported previously (Sorensen et al. 1988, Haadem et al. 1991). Until recently (Sorensen et al 1988, Haadem et al 1990, Nielsen et al 1992), the outcome of primary sphincter repair following a third degree tears was reported as good (Ingraham et al. 1949; Flemming 1959; Barter et al. 1960; Seiber and Kroon 1961; O'leary and O'Leary 1964). However in the present study approximately half the women with such a tear continue to experience some impairment of anal continence despite a primary sphincter repair.

This is the first study to demonstrate the outcome of primary sphincter repair with anal manometry, endosonography, pudendal nerve motor latency measurements and perineometry.

#### 7.3.4.1 Risk Factors for Third Degree Tears

In keeping with other studies, (Gass et al. 1986, Green and Soohoo 1989, Sorensen et al. 1988, Haadem et al. 1991) I have found that nulliparous women were more at risk of sustaining a third degree tear than women who had had a previous vaginal delivery. This probably relates to relative inelasticity of the perineum (Fischer 1979, Combs et al. 1990). If other risk factors are also present the attending obstetrician should anticipate the possibility of a major tear.

Half the women who sustained a third degree tear were delivered by forceps, although

this complication occurred in only 4 percent of all forceps deliveries. In contrast, during the same period no third degree tear occurred following a vacuum extraction. I have previously shown by anal endosonography (Section 7.1) that 80 percent of primiparae delivered by forceps develop subclinical sphincter defects. In that prospective study no defects were identified following a vacuum extraction. Johanson et al. (1993) in their randomised study of 600 women found a significantly higher incidence of maternal injuries after forceps delivery compared with vacuum delivery. The use of forceps therefore appears to be a major determinant of sphincter damage and supports the opinion that the vacuum extractor should be the instrument of choice (Chalmers and Chalmers 1989).

Forty two percent of the women who had a non-instrumental delivery sustained a third degree tear despite a postero-lateral episiotomy. There were no significant differences in other obstetric variables such as baby weight, position of the occiput and length of labour between these women and the remaining 52% who did not have an episiotomy. This finding although observational, supports recent speculation regarding the merits of an episiotomy especially in preventing damage to the anal sphincters (Thacker and Banta 1983, Sleep et al 1984, Gass et al 1986, Green and Soohoo 1989, Thorp and Bowes 1989, Combs et al 1990, Shiono et al 1990, Larsson et al 1991, Walker et al 1991, Henriksen et al 1992). However, factors such as operator expertise and the timing and size of episiotomy are complex variables that need further evaluation.

In a randomised prospective study of 407 primiparae, Coats et al (1980) found that

midline episiotomies were associated with 11.6% of third degree tears compared to 2% with mediolateral episiotomies. Shiono et al. (1990) reported that women who had a midline episiotomy were 50 times more likely to sustain a third degree tear and women who had a mediolateral episiotomy 8 times more likely than were women who did not have an episiotomy. Sleep et al (1984) concluded from their randomised trial that an intact perineum was more likely when a restrictive rather than a liberal policy of performing mediolateral episiotomies was employed. Nugent and Reading (1935) studied 202 primiparae who underwent a forceps delivery; 130 women had an episiotomy and 72 delivered with an intact perineum. No difference was noted in the incidence of third degree tears when an episiotomy was performed selectively.

The benefit of an episiotomy in the prevention of another third degree tear in the same woman has not been established. In current practice, an elective episiotomy is recommended in women who had sustained a previous third degree tear. Ingraham et al (1949) reported that none of the 19 women in their series who had a previous third degree tear had another tear in a subsequent delivery. The operator was not aware of the woman's previous history of a third degree tear and an episiotomy was performed in only 5 women. In the present study thus far, 4 women had a further delivery after a previous third degree tear. Although an episiotomy was not performed in a subsequent delivery in all 4 women, 2 had sustained third degree tear and 2 had not; one woman had an intact perineum despite delivering a 5.9 Kg baby at home.

#### **7.3.4.2 Outcome of Primary Sphincter Repair**

Third degree tears have previously not been regarded as a major complication of

childbirth (Ingraham et al. 1949; Flemming 1959; Barter et al. 1960; Seiber and Kroon 1961; O'leary and O'Leary 1964). However we have demonstrated that approximately half the women with such a tear continue to experience some impairment of anal continence, despite a primary sphincter repair. The cause of anal incontinence is persistent mechanical sphincter disruption rather than pudendal nerve damage.

Three smaller studies of third degree tears with anal manometry (Sorensen et al 1988, Haadem et al 1990, Nielsen et al 1992) have been described. The findings of the present study concur with that reported by Haadem et al (1990) in that both the resting and squeeze pressures were significantly lower in the study group compared to controls. Furthermore the resting pressure was lower with anorectal mucosa disruption (Haadem et al. 1987) in keeping with internal anal sphincter damage. Neilsen et al (1992) identified external sphincter defects in 54% of women who had a primary sphincter repair using anal endosonography and EMG studies.

A poor functional result from primary repair may relate to failure of identification of the components of the sphincter and hence incomplete union along the full sphincter length. The shorter anal canal length in women who had a sphincter repair would support this explanation. Alternatively the inherent tone in the sphincter muscles may cause the approximated torn ends of the muscle to retract. Technical differences in surgical technique may also be important; it has not been determined whether the most effective repair involves simple approximation (Blaisdell 1940) or overlap of the muscle ends,(Browning and Motson 1983) nor whether separate repair of the internal anal sphincter should be undertaken. In addition, some have attempted to unite the

puborectalis muscle at the apex of the perineal body (Corman 1980, Pezim et al 1987).

No study has ascertained whether outcome could be improved if primary repair were undertaken by an experienced obstetrician or surgeon experienced in sphincter surgery, or if the repair was delayed. These factors and other aspects of postoperative management, need to be addressed prospectively.

In the present study all the women with impaired continence had sonographic defects in both sphincter muscles, an appearance which has been previously validated to accurately reflect the presence of defects (Section 5.2, 5.3). Functional sphincter impairment, as demonstrated by significantly lower anal pressures, was also evident.

It has been previously shown that vaginal delivery results in prolongation of pudendal nerve terminal motor latencies (Section 7.1), indicating damage to the fast conducting fibres of the pudendal nerve. However, compared to matched controls women who sustained a third degree tear in this study showed no significant difference in their latency measurements. Snooks et al (1985) reported that 40% of women who had a previous third degree tear and subsequently presented with faecal incontinence had prolonged PNTML. In this study only 3 out of 31 women (10%) were found to have an abnormally prolonged PNTML ( $> 2$  SD from the mean). This could be explained by the fact that in their study only incontinent women were selected and the mean period of follow up was 4,3 years (range 1 to 20 years). It has been previously been shown that PNTML can deteriorate with time (Snooks et al. 1990) and ageing (Laurberg et al 1989). As 47% of women were symptomatic in the present study and

only 10% had abnormal PNTML it would suggest that the major factor in the development of defaecatory symptoms is the mechanical trauma rather than pudendal nerve damage.

Sonographic defects were identified in some asymptomatic women with a third degree tear and also some women in the control group. The occurrence of occult sphincter damage in approximately a third of women having their first vaginal delivery has been previously documented in a prospective study (Section 7.2). In women without a third degree tear such lesions could be due to extrinsic blunt trauma during "crowning" of the fetal head, or due to an unrecognised extension of a second degree tear or episiotomy. Long term studies are required to determine if these asymptomatic women with sphincter defects are more likely to develop late faecal incontinence, although the almost universal finding of sphincter defects in women presenting later in life with faecal incontinence (Burnett et al. 1991) would suggest that this is the case.

Although 47 percent of women with a third degree tear admitted to defaecatory symptoms, none had sought medical attention. This highlights the need to directly ask women about such symptoms at their postnatal visit. Even temporary anal incontinence after a third degree tear, which occurred in three women in the present study, has been shown to be a predictive factor for anal incontinence after subsequent vaginal delivery (Bek and Laurberg 1992).

The ideal management in subsequent deliveries of women who have sustained a third degree tear has not been prospectively established. However, I believe that these

women should be assessed by anal endosonographic and physiological tests prior to delivery. Any woman who is symptomatic or has major sphincter defects should be offered a caesarean section. In the presence of minor defects, a potentially traumatic vaginal delivery should be avoided.

In summary third degree tears are an uncommon but serious complication of vaginal delivery. When multiple risk factors are present, special attention should be directed to their prevention. Primary sphincter repair appears to be inadequate in at least half the women, often resulting in persistent symptoms. Because incontinence can be such a devastating social disability, the nature of sphincter repair deserves serious further attention.

## SECTION 7.4

### **ANAL SPHINCTER TRAUMA DURING INSTRUMENTAL DELIVERY:**

#### **A Comparison Between Forceps And Vacuum Extraction**

##### **7.4.1 INTRODUCTION**

In the prospective endosonographic study described in Section 7.2, 35% of women having their first vaginal delivery sustained damage to their anal sphincters. Apart from the two percent of primiparae who sustained a third degree tear, the sphincter injuries were not clinically obvious. In the same study 8 out of 10 forceps deliveries, but none of 5 vacuum extractor deliveries, were associated with sphincter muscle damage. In addition to direct mechanical trauma to the sphincter muscles, pudendal nerve damage was identified in 16% of all primiparae at 6 weeks post-partum. At the 6 months post-partum assessment, although abnormal pudendal nerve function was reduced to 5%, sonographic anal sphincter defects remained unchanged and was identified in all women who had defaecatory symptoms.

In the second study (Section 7.3) half the women who had sustained a third degree tear were delivered by forceps but none were associated with vacuum extraction.

The aim of this study was to establish the incidence of mechanical and nerve trauma in a large series of primiparous women delivered by either forceps or the vacuum

extractor, using anal endosonography and physiological measurements of anorectal function. The relationship of these findings to other obstetric variables and defaecatory symptoms has also been evaluated.

## 7.4.2 SUBJECTS AND METHODS

### 7.4.2.1 Subjects

#### 7.4.2.1.1 Instrumental delivery group

Consecutive primiparous women who had undergone instrumental vaginal delivery were asked to participate in this study. Forty three women (mean age 30 years, range 21 to 43) were recruited with a median time between delivery and assessment of 163 (range 44 to 1265) days. None suffered from diabetes mellitus, neurological or anorectal disease and none had defaecatory symptoms prior to their delivery.

Twenty six women were delivered by forceps (18 Simpsons, 5 Wrigley's and 3 Kiellands forceps) and 17 by the vacuum extractor. In total, there were 5 rotational deliveries; two rotated spontaneously to an occipito-anterior position during vacuum extraction and three underwent forceps rotation prior to extraction. The soft silicone cup (Silc cup) was used in 14 women and in the remaining 3 the Malmström metal cup was used. One of the forceps deliveries followed an unsuccessful vacuum delivery. The two instrumental delivery groups were not significantly different with respect to age, race, weight, height, length of the various stages of labour, incidence of shoulder

dystocia (2 in each group), baby weight and head circumference. The indications for instrumental delivery were also similar in the 2 groups (prolonged second stage in 19 (73%) of forceps deliveries and 11 (63%) of vacuum deliveries). There were no cases of "face to pubis" delivery.

A postero-lateral episiotomy was performed in all women who had an instrumental delivery except for four in the vacuum extraction group. These four women all sustained a spontaneous perineal body tear. Only one woman in this study sustained a third degree tear (involving the anal sphincter) and this followed a forceps delivery. All deliveries were conducted either by, or under the supervision of, experienced registrars.

Each woman was interviewed about bowel function according to a questionnaire. This included details of bowel frequency, excessive straining at stool, faecal urgency (difficulty in deferring defecation for more than five minutes), and continence to flatus, liquid and solid stool. Sphincter function and morphology were assessed by anal endosonography, anal manometry, pudendal nerve terminal motor latency studies and perineometry.

#### **7.4.2.1.2 Non-instrumental delivery (control group)**

Forty seven randomly selected primiparae who had had a normal vaginal delivery, but sustained a spontaneous perineal body tear (second degree) or a posterolateral episiotomy were studied as the control group. All these women were investigated at

a median time of 148 days (range 42 to 967 days) after delivery.

#### **7.4.2.2 Methods**

Anal endosonography (Section 1.4), anal manometry (Section 2.2.2.4), measurements of pudendal nerve terminal motor latencies (Section 2.2.3.4) perineometry (Section 2.2.4.1) and statistical analyses (Section 3) were performed as described in the relevant sections.

### **7.4.3 RESULTS**

#### **7.4.3.1 Defaecatory symptoms**

Twelve (28%) women admitted to new defaecatory symptoms following instrumental delivery (Table XIX). Eight women were incontinent (4 flatus only and 4 liquid and flatus). A further two women had experienced temporary flatus incontinence lasting less than 2 weeks following delivery. Ten of the symptomatic women belonged to the forceps delivery group (38%) and 2 belonged to the vacuum extraction group (12%) (Table XIX).

Two (4%) women in the control group were symptomatic (1 faecal urgency and 1 flatus incontinence). Compared to the control group, forceps delivery but not vacuum extraction was associated with a significantly ( $P=0.0002$ ) higher incidence of defaecatory symptoms (Table XIX).

**TABLE XIX Relationship between the method of instrumental delivery and the development of anal sphincter defects, defaecatory symptoms and abnormal perineal descent compared to control subjects.**

	<b>CONTROLS</b> (n=47)	<b>FORCEPS</b> (n=26)	<b>VACUUM</b> (n=17)
<b>DEFAECATORY SYMPTOMS</b>			
Incontinence only	1 (2%)	1 (4%)	1 (6%)
Urgency only	1 (2%)	4 (15%)	0
Incontinence & Urgency	0	5 (19%)	1 (6%)
<b>TOTAL SYMPTOMS</b>	2 (4%)	10 (38%)	2 (12%)
<b>TOTAL SYMPTOMS compared to controls</b> (P values and 95% confidence intervals)		P = 0.0003* 15 to 54	P = 0.57 9 to 24
<b>ANAL SPHINCTER DEFECTS</b>			
IAS only	8 (17%)	7 (27%)	0
EAS only	4 (9%)	3 (12%)	0
IAS & EAS	5 (11%)	11 (42%)	4 (24%)
<b>TOTAL DEFECTS</b>	17 (36%)	21 (81%)	4 (24%)
<b>TOTAL DEFECTS compared to controls</b> (P values and 95% confidence intervals)		P = 0.0005* 24 to 65	P = 0.39 -12 to 37
<b>PERINEAL DESCENT</b>			
<b>ABNORMAL DESCENT</b>	21 (45%)	18 (69%)	6 (35%)
<b>ABNORMAL DESCENT compared to controls</b> (P values and 95% confidence intervals)		P = 0.05* 2 to 47	P = 0.58 18 to 36

\* = statistically significant (Fisher's exact test).

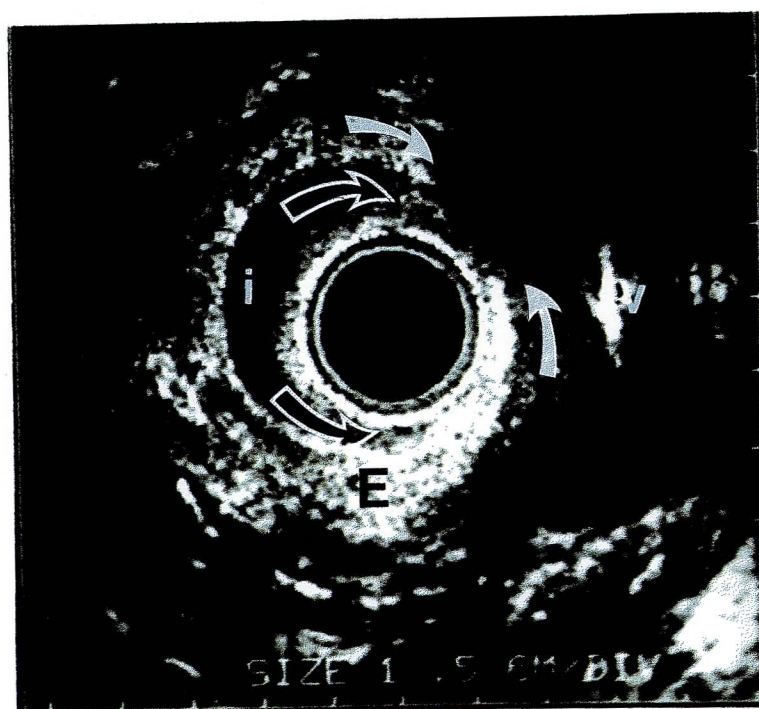
Perineal descent is regarded as abnormal when the plane of the perineum lies below the ischial tuberosities during straining

#### 7.4.3.2 Anal endosonographic findings

Sonographic sphincter defects were identified in 25 (58%) of the 43 women in the instrumental delivery group (Table XIX). All defects were anterior (Fig 7.5). Eleven of the IAS defects occupied the full length of the anterior external sphincter and 11 the distal half only. Nine of the EAS defects involved the full length of the anal canal, 8 involved only the proximal half and one only the distal half of the anal canal.

When comparing forceps to vacuum delivery, forceps deliveries were associated with significantly ( $P=0.0002$ ) more sphincter defects than vacuum deliveries (Table XIX). Compared to the control group ( $n=47$ ), forceps delivery, but not vacuum delivery, was significantly ( $P=0.0003$ ) associated with the development of sphincter defects (Table XIX).

In the instrumental delivery group as a whole there was a significant association between the development of faecal urgency ( $P<0.01$ ) or anal incontinence ( $P<0.01$ ) and the development of any sphincter defect.



**Fig 7.5** Anal endosonographic image after forceps delivery.

v = vagina. The open arrows indicate an internal sphincter (i) defect recognised by a loss of the hypoechoic ring anteriorly. There is also a defect (closed arrows) involving the external sphincter (E) evident from a break in the normal hyperechoic ring.

### 7.4.3.3 Anal manometry

Table XX shows the differences in anal manometric measurements between the forceps and control groups, and the vacuum and control groups.

Both the maximum resting and the maximum squeeze pressures were significantly lower ( $P<0.05$ ) in the forceps delivery group compared to the vacuum extraction group (Table XX). The maximum resting pressure was significantly lower in the 22 women who developed an internal sphincter defect compared to the 21 women who did not develop a defect  $46\pm 12$  (mean $\pm$ SD) v  $62\pm 10$ , defect v no defect,  $P<0.00001$ , 95% CI= 9 to 23]. The maximum squeeze pressure was significantly lower ( $P<0.00001$ ) in the 18 women who developed an external sphincter defect compared to the 25 women who did not develop an EAS defect  $43\pm 21$  v  $83\pm 34$ , defect v no defect, 95% CI= 23 to 59].

There was no significant difference in the manometric anal canal length between the women delivered by forceps and those delivered by the vacuum extractor. In the instrumental delivery group as a whole, the anal length was significantly ( $P<0.02$ ) shorter in those women who developed an internal anal sphincter defect,  $n=22$ ;  $3.5\pm 0.5$ ) v no defect,  $n=21$ ;  $3.8\pm 0.5$ ), 95% CI= 0.1 to 0.6].

**TABLE XX Relationship between methods of instrumental delivery and measurements of anal manometry and pudendal nerve terminal motor latency.**

	<b>CONTROLS (n=47)</b>	<b>FORCEPS (n=26)</b>	<b>VACUUM (n=17)</b>
<b>ANAL MANOMETRY (mm Hg)</b>			
Maximum resting pressure	59 ± 13	51 ± 11	59 ± 6
P value and 95% CI compared to controls		P = 0.006* 2 to 13	P = 0.86 -9 to 7
Maximum squeeze pressure	61 ± 30	57 ± 32	80 ± 37
P value and 95% CI compared to controls		P = 0.57 -10 to 19	P = 0.04* 1 to 37
<b>PUDENDAL NERVE TERMINAL MOTOR LATENCY (msec)</b>			
RIGHT	1.99 ± 0.03	1.99 ± 0.06	1.92 ± 0.03
P value and 95% CI compared to controls		P = 0.97 -0.12 to 0.13	P = 0.17 -0.03 to 0.19
LEFT	2.03 ± 0.03	1.96 ± 0.05	2.01 ± 0.05
P value and 95% CI compared to controls		P = 0.19 -0.04 to 0.18	P = 0.72 -0.10 to 0.72

Values represent mean ± SD

\* = statistically significant difference

95% CI refers to the 95% confidence interval of the difference between control values and the appropriate mode of delivery.

#### **7.4.3.4 Pudendal nerve terminal motor latency (PNTML) measurements**

There was no significant difference when comparing the PNTML measurements in the forceps delivery and vacuum extraction groups (Table XX). No difference was noted in PNTML measurements when either forceps or vacuum delivery were compared to the control group (Table 7.XX).

The PNTML measurements did not statistically differ between patients with and without defaecatory symptoms, with and without a sphincter defect. There was no significant correlation between PNTML and anal manometry measurements.

#### **7.4.3.5 Perineometry**

Eighteen (69%) of the women who had a forceps delivery compared to 6 (35%) of the women who had a vacuum extraction demonstrated abnormal perineal descent (below the level of the ischial tuberosities) on straining ( $P < 0.05$ ). Similarly, compared to the control group, forceps but not vacuum delivery was associated ( $P < 0.05$ ) with abnormal perineal descent (Table XIX).

No significant relationship was demonstrated between abnormal perineal descent and symptoms, sphincter defects, manometry or PNTML measurements.

#### 7.4.4 DISCUSSION

This study has evaluated defaecatory symptoms, occult anal sphincter defects and neuro-physiological measurements in women delivered by forceps, vacuum extraction or unassisted delivery.

Although the choice of instrument for delivery was not randomised, bias in the selection of patients for the study was minimised as consecutive primiparae who had an instrumental delivery were recruited. The two instrumental delivery groups did not differ in the characteristics of their labour, size of the baby or indication for delivery; instrumental choice related to operator preference. Operators therefore used the instrument with which they were most familiar.

The striking finding in this study was the high incidence of defaecatory symptoms, occult sphincter defects and corresponding manometric changes following forceps delivery, compared to vacuum-assisted or unassisted delivery. The finding of occult sphincter defects in 81% of forceps deliveries is in keeping with the previous prospective study (Section 7.2) in which sphincter defects were identified in 8 of 10 forceps deliveries. These sonographic sphincter defects appear to have physiological and clinical relevance as sphincter defects were associated with corresponding reductions in anal pressures. Furthermore, 38% of women who were delivered by forceps developed defaecatory symptoms compared to 4% of controls and 12% of vacuum deliveries.

Forceps may cause damage by more than one mechanism. The blade occupies more space in the pelvic outlet and it exerts direct pressure on the perineum during traction. In addition, forceps delivery may produce premature extension of the fetal head, resulting in a larger diameter of the presenting part at the outlet. In contrast, the vacuum cup occupies no additional space in the pelvis and allows the foetal head to rotate spontaneously and deliver in the position of least resistance. Snooks et al. (1986) found that forceps delivery increased the risk of pudendal nerve damage during delivery, as measured by nerve latencies and muscle fibre density measurements. However, in keeping with the findings of Allen et al. (1990), in the present study we found no significant difference between the pudendal nerve motor latencies of women who delivered spontaneously and those who delivered by forceps, nor between forceps and vacuum deliveries. The relatively minor changes, if any, in pudendal nerve function suggest therefore that early symptoms are due to mechanical muscle disruption.

As compared with obstetric forceps, the vacuum extractor has until recently been unpopular, particularly in English speaking countries. In England and Wales during 1978 only one in twenty instrumental deliveries were by vacuum extraction (Garcia et al 1985). Unfamiliarity with the vacuum extractor, a longer period of time required for effective application and uncertainty regarding perinatal morbidity following vacuum extraction are some of the reasons why the forceps are preferred. However the development of an electrical suction apparatus with the soft silicone cup (Berkus et al. 1985, Dell et al. 1985) has reduced application time to that comparable with forceps delivery. The vacuum extractor has been consistently reported to be associated

with less maternal perineal trauma when compared to forceps (Vacca & Kierse 1989). In a meta-analysis of five randomised controlled studies comparing vacuum and forceps deliveries (Vacca & Kierse 1989), the vacuum extractor was associated with one third the incidence of maternal injury compared to forceps delivery. Although the vacuum was associated with an increased incidence of cephalhaematoma, there were more facial injuries in the forceps-delivered group of babies. Phototherapy was required equally in each group. A further randomised comparison (Johanson et al 1989) of the new silicone cup with the forceps demonstrated significantly less maternal trauma with the former; no differences were demonstrated in fetal outcome between the groups with regard to cephalhaematoma, jaundice or retinal haemorrhages (Johanson et al 1989). Other studies have also confirmed these findings (Berkus et al 1985; Williams et al 1991). However a long term follow-up study of a randomised controlled group of children who had an instrumental delivery has not been done. The longest follow-up of babies in a randomised controlled trial was at the age of one year (Carmody et al. 1986). In that study (n=232) strabismus was found in 8 of 115 vacuum delivered babies and 6 of 117 forceps delivered babies. However hearing problems were found in 3 forceps delivered babies but in none of the vacuum delivered babies. Maternal worry is also a concern with instrumental delivery (Garcia et al. 1985, Pusey et al. 1991, Johanson et al. 1993a). In particular, the worry appears to be related to the appearance of the chignon following vacuum delivery. However, no significant differences in maternal concern were noted at 2 years (Johanson et al. 1993a). Indeed in this long term follow-up the only persistent instrument marks were that of the forceps.

Apart from rare situations such as a breech or face presentation, the forceps and vacuum extractor are largely interchangeable. A recent large prospective randomised trial (Johanson et al. 1993) demonstrated that successful instrumental vaginal delivery was achieved in more women with the vacuum extractor compared to forceps and also with significantly less maternal trauma in the vacuum extraction group.

Third degree tears are also more common after forceps than vacuum extraction (Combs et al 1990). It is therefore likely that the underlying mechanism for occult sphincter damage in women delivered by forceps is of the same nature as those sustaining a third degree tear.

Some women in this study had sphincter defects in the absence of symptoms. Longitudinal studies are required to determine whether these women stand an increased risk, of developing faecal incontinence later in life.

In conclusion, forceps delivery is associated with significantly more damage to the anal sphincters than vacuum extraction and is more frequently associated with anal incontinence. As the forceps and vacuum extractor are interchangeable in most clinical situations, we endorse the recommendation made by Chalmers and Chalmers (1989) that the vacuum extractor should be "the instrument of first choice for operative vaginal delivery" in those situations when either instrument can be used.

## SECTION 7.5

### **PERINEAL TRAUMA AT DELIVERY: An Audit of Training of Doctors and Midwives**

#### **7.4.1 INTRODUCTION**

Perineal trauma occurs frequently during vaginal delivery. This trauma may be obvious following an episiotomy or a spontaneous perineal tear, but there may also be occult trauma to the anal sphincter muscles (Section 7.2).

An episiotomy is the most common operation performed in obstetrics (Cunningham et al 1993) and some two thirds of all primiparous women sustain trauma sufficient to require suturing (Sleep et al. 1991). Inadequate repair at the time of delivery may lead to long term sequelae such as perineal pain, dyspareunia and anal incontinence.

Although third degree tears are rare, it would appear that primary repair is often unsatisfactory, as 47% of women have defaecatory symptoms following a primary repair of a third degree tear (Section 7.3), and all who were symptomatic after primary repair had persistent sonographic sphincter defects in both the internal and external anal sphincter muscles.

Furthermore, occult damage to the anal sphincter appears to occur frequently. In a

large prospective study, unsuspected occult anal sphincter defects were identified by anal endosonography in 35% of recently delivered primiparae (Section 7.2). Thirteen percent of primiparae and 23% of multiparae developed defaecatory symptoms.

Most perineal repairs are performed by trainee doctors and increasingly, by midwives. However, the expertise of these operators in recognising the full extent of trauma and conducting a satisfactory repair has not been evaluated. The aim of this study was to ascertain if trainee doctors and midwives have adequate knowledge of perineal anatomy and whether a consistent definition of a third degree tear is adhered to. In addition, the level of satisfaction of trainee doctors and midwives with regard to training in the repair of perineal lacerations has been assessed.

#### **7.4.2 METHODS**

Seventy five qualified midwives (mean time since qualification, 10 years, range 1-30) and 75 trainee doctors (53 registrars and 22 senior house officers who had completed at least 6 months training in obstetrics) were interviewed personally and a confidential questionnaire completed (Appendix B). All midwives had qualified in the United Kingdom. Although 44% of the doctors were foreign graduates, all were career orientated and had been working in hospitals in the United Kingdom. The questionnaire inquired about the degree of supervised training of perineal repair, knowledge of perineal anatomy, the classification of perineal tears and the degree of satisfaction with their training in this aspect of obstetrics (Appendix C).

### 7.4.3 RESULTS

The median number of episiotomies performed by the doctors was estimated to be between 50-100 and midwives 25-50 (range 25 to >100). Doctors were supervised for 2 (range 0-15) episiotomy repairs and midwives 3 (range 0-15) prior to repairing perineal lacerations unsupervised. Many doctors commented that they had only been supervised as medical students and received no formal training as doctors.

Fifty two (69%) doctors and 19 (25%) midwives stated that they knew which muscles were cut when performing an uncomplicated postero-lateral episiotomy. Nevertheless 28 (54%) of the 52 doctors who claimed to know the muscles usually involved and 11 (58%) of the 19 midwives were under the impression that the levator ani was divided during this procedure. It is in fact only divided when the incision is very deep or when there has been an extension of an episiotomy. One doctor believed that the gluteus maximus was normally divided and another two the external anal sphincter. Most of the answers to a request to name the muscles divided during a midline episiotomy were wrong and many believed that the external anal sphincter or the levator ani muscles were normally divided during an uncomplicated midline episiotomy.

The response to the question, " what is the closest distance between the posterior vaginal wall and the external anal sphincter" was as follows: doctors, median of 2 cm (range 0.5 to 7 cm) and midwives, median of 3 cm (range 0.5 to 7 cm).

The doctors and midwives were then asked to classify perineal tears. Seventy four

(99%) of the midwives and 69 (92%) of the doctors mentioned first, second and third degree tears. The remainder also mentioned a fourth degree tear. The respondents definition of a third or fourth degree tear is described in Table XXI.

Doctors and midwives were asked to state whether in their opinion it is better practice to perform an episiotomy or to allow a tear to occur. Fifty five (73%) doctors compared to 30 (40%) midwives preferred an episiotomy. Nine (12%) doctors and 30 (40%) midwives felt that the decision to perform an episiotomy should only be made at the time of delivery.

Most doctors and midwives admitted that they were not aware that anal incontinence was an important problem following delivery. Only 16% of midwives and 34% of doctors had come across women with obstetric related anal incontinence.

Doctors and midwives were also asked if at the time of performing their first unsupervised perineal repair they considered their level of training to be of a good standard. The results are shown in Table XXII.

There were no significant difference in responses between local and foreign graduates.

**Table XXI Responses of doctors and midwives regarding the definition of a third or fourth degree tear. Figures represent the number (percentages) that responded yes.**

	<b>DOCTORS (n=75)</b>	<b>MIDWIVES (n=75)</b>	<b>CORRECT ANSWERS</b>
External anal sphincter exposed	14 (19%)	29 (39%)	No
External anal sphincter torn	44 (59%)	63 (84%)	Yes
Internal anal sphincter exposed	33 (44%)	52 (70%)	Yes
Internal anal sphincter torn	51 (68%)	54 (72%)	Yes
Anal sphincter and anorectal mucosa torn	70 (93%)	51 (68%)	Yes
Torn urethra	6 (8%)	11 (15%)	No
Torn cervix	1 (1%)	2 (3%)	No
All extended episiotomies	0	11 (15%)	No

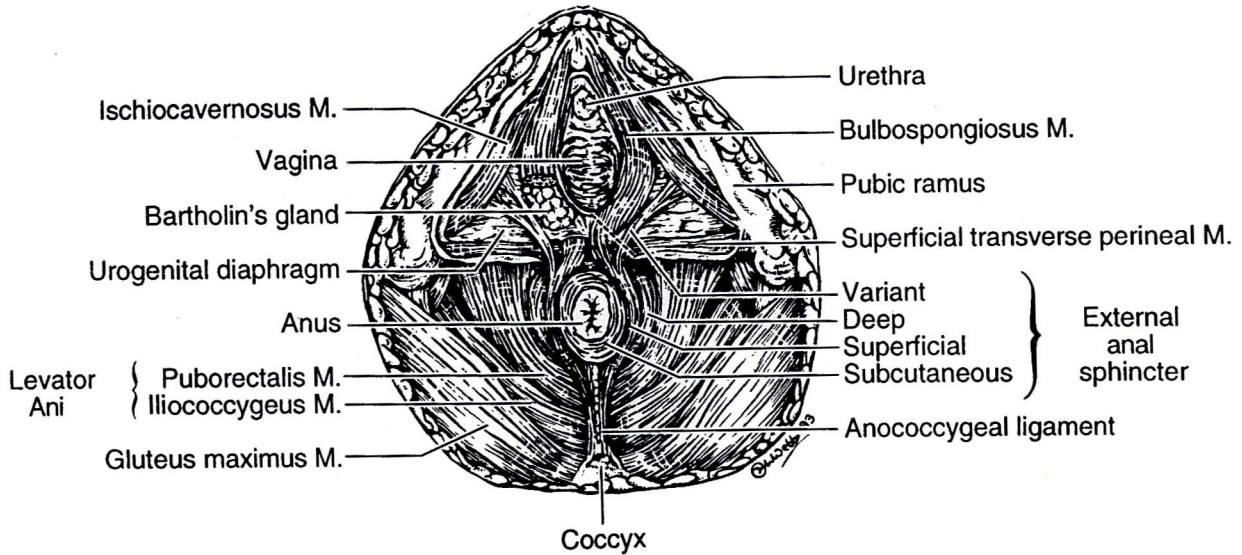
**Table XXII Number of doctors and midwives who they considered their training to be of a good standard at the time of being allowed to perform their first unsupervised perineal repair.**

	<b>DOCTORS (n=75)</b>	<b>MIDWIVES (n=75)</b>
Perineal anatomy	7 (9%)	30 (40%)
Performing episiotomy	14 (19%)	55 (75%)
Episiotomy/2nd degree tear repair	15 (20%)	36 (48%)
Recognising a 3rd degree tear	12 (16%)	29 (39%)
Repair of a 3rd degree tear (n=63)	4 (6%)	-

#### 7.4.4 DISCUSSION

During a median (midline) episiotomy the fibro-muscular perineal body alone is divided. During postero-lateral episiotomy the superficial part of the perineal body which includes the bulbospongiosus (previously known as the bulbocavernosus) muscle is first divided (Fig 7.6), but as the incision is extended lateral to the anus the superficial transverse perineal muscle is then divided. As an episiotomy is usually performed when the head distends and stretches the perineum, the levator ani muscle is commonly not involved during an uncomplicated episiotomy, but if this does occur the most medial component of the levator ani muscle (the puborectalis) would be cut. In a large prospective study involving 202 women (Section 7.2), although occult defects in the anal sphincter muscles were identified, no defects were found in the puborectalis muscle following delivery.

Despite the fact that episiotomy and repair of a perineal laceration is the commonest operation performed in obstetrics (Cunningham et al 1993), perineal anatomy is poorly understood by doctors and midwives. Few could name the small muscle namely, bulbospongiosus that acts as a superficial vulval sphincter. It has to be admitted however that "cut ends" are not in evidence in the perineal body during the repair so that it could be argued that the naming of the muscles may be of little importance. It was however surprising to note most of those who had named the muscles wrongly also assumed that the levator ani was routinely divided during this procedure.



**Fig 7.6 Schematic representation of the perineal muscles.**

The right bulbospongiosus muscle covering the vestibular bulb is cut to expose the Bartholin's gland. The broken line indicates the line of incision during a left postero-lateral episiotomy

The external anal sphincter is shorter anteriorly (Section 6.2) and quite close to the posterior vaginal wall at the apex of the perineal body where it is less than 5 mm away (Section 4.4). Many clinicians are not aware of how close the anal sphincter may be, particularly if the apex of the perineal body has dehiscenced during childbirth.

There is lack of consistency in the definition of a third degree tear. Donald (1979) defined a third degree tear as a perineal tear in which the anal sphincters and anal epithelium are involved, hence implying that involvement of the anal sphincters without a tear in the anal epithelium should be classified as second degree. Some consider involvement of the anal epithelium as less important (Myerscough 1982) while others classify a tear which involves the anal sphincter and epithelium as fourth degree (Cunningham et al. 1993). This confusion in the definition of a third degree tear may contribute to the lack of recognition or documentation of anal sphincter defects during normal vaginal delivery (Section 7.2). It was surprising to note that a considerable number of doctors and midwives considered exposure of the untorn external anal sphincter to be a third degree tear. Inconsistent responses concerning involvement of the internal and external sphincter muscles clearly demonstrate lack of understanding of the anal sphincter anatomy. Inclusion of torn urethra, torn cervix and all extended episiotomies in the definition of a third degree tear was also surprising. We believe that a third degree tear should be clearly defined as a tear that involves the anal sphincter (Cunningham et al. 1993). Although involvement of the anal epithelium (fourth degree) may indicate a more extensive lesion as the internal anal sphincter would invariably tear, the outcome of primary sphincter repair does not

appear to be influenced by anal epithelial disruption (Section 7.3), apart from a risk of residual ano-vaginal fistula (Fig 7.4b).

The understanding of normal anal sphincter anatomy, adequate assessment of obstetric trauma and appropriate repair are central to restoration of continence. Forty seven percent of women who have primary sphincter repair following a third degree tear continue to experience defaecatory symptoms (Section 7.3). Persistent anal sphincter defects were identified by anal endosonography in all these women. The poor outcome of primary sphincter repair may be related to operator inexperience; this aspect needs further evaluation.

Recently, there has been considerable speculation regarding the benefits of episiotomy (Thacker and Banta 1983, Harrison et al 1984) and it has been suggested that the episiotomy rate could with advantage be reduced to 20% (Henriksen et al. 1992). Nevertheless, it is evident from the present study that some 73% of trainee doctors believe an episiotomy to be preferable to a tear. This is probably based on the belief that cleanly incised wounds heal better than tissues stretched and torn after preceding distraction damage. Only 40% of the midwives surveyed preferred performing episiotomy to a spontaneous tear as delivery without 'needing stitches' attracts professional and client plaudits.

The incidence of defaecatory symptoms following vaginal delivery is under-estimated and these symptoms are under-reported by women. Incontinence is a socially taboo subject and women are too embarrassed to complain. Thirteen percent of primiparae

and 23% of multiparae were found to have developed defaecatory symptoms after vaginal delivery in one prospective study (Section 7.2), yet none of these women complained voluntarily of their symptoms. Clinicians do not enquire about defaecatory symptoms and when women do complain to their general practitioner they are usually referred to general surgeons. It is therefore not surprising that many obstetricians are unaware of the true magnitude of the problem. This was reflected in the present study as only 16% of midwives and 34% of trainee doctors had come across women suffering from anal incontinence.

This study has clearly highlighted deficiency and dissatisfaction among trainee doctors and midwives with their training in perineal anatomy and repair. Barely a fifth of these doctors and half of the midwives considered their training to be good, but many of the answers given by even the satisfied respondents were incorrect. More intense and focused training in these areas is needed for trainee doctors and midwives. The use of teaching videos would be most practical in illustrating anatomy, recognition of third degree tears and the appropriate methods of repair of perineal lacerations. As dyspareunia, perineal pain and defective anal sphincter function can be devastating social disabilities, greater care and increased supervision of trainee doctors and midwives is required during repair.

## SECTION 8

### OVERVIEW AND CONCLUSIONS

#### 8.1 Anal Endosonography

There are conflicting reports in the literature regarding the anatomy of the anal sphincter. In particular, controversy surrounds the subdivisions of the external anal sphincter and its attachments. The study in Section 4.1 has shown that the main reasons for this inconsistency are inter-individual variation as well as variation along the length and circumference of the anal sphincter in the same individual. The advent of anal endosonography has added a new dimension to the understanding of in vivo anal sphincter anatomy. Interpretation of anal endosonographic images has now been clarified and validated (Section 4.3). Furthermore in Section 4.4 the normal anal sphincter anatomy has been defined in a large series of healthy subjects. Anatomical gender differences and normal variants have been identified. As a result, imaging pitfalls during scanning in disease states have been highlighted leading to the possibility of confident and precise diagnosis.

A major clinical application of anal endosonography is in the investigation of faecal incontinence. Until the advent of anal endosonography the diagnosis of external anal sphincter defects relied on needle electromyographic mapping which is a blind and painful procedure. The diagnosis of internal sphincter defects could only be inferred

indirectly by measurement of the resting pressure of the anal canal. However anal endosonography has enabled precise mapping of external and internal anal sphincter defects painlessly. In Section 5.2 the diagnosis of external sphincter defects has been prospectively validated with histological confirmation. The sonographic appearance of internal sphincter defects has also been prospectively validated in Section 5.3. An important finding in the latter study was the unsuspected morbidity in terms of anal incontinence associated with lateral anal sphincterotomy in females as treatment for anal fissure. However, although this morbidity is related to the procedure, it highlights the vulnerability of women to develop anal incontinence particularly in the presence of injuries sustained at childbirth. Therefore care needs to be exercised prior to any operative procedure on the anal sphincter in females as it may jeopardise the woman's continence later in life.

In Section 6.2 vaginal endosonography, an alternative form of imaging the anal sphincters is described. For the first time this novel technique enables clear imaging of the undisturbed anal sphincter. It should now be possible to extend its role to study the pathogenesis of anal fissure and haemorrhoids. Furthermore it has been shown to be as accurate as anal endosonography in the diagnosis of anal sphincter defects (Section 6.2) and could therefore be preferred in females when the insertion of an anal probe is not feasible or uncomfortable eg. anal fissure or sepsis. Assessment and staging of anovaginal malignancy is another potential use of this procedure that needs to be explored.

## 8.2 Anal sphincter trauma at childbirth

### 8.2.1 Occult anal sphincter damage

Until recently the development of faecal incontinence in young and middle aged women has been attributed largely to pelvic nerve damage and progressive denervation and reinnervation of the pelvic floor and external anal sphincter. In one prospective study involving 96 nulliparae, Allen et al. (1990) identified EMG evidence of re-innervation in the pelvic floor muscles of 80% of the 75 nulliparae studied 2 months after delivery. However none of these studies evaluated the incidence and significance of occult mechanical trauma to the anal sphincters. The first prospective study to evaluate the incidence and significance of both mechanical and neurological damage to the anal sphincter has been described in Section 7.2. Occult anal sphincter defects involving one or both anal sphincter muscles were identified in 35% of primiparae and 44% of multiparae. Thirteen percent of primiparae and 23% of multiparae developed defaecatory symptoms (faecal urgency and/or anal incontinence) following vaginal delivery. There was a strong association between sphincter defects and symptoms. Although there was evidence of pudendal nerve damage in 16% of primiparae at 6 weeks postpartum, two thirds had recovered by 6 months and there was no relationship between the development of symptoms and pudendal nerve damage. Forceps delivery was identified as a single independent factor associated with occult sphincter damage. The 23 women delivered by caesarean section were asymptomatic and none developed a sphincter defect although a few women who were delivered by caesarean section after the onset of labour

demonstrated evidence of impaired pudendal nerve function (Section 7.2).

### 8.2.2 Third and fourth degree tears

Although third and fourth degree obstetric anal sphincter tears are reported to be an infrequent complication of childbirth, they result in persistent defaecatory symptoms in almost half the affected women (Section 7.3). In a study of 8603 women over a 31 month period 50 women (0.6%) sustained a tear of the anal sphincter during delivery. The following risk factors were identified: primiparity, forceps delivery, occipito-posterior position and baby weight > 4kg. No women delivered by the vacuum extractor during the same period sustained a third degree tear. Thirty four of the 50 women were later studied with anal endosonography and anorectal neurophysiological tests. All 16 symptomatic women were found to have both internal and external anal sphincter damage. Poor outcome did not appear to be related to involvement of the anal epithelium (fourth degree), choice of suture material, use of antibiotics or type of anaesthesia for repair. As there is a strong association between the presence of an anal sphincter defect and the development of symptoms techniques of primary sphincter repair also need re-evaluation. However a large multicentre randomised study would be required to address the effect of these factors on outcome of primary sphincter repair.

### 8.2.3 Perineal trauma and instrumental vaginal delivery

Apart from rare specific clinical situations such as breech and face presentations, the

forceps and vacuum extractor are generally interchangeable instruments. In a large randomised trial involving 607 women having an instrumental delivery (Johanson et al 1993), 98% of the vacuum deliveries compared to 96% of those delivered by forceps were successful. However the use of the vacuum extractor was associated with less maternal trauma than the forceps without any significant difference in neonatal morbidity and mortality. Third and fourth degree tears occur more frequently with the forceps than the vacuum extractor (Section 7.2). In Section 7.4 I have described another study involving 43 primiparae who had had instrumental delivery and 47 matched controls. In this study I identified occult anal sphincter defects in 81% of women delivered by forceps compared to 21% of vacuum deliveries. Furthermore, 38% of those delivered by forceps compared to 12% of vacuum deliveries developed defaecatory symptoms. Although this is not a randomised study, there is now substantial evidence (Section 7.4) in favour of the vacuum extractor compared to the forceps, and all other factors being equal, it should be the instrument of choice.

#### 8.2.4 Defaecatory symptoms following childbirth

The consequences of injuries attributed to childbirth are both under-reported and underestimated. The social stigma associated with incontinence leaves many women too embarrassed to seek medical help. Thirteen percent of women having their first vaginal delivery developed new defaecatory symptoms (Section 7.2). Although only 1 of the 79 primiparae developed incontinence to liquids, 3 others developed incontinence to flatus. Incontinence to flatus alone can also be a social disability. In contrast 47 percent of women who had a primary sphincter repair following a third

degree tear had defaecatory symptoms. Sixteen of the 34 women (41%) experienced anal incontinence (11 to flatus and 3 to flatus and liquid). However none of the women in my studies (Sections 7.2, 7.3 & 7.4) including those that were incontinent to liquid stool complained voluntarily of anal incontinence. One woman in her second pregnancy was incontinent for sixteen years following a previous vaginal delivery and was too embarrassed to seek help. She had only admitted that she suffered from incontinence to anyone for the first time with my direct questioning. Clinicians therefore need to enquire about anal incontinence particularly in the presence of a history of a traumatic delivery. Progressive deterioration of these symptoms over a period of time may encourage women to seek medical assistance. However when a woman does consult her General Practitioner she is usually referred to a general surgeon, and it is therefore not surprising that obstetric attendants are unaware of the true magnitude of obstetric related anal incontinence.

### **8.2.5 Expertise at perineal repair**

An objective audit of the conduct and outcome of adequate perineal repair by doctors and midwives has not yet been performed. The relatively high incidence of occult anal sphincter defects (Section 7.2) may be attributed either to blunt trauma during descent of the foetus through the vagina, or to direct trauma (following a tear or episiotomy) which may be either unrecognised or recognised but inadequately repaired. External anal sphincter defects were identified only in the presence of a perineal tear or an episiotomy. In three of the 17 women with an intact perineum following vaginal

delivery, minor internal sphincter defects were identified (Section 7.2). These findings therefore suggest that unrecognised direct trauma to the anal sphincters is a major factor. However a large randomised trial of episiotomy in one arm and no episiotomy in the other would be necessary to determine if occult anal sphincter trauma could be reduced .

Despite measures to reduce perineal trauma, injuries requiring repair will occur and it is therefore essential that the operator has a good understanding of perineal anatomy prior to embarking on surgical repair. In the UK most perineal repairs are performed by trainee doctors and midwives. In a survey involving 150 trainee doctors and qualified midwives (Section 7.5) it was alarming to note how few understood perineal anatomy. Although there is evidence to the contrary many doctors preferred performing an episiotomy instead of allowing a woman to have a delivery with an intact perineum or an inevitable tear. Despite the fact that an episiotomy is the commonest operation performed in obstetrics, none of the doctors could name the muscles that are cut during an uncomplicated episiotomy. Over 80% of doctors felt that training in performing an episiotomy and repairing perineal tears, as well as recognising and repairing anal sphincter tears, was suboptimal.

### **8.3 Recommendations**

- 1.** As the development of defaecatory symptoms is not uncommon and as women are too embarrassed to admit to them voluntarily, clinicians should make enquiries at the postnatal visit especially following a traumatic vaginal delivery.

Symptomatic women should be investigated with anal endosonography and anorectal physiological tests and treatment offered accordingly. Conservative therapies such as physiotherapy, biofeedback, dietary adjustments and antispasmodics have variable success rates. If secondary sphincter repair is contemplated I believe that caesarean section should be offered for any subsequent delivery. In any event a caesarean section should be considered for any pregnant woman who experiences anal incontinence attributable to anal sphincter damage. Alternatively, repair should be delayed till after the last vaginal delivery.

2. As there is overwhelming evidence that forceps delivery causes more maternal trauma than the vacuum extractor and as there is no evidence that either instrument is any more detrimental to the neonate, the vacuum extractor should be the instrument of choice when other factors are equal.

3. There is little to suggest that an episiotomy is of more than limited value in preventing anal sphincter damage. The only clear benefit of an episiotomy is that it may expedite delivery but without any significant benefit on perinatal mortality or 5 minute Apgar scores. However neither a very restrictive approach nor a very liberal approach during occipito-anterior vaginal delivery yields optimal results and it has been recommended that an ideal episiotomy rate should be about 20%. Therefore the decision to perform an episiotomy needs to be individualised. A thick and poorly elastic perineum which is likely to sustain a severe spontaneous tear would probably benefit from an episiotomy. The use of the vacuum extractor in preference to the forceps would also reduce the episiotomy rate as the need for an episiotomy is

inevitable during forceps delivery. The appropriate management of a pregnant woman who has previously sustained disruption to the anal sphincter is equally anecdotal. It is current practice to perform an episiotomy prophylactically in a woman who has had a previous third or fourth degree tear. Yet there is no evidence to suggest that this is effective in preventing a recurrence of a tear. Long term studies are needed to evaluate this.

4. Inconsistency in the classification and hence documentation of a third degree tear may account for some occult anal sphincter defects identified by anal endosonography. To avoid confusion a standard universal definition should be adopted:

**First degree:** Laceration of the vaginal epithelium or perineal skin only.

**Second degree:** Involvement of the perineal muscles but not the anal sphincters.

**Third degree:** Disruption of the anal sphincter muscles which may be partial or complete without involvement of the anal epithelium.

**Fourth degree:** A third degree tear with disruption of the anal epithelium as well.

A fourth degree tear indicates more extensive damage as the internal anal sphincter would invariably be disrupted. Furthermore when the anorectal epithelium is breached, there is an increased risk of faecal contamination of the wound and subsequent development of an anovaginal or rectovaginal fistula. An isolated tear of the anorectal epithelium without involvement of the anal sphincters (buttonhole) is a rare event and to avoid confusion should not be included in the above classification.

5. The ideal surgical technique of primary sphincter repair following a third or fourth degree tear has not been determined. It has not been established whether a better result could be obtained if primary repair were undertaken by an experienced obstetrician or a surgeon experienced in sphincter surgery, or whether primary repair should be delayed. The correct suture material, the use of antibiotics, type of anaesthesia and the use of post-operative laxatives are some factors that need scientific evaluation. A large multicentre study is urgently required.

6. Trainee doctors and qualified midwives expressed dissatisfaction in training with regard to perineal anatomy and repair. Doctors in particular indicated that supervised training in perineal repair was inadequate. As perineal repair is the most common operation in obstetrics, a more focused training programme is required. The use of audiovisual aids (teaching video programmes) may be of enormous benefit to the uninitiated so that anal sphincter disruption may be recognised and repair conducted by an experienced obstetrician.

#### 8.4 Conclusions

Perineal trauma, both overt and occult, causes considerable maternal morbidity. Greater emphasis needs to be placed on preventing perineal injury. In trained hands the vacuum extractor may be preferred over the use of the forceps. Early training of junior doctors and midwives in perineal anatomy and surgical repair needs to be intensified. As the outcome of primary sphincter repair following anal sphincter disruption is unsatisfactory, and defective anal sphincter function can be a devastating social disability, randomised studies are needed to establish the ideal method of initial repair and management in subsequent pregnancies.

## SECTION 9

## BIBLIOGRAPHY

- Abcarian H. Surgical correction of chronic anal fissure: Results of lateral anal sphincterotomy vs fissurectomy - midline sphincterotomy. *Dis Colon Rectum* 1980; 23: 31-36.
- Abel AL. The pecten band, pectenosis and pectenotomy. *Lancet* 1932; i: 714-720.
- Ahran P, Faverdin C, Persoz B. Relationship between viscoelastic properties of the rectum and anal pressure in man. *J applied physiology* 1976; 41: 677-682.
- Allen RE, Hosker GL, Smith ARB, Warrell DW. Pelvic floor damage and childbirth: a neurophysiological study. *Br J Obstet Gynaecol* 1990; 97: 770-779.
- Aronson MP, Lee RA, Berquist TH. Anatomy of anal sphincters and related structures in continent women studied with magnetic resonance imaging. *Obstet Gynecol* 1990; 76: 846-851.
- Ayoub SF. Anatomy of the external anal sphincter in man. *Acta Anatomy* 1979; 105: 25-36.
- Bannister JJ, Abouzekry L, Read NW. Effect of ageing on anorectal function. *Gut* 1987; 28: 353-357.
- Bannister JJ, Read NW, Donnelly TC, Sun WM. External and internal anal sphincter responses to rectal distension in normal subjects and in patients with idiopathic faecal incontinence. *Br J Surg* 1989; 76: 617-621.
- Barnes PRH, Hawley PR, Preston DM, Lennard-Jones JE. Experience of posterior division of the puborectalis muscle in the management of chronic constipation. *Br J Surg* 1985; 72: 475-477.
- Barter RH, Parks J, Tyndal C. Median episiotomies and complete perineal lacerations. *Am J Obstet Gynecol* 1960; 80: 654-662.
- Bartolo DCC, Jarratt JA, Read NW. The cutaneo-anal reflex: a useful index of neuropathy? *Br J Surg* 1983; 70: 660-663.
- Bartolo DCC, Roe AM, Locke-Edmunds JC, Virjee J, Mortensen NJMcC. Flap-valve theory of anorectal incontinence. *Br J Surg* 1986; 73: 1012-1014.
- Bartolo DCC, Jarratt JA, Read NW. The use of conventional electromyography to assess external sphincter neuropathy in man. *J Neurol Neurosurg Psychiatr* 1983a; 46: 1115-1118.

- Bartram CI, Burnett SJD. Atlas of anal endosonography. London: Butterworth-Heinemann, 1991.
- Bassett DL. A stereoscopic atlas of human anatomy: the pelvis. Sawyers inc: Portland (Oregon), 1961: vi.
- Beck A. Electromyographische untersuchungen am sphinkter ani. Arch Physiol 1930; 224: 278-292.
- Beersiek F, Parks AG, Swash M. Pathogenesis of anorectal incontinence: a histometric study of the anorectal musculature. J Neurol Sci 1979; 42: 111-127.
- Bennett LRC, Friedman MHW, Goligher JC. Late results of haemorrhoidectomy by ligation and excision. Br Med J 1963; ii: 216-219.
- Bennett RC, Duthie HL. The functional importance of the internal anal sphincter. Brit J Surg 1964; 51: 355-357.
- Berkus MD, Ramamurthy RS, O'Connor PS, Brown KJ, Hayashi RH. Cohort study of silastic obstetric vacuum cup deliveries: Safety of the instrument. Obstet Gynecol 1985; 66: 503-510.
- Beynon CL. The normal second stage of labour. J Obstet Gynaecol Brit Emp 1957; 64: 815-820.
- Beynon J, Foy DMA, Temple JL, Channer J and Mortensen McC. The endosonic appearances of normal colon and rectum. Dis Colon Rectum 1986a; 29: 810-813.
- Beynon J, Foy DMA, Roe AM, Temple LN, Mortensen NJMcC. Endoluminal ultrasound in the assessment of local invasion in rectal cancer. Br J Surg 1986b; 73: 474-477.
- Bielefeldt K, Enck P, Erckenbrecht JF. Sensory and motor function in the maintenance of anal continence. Dis Colon Rectum 1990; 33: 674-678.
- Blaisdell PC. Repair of the incontinent sphincter ani. Surg Gynecol Obstet 1940; 70: 692-697.
- Brindley GS. Electroejaculation: its technique, neurological implications and uses. J Neurol Neurosurg Psychiat 1981; 44: 9-18.
- Brocklehurst JC. Management of anal incontinence. Clinics in Gastroenterology 1975; 4: 479-487.
- Browning GGP and Motson RW. Results of Parks operation for faecal incontinence after anal sphincter injury. Br Med J 1983; 286: 1873-1875.

- Buchmann P, Mogg GAG, Alexander-Williams J, Allan RN, Keighley MRB. Relationship of proctitis and rectal capacity in Crohn's disease. *Gut* 1980; 21: 137-140.
- Burnett SJD, Speakman CTM, Kamm MA, Bartram CI. Confirmation of endosonographic detection of external anal sphincter defects by simultaneous electromyographic mapping. *Br J Surg* 1991; 78: 448-450.
- Burnett SJD, Spence-Jones C, Speakman CTM, Kamm MA, Hudson CN, Bartram CI. Unsuspected sphincter damage following childbirth revealed by anal endosonography. *Brit J Radiol* 1991a; 64: 225-227.
- Buser WD, Miner PB. Delayed rectal sensation with faecal incontinence. Successful treatment using anorectal manometry. *Gastroenterology* 1986; 91: 1186-1191.
- Bustami FMJ. A reappraisal of the anatomy of the levator ani muscle in man. *Acta Morphol Neerl-Scand* 1989; 26: 255-268.
- Callaghan RP, Nixon NH. Megarectum: physiological observations. *Arch Dis Childhood* 1964; 39: 153-157.
- Carlstedt A, Nordgren S, Fasth S, Appelgren L, Hulten L. Sympathetic nervous influence on the internal anal sphincter and rectum in man. *Int J Colorect Dis* 1988; 3: 90-95.
- Carmody F, Grant A, Mutch L, Vacca A, Chalmers I. Follow up of babies delivered in randomised comparison of vacuum extraction and forceps delivery. *Acta Obstet Gynecol Scand* 1986; 65: 763-766.
- Chalmers JA, Chalmers I. The obstetric vacuum extractor is the instrument of first choice for operative vaginal delivery [Commentary]. *Br J Obstet Gynaecol* 1989; 96: 505-506.
- Cherry DA, Rothenberger DA. Pelvic floor physiology. *Surg Clin N Am* 1988; 68(6): 1217-1230.
- Cheskin LJ, Schuster MM. Fecal incontinence. In: Hazzard WR, Andres R, Bierman EL, Blass JP, eds. *Principles of geriatric medicine and gerontology*. 2nd ed. New York: Mc Graw-Hill, 1990: 1143-1145.
- Choen S, Burnett S, Bartram CI, Nicholls RJ. Comparison between anal endosonography and digital examination in the evaluation of anal fistulae. *Brit J Surg*; 1991; 78: 445-447.
- Coats PM, Chan KK, Wilkins M, Beard RJ. A comparison between midline and mediolateral episiotomies. *Br J Obstet Gynaecol* 1980; 87: 408-412.

- Coller JA. Clinical application of anorectal manometry. *Gastroenterology Clin N Am.* 1987; 16(1): 17-33.
- Cochran WG. Some methods for strengthening the  $X^2$  test. *Biometrics* 1954; 10: 417-451.
- Collins CD Brown BH, Whittaker GE, Duthie HL. New method of measuring forces in the anal canal. *Gut* 1969; 10: 160-163.
- Combs C.A., Robertson P.A. & Laros R.K. Jr. Risk factors for third-degree perineal lacerations in forceps and vacuum deliveries. *Am J Obstet Gynecol* 1990; 163: 100-104.
- Corman ML. Anal sphincter reconstruction. *Surg Clin N Am* 1980; 60(2): 457-463.
- Corman ML. *Colon and rectal surgery.* Philadelphia. JB Lippincott, 1984: 118
- Cornes H, Bartolo DCC, Stirrat. Changes in anal canal sensation after childbirth. *Br J Surg* 1991; 78: 74-77.
- Courtney H. Anatomy of the pelvic diaphragm and anorectal musculature as related to sphincter preservation in anorectal surgery. *American Journal of Surgery* 1950; 79: 155-173.
- Cowper W. *Myotomia Reformata* London: 1694, as quoted by Levy 1936
- Cruveilhier H. *Traite d'anatomie descriptive.* Paris: Labe, 1852.
- Cuesta MA, Meijer S, Derksen EJ, Boutkan H, Meuwissen SGM. Anal sphincter imaging in fecal incontinence using endosonography. *Dis Colon Rectum* 1992; 35: 59-63.
- Cunningham FG, MacDonald PC, Gant NF, Leveno KJ, Gilstrap LC III. *Williams Obstetrics.* 19th edn, Norwalk, Connecticut, 1993: 388-393.
- Dalley AF II. The riddle of the sphincters: The morphophysiology of the anorectal mechanism reviewed. *The American Surgeon* 1987;53:298-306.
- Davidson JS, Davison MC, Hay DM. Gastric emptying time in late pregnancy and labour. *J Obstet Gynaecol Br Emp* 1970; 77: 37-41.
- Dell DL, Sighter SE, Plauche WC. Soft cup vacuum extraction: A comparison of outlet delivery. *Obstet Gynecol* 1985; 66: 624-628.
- Denny-Brown D, Robertson EG. An investigation of the nervous control of defaecation. *Brain* 1935; 58: 256-310.

- Dent JA. A new technique for continuous sphincter measurement. *Gastroenterology* 1976; 71: 263-267.
- Desch CH, Sproule DO, Dawson EJ. The detection of cracks in steel by means of supersonic waves. *J Iron Steel Inst, London* 1946; 153: 319.
- Dickinson VA. Maintenance of anal incontinence: a review of pelvic floor physiology. *Gut* 1978; 19: 1163-1174.
- Donald I, MacVicar J, Brown TG. Investigation of abdominal masses by pulsed ultrasound. *Lancet* 1958; 1: 1188-1195.
- Donald I, Abdullah U. Placentography by sonar. *J Obstet Gynaecol Brit Commonwealth* 1968; 75: 993.
- Donald I. *Practical Obstetric Problems*. 5th edn, London: Lloyd-Luke Ltd, 1979: 811.
- Donaldson A, Nicolini U, Symes EK, Rodeck CH, Tannirandorn Y. Changes in concentrations of cortisol, dehydro-epiandrosterone sulphate and progesterone in fetal and maternal serum during pregnancy. *Clin Endocrinol* 1991; 35: 447-451.
- Dragsted J, Gammelgaard J. Endoluminal ultrasonic scanning in the evaluation of rectal cancer. *Gastrointest Radiol* 1983; 8: 367-369.
- Dubowitz V. *Muscle biopsy: a practical approach*. 2nd ed. London: Bailliere Tindall, 1986.
- Duthie HL, Watts J. Contribution of the external anal sphincter to the pressure zone in the anal canal. *Gut* 1965; 6: 64-68.
- Duthie GS, Cornes H and Bartolo DCC. Prediction of anorectal trauma from delivery variables. *Br J Surg* 1991; 78: 746
- Duthie HL. Progress report: Anal continence. *Gut* 1971; 12: 844-852.
- Duthie HL, Gairns FW. Sensory nerve endings and sensation in the anal region of man. *Br J Surg* 1960; 47: 585-595.
- Duthie HL, Bennett RC. The relation of sensation in the anal canal to the functional anal sphincter: a possible factor in anal continence. *Gut* 1963; 4: 179-182.
- Eaton C. Proctologic postulates from an anatomic standpoint: Arrangement of anorectal musculature as useful surgical landmarks. *Am J Surg* 1942; 58: 64-68.
- Eckardt VF, Elmer T. Reliability of anal pressure measurements. *Dis Colon Rectum* 1991; 34: 72-77.

- Eisenhammer S. The surgical correction of chronic anal (sphincteric) contracture. *S Afr Med J* 1951; 25: 486-489.
- Eisenhammer S. The internal anal sphincter: Its surgical importance. *S Afr Med J* 1953; 27: 266-270.
- Ellis GV. *Demonstrations of Anatomy*. 8th ed. London: Smith Elder & co., 1878.
- Enck P, Bielefeldt K, Rathmann W, Purman J, Tschöpe D, Erckenbrecht JF. Epidemiology of faecal incontinence in selected patient groups. *Int J Colorect Dis* 1991; 6: 143-146.
- Enck P, Kuhlbusch R, Lubke H, Frieling T, Erckenbrecht JF. Age and sex and anorectal manometry in incontinence. *Dis Colon Rectum* 1989; 32: 1026-1030.
- Fagan EA. Disorders of the gastrointestinal tract. In De Swiet M, ed. *Medical disorders in obstetric practice*, 2nd edition. London: Blackwell Scientific Publications, 1989: 521-583.
- Felt-Bersma RJF, Gorr G, Meuwissen SGM. Normal values in anal manometry and rectal sensation: a problem of range. *Hepato-Gastroenterol* 1991; 38: 444-449.
- Felt-Bersma RJF, Klinkenberg-Knol EC, Meuwissen SGM. Investigation of anorectal function. *Br J Surg* 1988; 75: 53-55.
- Felt-Bersma RJF, Meuwissen SGM. Anal Manometry. *Int J Colorect Dis* 1990; 5: 170-173.
- Fine J and Wickham Lawes CH. On the muscle-fibres of the anal submucosa, with special reference to the pecten band. *Brit J Surg* 1940; 27: 723-727.
- Finlay JG, Carter K, McLeod I. A comparison of intrarectal infusion of gas on anorectal angle and anal canal pressure. *Br J Surg* 1986; 76: 1025.
- Firestone FA. The supersonic reflectoscope, an instrument for inspecting the interior of solid parts by means of sound waves. *J Acoust Soc Amer* 1946; 17: 287.
- Fischer SR. Factors associated with the occurrence of perineal lacerations. *J Nurse midf* 1979; 24: 18-26.
- Flemming AR. Complete perineotomy. *Obstet Gynecol* 1960; 16: 172-174.
- Floyd WF, Walls EW. Electromyography of the sphincter ani externus in man. *J Physiol (Lond)* 1953; 122: 599-609.
- Fornage BD. Achilles tendon. US examination. *Radiology* 1986; 159(3): 759-764.

- Fowler R. Jnr. Landmarks and legends of the anal canal. *Australian and New Zealand Journal of Surgery* 1957; 27: 1-18.
- Frenckner B, Euler CV. Influence of pudendal block on the function of the anal sphincters. *Gut* 1975; 16: 482-489.
- Frenckner B, Ihre T. Influence of autonomic nerves on the internal anal sphincter in man. *Gut* 1976; 17: 306-312.
- Frentzel-Beyme B et al. Die transrektale prostatasonographie. *Computertomogr Sonogr Juni* 1982; 2(2): 58-112.
- Frezza EE, Sandei F, Leoni G, Biral M. Conservative and surgical treatment in acute and chronic anal fissure. A study of 308 patients. *Int J Colorect Dis* 1992; 7: 188-191.
- Galen (129-200 A.D.) *De Sedis Musculis*, as quoted by Levy, 1936.
- Galloway CE. The management of vertex presentation by episiotomy and outlet forceps. III. *Med J* 1935; 67: 526-535.
- Ganiban G, Besselman D, Harcelrode J, Murthy SNS. Effect of sex steroids on total gastrointestinal transit in male rats. *Gastroenterology* 1985; 88: 1713.
- Garcia J, Anderson J, Vacca A, Elbourne D, Grant A, Chalmers I. Views of women and their medical and midwifery attendants about instrumental delivery using vacuum extraction and forceps. *J Psychosomatic Obstet Gynaecol* 1985; 4: 1-9.
- Gardener MJ, Altman DG. *Statistics with Confidence - Confidence intervals and statistical guidelines*. London: British Medical Journal, 1989: 6-33.
- Gass MS, Dunn C, Stys SJ. Effect of episiotomy on the frequency of vaginal outlet lacerations. *J Reprod Med* 1986; 31: 240-244.
- Gaston EA. The physiology of fecal continence. *Surg, Gynecol Obstet* 1948; 87: 280-290.
- Gibbons CP, Read NW. Anal hypertonia in fissures: cause or effect? *Br J Surg* 1986; 73: 443-445.
- Gibbons CP, Trowbridge EA, Bannister JJ, Read NW. Role of anal cushions in maintaining continence. *Lancet* 1986; i: 886-888.
- Glazier A, McNeilly AS, Howie PW. Fertility after childbirth: Changes in serum gonadotrophin levels in bottle and breast feeding women. *Clin Endocrinol* 1983; 19: 493-501.

- Goligher JC. Surgery of the Anus Rectum and Colon. 5th ed. London: Bailliere Tindall, 1984.
- Goligher JC, Leacock AG and Brossy JJ. The surgical anatomy of the anal canal. *Br J Surg* 1955; 43: 51-61.
- Goligher JC, Hughes ESR. Sensibility of the rectum and colon. Its role in the mechanism of anal continence. *Lancet* 1951; i: 543-547.
- Gorsch RV. Proctologic Anatomy. 2nd ed. Baltimore: Williams and Wilkins, 1955.
- Gorsch RV. Perineopelvic Anatomy. New York City: The Tilghman Company, 1941.
- Gowers WR. The automatic action of the sphincter ani. *Proc R Soc (Lond)* 1877; 26: 77-84.
- Grant JCB Method of Anatomy. 5th ed. Baltimore: Williams & Wilkins, 1952.
- Gray H. Grays Anatomy. Johnston TB and Whillis J. eds. 31st ed. London: Longman's Green & co., 1954.
- Green JR, Soohoo SL. Factors associated with rectal injury in spontaneous deliveries. *Obstet Gynecol* 1989; 73: 732-38.
- Gunterberg B, Kewenter J, Petersen I, Stener B. Anorectal function after major resections of the sacrum with bilateral or unilateral sacrifice of sacral nerves. *Br J Surg* 1976; 63: 546-554.
- Gutierrez JG, Shah AN. Autonomic control of the internal anal sphincter in man. In: Vantrappen G. ed. Vth international symposium of gastrointestinal motility. Herentals Belgium: Typoff press, 1975: 336-373.
- Haadem K, Ohrlander S, Lingman G. Long-term ailments due to anal sphincter rupture caused by delivery - a hidden problem. *Eur J Obstet Gynecol Reprod Biol* 1988; 27: 27-32.
- Haadem K, Ling L, Ferno M, Graffner H. Estrogen receptors in the external anal sphincter. *Obstet Gynecol* 1991; 164: 609-610.
- Haadem K, Dahlstrom JA, Lennart L. Anal sphincter competence in healthy women: clinical implications of age and other factors. *Obstet Gynecol* 1991a; 78:823-7.
- Haas PA and Haas GP. "Current Status" not Current Status. *Dis Colon Rectum* 1988; 31: 747
- Hallan RI, Marzouk DEMM, Waldron DJ, Womack NR, Williams NS. Comparison of digital and manometric assessment of sphincter function. *Br J Surg* 1989; 76: 973-975.

- Hancock BD. The internal sphincter and anal fissure. *Br J Surg* 1977; 64: 833-836.
- Harada K, Tanahashi Y, Igari D, Numata I, Orikasa S. Gray scale transrectal ultrasonography of the prostate. *J Clin Ultrasound* 1980; 7: 45-49.
- Hardcastle JD, Parks AG. A study of anal incontinence and some principles of surgical treatment. *Proc R Soc Med* 1970; 63: 116-118.
- Harrison RF, Brennan M, North PM, Reed JV, Wickham EA. Is routine episiotomy necessary? *Br Med J* 1984; 288: 1971-1975.
- Hatcher PA, Thomson H, Ludgate S, Small WP, Smith AN. Surgical aspects of intestinal injury due to pelvic radiotherapy. *Ann Surg* 1984; 201: 470-475.
- Hawley PR. The treatment of chronic fissure-in-ano. A trial of methods. *Br J Surg* 1969; 56: 915-918.
- Henriksen TB, Bek KM, Hedegaard M, Secher NJ. Episiotomy and perineal lesions in spontaneous vaginal deliveries. *Br J Obstet Gynaecol* 1992; 99: 950-954.
- Henriksen TB, Bek KM, Hedegaard M, Secher NJ. Episiotomy and perineal lesions in spontaneous vaginal deliveries. *Br J Obstet Gynaecol* 1992; 99: 950-954.
- Henry MM, Swash M. Assessment of pelvic floor disorders and incontinence by electrophysiological recording of the anal reflex. *Lancet* 1978; i: 1290-1291.
- Henry MM, Parks AG, Swash M. The anal reflex in idiopathic faecal incontinence; an electrophysiological study. *Br J Surg* 1980; 67: 781-783.
- Henry MM, Parks AG and Swash M. The pelvic floor musculature in the descending perineum syndrome. *Br J Surg* 1982; 69: 470-472.
- Henry MM, Snooks SJ, Barnes PRH, Swash M. Investigations of disorders of the anorectum and colon. *Annals of the Royal College of Surgeons England* 1985; 67: 355-360.
- Henry MM. Pathogenesis and management of fecal incontinence in the adult. *Gastroenterol Clin N Am* 1987; 16: 1358-1360.
- Hertz AF. Constipation and allied intestinal disorders. London: Oxford University Press, 1909.
- Hertz HG. Pulse-echo technique In: De Vlieger M, ed. *Handbook of clinical ultrasound*. New York: John Wiley and sons, 1978: 31-37.
- Hey VMF, Cowley DJ, Ganguli PC, Skinner LD, Ostick DG, Sharp DS. Gastro-oesophageal reflux in late pregnancy. *Anaesthesia* 1987; 32: 372-377.

- Hiller RI. The anal sphincter and the pathogenesis of anal fissure and fistula. *Surgery, Gynecology and Obstetrics* 1931; L11: 921-940.
- Holl K von B. *Handbuch der Anatomie des Menschen*. Vol 7, Bk.2, Sect 2. Jena, 1897. (quoted by Levy 1936).
- Holm HH, Kristensen JK, Rasmussen SN, Pedersen JF, Hancke S. Abdominal ultrasound. Munksgaard: University Parks Press, 1976: 13-16.
- Holmes JH, Wright W, Meyer EP. Ultrasonic contact scanner for diagnostic application. *Amer J Med Electron* 1965; 4: 147.
- Howry DH, Bliss WR. Ultrasonic visualisation of soft tissue structures of the body. *J Lab Clin Med* 1952; 40: 579-592.
- Hughes ESR. Surgical anatomy of the anal canal. *Aust N Z J Surg* 1956; 26: 48-55
- Ihre T. Studies on anal function in continent and incontinent patients. *Scand J Gastroenterology* 1974; 9 (suppl): 7-59.
- Ingraham HA, Gardner MM, Heus GE. A report on 159 third degree tears. *Am J Obstet Gynecol* 1949; 57: 730-735.
- Ingraham HA, Gardner MM, Heus GE. A report on 159 third degree tears. *Am J Obstet Gynecol* 1949; 57: 730-5.
- Jaffe B, Roth RS, Marzullo S. Properties of piezoelectric ceramics in solid-solution series lead titanate-lead zirconate-lead oxide: tin oxide and lead titanate-lead hafnate. *J Res Nat Bur Stand Sect A* 1955; 55: 239.
- James ED. Continuous monitoring. *Urol Clin North Am* 1979; 6: 125-137.
- Jarvinen M, Aho AL, Lehto M, Hannu T. Age dependent repair of muscle rupture. *Acta Orthop Scand* 1983; 54: 64-74.
- Johanson R, Pusey J, Livera N, Jones P. North Staffordshire/Wigan assisted delivery trial. *Br J Obstet Gynaecol* 1989; 96: 537-544.
- Johanson RB. Ventouse or forceps? [Editorial] *Br J Hos Med* 1991; 46:13.
- Johanson RB, Wilkinson P, Bastible A, Ryan S, Murphy H, Redman CWE, O'Brien PMS. Health after assisted vaginal delivery: follow up of a random controlled study. *J Obstet Gynaecol* 1993a; 13: 242-246.
- Jones PN, Lubowski DZ, Swash M, Henry MM. Relationship between perineal descent and pudendal nerve damage in idiopathic faecal incontinence. *Int J Colorect Dis* 1987; 2: 93-95.

- Juniper EF, Daniel EE, Roberts RS, Kline PA, Hargreave FE, Newhouse MT. Improvement in airway responsiveness and asthma severity during pregnancy. *Ann Rev Respir Dis* 1989; 140: 924-931.
- Kamm MA, Farthing MJG, Lennard-Jones JE. Bowel function and transit rate during the menstrual cycle. *Gut* 1989; 30: 605-608.
- Kamm MA. Reproductive hormones and motility. *Motility* 1991; 14 :12-14
- Kamm MA, Hawley PR and Lennard-Jones JE. Lateral division of the puborectalis muscle in the management of severe constipation. *Br J Surg* 1988; 75: 661-663.
- Keighley MRB, Winslet MC, Yoshioka K, Lightwood R. Discrimination is not impaired by excision of the anal transition zone after restorative proctocolectomy. *Br J Surg* 1987; 74: 1118-1121.
- Keighley MRB, Henry MM, Bartolo DCC, Mortensen NJMcC. Anorectal physiology measurement: report of a working party. *Br J Surg* 1989; 76: 356-357.
- Kerremans R. Electrical activity and motility of the internal anal sphincter. *Acta Gastroenterologica Belgica* 1968; 31: 465-482.
- Kerremans R. Morphological and Physiological aspects of anal incontinence and defaecation. Bruxelles: Arscia Uitgaven, 1969: 57-67.
- Khubchandani IT, Reed JF. Sequelae of internal sphincterotomy for chronic fissure in ano. *Br J Surg* 1989; 76: 431-434.
- Kiff ES and Swash M. Normal proximal and delayed distal conduction in the pudendal nerves of patients with idiopathic (neurogenic) faecal incontinence. *J Neurol Neurosurg Psychiatry* 1983; 46:67-71.
- Kiff ES, Swash M. Slowed conduction in the pudendal nerves in idiopathic (neurogenic) faecal incontinence. *Br J Surg* 1984; 71:614-616.
- Kiff ES and Swash M. Normal proximal and delayed distal conduction in the pudendal nerves of patients with idiopathic (neurogenic) faecal incontinence. *J Neurol Neurosurg Psychiatry* 1984b; 47: 820-823.
- Kiff ES, Barnes RPH, Swash M. Evidence of pudendal neuropathy in patients with perineal descent and chronic constipation. *Gut* 1984c; 25: 1279-1282.
- Knudsen UB, Laurberg S, Danielsen CC. Influence of bilateral oophorectomy and oestrogen substitution on the striated anal sphincter in adult female rats. *Scand J Gastroenterol* 1991; 26: 731-736.
- Kobayashi T. Ultrasonic diagnosis of breast cancer. *Ultrasound Med Biol* 1975; 1: 383.

- Kohlrausch O. Zur Anatomie und Physiologie der Beckenorgane. Lepsig: S. Hirzel, 1854. p.9.
- Kossoff G. The Transducer. In: De Vlieger M, ed. Handbook of clinical ultrasound. New York: John Wiley and sons, 1978: 25-30.
- Kossoff G, Garrett WJ. Ultrasonic film echoscopy for placental localisation. Aust N Zeal J Obstet Gynaecol 1972; 12: 117.
- Kumar D. In vitro inhibitory effect of progesterone on extrauterine human smooth muscle. Am J Obstet Gynecol 1962; 84: 1300-1304.
- Lahr CJ. Evaluation and treatment of incontinence. Practical Gastroenterol 1988;12: 27-35.
- Laimer E. Zur Anatomie des Mastdarmes Med. Jahrb. Wien. 1884; 49-59.
- Larsson P-G, Platz-Christensen J-J, Bergman B, Wallsterrson G. Advantage or disadvantage of episiotomy compared with spontaneous perineal laceration. Gynecol Obstet Invest. 1991; 31: 213-16.
- Last RJ. Anatomy, regional and applied. 7th ed. London: Churchill and Livingstone, 1984, pp 345-361.
- Last RJ. Anatomy Regional and Applied. London: J & A Churchill, 1954.
- Laurberg S, Swash M. Effects of ageing on the anorectal sphincters and their innervation. Dis Colon Rectum 1989; 32: 737-742.
- Laurberg S, Swash M, Henry MM. Delayed external sphincter repair for obstetric tear. Br J Surg 1988; 75: 786-788.
- Law PJ, Talbot RW, Bartram CI and Northover JMA. Anal endosonography in the evaluation of perianal sepsis and fistula in ano. Brit J Surg 1989; 76: 752-755.
- Law PJ, Bartram CI. Anal endosonography: technique and normal anatomy. Gastrointest Radiol 1989; 14: 349-353.
- Law PJ, Kamm MA, Bartram CI. A comparison between electromyography and anal endosonography in mapping external anal sphincter defects. Dis Colon Rectum 1990; 33: 370-373.
- Law PJ, Kamm MA and Bartram CI. Anal endosonography in the investigation of faecal incontinence. Brit J Surg 1991; 78: 312-14.
- Lawson JON. Pelvic anatomy I. Pelvic floor muscles. Ann R Coll Surg Engl 1974a; 54: 245-252.

- Lawson JON. Pelvic anatomy. II. Anal canal and associated sphincters. *Ann R Coll Surg Eng* 1974; 54: 288-300.
- Leigh RJ, Turnberg LA. Faecal incontinence: the unvoiced symptom. *Lancet* 1982; i: 1349-1351.
- Lestar B, Penninckx F, Kerremans R. The composition of anal basal pressure. An in vivo and in vitro study in man. *Int J Colorec Dis* 1989; 4: 118-122.
- Levi AC, Borghi F, Garavoglia M. Development of the anal canal muscles. *Dis Colon Rectum* 1991; 34: 262-266.
- Levy E. Anorectal musculature. *Am J Surg.* 1936; 34: 141-198.
- Lewis TH, Corman ML, Prager ED, Robertson WG. Long-term results of open and closed sphincterotomy for anal fissure. *Dis Colon Rectum* 1988; 31: 368-371.
- Lind JF, Smith AM, McIver DK, Coopland AT, Crispin JS. Heartburn in pregnancy - a manometric study. *Can Med Assoc J* 1968; 98: 571-574.
- Loder PB, Kamm MA, Nicholls RJ, Phillips RK. Topical application of a nitrous oxide donor reduces internal anal sphincter tone: therapeutic implications. *Gut* 1993; 34(1): S25.
- Loening-Baucke V, Anuras S. Effects of age and sex on anorectal manometry. *Am J Gastroenterology* 1985; 80(1): 50-53.
- Lubowski DZ, Nicholls RJ, Swash M, Jordan MJ. Neural control of internal anal sphincter function. *Br J Surg.* 1987; 74: 668-670.
- Lubowski DZ, Nicholls RJ. Faecal incontinence associated with reduced pelvic sensation. *Br J Surg* 1988; 75: 1086-1088.
- Lubowski DZ, Swash M, Nicholls RJ and Henry MM. Increase in pudendal nerve terminal motor latency with defaecation straining. *B J Surg* 1988a; 75: 1095-1097.
- Lubowski DZ, Jones PN, Swash M, Henry MM. Asymmetrical pudendal nerve damage in pelvic floor disorders. *Int J Colorect Dis* 1988b; 3: 158-160.
- Lubowski DZ, Swash M, Henry MM. Neural mechanisms in disorders of defaecation. In: Grundy D, Read NW, eds. *Baillière's Clinical Gastroenterology: Gastrointestinal Neurophysiology*. London: Baillière Tindall, 1988c: 216-7.
- Ludwig GD, Struthers FW. Considerations underlying the use of ultrasound to detect gall stones and foreign bodies in tissue. *Naval Medical Research Institute* 1949; Project MN 004:001: report no 4.(as quoted by Holm (1976).

- Lunniss PJ and Phillips RKS. Anatomy and function of the anal longitudinal muscle. *British Journal of Surgery* 1992; 79: 882-884.
- Mac Donald A, Smith A, McNeill AD, Finlay IG. Manual dilatation of the anus. *Br J Surg* 1992; 79: 1381-1382.
- Mc Hugh SM, Diamant NE. Effect of age, gender, and parity on anal canal pressures. Contribution of impaired anal sphincter function to faecal incontinence. *Dig Dis Sciences* 1987a; 32(7): 726-736.
- Mc Hugh SM, Diamant NE. Anal canal pressure profile: a reappraisal as determined by rapid pull through technique. *Gut* 1987b; 28: 1234-1241.
- Melzak J, Porter NH. Studies of the reflex activity of the external sphincter ani in spinal man. *Paraplegia* 1964; 1: 277-296.
- Merton PA, Holl DK, Morton HB, Marsden CD. Scope of a technique for electrical stimulation of human brain, spinal cord and muscle. *Lancet* 1982; ii: 597-600.
- Miller R, Bartolo DCC, Cavero F, Mortensen NJMcC. Anorectal temperature sensation: a comparison of normal and incontinent patients. *Br J Surg* 1987; 74: 511-515.
- Miller R, Bartolo DCC, Locke-Edmonds JC, Mortensen NJMcC. Prospective study of conservative and operative treatment for faecal incontinence. *Br J Surg* 1988a; 75: 101-106.
- Miller R, Lewis GT, Bartolo DCC, Mortensen NJMcC. Sensory discrimination and dynamic activity in the anorectum: evidence using a new ambulatory technique. *Br J Surg* 1988b; 75: 1003-1007.
- Miller R, Bartolo DCC, Cavero F, Mortensen NJMcC. Anorectal sampling: a comparison of normal and incontinent patients. *Br J Surg* 1988c; 75: 44-47.
- Miller R, Bartolo DCC, Roe AM, Mortensen NJMcC. Assessment of microtransducers in anorectal manometry. *Br J Surg* 1988d; 75: 40-43.
- Miller R, Bartolo DCC, James D, Mortensen NJMcC. Air-filled microballoon manometry for use in anorectal physiology. *Br J Surg* 1989; 76: 72-75.
- Milligan ETC, Morgan CN. Surgical anatomy of the anal canal with special reference to anorectal fistulae. *Lancet* 1934; 2: 150-156, 1213-1217.
- Milligan ETC. Surgical anatomy and disorders of the perianal space. *Proc Roy Soc Med* 1943; 36: 365-378.

- Morgan CN and Thompson HR. Surgical anatomy of the anal canal with special reference to the surgical importance of the internal sphincter and conjoint longitudinal muscle. *Annals R Coll Surg Engl* 1956; 19: 88-114.
- Morgan CN. The surgical anatomy of the ischiorectal space. *Proc Roy Soc Med* 1948; XL11: 189-200.
- Murray GD, Miller R. Statistical comparison of two methods of clinical measurement. *Br J Surg* 1990; 77: 384-387.
- Myerscough PR. Munro Kerr's operative obstetrics. 10th edn. London: Bailliere Tindall, 1982: 457.
- Nagler R, Spiro HM. Heartburn in late pregnancy. manometric studies of esophageal motor function. *J Clin Invest* 1961; 40: 954-970.
- Neill ME, Swash M. Increased motor unit fibre density in the external anal sphincter in ano-rectal incontinence: a single fibre EMG study. *J Neurol Neurosurg Psychiatry* 1980; 43: 343-347.
- Neill ME, Parks AG, Swash M. Physiological studies of the pelvic floor in idiopathic faecal incontinence and rectal prolapse. *Br J Surg* 1981; 68: 531-536.
- Neilsen MB, Hauge C, Rasmussen OO, Pedersen JF, Christiansen J. Anal endosonographic findings in the follow-up of primarily sutured sphincteric ruptures. *Br J Surg* 1992; 79: 104-106.
- Nielsen MB, Hauge C, Rasmussen OO, Sorensen M, Pedersen JF, Christiansen J. Anal sphincter size measured by endosonography in healthy volunteers. *Acta Radiologica* 1992a; 33: 453-456.
- Nivatvongs S, Stern HS, Fryd DS. The length of the anal canal. *Dis Colon Rectum* 1981; 24: 600-601.
- Notaras MJ. The treatment of anal fissure by lateral subcutaneous internal sphincterotomy - A technique and results. *Br J Surg* 1971; 58: 96-100.
- Nugent FB and Reading PA. The primiparous perineum after forceps delivery. *Am J Obstet Gynecol* 1935; 30: 249-256.
- Oettle GJ, Roe AM, Bartolo DCCC, Mortensen NJMcC. What is the best way of measuring perineal descent? A comparison of radiographic and clinical methods. *Br J Surg* 1985; 72: 999-1001.
- O'Leary P, Boyne P, Flett P, Beilby J, James I. Longitudinal assessment of changes in reproductive hormones during normal pregnancy. *Clin Chem* 1991; 37: 667-672.

- O'Leary JL, O'Leary JA. The complete episiotomy. Analysis of 1224 complete lacerations, sphincterotomies, and episi-proctotomies. *Obstet Gynecol* 1965; 25: 235-40.
- Oh C, Kark AE. Anatomy of the external anal sphincter. *Br J of Surg* 1972; 59: 717-723.
- Olsen J, Mortensen PE, Krogh Petersen I, Christiansen J. Anal sphincter function after treatment of fissure-in-ano by lateral subcutaneous sphincterotomy versus anal dilatation. *Int J Colorect Dis* 1987; 2: 155-157.
- Orrom WJ, Williams JG, Rothenberger DA, Wong WD. Portable anorectal manometry. *Br J Surg* 1990; 77: 876-877.
- Orrom WJ, Wong WD, Rothenberger DA, Jensen LL. Evaluation of an air-filled microballoon and minitransducer in the clinical practice of anorectal manometry. *Dis Colon Rectum* 1990a; 33: 594-597.
- Parks AG. A note on the anatomy of the anal canal. *Proc Roy Soc Med* 1954 :997-998.
- Parks AG. Modern concepts of the anatomy of the ano-rectal region. *Postgrad Med J* 1958; 34: 360-366.
- Parks AG, Porter NH, Melzack J. Experimental study of the reflex mechanism controlling the muscles of the pelvic floor. *Dis Colon Rectum* 1962; 5: 407-414.
- Parks AG, Porter NH, Hardcastle JD. The syndrome of the descending perineum. *Proc R Soc Med* 1966; 59: 477-482.
- Parks AG. The management of fissure-in-ano. *Hosp Med* 1967; 1: 737-431.
- Parks AG, Swash M, Urich H. Sphincter denervation in anorectal incontinence and rectal prolapse. *Gut* 1977; 18: 656-665.
- Pedersen IK, Christiansen J. A study of the physiological variation in anal manometry. *Br J Surg* 1989; 76: 69-71.
- Penninckx F, Lestar B, Kerremans R. The internal anal sphincter: Mechanisms of control and its role in maintaining anal continence. In: Henry MM, ed. *Baillière's Clinical Gastroenterology*. London: Baillière Tindall, 1992; 6(1): 193-214.
- Percy JP, Neill ME, Parks AG, Swash M. Electrophysiological study of motor nerve supply of the pelvic floor. *Lancet* 1980; i: 16-17.

- Perry RE, Blatchford GJ, Christensen MA, Thorson AG, Attwood SEA. Manometric diagnosis of anal sphincter injuries. *Am J Surg* 1990; 159: 112-117.
- Pezim MF, Spencer RJ, Stanhope CR, Beart RW, Ready RL, Ilstrup DM. Sphincter repair for fecal incontinence after obstetrical and iatrogenic injury. *Dis Colon Rectum* 1987; 30: 521-525.
- Phillips SF, Edwards AW. Some aspects of anal continence and defaecation. *Gut* 1965;6: 396-406.
- Porter NH. A physiological study of the pelvic floor in rectal prolapse. *Ann R Coll Surg Engl* 1962; 31: 379-404.
- Power RMH. Embryological development of the levator ani muscle. *Am J Obstet & Gynec* 1948; 55 : 367-381.
- Ravikumar TS, Sridhar S, Rao RN. Subcutaneous lateral internal sphincterotomy. *Dis Colon Rectum* 1982; 25: 798-801.
- Read MA, Read NW. Role of anorectal sensation in preserving continence. *Gut* 1982; 23: 345-347.
- Read MG, Read NW, Haynes WG, Donnelly TC, Johnson AG. A prospective study of the effect of haemorrhoidectomy on sphincter function and faecal incontinence. *Br J Surg* 1982; 69: 396-398.
- Read NW, Bartolo DCC, Read MG. Differences in anal function in patients with incontinence to solids and in patients with incontinence to liquids. *Br J Surg* 1984; 71: 39-42.
- Read NW, Sun WM. Anorectal manometry. In: Henry MM, Swash M, eds. *Coloproctology and the pelvic floor*. London: Butterworth-Heinemann, 1992: 119-45.
- Roberts JP, Williams NS. The role and technique of ambulatory manometry In: Henry MM, ed. *Baillière's Clinical Gastroenterology*. London: Baillière Tindall, 1992; 6(1): 163-178.
- Robin C and Cadiat. Sur la structure et les rapports des teguments dans les regions anale, vulvaire et du col uterin. *J Anat & Physiol*. 1874; 10: 589-620.
- Roe AM, Bartolo DCC, Mortensen NJMcC. New method for assessment of anal sensation in various anorectal disorders. *Br J Surg* 1986; 73: 310-312.
- Rogers J, Hayward MP, Henry MM, Misiewicz JJ. Temperature gradient between the rectum and anal canal: evidence against the role of temperature sensation as a sensory modality in the anal canal of normal subjects. *Br J Surg* 1988a;75: 1083-1085.

- Rogers J, Henry MM, Misiewicz JJ. Combined sensory and motor deficit in primary neuropathic faecal incontinence. *Gut* 1988b; 29: 5-9.
- Rogers J, Henry MM and Misiewicz JJ. Disposable pudendal nerve stimulator: evaluation of the standard instrument and new device. *Gut* 1988c; 29: 1131-1133.
- Rogers J, Laurberg S, Misiewicz JJ, Henry MM, Swash M. Anorectal physiology validated: a repeatability study of the motor and sensory tests of anorectal function. *Br J Surg* 1989; 76: 607-609.
- Roux c. Contributions to the knowledge of the anal muscles in man. *Arch Mike Anat* 1881; 19: 721
- Rudinger N. *Topographisch-chirurgische Anatomie des Menschen*. Stuttgart: Cotta JG, 1873-79.
- Sakaniwa M, Sawaguchi S, Ohkawa H, Ikebukuru K. Computerised analysis of anorectal manometry. *Prog Ped Surg* 1989; 24: 21-32.
- Santorini GD. *Septem decim tabulae edit et explici*. Parone: Mich. Geradi, 1715; tabula 15.
- Scharli AF, Keisewetter WB. Defaecation and continence: some new concepts. *Dis Colon Rectum* 1970; 13: 81-107.
- Schuster MM, Hendrix TR, Mendeloff AI. The internal anal sphincter response: manometric studies on its normal physiology, neural pathways, and alteration in bowel disorders. *J Clin Invest* 1963; 42: 196-207.
- Schuster MM. The riddle of the sphincters. *Gastroenterology* 1975; 69 (1): 249-262.
- Schwartz MS, Gordon JA, Swash M. Slowed nerve conduction with wrist flexion in carpal tunnel syndrome. *Ann Neurol* 1980; 8: 69-71.
- Schweiger M. Method of determining individual contribution of voluntary and involuntary anal sphincters to resting tone. *Dis Colon Rectum* 1979; 22: 415-416.
- Shafik A. A new concept of the anatomy of the anal sphincter mechanism and the physiology of defecation. The external anal sphincter: a triple loop system. *Invest Urol* 1975a; 12: 412-419.
- Shafik A. A new concept of the anatomy of the anal sphincter mechanism and the physiology of defecation. II. Anatomy of the levator ani muscle with special reference to the puborectalis. *Invest Urol* 1975b; 13: 175-182.

- Shafik A. A new concept of the anatomy of the anal sphincter mechanism and the physiology of defecation. 111. The longitudinal anal muscle: Anatomy and role in sphincter mechanism. *Invest Urol* 1976; 13: 271-277.
- Shafik A. A new concept of the anatomy of the anal sphincter mechanism and the physiology of defecation. XIV. Anal canal. A fallacious embryological and anatomical entity. *Am J Proc Gastro Col Rect Surg* 1982; 33: 14-36.
- Shepherd JJ, Wright PG. The response of the internal anal sphincter in man to stimulation of the presacral nerve. *Am J Dig Dis* 1968; 13: 421-427.
- Shiono P, Klebanoff MA, Carey JC. Midline episiotomies: more harm than good? *Obstet Gynecol* 1990; 75: 765-70.
- Sieber EH, Kroon JD. Morbidity in the third degree laceration. *Obstet Gynecol* 1962; 19: 677-80
- Singh S, Poulson R, Hanby A, Wright NA, Sheppard MC, Langman MJS. Expression of oestrogen receptors and an oestrogen induced protein in large bowel mucosa and cancers. *Gut* 1992; 33(1 suppl): S34.
- Sir Alan Parks 1920-1982; Surgeon and Scientist. *Ann R Coll Surg Eng. Bibliography and Proceedings of the Memorial Symposium* 1983.
- Sleep J, Grant A, Garcia J, Elbourne D, Spencer J, Chalmers I. West Berkshire perineal management trial. *Br Med J* 1984; 289: 587-90.
- Sleep J, Roberts J, Chalmers I. Care during the second stage of labour. In: *Effective care in pregnancy and childbirth*. Chalmers I, Enkin M, Kierse MJNC, eds. Oxford: Oxford University Press, 1991: 1130-1143.
- Small KA, Wynne JM. Evaluating the pelvic floor in obstetric patients. *Aust NZ J Obstet Gynaecol* 1990; 30: 41-45.
- Snooks S, Swash M, Setchell M, Henry MM. Injury to innervation of pelvic floor sphincter musculature in childbirth. *Lancet* 1984; ii: 564-550.
- Snooks S, Swash M, Henry MM. Faecal incontinence after anal dilatation. *Br J Surg* 1984a; 71: 617-618.
- Snooks SJ, Henry MM, Swash M. Faecal incontinence due to external sphincter division in childbirth is associated with damage to the innervation of the pelvic floor musculature: a double pathology. *Br J Obstet Gynaecol* 1985; 92: 824-828.
- Snooks SJ, Swash M. Nerve stimulation techniques. In Henry MM and Swash M. eds. *Coloproctology and the pelvic floor*. Butterworths: London, 1985 :112-128.

- Snooks SJ, Henry MM, Swash M. Anorectal incontinence and rectal prolapse: differential assessment of the innervation to puborectalis and external anal sphincter muscles. *Gut* 1985b; 26: 470-476.
- Snooks SJ, Swash M, Henry MM, Setchell M. Risk factors in childbirth causing damage to the pelvic floor innervation. *Int J Colorect Dis* 1986; 1:20-24.
- Snooks SJ, Swash M, Mathers SE, Henry MM. Effect of vaginal delivery on the pelvic floor: a 5-year follow-up. *Br J Surg* 1990; 77: 1358-1360.
- Sorensen SM, Bondesen H, Istre O, Vilmann P. Perineal rupture following vaginal delivery. *Acta Obstet Gynecol Scand* 1988; 67: 315-318.
- Speakman CTM, Hoyle CHV, Kamm MA, Henry MM, Nicholls RJ, Burnstock G. Adrenergic control of the internal anal sphincter is abnormal in patients with idiopathic faecal incontinence. *Br J Surg* 1990; 77: 1342-1344.
- Speakman CTM, Burnett SJD, Kamm MA, Bartram CI. Sphincter injury after anal dilatation demonstrated by anal endosonography. *Br J Surg* 1991; 78: 1429-1430.
- Speakman CTM, Kamm MA. The internal anal sphincter - new insights into faecal incontinence. *Gut* 1991; 32: 345-346.
- Stalberg E, Thiele B. Motor unit fibre density in the extensor digitorum communis muscle. *J Neurol Neurosurg Psychiat* 1975; 386: 874-880.
- Stelzner F. *Die Anorektalen fisteln*. 3 Aufl Berlin: Springer-Verlag, 1981: pp 1-30.
- Stonesifer GL, Jr., Murphy GP, Lombardo CR. The Anatomy of the Anorectum. *Am J Surg* 1960; 100: 666-671.
- Sun WM, Donnelly TC, Read NW. Impaired internal anal sphincter in a sub-group of patients with idiopathic faecal incontinence. *Gastroenterology* 1989; 97:130-35.
- Sun WM, Read NW. Anorectal function in normal subjects: effect of gender. *Int J Colorect Dis* 1989; 4: 188-196.
- Sun WM, Read NW, Miner PB. Relation between rectal sensation and anal function in normal subjects and patients with faecal incontinence. *Gut* 1990a; 31: 1056-1061.
- Sun WM, Read NW, Miner PB, Kerrigan DD, Donnelly TC. The role of transient internal sphincter relaxation in faecal incontinence? *Int J Colorect Dis* 1990b; 5: 31-36.

- Sun WM, Peck RJ, Shorthouse AJ, Read NW. Haemorrhoids are associated not with hypertrophy of the internal sphincter, but with hypertension of the anal cushions. *British Journal of Surgery* 1992; 79: 592-594.
- Sunderland S. The mechanical properties of peripheral nerve trunks. In: *Nerves and nerve injuries*. 2nd ed. Edinburgh: Churchill Livingstone, 1978: 62-66.
- Sutton D. *Textbook of Radiology and Imaging*. London: Churchill Livingstone, 1980: 1339-1345.
- Swash M. Electromyography in pelvic floor disorders. In: Henry MM, Swash M, eds. *Coloproctology and the pelvic floor*. London: Butterworth-Heinemann, 1992:184-95.
- Swash M, Snooks SJ. Motor nerve conduction studies of the pelvic floor innervation. In Henry MM and Swash M. eds. *Coloproctology and the pelvic floor*. Butterworth-Heinemann: London, 1992: 196-206.
- Swash M, Schwartz MS. *Neuromuscular Diseases: a practical approach to diagnosis and management*. 2nd ed. London: Springer-Verlag, 1988.
- Swash M, Gray A, Lubowski DZ, Nicholls RJ. Ultrastructural changes in internal anal sphincter in neurogenic faecal incontinence. *Gut* 1988; 29; 1692-1698.
- Taverner D, Smiddy FG. An electromyographic study of the normal function of the external anal sphincter and pelvic diaphragm. *Dis Colon Rectum* 1959; 2: 153-160.
- Taylor BM, Beart RW Jr, Phillips SF. Longitudinal and radial variations of pressure in the human anal canal. *Gastroenterology* 1984; 86: 693-697.
- Thacker SB, Banta DH. Benefits and risks of episiotomy: An interpretative review of the English language literature, 1860-1980. *Obstet Gynecol Surv* 1983; 38(6): 322-38.
- Thomas TM, Egan M, Walgrove A, Meade TW. The prevalence of faecal and double incontinence. *Community Medicine* 1984; 6: 216-220.
- Thompson P. *The Myology of the pelvic Floor*. London: Newton, McCorquodale & co.,1899.
- Thompson DJ. No Episiotomy. *Aust NZ J Obstet Gynaecol* 1987; 27: 18-20.
- Thorp JM Jr, Bowes WA Jr. Episiotomy: can its routine use be defended? *Am J Obstet Gynecol*. 1989; 160: 1027-30.

- Tjandra JJ, Milsom JW, Stolfi VM, Lavery I, Oakley J, Church J, Fazio V. Endoluminal ultrasound defines anatomy of the anal canal and pelvic floor. *Dis Colon Rectum* 1992;35:465-470.
- Tjandra JJ, Milsom JW, Schroeder T, Fazio VW. Endoluminal ultrasound is preferable to electromyography in mapping anal sphincteric defects. *Dis Colon Rectum* 1993; 36: 689-692.
- Tobin GW, Brocklehurst JC. faecal incontinence in residential homes for the elderly: prevalence, aetiology and management. *Age and Ageing* 1986; 15: 41-46.
- Uhlenhuth E. Problems in the anatomy of the pelvis. Philadelphia: Lippincott, 1953.
- Vacca A, Kierse MLNC. Instrumental vaginal delivery. In: Effective care in pregnancy and childbirth. Chalmers I, Enkin M, Kierse MJNC, eds. Oxford: Oxford University Press, 1989: 1216-1233.
- Van Thiel DH, Gavalier JS, Joshi SN, Sara SK, Stremple J. Heartburn of pregnancy. *Gastroenterology* 1977; 72: 666-668.
- Varma KK, Stephens D. Neuromuscular reflexes of anal incontinence. *Aust N Z J Surg* 1972; 41: 263-272.
- Varma JS, Smith AN. Internal anal sphincter damage in radiation proctitis. *Gut* 1984; 25: 564.
- Varma JS, Smith AN, Busuttill A. Correlation of clinical and manometric abnormalities of rectal function following chronic radiation injury. *Br J Surg* 1985; 72: 875-878.
- Vela AR, Rosenberg AJ. Anorectal manometry: A new simplified technique. *Am J Gastroenterology* 1982; 77: 486-490.
- Vesalius A. De humani corporis fabrica de recti intestini musculis. 1st ed. Brussels 1543; 228.
- Wald A, Van Thiel DH, Hoehstetter L, et al. Effect of pregnancy on gastrointestinal transit. *Dis Dig Sci* 1982; 27: 1015-1018.
- Walker MPR, Farine D, Rolbin SH and Ritchie JWK. Epidural anesthesia, episiotomy and obstetric laceration. *Obstet Gynecol* 1991; 77: 668-671.
- Walker WA, Rothenberger DA, Goldberg SM. Morbidity of internal sphincterotomy for anal fissure and stenosis. *Dis Colon Rectum* 1985; 28: 832-835.
- Walker MPR, Farine D, Rolbin SH and Ritchie JWK. Epidural anesthesia, episiotomy and obstetric laceration. *Obstet Gynecol* 1991; 77: 668-71.

- Walls EW. *The Scientific Basis of Medicine: Annual Reviews*. London: Athlone Press, 1963; p.113.
- Wankling WJ, Brown BH, Collins CD, Duthie HL. Basal electrical activity in the anal canal in man. *Gut* 1968; 9: 457-460.
- Watanabe H, Kaiho H, Tanaka M, Tarasawa Y. Diagnostic application of ultrasonotomography to the prostate. *Invest Urol* 1971; 8: 548-559.
- Wells PNT. Clinical applications of ultrasonics. In: Watson EW, ed. *IEE Medical Electronics Monographs*. London: 1971: 145-180.
- Wells PNT. Developments in medical electronics. *World Med Electron* 1966; 4: 272.
- Wells PNT. History. In: De Vlieger M, ed. *Handbook of clinical ultrasound*. New York: John Wiley and sons, 1978: 3-13.
- Wells PNT. Real-Time Scanning Systems. In: Wells PNT and Ziskin MC, eds. *New Techniques and Instrumentation in Ultrasonography*. London: Churchill Livingstone, 1980: 69-84.
- Wendell-Smith CP. Studies on the morphology of the pelvic floor. PhD thesis. University of London, U.K. 1967.
- Wendell-Smith CP and Wilson PM. In Philipp EE, Barnes J and Newton M, eds. *Scientific Foundations in Obstetrics and Gynaecology*. 3rd ed. London: Heinemann, 1986: 98.
- West CP, McNeilly AS. Hormonal profiles in lactating and non-lactating women immediately after delivery and their relationship to breast engorgement. *Br J Obstet Gynaecol* 1979; 86: 501-506.
- Whitehead WE, Orr WC, Engel BT, Schuster MM. External anal sphincter response to rectal distension: learned response or reflex. *Psychophysiology* 1982; 19: 57-62.
- Wild JJ. The use of ultrasonic pulses for the measurement of biologic tissues and the detection of tissue density changes. *Surg* 1949; 27(2): 183-188.
- Wild JJ, Reid JM. Echographic tissue diagnosis. *Proceedings at the Fourth Annual Conference on Ultrasonic Therapy* 1955:1
- Wild JJ, Reid JM. Progress in the techniques of soft tissue examination by 15 M.C. pulsed ultrasound. *Proceedings, symposium on ultrasound in medicine and biology*, June 1955. Publication no 3, 1957, American Institute of Biological Sciences.

- Wild JJ. A historical review of the genesis and early development of intrusive pulse-echo ultrasound. In: Feifel G, Hildebrandt U, Mortensen NJMcC. eds. *Endosonography in Gastroenterology, Gynecology and Urology*. London: Springer-Verlag, 1990: 1-19.
- Wilde RF. The anal intermuscular septum. *Br J Surg* 1949; 36: 279-285.
- Williams NS. Faecal Incontinence. In: Kumar D, Waldron DJ, Williams NS, eds. *Clinical measurement in coloproctology*. London: Springer-Verlag 1991:109-121.
- Williamson JL, Nelson RL, Orsay C, Pearl RK, Abcarian H. A comparison of simultaneous longitudinal and radial recordings of anal canal pressures. *Dis Colon Rectum* 1990; 33: 201-206.
- Wilson PM. Anchoring mechanisms of the ano-rectal region. *S Afr Med J* 1967; 36: 1138-1143.
- Winkler G. Remarques sur la morphologie et l'innervation du muscle releveur de l'anus. *Archives & Anatomie, d'Histologie et d'Embryo* 1958; 41: 77-95.
- Wunderlich M, Swash M. The overlapping innervation of the two sides of the external anal sphincter by the pudendal nerve. *J Neuro Sci* 1983; 59: 91-109.

PROTOCOL - The Effect of Childbirth on the Anal Sphincters. A. SULTAN

Patient's Name.....Research Case No.....

Hospital Number.....Telephone.....

Age.....yrs .....Height.....

Race...White/Black/Asian/Other[ ].....Weight.....

Relevant Past Medical History.....

Time exam ..... at 34 weeks ..... 6 wks pp

Date ..... / ..... / ..... .....

Details of Bowel Habit

No stools/week ..... [ ] ..... [ ]  
 Straining >25% ..... Y/N [ ] ..... Y/N [ ]  
 Regular use laxatives ..... Y/N [ ] ..... Y/N [ ]  
 Ano-rectal bleeding ..... Y/N [ ] ..... Y/N [ ]  
 Tenesmus ..... Y/N [ ] ..... Y/N [ ]  
 Urgency ..... Y/N [ ] ..... Y/N [ ]  
 Soiling ..... Y/N [ ] ..... Y/N [ ]  
 Incontinence ..... Y/N [ ] ..... Y/N [ ]  
 if YES Flatus/Liquid stool/Solid stool ..... [ ] ..... [ ]  
 Urinary Stress Incontinence. .... Y/N [ ] ..... Y/N [ ]

Clinical Examination

Inspection anal canal-

Soiling ..... Y/N [ ] ..... [ ]  
 Prolapse ..... Y/N [ ] ..... [ ]  
 Haemorrhoids ..... Y/N [ ] ..... [ ]  
 Scars ..... Y/N [ ] ..... [ ]  
 Perineal descent ..... Y/N [ ] ..... [ ]  
 Vagino-Anal Distance (post. fourchette to mid-anus). .... [ ] cm.

Anal Manometry

Resting pressure ..... [ ] mm. Hg. .... [ ]  
 Contraction (Squeeze) pressure ..... [ ] mm. Hg ..... [ ]  
 Anal length ..... [ ] cm.

Pudendal Nerve Terminal Motor Latencies

PNTML performed ..... Y/N [ ] ..... Y/N [ ]  
 Right ..... [ ] msec ..... [ ] msec  
 Left ..... [ ] msec ..... [ ] msec

Anal Endosonography

IAS intact ..... Y/N [ ] ..... Y/N [ ]  
 -if defect hrs ..... [ ] ..... [ ]  
 EAS intact ..... Y/N [ ] ..... Y/N [ ]  
 -if defect hrs ..... [ ] ..... [ ]  
 -echogenicity defect hypEr/hypO/Amorphous ..... [ ] ..... [ ]  
 Perineal body Intact/Disrupted ..... [ ] ..... [ ]  
 Video Record No ..... [ / ..... ] ..... [ / ..... ]  
 Comment

Obstetric History

Parity . . . . . [ ] [ ] [ ] [ ]  
Date delivery . . . . . --/--/-- --/--/-- --/--/--  
Birthweight (Kg) . . . . . [ ] [ ] [ ] [ ]  
Gestation (wks) . . . . . [ ] [ ] [ ] [ ]  
Vaginal/Caesarian . . . . . [ ] [ ] [ ] [ ]  
if caesarian eEmergency/eLective . . . . . [ ] [ ] [ ] [ ]  
if emergency length of-  
Labour hrs . . . . . [ ] [ ] [ ] [ ]  
Pushing hrs . . . . . [ ] [ ] [ ] [ ]

Labour and Delivery

Initiation-  
Spontaneous/Induced . . . . . [ ] [ ] [ ] [ ]  
Augmentation ( Y/N ) . . . . . [ ] [ ] [ ] [ ]  
Presentation and Position  
Cephalic/Breech . . . . . [ ] [ ] [ ] [ ]  
If Cephalic : occ Ant/ occ Post . . . . . [ ] [ ] [ ] [ ]  
Head circumference (cm) . . . . . [ ] [ ] [ ] [ ]  
Instrumentation-  
No/ Outlet Forceps/Rotational Forceps/Ventouse . . . [ ] [ ] [ ] [ ]

Analgesia-

Local/General/Epidural/Pethidine/eNtonox . . . . . [ ] [ ] [ ] [ ]

Maternal Position-

SUPine/SITting/Lateral . . . . . [ ] [ ] [ ] [ ]  
Labour Duration  
First Stage . . . . . [ ] [ ] [ ] [ ]  
Second Stage  
Active hrs . . . . . [ ] [ ] [ ] [ ]  
Passive hrs . . . . . [ ] [ ] [ ] [ ]  
Total recorded . . . . . [ ] [ ] [ ] [ ]  
Third Stage . . . . . [ ] [ ] [ ] [ ]

Perineum Intact (Y/N) . . . . . [ ] [ ] [ ] [ ]

Midline/Posterolateral Episiotomy . . . . . [ ] [ ] [ ] [ ]  
Extension ( Y/N ) . . . . . [ ] [ ] [ ] [ ]  
Tears (0 =None/1=1st deg/2=2nd/3=3rd) . . . . . [ ] [ ] [ ] [ ]  
Suture Material used  
Dexon/Vicryl/Chromic Catgut/Unknown . . . . . [ ] [ ] [ ] [ ]

Repaired by-

Midwife/Medical Student/Doctor . . . . . [ ] [ ] [ ] [ ]

Pelvic floor exercises

No/Occasionally/Religiously . . . . . [ ] [ ] [ ] [ ]  
Comment

Any further follow-up recommended :

ANONYMOUS OBSTETRIC QUESTIONNAIRE

AIM: To assess the knowledge, experience and training of those performing perineal operations.

PLEASE PLACE AN X OR CIRCLE YOUR ANSWER WHERE APPROPRIATE.

DOCTOR.....[ ]                      MIDWIFE.....[ ]

CAREER SHO/ GPT/ GP/ REG                      ST.MW/ SMW/ SISTER

YEARS IN O & G GRADE..[ ]                      YEARS QUALIFIED.....[ ]

1. How many episiotomy incisions have you performed ?

< 25.....25 - 50.....50 - 100.....> 100

2. For how many episiotomy repairs have you been supervised ?

< 5.....6-10.....11-15.....16-20.....>21

3. How many episiotomies or tears have you repaired without supervision ?

<10.....11-20.....21-30.....31-40.....>50

4. Name the muscles that you cut through when performing an uncomplicated episiotomy :- I don't know.....[ ].

(a) postero-lateral :

(b) midline :

I don't know.....[ ]

I don't know.....[ ]

.....

.....

.....

.....

.....

.....

5. What in your opinion is the closest distance between the posterior vaginal wall and the external anal sphincter ?

I don't know.....[ ]                      answer.....[ ] cms.

6. In the classification that you follow, how many degree tears of the perineum can you describe ? ( ring your answer )

I don't know.....[ ]                      0....1...2....3...4...5....degree  
continued.....

7. Which of the following would you record as a third degree tear?

	YES	NO	DON'T KNOW
<b>Striated muscle</b>			
External anal sphincter exposed only?..[ ]	[ ]	[ ]	[ ]
External anal sphincter torn only?.....[ ]	[ ]	[ ]	[ ]
<b>Smooth muscle</b>			
Internal anal sphincter exposed ?.....[ ]	[ ]	[ ]	[ ]
Internal anal sphincter torn ?.....[ ]	[ ]	[ ]	[ ]
Anorectal mucosa & muscle torn?.....[ ]	[ ]	[ ]	[ ]
Torn urethra ?.....[ ]	[ ]	[ ]	[ ]
Torn cervix ?.....[ ]	[ ]	[ ]	[ ]
All extended episiotomies ?.....[ ]	[ ]	[ ]	[ ]

8. How many third degree tears have you seen ?.....+/-[ ]

9. How many third degree tears have you repaired ?...+/-[ ]

10. In your opinion would you consider it better practice to perform an episiotomy or allow a tear to occur ?

episiotomy...[ ]      tear...[ ]      don't know...[ ]

comments:-

.....  
 .....  
 .....

11. Have you ever come across any women suffering from flatus or faecal incontinence. If yes, how many ?

.....  
 .....

11. Do you consider the level of training of a good standard in the following fields at the time of performing or repairing your first episiotomy unsupervised ?

	YES	NO
Anatomy of the perineum and anal sphincters.....[ ]	[ ]	[ ]
Performing episiotomies.....[ ]	[ ]	[ ]
Repairing episiotomies & 2nd degree tears.....[ ]	[ ]	[ ]
Recognising 3rd degree tears.....[ ]	[ ]	[ ]
Repairing 3rd degree tears.....[ ]	[ ]	[ ]

Any comments?

.....  
 .....  
 .....