



*Your complimentary
use period has ended.
Thank you for using
PDF Complete.*

[Click Here to upgrade to
Unlimited Pages and Expanded Features](#)

Effect of Bronchial Artery Embolisation when superimposed on Pulmonary Tuberculosis (either active or sequelae Tuberculosis) on the Success of Bronchial Artery Embolisation

By

Mayuri Govind

(Student Number: 933481893)

SUBMITTED TO THE UNIVERSITY OF KWA ZULU NATAL

In fulfillment of the requirements for the degree MMed Radiology

Master of Medicine in Diagnostic Radiology

Faculty of Health Sciences

UNIVERSITY OF KWA ZULU NATAL

Date of Submission: 2 November 2011

Supervisor: Dr J Maharajh (Department of Radiology – King Edward VIII Hospital)



*Your complimentary use period has ended.
Thank you for using PDF Complete.*

[Click Here to upgrade to Unlimited Pages and Expanded Features](#)

I, Mayuri Govind, declare that:

- (i) The research reported in this dissertation, except where otherwise indicated, and is my original work.
- (ii) This dissertation has not been submitted for any degree or examination at any other university.
- (iii) This dissertation does not contain other persons' data, pictures, graphs or other information, unless specifically acknowledged as being sourced from other persons.
- (iv) This dissertation does not contain other persons' writing, unless specifically acknowledged as being sourced from other researchers. Where other written sources have been quoted, then:
 - a) Their words have been re-written but the general information attributed to them has been referenced;
 - b) Where their exact words have been used, their writing has been placed inside quotation marks, and referenced.
- (v) Where I have reproduced a publication of which I am an author, co-author or editor, I have indicated in detail which part of the publication was actually written by myself alone and have fully referenced such publications.
- (vi) This dissertation does not contain text, graphics or tables copied and pasted from the Internet, unless specifically acknowledged, and the source being detailed in the dissertation and in the References sections.

Signed: _____ Date: _____



PDF
Complete

*Your complimentary
use period has ended.
Thank you for using
PDF Complete.*

[Click Here to upgrade to
Unlimited Pages and Expanded Features](#)

This work is dedicated to Ashveer and Kirti.



PDF
Complete

*Your complimentary
use period has ended.
Thank you for using
PDF Complete.*

[Click Here to upgrade to
Unlimited Pages and Expanded Features](#)

Dr Kalpesh Girish Mody and Dr Jaynund Maharajh for their invaluable support and encouragement in completion of the study.

Dr Gareth Bydawell for assistance in interpretation of the imaging findings.

Mr Stephan van der Linde for statistical support.

Title page	i
Declaration	ii
Dedication	iii
Acknowledgements	iv
Table of contents	v
List of tables	ix
List of figures	x
Glossary of abbreviations	xi
Abstract	xii
<u>CHAPTER 1: INTRODUCTION AND LITERATURE REVIEW</u>	1
1.1 Demographic data related to Pulmonary Tuberculosis and Human Immunodeficiency Virus infection	1
1.2 Bronchial Artery Embolisation at Inkosi Albert Luthuli Central Hospital	3
1.3 Definition of massive haemoptysis	4
1.4 Aetiology of massive haemoptysis	4
1.5 Pathophysiology of pulmonary Tuberculosis	5
1.6 Diagnosis of pulmonary Tuberculosis	7
1.7 Pulmonary Tuberculosis in HIV positive patients	8
1.8 Radiological findings	9
1.8.1 Chest radiograph and HRCT chest	9
1.8.1.1 Role of imaging and modalities	9



PDF Complete

Your complimentary use period has ended. Thank you for using PDF Complete.

[Click Here to upgrade to Unlimited Pages and Expanded Features](#)

	Analysis on imaging	10
1.8.2	Bronchial artery embolisation	12
1.8.2.1	Role of the procedure	12
1.8.2.2	Technique and complications	13
1.9	Management options and protocols at IALCH	19
<u>CHAPTER 2: METHODS</u>		20
2.1	Study design	20
2.2	Study participants	20
2.3	HRCT chest procedure	23
2.4	Bronchial artery embolisation procedure	23
2.5	Laboratory investigations	25
2.5.1	Microbiology	25
2.5.2	Virology	26
2.6	Ethical considerations	27
2.7	Data capture and analysis	27
2.8	Outcome measures	28
2.8.1	HRCT	28
2.8.2	BAE	29
2.9	Clinical records	30

	31
3.1 Patient demographics	32
3.1.1 Age and HIV status	32
3.1.2 Gender and HIV status	33
3.1.3 HIV status and CD4 levels	33
3.1.4 Previous bronchial artery embolisation	34
3.2 Diagnosis of Pulmonary Tuberculosis	35
3.3 Imaging Findings	36
3.4 Outcome	38
3.4.1 Clinical versus procedural outcome	39
3.4.2 Clinical outcome	40
3.4.3 Bronchial artery embolisation outcome	41
3.4.3.1 Selection and embolisation of vessels	42
3.4.3.2 Reasons for technical failure of the procedure and HIV status	43
3.4.4 CD4 level	44
3.4.5 Complications and mortality	46
<u>CHAPTER 4: DISCUSSION</u>	47
4.1 Outcome	49
4.2 Imaging findings	49
4.2.1 High resolution CT scan	49
4.2.2 Bronchial artery embolisation	51



PDF Complete

Your complimentary use period has ended. Thank you for using PDF Complete.

[Click Here to upgrade to Unlimited Pages and Expanded Features](#)

	54
5.1 Study benefits	54
5.2 Study limitations and suggestions	55
5.3 Conclusions	56

ANNEXURES

Annexure 1: Literature review summary	57
Annexure 2: Checklist for independent radiologist	59
Annexure 3: Universal precautions for exposure to blood and blood products ó IALCH	60
Annexure 4: Microbiology: handling of sputum sample	62
Annexure 5: Protocol approval by postgraduate committee UKZN	63
Annexure 6: Ethical approval by Biomedical Research Ethics Committee -UKZN	64
Annexure 7: Permission to conduct study at IALCH	65
Annexure 8: Data capture form	67

<u>REFERENCES</u>	68
--------------------------	----

Table 1:	Reasons for exclusion of cases	31
Table 2:	Correlation of method of diagnosis of PTB and HIV status	36
Table 3:	Correlation of imaging study availability and HIV status	36
Table 4:	Correlation of zonal distribution of pathology on imaging findings and HIV status	37
Table 5:	Correlation of pathological findings on imaging studies and HIV status	38
Table 6:	Correlating clinical and procedural outcome	39
Table 7:	Comparing procedural and clinical success based on HIV status	39
Table 8:	Correlation of clinical follow up HIV status	41
Table 9:	Correlation of procedural outcome and HIV status	41
Table 10:	Incidence of vessel selection and embolisation	42
Table 11:	Correlation of the incidence of selection and embolisation of arteries with HIV status	43
Table 12:	Correlation of reasons for failure to embolise and HIV status	44
Table 13:	Correlating CD4 Value and clinical and procedural Success	45

Figure 1:	Worldwide distribution of HIV-PTB coinfection in 2007 (Duplicated from WHO)	2
Figure 2:	Histogram of age distribution and HIV status of included cases	32
Figure 4:	Histogram of gender distribution and HIV status of included cases	33
Figure 5:	Histogram of CD4 levels of included cases	34

AFB	ACID-fast Bacilli
AIDS	Acquired Immune Deficiency Syndrome
BAE	Bronchial Artery Embolisation
BCG	Bacille Calmette-Guerin
CCF	Congestive Cardiac Failure
CD4	Cluster of Differentiation 4
CMSA	College of Medicine of South Africa
COAD	Chronic Obstructive Airways Disease
CT scan	Computed Tomography Scan
CXR	Chest X-ray
F	French
HIV	Human Immunodeficiency Virus
HRCT	High Resolution Computed Tomography
IALCH	Inkosi Albert Luthuli Central Hospital
KZN	Kwa Zulu Natal
LAP	Lymphadenopathy
MDR	MultiDrug Resistant
MGIT	Mycobacterial Growth Indicator Tube
MOTT	Mycobacterium other than Tuberculosis
MTB	Mycobacterium Tuberculosis
MRI	Magnetic Resonance Imaging
p value	Probability value
PACS	Picture Archiving and Communication System
PCR	Polymerase Chain Reaction
PTB	Pulmonary Tuberculosis
PVA	Polyvinyl Alcohol
TB	Tuberculosis
WHO	World Health Organisation
ZN	Ziehl-Neelson

Pulmonary Tuberculosis (PTB) rates in Kwa Zulu Natal (KZN) is amongst the highest in the South Africa and is often associated with Human Immunodeficiency Virus (HIV) co-infection. Bronchial Artery Embolisation (BAE) is an expensive, time consuming procedure requiring operator skill and is accompanied by risk to both patient and operator.

Aim:

To investigate the impact of HIV infection when superimposed on PTB (active or sequelae) on the success of BAE.

Method:

A retrospective cross sectional study with descriptive and analytical components of the BAE procedure between January 2006 and December 2007 was performed on sequential BAE studies. These were analyzed for procedural and clinical outcome and reasons for procedural failure were investigated. The impact of CD4 level on procedural and clinical failure was investigated for a subset of cases.

Cases were included if they presented with massive or life threatening haemoptysis with a diagnosis of previous or active PTB (made clinically, radiologically or microbiologically) in whom HIV status is known and where the clinician assessed a need for BAE, but excluded any third or more attempt at the procedure for that patient.

The final sample size after exclusion of 91 cases is 107. Each attempt at BAE was viewed as an individual case. The study population is made up of 74 HIV positive and 33 HIV negative cases. The median CD4 level is 176 cells / microlitre.

Statistically, procedural success does not imply clinically successful outcome. HIV status does not correlate significantly with clinical or procedural results of BAE. CD4 level does not correlate significantly with clinical or procedural results of BAE.

There is no technical reason of statistical significance that impacts on the success of the procedure when correlated with HIV status. These include being unable to select, unable to subselect, unable to engage securely, reflux, presence of fistulae and the presence of spinal feeder arteries.

The complication rate is not statistically significant when correlated with HIV status. The differences in follow up of clinically unsuccessful cases were not significant when correlated with HIV status.

On imaging, all cases demonstrated pathology. No particular zone is significant when correlated with HIV status. The most common finding is parenchymal architectural distortion followed closely by features of active tuberculous infection and no statistical significance is attributed to either when correlated with HIV status. The detection of lymphadenopathy is noted in 19.1% of HIV positive cases and 42.4% of HIV negative cases, and is the only feature of significance when correlated with HIV status.



PDF
Complete

*Your complimentary
use period has ended.
Thank you for using
PDF Complete.*

[Click Here to upgrade to
Unlimited Pages and Expanded Features](#)

Coinfection with HIV does not have an impact on the success of BAE in patients with active or sequelae PTB who present with massive or life threatening haemoptysis.

The rate of technical failure of the procedure suggests that this needs to be performed by persons that are adequately trained. Technical success does not imply clinical success but this finding was not statistically significant when correlated with HIV status. Re-evaluation of the procedure technique and improvements in local practice may produce results that correlate better with international standards.

The literature is extensive on the topic of Bronchial Artery Embolisation (BAE) and its efficacy as a means of treatment and palliation of haemoptysis. There is agreement that BAE is a safe and effective method of management and palliation of haemoptysis. Immediate success rates of the procedure range from 73% by Ramakantan et al in 1996 to 99% by Lee et al in 2008(1, 2). Not all studies have described technical failure and reasons for this. Annexure 1 summarizes details of the studies in the literature including case numbers, reasons for technical failure, etiology of haemoptysis, clinical presentation and whether HIV status was investigated.

1.1 Demographics data related to Pulmonary Tuberculosis (PTB) and Human Immunodeficiency Virus infection (HIV)

By the end of 2007 the province of KwaZulu Natal (KZN) had a population of 10 014 500 accounting for 20.9% of the population of South Africa(3). The province consists of 54% rural settlements and has 8.6% of the population living in informal homes(3).

The number of new cases of pulmonary tuberculosis (PTB) rose from 2006 to 2007 from 88271 to 93204, with an increase of new PTB cases from 37 - 40% (new smear positive 337.6/100000 to 372.7/100 000 people) in that period(3). This incidence is third highest in the country after the Northern and Western Cape (4).

The cure rate of new smear positive cases of PTB for KZN remained the lowest in the country at 45.2% and 52.9% in 2005 and 2007 respectively, with the highest death rate in the country in 2005 of 236 persons per 100 000(3).

with Human Immunodeficiency Virus (HIV) infection in the province was 1 552 590(5). The most common cause of death (57.5%) in the country was Acquired Immune Deficiency Syndrome (AIDS) and the HIV incidence (new cases per year as a percentage of the uninfected population) is the highest in the country at 1.6% of total deaths(3).

In 2006, 7.7% of new global cases of PTB were co-infected with HIV and this rose to 14.8% in 2007(5, 6). The epicenter of the co-epidemic lay in southern Africa (79%) (6). South Africa had the second highest incidence of PTB and HIV infection (following Swaziland) in 2006 and 2007 (5, 6). Figure 1 demonstrates the worldwide distribution of HIV-PTB co-infection in 2007.

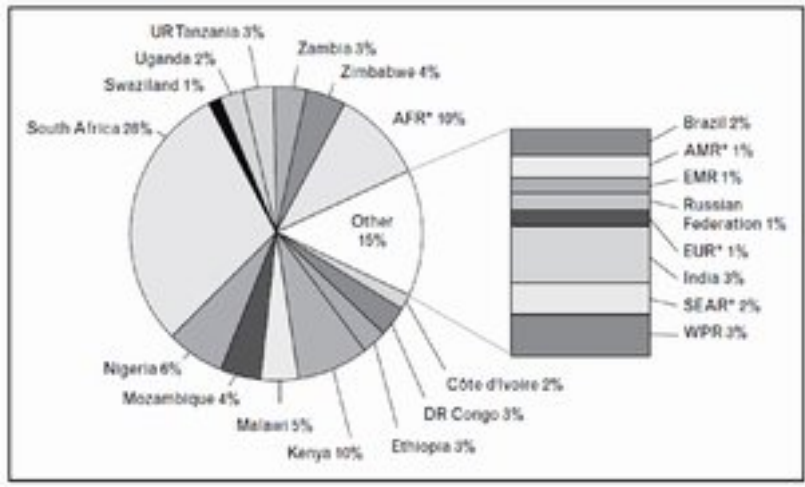


Figure 1: Worldwide distribution of HIV-PTB coinfection shown as a percentage of the global total in 2007. AFR represents all countries in the WHO African region other than those shown separately. AMR represents all countries in the WHO region of the Americas except Brazil. EUR is the WHO European region excluding the Russian Federation. SEAR is the WHO south-east Asia region excluding India (reproduced from the WHO) (6)



Your complimentary use period has ended.
Thank you for using PDF Complete.

[Click Here to upgrade to Unlimited Pages and Expanded Features](#)

Bronchial Artery Embolisation (BAE) at Inkosi Albert Luthuli Central Hospital

(IALCH)

Inkosi Albert Luthuli Central Hospital in Durban has the only public sector Cardiothoracic Unit in the province of KZN and serves as the specialist referral centre for this province and the Eastern Cape as far south as Umtata. The Department presently deals with all types of cardiothoracic surgery other than transplantation. It is an 846 bed hospital with 92 beds afforded to the Cardiothoracic Unit (including paediatric cardiothoracic beds). In 2006 and 2007 the unit had 1379 and 1392 admissions respectively. In 2006 and 2007, 15 and 28 pneumonectomies and 42 and 41 lobectomies respectively, were performed for a diagnosis of bronchiectasis. The vast majority of these cases were on the basis of old pulmonary tuberculosis.

The most common presentation of PTB is haemoptysis and patients presenting with haemoptysis is common at Durban hospitals. Massive haemoptysis is associated with a mortality rate ranging from 30 - 50% (7). In the late 1960s emergency lung resection assisted in reducing the mortality rate, but the overall mortality, especially after emergency surgery as opposed to elective surgery is still high and ranges from 10-38% (7, 8). It has therefore been the role of Bronchial Artery Embolisation (BAE) to temporize the bleeding until elective surgery can be planned while medical therapy is instituted to treat the offending organism that led to structural changes in the lung.

The definition of massive haemoptysis is controversial. Quantitatively it has been defined as expectoration of blood of 100 to 1000mls per 24 hours. The most widely used criterion is the expectoration of 300 to 600mls per 24 hours (9). It is estimated that more than 400mls of blood in the alveolar spaces is sufficient to cause impairment of oxygenation (10) and leads to the morbidity of the patient by asphyxiation rather than exanguination (8) . Observed quantitative expectoration may underestimate the actual volume of blood loss should it remain in the alveoli and expectoration of even a small amount of blood in a person with impaired pulmonary function, such as Chronic Obstructive Airways Disease (COAD) or Congestive Cardiac Failure (CCF), can lead to a life threatening state. Therefore, the definition should include a functional assessment of the effect of the haemoptysis (9).

For the purposes of this study, massive haemoptysis is defined as the expectoration of 300 to 600mls of blood per 24 hours; or less if the result is life threatening and/or required blood transfusion for significant reduction in hemoglobin level; and is not controllable by conservative measures as regarded by the clinician in charge of the patient.

1.4 Aetiology of Massive Haemoptysis

While the etiology of massive haemoptysis in the western world is extensive (led by bronchiectasis caused by Cystic Fibrosis and carcinoma of the bronchus), the most common etiology in sub Saharan Africa is secondary to pulmonary tuberculosis or the sequelae of previous PTB infection such as bronchiectasis (7) followed by bronchogenic carcinoma(5%) (7).

der aspergillosis, lung abscess, bronchiectasis, carcinoma, cystic fibrosis, pneumoma, pulmonary interstitial fibrosis, pneumoconiosis, congenital cardiac and vascular abnormalities, aorto-bronchial fistula, aortic aneurysm, bronchial artery aneurysm or pulmonary artery aneurysm (11).

1.5 Pathophysiology of Pulmonary Tuberculosis

The lungs are the primary site of infection of the bacillus *Mycobacterium Tuberculosis* (MTB), an airborne acid-fast bacteria that is latent in lung parenchyma of all those exposed to it. The disease process manifests when the patient mounts an immune response, leading to clinical symptoms and signs.

Haemoptysis results from embarrassment of the bronchial arteries (consequent to structural alterations in the caliber and integrity of the vessels) in most cases (90%), although embarrassment of other vessels such as the pulmonary arteries (5%) or systemic vessels have been documented as well (9, 11, 12).

Following acute or chronic lung condition, hypoxic vasoconstriction, intravascular thrombosis and vasculitis (13) bronchial artery proliferation occurs (9) as a compensatory mechanism. These are seen angiographically as bronchial arteries larger than 1-2mm in diameter (9). Neovascularity promotes aberrant vasculopathy in terms of arterial-arterial and arterial-venous fistulation. Bronchopulmonary shunts develop within peribronchial inflammatory tissue (9) also contributing to the increase in size of the bronchial and other collateral arteries (9) because of increased blood flow. These enlarged vessels exist in a region of inflammation (acute/chronic)

by bacterial agents or due to exposure to elevated blood pressure (9, 13), and results in extravasation into the bronchoalveolar tree.

Residual damage leads to bronchiectasis, broncholith formation or allows for the formation of an intracavitary mycetoma. These factors contribute to bleeding from the bronchial arteries. In bronchiectasis the hypertrophied bronchial arteries, being systemic arteries, are subject to the systemic arterial pressure and this leads to massive haemoptysis. The most common cause (73%) of bronchiectasis documented in the Western Cape is post tuberculous changes (7).

In treated PTB, residual scarring and cavitation contributes to the fragility of the vessels supplying these regions (9). Other mechanisms of haemoptysis include the formation and rupture of a Rasmussen's aneurysm caused by the erosion of pulmonary artery. Therefore massive haemoptysis can be a presentation of active or treated sequelae of PTB.

Embolisation of the bronchial arteries aims to decrease the perfusion pressure to fragile vessels by occluding the arteries, staunching the vascular compromise and decreasing the likelihood of alveolar flooding and haemoptysis (9). Embolisation should be done close to the abnormality to prevent establishment of non-bronchial systemic collateral vessels later (9).

In order to defend the body against intracellular growth of MTB, Cluster of Differentiation 4 cells (CD4) produce a number of immunological factors and it is the reduction of these factors in HIV infection that leads to an increased risk of developing reactivation or reinfection (14). In addition, the tuberculous granuloma has been associated with an increased HIV viraemia with the risk of death in HIV infected patients with TB doubling that of HIV infection patients without TB with matched CD4 cell counts (15). HIV arteritis would result in inflammation of

unstable and more susceptible to the high pressures of the systemic circulation and therefore, more easily incompetent.

1.6 Diagnosis of Pulmonary Tuberculosis

The diagnosis of PTB is confirmed by the presence of acid-fast bacilli (AFB) on smear or a positive culture of MTB of sputum sample, histological evidence of granuloma responding to appropriate antituberculous treatment or an anatomical diagnosis of tuberculosis at necropsy (16).

In the presence of concurrent HIV infection a higher false negative rate of sputum smears has been found. The literature is contradictory with regards to the confidence interval of sputum positivity rates and culture proven MTB. Smith et al reported that positive acid fast sputum smears in culture proven MTB occur with similar frequency in patients with and without HIV (84 versus 85%) (17) compared with Klein et al who showed a decreased sensitivity of sputum positive smears in culture positive MTB among patients with HIV infection (45 versus 81 percent among patients without HIV)(18).

For patients with HIV, the likelihood of a positive smear was also found to be independent of CD4 counts and drug resistance and Smith et al quotes 58 vs 50% for HIV positive and HIV negative patients (17)

In a South African study, the yield of positive culture on the first sputum sample was 74% on smear negative patients and 86% on smear positive patients. Examination of multiple sputum



Your complimentary use period has ended.
Thank you for using PDF Complete.

[Click Here to upgrade to Unlimited Pages and Expanded Features](#)

field in HIV-associated tuberculosis suggesting a potential delay in diagnosis. (10).

In our environment because of the high rate of PTB infection our clinicians are suspicious of PTB infection in any patient presenting with haemoptysis and often treatment is instituted before positive culture has been established. Correlation with clinical and radiographic findings is performed acutely and management decisions were made before sputum is sent for microscopy and culture. The laboratory diagnosed PTB infection was confirmed retrospectively.

1.7 Pulmonary Tuberculosis in HIV Positive Patients

There are recognizable differences in presentation, extent and severity of PTB when HIV infection co-exists. HIV and PTB share the same exacerbating factors and TB has been shown to speed the progression of HIV infection to AIDS in dually affected individuals and significantly reduce survival rate (19) even when other risk factors are taken into consideration. In particular localized parenchymal PTB disease was less commonly seen in HIV positive patients and there is a higher prevalence of disseminated disease (14), military disease, lymphadenopathy, extra-pulmonary disease and features of primary tuberculosis when the patient become more immunocompromised (10, 20, 21).

A local study of HIV seroconverter cohort of gold miners found that TB risk rapidly increased threefold within the first 2 years of HIV infection (22)

1.8.1 Chest Radiograph and HRCT Chest

1.8.1.1 Role of imaging and modalities

The diagnostic workup aims to locate and establish the cause of the bleeding in order to plan purposeful embolisation of the affected bronchial arteries. Bronchoscopy is a useful diagnostic and therapeutic modality but one needs to be aware of the timing and limitations of the procedure.

Chest radiographs (CXR) are routinely performed on patients with a presentation of haemoptysis. While it is widely available there is a wide range of radiographic appearances of the different stages of pulmonary tuberculosis on CXR including a large proportion of normal radiographs. In a retrospective study of 208 patients with haemoptysis, the CXR was found to be diagnostic in only 50% of cases (23). The CXR may fail to localise a lesion because the chest radiograph is either normal or shows bilateral disease (4). In the presence of concurrent HIV infection, higher rates of false negative CXR are noted (10, 14).

Computed Tomography of the Chest (CT Chest) is more helpful than CXR in excluding other causes of haemoptysis. CT chest, if used alone, is the most sensitive diagnostic test with a positive yield of 67% (23) and can suggest a specific diagnosis. It is often used to detect lesions overlooked on standard radiographs, to define equivocal lesions or to analyse complications (24).

High Resolution Computed Tomography (HRCT) of the chest, by virtue of its thin slice width, is helpful in differentiating active from inactive disease. It is also more sensitive to the detection of miliary spread of infection, detection of small cavities, differentiation of paracatricial

...cavities (24) and assesment of lymphadenopathy. CT Chest or HRCT Chest is sensitive to the detection of aspergillomas (aspergillous infection found in mycetomas) which has been established to be a risk factor for recurrence of haemoptysis following bronchial artery embolisation (25-27).

Contrast Enhanced CT Scan can be used to detect alternate vascular etiology and may help visualize the bronchial and non bronchial systemic feeder vessels.

1.8.1.2 Features of Pulmonary Tuberculosis on imaging

Primary PTB in an adult in South Africa is considered rare due to the high disease prevalence at a young age and routine immunisation with Bacille Calmette-Guerin vaccine at birth. Typical appearances of primary PTB are airspace consolidation predominately in the lower lobes, lymphadenopathy, pleural effusion and miliary disease (28).

Post primary pulmonary tuberculosis occurs with reactivation of dormant bacilli, often during periods of immunosuppression, malnutrition and debilitation or as the result of aging (24). Post primary TB is chronic and slowly progressive compared with primary PTB where fibrosis and healing is more the norm (28). While features of previous primary disease may be present, the commoner appearance of active disease is the presence of a secondary focus or tuberculoma in the apical and posterior segments of the upper lobes or the superior segment of the lower lobe. This may be infiltrative or consolidative with or without cavitation or nodules. Cavitation is the hallmark of post primary TB (24). Endobronchial spread may occur in the absence of cavitation and presents radiographically as 'tree in bud' appearance. Acinar (peribronchiolar) nodules suggests bronchogenic dissemination and even in the appropriate clinical setting has a wide

are micronodules spread evenly in the lung parenchymal without any zonal or lobular predominance but this appearance is more commonly seen in immunocompetent patient who have primary PTB (20).

Kim et al have categorized features of previous and inactive disease as parenchymal, airway, vascular, mediastinal, pleural and extrapleural changes. Parenchymal features of fibroarchitectural distortion manifests as fibrotic bands, calcified nodules, atelectasis, cicatrization and end stage lung destruction. Destruction of lung can follow progressive primary infection, prolonged cavitation, reinfection, spread and fibrosis (24) and complete destruction of lung is not uncommon as a result of parenchymal and airway involvement (28). Once there is destruction of lung parenchyma, assessment of new disease activity is challenging.

Airway manifestations include bronchiectasis, broncholithiasis and tracheobronchial stenosis(28). Bronchiectasis may be the consequence of TB involvement of the bronchial wall and subsequent fibrosis namely cicatricial bronchial stenosis, or more commonly, destruction and fibrosis of lung parenchyma with secondary bronchial dilatation namely traction bronchiectasis (28). When bronchiectasis is seen in the apical and or posterior upper lobe this is suggestive of TB being the primary aetiology (28). Tracheobronchial stenosis is the result of granulomatous changes in the wall or from extrinsic pressure from enlarged peribronchial lymph nodes(28).

Vascular manifestations include pulmonary or bronchial artery arteritis or thrombosis in an area of active infection, bronchial artery dilatation and, less commonly, Rasmussen aneurysm formation(28). Bronchial artery dilatation may accompany parenchymal PTB or be associated with PTB bronchiectasis. Other manifestation on imaging include calcified lymphadenopathy, fibrosing mediastinitis, empyema, fibrothorax, bronchopleural fistula and pneumothorax (28).



Your complimentary use period has ended.
Thank you for using PDF Complete.

[Click Here to upgrade to Unlimited Pages and Expanded Features](#)

manifestation and diagnosis of PTB on imaging becomes more complicated. As the disease course depends on the host immune response to the organism virulence, the manifestations are often less severe. The sensitivity of CXR to screen for PTB decreases with normal radiographs having been reported in up to 40% of sputum positive cultures (10) as opposed to 15% in HIV seronegative patients. In seropositive patients there is a lower prevalence of parenchymal consolidation, cavitation and post primary pattern, and a higher prevalence of extrapulmonary and miliary disease as compared with seronegative patients (14, 24). The sensitivity of CT scan to detect PTB remained independent of HIV status (14).

1.8.2 Bronchial Artery Embolisation

1.8.2.1 Role of the procedure

BAE was first performed in 1973 by Remy et al (11). Today, it usually utilizes Digital Subtraction Angiography Technique for its superior spatial resolution, rapid acquisition and review capabilities (9). A transfemoral approach is used to select and embolise the bronchial arteries.

Bleeding originates from the bronchial arteries in the majority of patients (15). Even mild bleeding originating from the bronchial arteries can cause life-threatening hemoptysis due to the higher blood pressure (15) in these vessels. Since then, sub-selection and super selection has allowed embolisation of the artery as close to the site of haemorrhage as possible by bypassing areas that would previously have precluded safe embolisation(9).

ing refers to embolisation of the bronchial arteries only. However, it has been shown that early (within 2 weeks) failure rate of the procedure could be accounted for by an incomplete procedure where the other systemic arteries (such as the internal mammary artery or the phrenic artery) that maybe involved in haemorrhage are not embolised (29). Nevertheless, BAE has been shown to achieve high rates of immediate control of haemoptysis and is generally accepted as a first line treatment for acute massive haemoptysis. The literature quotes immediate response rates from 73 to 98% (2, 9, 11, 12, 30, 31). With the advent of coaxial microcatheter expertise and availability, the ability to achieve immediate control of haemoptysis approaches 90% (25) to 95.7% (29) with reduction of observed complications (2).

Some centers promote emergency surgery as initial management especially if the bleeding point is localized and pulmonary function test permits pulmonary resection, because it permits definitive treatment of haemoptysis by removing the source of bleeding (26, 30, 31). When active PTB is the cause, surgery can be deferred in the emergency setting with BAE used to control haemoptysis until such time as effective medical treatment can be initiated and sustained. Traditionally surgery during active infection, before the initiation and maintenance on medical treatment, has been associated with a poor surgical and clinical outcome as a result of higher complication rates (7).

1.8.2.2 Technique and Complications

The literature documents many complications of the procedure. These include, amongst others, contrast reaction, subsequent renal function impairment, introduction of infection, procedural

thrombosis, subintimal dissection of femoral, aorta or bronchial arteries, fistulation, haemorrhage or puncture site haematoma formation and femoral nerve damage(9).

Complications of embolisation itself include transverse-myelitis (9, 31) (less common now as a result of lower osmolar contrast media), bronchial or aortic necrosis, inappropriate embolisation of non target tissue such as the colon, pulmonary infarction, ipsilateral face and orbital pain and transient cortical blindness, extremities, complication of catheterization or disturbance of ostia of other vessels, embolism, dissection and clinically evident complications such as transient chest pain, transient dysphagia, and broncho-oesophageal fistula.

For the radiologist the risks of the procedure includes exposure to blood, blood products and blood borne infection such as HIV and hepatitis, needle stick injury risk and radiation exposure.

Technical failure of the procedure may be broadly accounted for by failed bronchial arterial access or the presence of contraindications to embolisation.

Failed bronchial access may be due to differing level of skill and experience of the operator, inability to cannulate artery (dependant on size of vessel, take off from parent vessel), variant anatomy; or distorted anatomy from previous intervention or end stage lung disease from previous disease. In 70% of people the origin of the bronchial arteries is found to arise between the top of the fifth thoracic vertebrae and the bottom of the sixth thoracic vertebrae (9). Variations of this include the vessels arising from the aortic arch or from visceral vessels such as the internal mammary artery, thyrocervical trunk or inferior phrenic artery (32). Most commonly, there are 2 left bronchial arteries and 1 right bronchial artery, followed by bilateral single bronchial arteries, all of which emerge anterolaterally from the aorta. The right



PDF Complete
Your complimentary use period has ended.
Thank you for using PDF Complete.

[Click Here to upgrade to Unlimited Pages and Expanded Features](#)

common vessel identified and is seen in 80% of patients

(9).

Contraindications to safe embolisation include failure to securely cannulate the pathological vessel (31) resulting in dislodgement and inadvertent embolisation of non target tissue. This may be prevented by screening the tip of the catheter at all times during embolisation.

The presence of reflux during embolisation can be appreciated on a magnified view of the catheter tip during continuous screening. It appears as a blush of contrast in the aorta and is usually the result of poor engagement of the vessel. Detection of reflux is optimized by mixing embolic material with concentrated contrast. Reflux contraindicates embolisation with embospheres as it results in distal non-target embolisation. Better engagement with microcatheters or change in catheter is advised. Watching for reflux during the entire embolisation procedure is mandatory as it may only become evident when the pathological vessel, having been partially embolised, experiences slower flow due to an increase in distal resistance.

Inappropriate non-target embolisation may also result from not flushing the catheter with saline prior to disengagement, before or after selection of another vessel.

An important complication to be aware of is embolisation of a spinal arterial feeder resulting in spinal cord ischemia or infarction. Spinal arteries may be evident at the start of embolisation or become more easily detected following partial embolisation when the steal phenomenon of the pathological bronchial arteries is being staunched. When a spinal arterial feeder is identified one should attempt to subselect or superselect beyond its origin using a coaxial system and avoid forceful embolisation to prevent reflux into the spinal feeder (9).

in view of the complications associated with spinal artery embolisation, one should look for these carefully. There are many small branches seen to arise from the right intercostobronchial trunk and course towards the midline but their supply to the spinal cord should be confirmed on a lateral view (9). Another common site of origin of spinal vessels is from the right fifth intercostal artery and therefore care must be taken when an exhaustive embolisation of other systemic vessels is undertaken. Embolisation into the fifth right intercostal artery with ionic contrast media has been reported to be a risk for transverse myelitis (33, 34).

The most concerning spinal artery is that of the anterior spinal artery of Adamkiewitz. This arises between the ninth and twelfth thoracic vertebrae in 75% of cases (13) and has a characteristic hairpin bend seen on the subtracted anteroposterior (AP) view. This should be confirmed on a steep oblique or lateral view and viewed on the native image.

A fistula is a direct communication between two endothelial surfaces. Embolisation through bronchopulmonary anastomosis can result in pulmonary infarction (via pulmonary arterial embolisation) or systemic organ infarction (via pulmonary vein embolisation) (9). The consequence of embolisation in the presence of a pulmonaryóbronchial artery fistula depends on the size of embolic material and how proximal the fistula is in relation to the pulmonary artery, the most significant of which is embolisation of the entire lung. We use a delay in appearance of the pulmonary vein to decide if there is an adequate pulmonary bed present. Arterial-arterial fistula is found between the bronchial artery and visceral arteries such as the subclavian artery, cervical trunk vessels or the vertebral artery. To prevent non-target embolisation one must sub-select beyond the fistulous region prior to embolisation.

for 5 to 7 days, is characterized by pleuritic pain, fever, dyspnea and leukocytosis and responds to symptomatic treatment (35).

Signs on arteriography that suggests site of bleeding include enlargement of vessel, vascular blush, increase in hypervascularity and evidence of vascular shunts between the systemic arteries and pulmonary artery and vein. This may be pronounced enough to demonstrate reversal of flow in the pulmonary arteries (9). The pan-aortogram allows for visualisation of non-bronchial collateral vessels that may also need to be embolised. Abnormal vascularity shown angiographically has no correlation with the degree of hemoptysis (9) and too forceful injection of contrast can produce a similar hypervascular angiographic appearance (9). Nevertheless, non visualisation of hypertrophied bronchial arteries on pan-aortogram should not stop one from attempting to cannulate the bronchial arteries, as bleeding may occur from vessels that are normal in size(9).

There are a variety of methods available to embolise the vessels and the most commonly used agent is polyvinyl alcohol (PVA). These are available in various sizes but sizes of 350-500 micrometers in diameter are recommended (13) because these are large enough to embolise the target vessel distally but are not small enough to allow for occlusion of the pulmonary capillary bed, oesophageal vessels, vasavasorum of the pulmonary artery or aorta (9), or pass through bronchopulmonary anastomosis (13).

Other agents include absorbable gelatin sponge or the use of coils. Neither of these is recommended as sole therapy because of the likelihood of recanalization in the former and diminished accessibility in the latter, should a repeat embolisation be necessary (9).

tion of pathological systemic vessels such as transpleural vessels, intercostal vessels, axillary artery branches, internal mammary arteries, branches of thyrocervical and costocervical trunks and the left gastric artery, and the inferior phrenic artery branches (9).

Regardless of the etiology BAE is at best a palliative procedure (11, 12), to staunch the haemoptysis until definitive intervention is performed to prevent relapse. For active PTB the long term management is effective medical therapy to reduce the local inflammatory environment and thus prevent recurrence. For associated etiology, such as the presence of aspergilloma, surgical management to remove the site of pathological lung is needed to prevent recurrence as this is resistant to other therapies and is a cause of relapse in haemoptysis (25, 26).

In case of chronic PTB medical therapy is the definitive management with BAE serving as a palliative procedure. In patients with sequelae of old and treated PTB who present with haemoptysis, BAE is effective in controlling haemoptysis. Recurrence is an indicator for considering surgical management as even extensive re-embolisation has been shown to be non-effective (2).

Recurrence of haemoptysis may be the result of incomplete embolisation (36), recanalization of previously embolised vessels, collateral vessel revascularization of the region associated with progression of the disease (9, 12) especially in the setting of default of medical therapy (11). Early recurrence is usually due to incomplete embolisation while recurrence after 1 year is most likely due to disease progression (9) or revascularization in regions of pulmonary inflammation (37).

presence of aspergilloma as the major cause of recurrence of haemoptysis following BAE (25, 26), a local study reports 4 reasons for an increased likelihood of recurrence of haemoptysis following BAE namely, ongoing haemoptysis beyond 7 days after BAE, blood transfusion required during BAE, presence of aspergilloma and patients receiving treatment for active PTB at time of the procedure(27).

1.9 Management Options and Protocols at IALCH

Following admission and haemodynamic stabilization an HRCT Chest or diagnostic CXR was performed to identify source of bleeding and to localize sites of bleeding.

If the patient is deemed a non surgical candidate by the cardiothoracic team, an emergency non exhaustive BAE was performed. At IALCH the indications to opt for bronchial artery embolisation rather than surgery included patients that were HIV positive with CD4 < 400 (unless the presentation was life threatening), non-localised or bilateral disease, non-operative clinical patient profile, or recent bout of massive haemoptysis in a patient stable enough for bronchial artery embolisation.

This procedure may or may not be accompanied by embolisation of non-bronchial systemic vascular feeders. At this time, no limit was placed on the number of bronchial artery embolisations a patient may undergo.

2.1 Study Design

A retrospective analysis of clinical and radiological data was used to establish whether co-infection of HIV and PTB (acute and sequelae) has an impact on the success rate of BAE procedure.

The analytical component of the study aims to determine if co-infection adversely affected the outcome of the procedure (clinical and procedural). It also aims to determine if CD4 level affects the outcome of the procedure.

The descriptive component of the study aims to determine the cause for unsuccessful BAE studies in these patients.

2.2 Study Participants

IALCH is an 846 bed hospital of specialties in central Durban and serves as the draining hospital for all of Kwa Zulu Natal (KZN). The radiology service caters for all admitted patients.

One hundred and ninety eight bronchial artery embolisation procedures were performed from January 2006 to 31 December 2007. This study was performed on consecutive patients who underwent Bronchial Artery Embolisation (BAE) and who met the selection criteria. The cohort group is HIV positive patients and the control group is HIV negative patients.

...d using a 95% confidence interval. The significance level of the test was targeted at 0.05000. The sample size required was 26 in one group and 42 in the other to achieve 81% power to detect a difference between the group proportions of -0.3000. The proportion in group one (HIV positive) is assumed to be 0.9000 under the null hypothesis and 0.6000 under the alternative hypothesis, the proportion in group two (the control group ó HIV negative) is 0.9000. The significance level actually achieved by this design is 0.0266. The sample size of 107 patients (33 HIV negative, 74 HIV positive) is adequate.

The selection criteria included:

1. History of previous pulmonary tuberculosis, or microbiological or radiological diagnosis of active or sequelae pulmonary tuberculosis on HRCT or CXR.
2. Clinician assessed need for BAE namely not a surgical candidate.
3. Life threatening or massive haemoptysis accounted for by the diagnosis or complications of PTB.
4. First and second attempts at embolisation only.

Exclusion criteria included:

1. Other cause of haemoptysis as identified clinically, radiologically or microbiologically. These included lung abscess, bronchiectasis without previous history of tuberculosis, carcinoma, cystic fibrosis, pneumonia, pulmonary interstitial fibrosis, pneumoconiosis, congenital cardiac and vascular abnormalities, aortobronchial fistula, aortic aneurysm, bronchial artery aneurysm or pulmonary artery aneurysm.



Your complimentary use period has ended.
Thank you for using PDF Complete.

[Click Here to upgrade to Unlimited Pages and Expanded Features](#)

3. Third or subsequent DAE for the same diagnosis.
4. HIV status unknown.

The diagnosis of PTB was made as follows: Cases were included if they had a history of PTB (treated or otherwise). If not, charts were searched for microbiological evidence of PTB in current sputum samples. If this was negative, the chart was searched for radiographic features of active or previous tuberculous infection. If this was not found, clinical data and clinical diagnosis of PTB was relied upon.

Retrospective data capture to assess demographic, clinical (diagnosis and follow up) and laboratory parameters was performed and captured on an Excel document.

Images captured were those that were documented on the Picture Archive and Communication System (PACS). The images were analyzed by an independent radiologist who was provided with the images, the report from the performing radiologist, a checklist (annexure 2), and was blind to the HIV results or the clinical outcome of the procedure.

Scans were acquired on a Siemens Somatom Sensation 16 slice Computed Tomogram Scanner.

Patients were positioned supine with arms above the head and the scan field extends from the sternal notch to the diaphragm. Scans of 1mm slice thickness with 10mm gap were acquired and reconstructed prospectively on a high (sharp) spatial frequency kernel for lung windows and on a medium smooth kernel for mediastinal windows.

2.4 Bronchial artery embolisation: Procedure

The procedure was performed on the Siemens Artis FA angiogram system and utilizes Digital Subtraction Angiography technique. As with any interventional procedure there are risks and complications, that one needs to be aware of, before embarking on the procedure. Normal precautions for preventing exposure to blood borne risks were followed. (Annexure 3)

The procedure was performed by a registrar in Radiology under the guidance of a qualified Radiologist as part of their clinical training. Registrars rotating through the IALCH were involved in the procedures. All registrars involved had successfully completed their Part 1 examination in Diagnostic Radiology through the College of Medicine of South Africa (CMSA).

The procedure is conducted as a sterile procedure and is initiated with routine pre-procedure assessments of pulse, blood pressure, oxymetry and a clinical neurological assessment.

Access to the vasculature is via groin puncture of the right or left femoral artery using the modified Seldinger technique with placement of 11cm 5 French (F) Femoral sheath into the femoral artery.

angiogram using a 110cm 5F pigtail catheter was then performed to detect the ostia of bronchial arteries and exclude anomalous origins of bronchial arteries or systemic vascular pathology (9). 30-40ml of non-ionic iodine based contrast via an injector at a rate of 12-15ml/second was injected and 2 views (posteroanterior and right anterior oblique) were obtained.

Bronchial artery selection was undertaken even if the visualized bronchial arteries appeared angiographically normal on the aortogram(9). These were selected using an appropriate catheter and guidewires. Catheters available included the Headhunter, Cobra, Mickaelson, Maney, Sim 2 and Sidewinder in 4F and 5F. For embolisation, only end hole catheters were used as this is mandatory to prevent non-target embolisation (9). The guidewire available was the 5F standard J tip Emerald Guidewire.

Hand injection of 2-5mls of undiluted non-ionic low osmolar iodine contrast (300mg Iodine/ 100 milliliters) was used to obtain the bronchial artery arteriogram. The bronchial arteries were assessed for pathology. Sub-selection (if needed) was attempted using the same or smaller size catheters. Co axial microcatheters were not available as none of the radiologists or registrars were trained in its use.

Embolisation was performed with 2ml boluses of large embospheres (900-1200 micrometers) to which 8ml of contrast was added to improve visualization and to alert one to reflux of embolic material. Frequent angiographic runs were performed with 2 minute wait periods in-between injection of embolic material. This was done to assess for progress of vessel occlusion, subjective degree of increase in vessel resistance, and presence of steal phenomenon when

...e evident as the distal vessel occludes. The endpoint of embolisation was when there was stasis of contrast within the bronchial artery (9).

Post embolisation clinical neurological assessment on table was done prior to transfer to ward.

2.5 Laboratory Investigations

At the discretion of the supervising clinician, microbiological samples were sent to the laboratory for microscopy and culture and blood samples were sent for HIV testing.

2.5.1 Microbiology

In those patients with no history of previous pulmonary tuberculosis, a positive microbiological test for the disease was interpreted as sufficient proof of infection. As multiple factors were used to diagnose PTB infection for the study, the positive AFB or culture tests were included in the study but the negative tests were not excluded unless no other (clinical, radiological) evidence of active or old PTB was present. Annexure 4 describes the local laboratory handling of a sputum sample for microscopy and culture.

The sputum sample is initially decontaminated with alkali, neutralized with acid and centrifuged. The sediment is stained with Auramine and cultured routinely. Mycobacterial growth indicator tube (MGIT) bottle is plated onto solid Middlebrook agar media for first & second line susceptibility testing (INH, Rifampicin, Streptomycin, Ofloxacin and Kanamycin).

Positive MGIT bottles have a Ziehl-Neelson stain performed. If these are ZN positive and cording is present then the sample most likely represents MTB. If acid fast bacilli are present but no cording is noted on positive MGIT bottle, an MPT 64 Antigen test (immunochromatographic



PDF Complete
Your complimentary use period has ended.
Thank you for using PDF Complete.

[Click Here to upgrade to Unlimited Pages and Expanded Features](#)

is sent out as Mycobacterium other than Tuberculosis

(MOTT).

Smear positive samples, positive cultures and positive immunochromatographic rapid tests are sent to a molecular facility for line probe assay which determine whether the isolate is TB and determine susceptibility results for INH and Rifampicin. If the line probe assay shows that it is resistant to INH and/or Rifampicin further drug susceptibility test is done.

2.5.2 Virology

The HIV screening assay used by the lab is the 4th generation Elisa. It detects both HIV antigen and antibody and is run on the Roche Modular platform. The confirmatory assay is a 3rd generation Elisa and detects HIV antibodies and is run on the Advia Centaur platform.

An HIV diagnosis is only made if both tests are positive. In the case of discrepant results an HIV PCR or Western Blot is performed on a separate sample.

At the time of the procedure, the operator may or may not have been aware of the HIV status and CD4 count for that patient.

Protocol (student number: 933481893) and Ethical (reference number: BE059/010) approval was obtained from the University of Kwa Zulu Natal's Postgraduate and Research Office. (Appendix 5 and 6 respectively)

Permission to conduct the study at IALCH was obtained from Chief Executive Officer of IALCH. (Appendix 7)

The study is a retrospective analysis of data and images of the procedure and consent was not considered to be required.

HIV and CD4 testing was conducted at the discretion of the Cardiothoracic clinician. HRCT chest and testing of sputum for PTB was part of routine clinical workup of the patient. No additional test was performed solely for this study.

Confidentiality was respected throughout the data collection and will remain such. Each case was assigned a numerical code and this code was used in the different aspects of data collection and image analysis prior to collation by the primary investigator alone.

2.7 Data Capture and Analysis

A pilot study was not performed. Review of the electronic clinical records was performed and the relevant data captured by the primary investigator (Data capture form ó annexure 8). Review the HRCT and BAE was performed by an independent radiologist ó Dr G Bydowell who has been trained as an interventional radiologist and is now employed in private practice in Durban.

spreadsheet and differences between the groups were analyzed using the Chi squared test, Fisher's exact test or the Mann-Whitney test, as appropriate, using the SPSS programme. A probability- value (p) of less than or equal to 0.05 was considered significant.

2.8 Outcome measures

2.8.1 HRCT

Active PTB was suggested by the following radiological features on CXR and HRCT chest in the appropriate clinical setting:

1. Presence of a secondary focus or tuberculoma or nodules. The secondary focus may be infiltrative or consolidative and may cavitate. Nodules may be miliary, centrilobular and acinar. A nodule is a rounded or irregular opacity, well or poorly defined, measuring up to 3cm in diameter. Miliary pattern consists of profuse tiny, discrete, rounded pulmonary opacities that are uniform in size (3mm in diameter) and diffusely distributed throughout the lungs. Centrilobular nodules may be of soft-tissue or ground-glass attenuation, are ill defined and range in size from a few millimeters to a centimeter. Tree-in bud opacities or centrilobular nodules with or without cavitation suggesting bronchogenic dissemination.
2. Pleural effusion
3. Lymphadenopathy

Following radiological features on CXR and HRCT chest:

1. Fibroarchitectural distortion (fibrotic bands, calcified nodules, atelectasis, emphysema, bronchiectasis and volume loss). This may be accompanied by destruction of lung in the setting of history of previous PTB.
2. Presence of cavitation and mycetoma in the setting of history of previous PTB. A cavity is an air-filled space, seen as a lucency or low attenuation area within an area of consolidation, a mass or a nodule.

2.8.2 BAE

Clinical outcome was considered successful if there was immediate cessation of haemoptysis or cessation of haemoptysis by discharge following embolisation in the absence of any other intervention.

The radiological procedure was considered successful if there was successful identification of pathological vessels and embolisation was performed with success. The radiological procedure was considered unsuccessful if embolisation was not undertaken.

The radiological procedure was described as partial embolisation with clinical success if only some of the abnormal vessels were embolised and the clinical outcome was successful namely, cessation of massive haemoptysis. The radiological procedure was described as partial embolisation with clinical failure if only some of the abnormal vessels were embolised and the clinical outcome was unsuccessful namely, further definitive management was needed to staunch the haemoptysis. This included sedation and medical therapy, repeat bronchial artery

admission at a later date or if a serious complication such as non-target organ embolisation or death occurred.

Angiographic findings to suggest pathological bronchial arteries are hypertrophic and tortuous bronchial arteries, neovascularity, hypervascularity, and bronchial artery shunting into pulmonary arteries or veins, extravasation of contrast media when injected into bronchial artery, bronchial artery aneurysm and non-bronchial systemic vascular abnormalities.

Technical reasons for failure of BAE included:

1. Inability to select the primary artery such as the bronchial artery
2. Inability to sub-select specific divisions of the artery for safe embolisation
3. Instability of catheter tip
4. Reflux of the contrast media into the parent vessel
5. Visualization of a contraindication such as a bronchio-pulmonary vein fistula, bronchio-pulmonary artery fistula, bronchio-visceral artery fistula or spinal artery
6. No pathological vessel identified

2.9 Clinical record

The diagnosis and results of microbiological or virological test were retrospectively acquired from the patients chart. The clinical outcome of the procedure and clinical follow up were similarly noted from the patient's chart.

One hundred and ninety eight BAE studies were performed at IALCH in the period 1 January 2006 to 31 December 2007.

One hundred and seven (54%) cases were included in the study. The remaining 91 cases were excluded from the study for reasons displayed in Table 1. Some cases had more than one reason for exclusion. The commonest reason for exclusion was the lack of HIV results ó 53/91 (58.2%), followed by the presentation of minor rather than major haemoptysis ó 42/91 (46.2%).

Table 1: Excluded cases

Reason for exclusion (n=91)	Number of cases
Study not found	10
Minor haemoptysis	42
HIV unknown	53
Diagnosis other than PTB	2
More than 2 previous BAE	8

3.1.1 Age and HIV status

The age and HIV status of the included cases is displayed in figure 2. The age of included cases ranged in age from 15 to 67, with an average age of 36.6 years. The majority 37/107 (34.6%) of the patients were between 30 and 39 years old.

For HIV positive patients the distribution of ages is nonparametric with a standard deviation of 9.19 years. The median age of patients who are HIV positive is 32 years. The highest age in this category is 55, the lowest age is 20.

For HIV negative patients the distribution of the ages is normal with a standard deviation of 14.383 years. The average age of patients who are HIV negative is 40.85 years. The highest age in this category is 67, the lowest is 15.

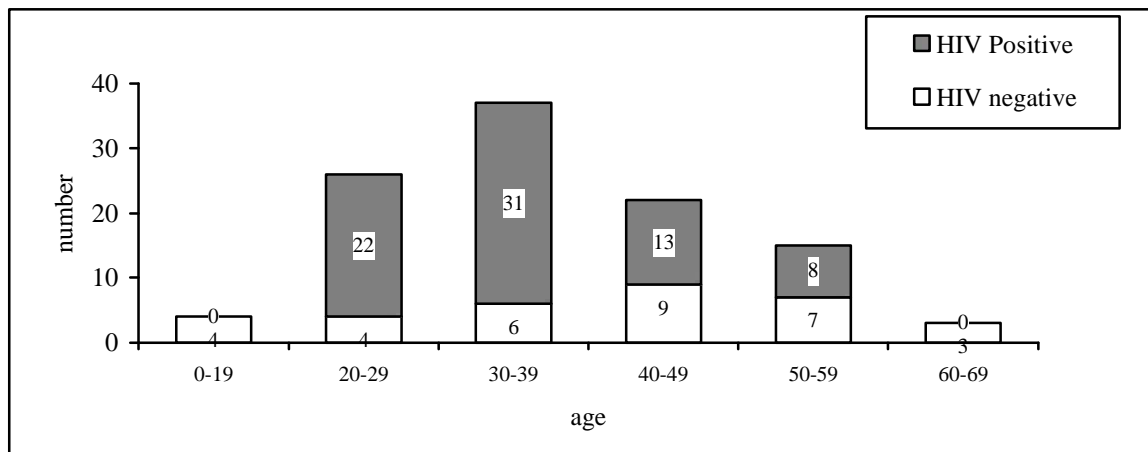


Figure 2: Histogram of age and HIV status

The gender distribution and HIV status is displayed in figure 3. There is no statistical significance in correlation of gender distribution with HIV status (actual $p = 1.000$).

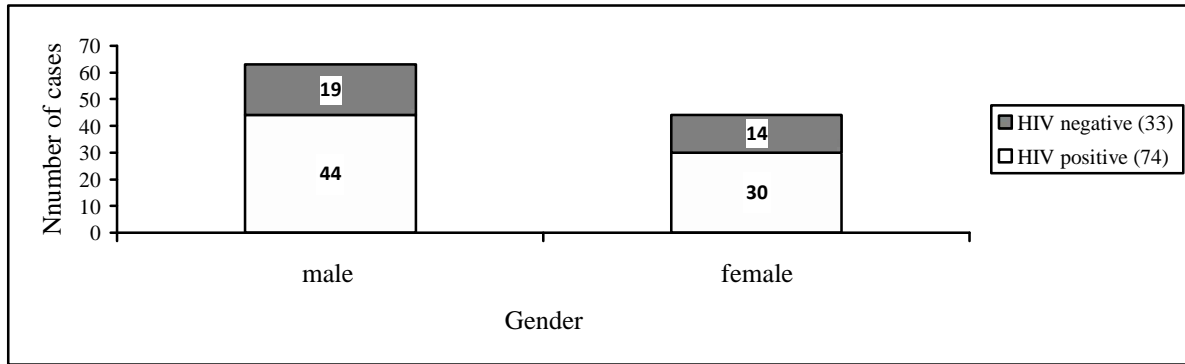


Figure 3: Histogram of gender and HIV status

3.1.3. HIV Status and CD4 Levels

Of the 107 included cases, 33 (30.8%) are HIV negative and 74 (59.8%) are HIV positive. The number in each category was adequate for the study.

CD4 levels were known in 57/74 (77%) cases. The distribution of the available data is non-parametric. The median level is 176. The highest level recorded is 768 and the lowest level recorded is 1. Using a CD4 count of 200 as a cutoff point, the majority 35/74 (47.3%) of cases had a CD4 level consistent with WHO stage 4 clinical disease.

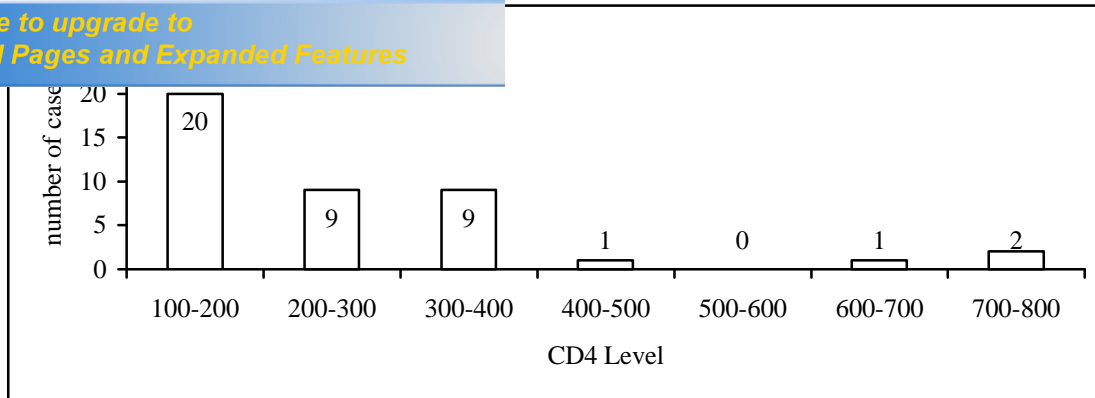


Figure 4: Histogram of available CD4 counts (n=57)

3.1.4 Previous bronchial artery embolisations

Cases with a history of 3 or more previous BAE were excluded from the study. 14 cases had a history of 2 or less previous BAE, 7 are HIV positive and 7 are HIV negative. There is no correlation between the incidence of a history of previous bronchial artery embolisations (≤ 2) and HIV status (actual $p = 0.123$).

tuberculosis

The cases were included if they had history, microbiological, radiological or clinical evidence of PTB. Seventy one (66.4%) cases had a history of previous pulmonary tuberculosis. Of the remaining 36, 17 were diagnosed microbiologically, 18 had radiological evidence of active or old pulmonary tuberculosis and one was diagnosed clinically.

Some cases met more than one criterion for diagnosis. The majority (94/106) of cases showed radiographic evidence of active (101/106 cases) or old PTB (102/106 cases). There was no significance to the correlation of HIV status and the presence of active or old PTB. (p values of 0.664 and 1.000 respectively)

Sixty one (57%) cases were referred with a diagnosis of PTB and were already on treatment. Twenty eight (26.2%) cases are sputum examination positive for AFB or culture positive for MTB. Nine (8.4%) cases are multidrug resistant positive PTB (MDR) with the majority being HIV positive cases (7/9 or 77.8%). Nineteen (17.8%) cases were diagnosed on clinical grounds.

The distribution of method of diagnosis of PTB across HIV status is displayed in table 2. There is no statistical significance when correlating the method of diagnosis of PTB and the HIV status.

correlated with HIV status

	HIV negative	HIV Positive
History of previous PTB (n=71; p=0.120)	18	53
AFB positive (n=28; p=1.000)	9	19
MDR (n=9; p=0.718)	2	7
XR evidence of old or new PTB (n=101; p=0.664)	32	69
Clinical (n=19; p=1.000)	6	13
Referral diagnosis (n=61; p=0.292)	16	45

3.3 Imaging Findings

There were 93 HRCT chest studies and 13 CXR available for review and all are abnormal. The correlation of imaging technique availability and HIV status is not significant ($p = 1.000$) and thus all imaging, findings regardless of whether they were identified on HRCT or CXR, were analyzed together. (Table 3)

Table 3: Imaging investigation availability correlated with HIV status

	HRCT	CXR
HIV positive (n=73)	64	9
HIV negative (n=33)	29	4

There is no correlation between the zones involved and the HIV status of the cases. In 57 cases, all four zones were involved and this is not statistically relevant when correlated with HIV status. The findings in terms of zonal distribution and HIV status is displayed in table 4.

ical changes on imaging

	HIV Positive (n=73)	HIV Negative (n=33)
Right upper zone (n=93; p=0.784)	66	30
Right lower zone (n=81; p=0.645)	57	24
Left upper zone (n=94; p=0.496)	64	30
Left lower zone (n=86; p=0.566)	59	27
All zones involved (n=57; p=1.000)	39	18

The most common feature reported on the imaging in both HIV positive and HIV negative cases is architectural distortion with no significance when compared with HIV status ($p = 1.000$) namely 95.6% and 97% respectively.

Lymphadenopathy is present in 18.9% of HIV positive cases and 42.2% of HIV negative cases and is the only features of significance when comparing with HIV status ($p = 0.017$). The other features and their incidence are listed in table 5.

There is no significant difference in findings when correlating HIV status and active disease (namely presence of acute infection, pleural effusion and lymphadenopathy) ($p = 0.664$) or when correlating HIV status and features of disease sequelae (namely presence of architectural distortion and mycetoma) ($p = 1.000$)

g correlated with HIV status

				Sequelae of disease	
	Acute infection (n=101)	Pleural effusion (n=17)	Lymph Adenopathy (n=28)	Architectural Distortion (n=102)	Mycetoma (n=46)
HIV positive (n=73)	69	13	14	70	33
HIV negative (n=33)	32	4	14	32	13
p value	0.664	0.576	0.017	1.000	0.676
p value	0.664			1.000	

3.4 Outcome

Clinical success of the procedure is defined as the cessation of the haemoptysis following the procedure during this admission.

The procedure was considered successful as the sum of 2 categories namely, embolised and partial embolisation with clinical success. The procedure was considered unsuccessful as the sum of 2 categories namely, not embolised or partial embolisation with clinical failure. The distribution of different values across *partially embolised with clinical success* and *partially embolised with clinical failure* are equally likely (actual p value = 0.146). The distribution of different values of *embolised* and *not embolised* are equally likely (actual p value = 0.213).

There is no statistical significance when correlating each category of procedural outcome with HIV status. (Table 9)

ly embolised with clinical success can be collapsed into one category and that *not embolised* and *partially embolised with clinical failure* can be collapsed into another category without affecting the results of the study.

3.4.1 Clinical versus procedural outcome

There is a significant difference in success rates for procedure versus clinical success for the entire caseload (actual $p = 0.008$). (Table 6) This means that the terms clinical and procedural success cannot be viewed interchangeably.

Table 6: Comparing clinical and procedural outcome

	Clinical success	
	No (n=56)	Yes (n=51)
Procedural success (n=63)	15	48
Procedural failure (n=44)	41	3

Fifteen cases were considered procedurally successful but did not have the desired clinical outcome. Of these, 3 are HIV negative and 12 are HIV positive. There is no significance when comparing this data with HIV status ($p=0.183$). (Table 7)

Table 7: Comparing procedural and clinical success based on HIV status

		Procedure success (n=63)	Procedure failure (n=44)
HIV negative (n=33)	Clinical success	14	0
	Clinical failure	3	16
HIV positive (n=74)	Clinical success	34	3
	Clinical failure	12	25

clinical outcome with Gender and HIV status is noted.

Failed clinical outcome $p = 0.594$, successful clinical outcome $p = 0.522$.

No significance in the correlation of procedural outcome with Gender and HIV status is noted.

Failed procedural outcome $p = 1.000$, successful procedural outcome $p = 1.000$.

3.4.2 Clinical outcome

Fifty one (47.7%) cases were clinically successful. Of this, 3 (5.9%) could not be accounted for by procedure success and may be the result of conservative and or medical management. (Table 7) All 3 are HIV positive. Fifty six (52.3%) cases were clinically unsuccessful and required alternative management. (Table 8)

There is no significance to the correlation of clinical success and HIV status ($p=0.469$).

There is no difference in likelihood of any of the clinical follow up noted for either HIV positive or HIV negative studies. (Table 8)

with HIV Status

		HIV positive (n=74)	HIV negative (n=33)
Clinical success (n=51; p=0.469)		37	14
Alternative therapy required	Medical therapy (n=29; p=0.150)	17	12
	Repeat bronchial needed (n=10;p=0.721)	8	2
	Surgery needed (n=16; p=0.564)	10	6
Death during admission (n=4; p=0.309)		4	0
Readmission (n=22; p=0.251)		13	9
Complication (n=4; p=1.000)		3	1

3.4.3 Bronchial Artery Embolisation Outcome

A total of 63 (58.9%) cases were classified as procedurally successful. A total of 44 (41.1%) cases were classified as procedurally unsuccessful. There is no statistical significance when correlating each category of procedural outcome or the 2 categories defined above, with HIV status. (Table 9)

Table 9: Procedure outcome and HIV status

Procedure outcome	HIV negative	HIV positive	Total (p value)
Embolised (n=53; p=1.962)	13	40	63 (1.069)
Partial embolised and clinically successful (n=10; p=0.434)	4	6	
Not embolised (n=40; p=2.512)	16	24	44 (1.069)
Partial embolised and clinically unsuccessful (n=4; p=1.853)	0	4	

Two hundred and twelve vessels were selected and 106 were embolised. (Table 10) Not all selected vessels would need to be embolised and therefore the two categories were not correlated.

Table 10: Incidence of vessel selection and embolisation

	Selected (n=212)	Embolised (n=106)
Right bronchial artery	83	43
Left bronchial artery	51	25
Intercostobronchial artery	36	25
Internal mammary artery	36	11
Intercostal artery	6	2

There is no significance in the correlation of selection of any of the vessels (right bronchial artery, left bronchial artery, intercostobronchial artery, intercostals or internal mammary arteries) and HIV status.

There is no significance in the correlation of embolisation of any of the vessels (right bronchial artery, left bronchial artery, intercostobronchial artery, intercostals or internal mammary arteries) and HIV status.

selection and embolisation of vessels in procedure failure

		Selected		Embolised	
		HIV negative	HIV positive	HIV negative	HIV positive
Bronchial arteries	Right bronchial artery	25	58	11	32
	p value	0.863		0.482	
	Left bronchial artery	15	36	5	20
	p value	0.761		0.182	
	Intercostobronchial artery	9	27	6	19
	p value	0.661		0.737	
Systemic arteries	Internal mammary artery	12	24	2	9
	p value	0.731		1.000	
	Intercostal artery	2	4	0	2
	p value	1.000		1.000	

3.4.3.2 Reasons for technical failure of the procedure and HIV status

Four factors were significant when correlated with overall failure of the procedure regardless of HIV status. These are -unable to select (p=0.007), -unable to subselect (p=0.015), -spinal feeder (p=0.006) and -no bleeder identified (p=0.010).

There is no difference in likelihood of occurrence of any of the factors investigated when correlated with HIV status (refer table 12).

use correlated with HIV status

	HIV negative	HIV positive
Unable to select (n=11; p=0.503)	5	6
Unable to subselect (n=10; p=0.144)	6	4
Unable to engage securely (n=3; p=1.000)	1	2
Reflux observed (n=0)	0	0
Bronchio-pulmonary artery fistula (n=4; p=1.000)	1	3
Bronchio-pulmonary vein fistula (n=8; p=1.000)	3	5
Bronchio-visceral fistula (n=5; p=1.000)	2	3
Spinal feeder identified (n=15; p=0.646)	6	9
No bleeder identified (n=5; p=0.651)	1	4
Other (n=1; p=1.000)	0	1

3.4.4 CD4 Level

Of the 74 HIV positive cases, the CD4 value was available in 57 (77.0%) cases only. The distribution of the data is non parametric therefore the median level is used for comparative purposes. The median CD4 level is 176. The highest recorded CD4 level is 768 and the lowest recorded CD4 level is 1. The following results apply to the available data.

The total number of clinically successful cases is 25/57 (43.86%). The CD4 level in the 2 categories has no significance when correlated with clinical success (p=0.829). (Table 13)

procedural success is 35/57 (56.1%). The CD4 level in the 2 categories has no significance when correlated with procedural success (p=0.266). (Table 13)

Table 13: Correlating CD4 value and clinical and procedural success

			Procedure successful		Total
			No (n=22)	Yes (n=35)	
CD4 ≤176 (n=31)	Clinically successful	no	12	5	17
		yes	2	12	14
CD4 >176 (n=26)	Clinically successful	no	8	7	15
		yes	0	11	11

Thirty one cases have a CD4 level at or below 176. 14 (45.2%) cases are clinically successful. Seventeen (54.8%) are procedurally successful. In 5 (16.1%) cases the procedure is considered successful but the patient did not have a good clinical outcome (p=0.002).

Twenty six cases have a CD4 level above 176. Fifteen (37.9%) cases are clinically successful. 11 (42.3%) are procedurally successful. In 7 (26.9%) cases the procedure is considered successful but the patient did not have a good clinical outcome (p=0.007).

The likelihood of a procedure being successful with poor clinical outcome is significant for both categories of CD4 levels and further studies with larger case numbers is warranted to investigate further.

Four patients died during the admission. All are HIV positive. Statistically this not significant ($p=0.309$). One died during the BAE procedure.

Three cases resulted in severe complications. All patients are HIV positive. Statistically there is no significance in the correlation of complications (minor and major) and HIV status ($p=1.000$).

Case 1: Infarction of the vermis and bilateral cerebellum following embolisation of a common bronchial artery. The patient became restless during the procedure and the procedure was abandoned. Infarction was confirmed on MRI.

Case 2: Locked-in syndrome following embolisation of the pons and left thalamus after the embolisation of the left bronchial artery. During embolisation, a bronchio-visceral fistula with the left subclavian artery was observed and flow into the left vertebral artery was seen. Infarction was confirmed immediately after the procedure on MRI.

Case 3: Lower thoracic spinal cord and conus medullaris ischaemia following embolisation of an intercostobronchial artery. This complication was not suspected at the time of the procedure. An MRI was performed the following day and confirmed features of cord ischaemia.

One case resulted in minor complication of dysphagia but no clinical follow up is recorded. The patient is HIV negative. No incidence of contrast reaction was noted.

This study of 107 cases is the second largest study to date (after Ramakantan Ravi et al) that specifically investigates the success of the BAE procedure where the clinical presentation of massive haemoptysis is the result of PTB (active or sequelae), comparing success rates with HIV status. The study also addresses the rate of technical success of the procedure, compares it with the rate of clinical success and correlates these with HIV status. By investigating technical events during the procedure the study aims to determine reasons for failed BAE. It is a retrospective observational study and had no impact on the outcome or method of management of the cases.

A local study by Corr et al (1998) in the same geographic region, investigated 87 patients retrospectively who presented with massive haemoptysis between 1997 and 1998 in order to determine the efficacy of BAE in the treatment of major haemoptysis. The rate of procedural success demonstrated in this study was 88.5% with the remaining having failed for unspecified technical reasons. A successful clinical outcome was noted in 66.5%. Fifty eight percent of patients had evidence of active PTB. The HIV rate was 32% and 75% of these patients were successfully managed with BAE (38).

International studies (Brazil, Turkey, USA, Hong Kong, France and Japan) have investigated the role of BAE since Remy et al in 1973 to Chun et al in 2010. Most have investigated the role of BAE without specifically addressing this etiology in the context of coinfection with HIV (1, 2, 11, 12, 25, 26, 29-31, 37, 39, 40) and specifically addressing only the cases with a clinical presentation of massive and life threatening haemoptysis (1, 12, 37, 39, 40).

cases, 53 were excluded because HIV status was not documented in the case notes. This may be due to the fear of stigmatization, patients concern that they would be managed differently should the diagnosis of HIV be proven, or non disclosure of a known diagnosis to clinician at this referral centre. None of the cases were assessed for evidence of immunosuppression due to other causes such as poor general health, poor nutrition, diabetes or concurrent disease.

The dominance of PTB as a cause for massive or life threatening haemoptysis in our setting is reflected in the exclusion of only 2 cases due to other causes (asthma and metastatic cancer). Many (66,4%) had a history of PTB and 57% were referred from another health care facility with diagnosis of active PTB and were on treatment at the time of referral. Twenty eight sputum cases were smear or culture positive for AFB or MTB respectively. Nine (32,1%) of these were also multidrug resistance. A large proportion of cases showed radiological evidence of either active or old disease (94,4%). Features of active disease investigated in this study (acute infection, pleural effusion or lymphadenopathy) are demonstrated in 95,3% cases and features of sequelae of previous PTB (architectural distortion or mycetoma) are demonstrated in 96,2% cases. This reflects the endemic nature of the disease in our environment. All methods of diagnosis were equally likely for control and cohort group.

The study did not demonstrate a difference in likelihood of procedural or clinical failure based on HIV status. This supports the findings of a local study where it was first suggested that HIV positive patients tolerate the procedure well (38). This study confirms that they tolerate the procedure as well as HIV negative patients.

Furthermore there is no statistical significance to the correlation of HIV status and the likelihood of procedural or clinical success at the 2 categories of CD4 levels assessed. The likelihood of a procedure being successful with poor clinical outcome is significant for both categories of CD4 levels and further studies with larger case numbers is warranted to investigate further.

4.2 **Imaging findings**

4.2.1 **High Resolution CT Scan**

IALCH is a tertiary/ quaternary hospital which receives referral of cases that can no longer be managed at a primary or secondary health care facility. This means that cases of a more serious nature would be encountered in this study. This may explain why there is no difference in the ability to detect imaging findings on either HRCT or CXR.

Post primary tuberculosis characteristically has a specific zonal distribution (28) namely upper lobe apical and posterior segments and apical segment of lower lobe in immunocompetent patients. In this study no specific zonal distribution was demonstrated in either HIV positive or negative cases with 57 (53.8%) cases demonstrating disease (old or active) in all 4 zones. This

more complicated cases to this hospital. Further studies in a primary care facility may be warranted to investigate the role of each imaging method.

The only feature of statistical significance in the imaging assessment is the presence of lymphadenopathy (LAP) found in 42.4% of HIV negative cases. This is observed to be almost twice as likely compared with HIV positive patients. The literature suggests that LAP is a reflection of the host immune response in primary TB rather than post primary PTB (26). One study has shown that LAP occurs more frequently with HIV positive patients on review of CXR (14). LAP in HIV negative patients +who have post primary TB may be under-reported because the lymphadenopathy is small and more difficult to detect on CXR than on CT scan and this would warrant further research. Studies have shown that the small LAP is better detected on CT chest than on CXR(41).

The relatively lower prevalence of LAP may be as a result of the predominance of post primary TB in our adult population or due to the degree of general immunosuppression (not necessarily due to HIV). It is technically more difficult to detect small LAP on HRCT compared with detection on contrast enhanced thicker slice CT chest. A single radiologist assessed each imaging study and while this may introduce a bias based on the ability to detect the findings, it does also standardize the assessment.

The described imaging pattern of PTB with HIV coinfection is not demonstrated in this study. The incidence of active and old disease is not significantly different between HIV positive and HIV negative cases which may be due to high prevalence of PTB in our environment. None of the imaging features investigated are of statistical relevance when correlated with HIV status.

likely in HIV positive and HIV negative cases and may be the result of immunosuppression due to poor general health.

The endemic nature of PTB in our environment is reflected by radiological features of PTB sequelae in the majority of the cases. Although the literature suggests that it is more difficult to detect active disease when there are features of previous disease on CXR and CT scans (26), 101 cases demonstrated features of active infection. The higher incidence of coinfection may have resulted in more complicated cases in our environment, thus making imaging features more obvious.

Only 15.9% of cases demonstrated pleural effusion but the detection of pleural effusion in the setting of previous pleural and parenchymal disease is difficult.

4.2.2 Bronchial artery embolisation

BAE is an expensive, time consuming and technically demanding procedure (37) with significant risk to patient and operator. When BAE is performed for PTB in the setting of HIV other risks to the operator and patient need to be taken into account. These include blood and blood product exposure and exposure to aerosol PTB/ MDR PTB as the procedure is performed in a closed environment over prolonged periods in the presence of actively expectorating patients. Immunosuppressed patients may have other significant concurrent disease that could impact on the handling of contrast by the patient.

by numerous operators the risk of long term radiation exposure to the operator is negligible. No adverse incidents such as needlestick injuries or eye splashes were recorded.

Three cases resulted in serious complications and 4 deaths were noted as a result of the procedure. Non target embolisation dominated the major complications. A minor complication of dysphagia was recorded but no clinical follow up is recorded. No incidence of contrast reaction was noted.

There is poor correlation between technical success of the procedure and the clinical outcome for the entire caseload. Sixty three of 107 cases were considered procedurally successful but 15 (23.8%) did not have a good clinical outcome. The remaining 48 cases demonstrated both technical and clinical success. The difference is significant ($p=0.008$) suggesting that technical success does not imply symptomatic resolution.

The procedure demands good angiographic technique and persistence. Forty four (41.1%) cases were considered procedurally unsuccessful. The literature reports rates of technical failure from 0 to 56.5% by Chun et al (25).

The 4 factors (unable to select, unable to subselect, spinal feeder and no bleeder identified) that are significant when correlated with overall failure of the procedure, regardless of HIV status, suggests that better training and equipment availability may improve overall procedural success. None of the factors investigated were significant when correlated with HIV status. The ability to select and to embolise arteries (bronchial and visceral) was equally likely for both HIV positive and negative cases.

operator was unable to select a vessel. Reasons for this could include operator inexperience, severe architectural distortion resulting in anatomical remodeling, lack of vessel dilatation and hypertrophy or the presence of vascular thrombosis.

Ten (22.7%) cases failed because of the inability to subselect a vessel and this may be due to operator inexperience, non-availability of specific catheters, microcatheters or guidewires. Vascular fistulae were identified in 17 (38.6%) cases and served as a contraindication to embolisation. This would be more relevant if smaller embospheres are available but only large embospheres were available.

Spinal feeders were identified in 15 (34.1%) cases and this is not in keeping with the literature available, that quotes rates of approximately 11.5% (11). The higher incidence of spinal feeders in this study may be the result of over-reporting, as review of the images suggest that proper confirmation was not undertaken. The decision not to embolise may be a reflection of operator inexperience and fear and this may be remedied with better training.

5.1 Projected study benefits

The finding that clinical and procedural success cannot be viewed interchangeably addresses the limitations of the procedure technique at our centre and thus calls for greater training and formation of an interventional unit in order to optimize services. In addition, this knowledge may be used to address both clinician and patient expectations and assist in obtaining informed consent.

The finding that both clinical and procedural success is independent of HIV status reinforces the need to not discriminate against HIV positive patients for this method of management. Furthermore, there is no technical factor to account for a greater chance of procedure failure in HIV positive cases and this would allow for standardization of the procedure. The observed limitations of the technical aspects of BAE in our centre can be addressed and improved upon, so that the procedure may again be used to offer palliative benefit to patients in whom surgery is contraindicated. Further studies are required to assess procedural and clinical outcome when sub-selection and super-selection is being practiced and the procedure technique is optimized.

The study confirms that both CXR and HRCT chest were able to demonstrate the same features in order to determine suitability for BAE. This is thought to be reflective of the severity of disease referred to IALCH. In centers where HRCT is easily accessible, it is the ideal method for pre-embolisation investigation, but in centers of limited resources the CXR can be successfully used as a cost effective screening tool.

The finding that lymphadenopathy is more likely in HIV negative patients ($p=0.017$) may serve as a predictor for the absence of HIV infection when a patient refuses to consent for such testing.

phadenopathy should not be used as an excuse to ignore the universal precautions observed during angio-invasive procedures.

The interpretative aspect of the study was performed by a single investigator thus limiting subjective variance in the interpretation of the CXR, HRCT chest and BAE.

5.2 Study limitations and suggestions

The procedure was performed by registrars at our centre at different stage of training, in the absence of a dedicated interventional unit, and the results may be a reflection of suboptimal skill. The acknowledgement of this should prompt one to improve training or establish a dedicated interventional unit. Once the procedure is standardized and the technique improved, further studies are warranted.

BAE is complex procedure and requires specific resources and thus cannot be performed at primary and secondary level health care facilities. The patients included in the study are those that were referred to the specialist unit for management, and are likely to have more complicated disease and more obvious imaging findings. This may affect the result of comparing CXR and HRCT for detection and assessment of the disease. Furthermore the general health status of each case was not assessed and reasons for immunosuppression other than HIV infection were not taken into account.

The high rate of PTB and HIV infection in our population and at this referral centre as well as the likelihood of greater disease severity may have influenced the results based on Bayesian principles.



PDF Complete

*Your complimentary use period has ended.
Thank you for using PDF Complete.*

[Click Here to upgrade to Unlimited Pages and Expanded Features](#)

imaging findings and BAE may have been improved by

double blinded reporting.

5.3 Conclusion

The study confirms the statement by Yoon et al in 2002 that BAE is a technically demanding procedure and should always be performed by skilled interventional radiologists(13).

HIV infection should not alter accessibility to BAE or affect the technical aspects of the procedure in a patient with massive haemoptysis. The knowledge of this may ease the concerns of patients and allow for testing for HIV status without fear of being sub-optimally managed.

	of cases	failure number and reasons	Haemoptysis (relevant to this study)	Clinical presentation	HIV status assessed	Conclusion
Rémy et al., 1977	104 (49 with active haemoptysis)	14 failure to achieve stable localization of catheter 12 spinal arteries	16 PTB 6 aspergilloma	Massive, life threatening or recurrent	No	success rate of 41/49 Long term success of embolisation depends not only on the quality of arterial occlusion but also on the efficacy of the medical treatment. The prognosis can be improved by this new therapeutic procedure
Uflacker et al., 1983	75 64 BAE	3 failure to select vessel	68 PTB	Life threatening haemoptysis	No	BAE is an effective treatment for immediate control of life-threatening haemoptysis, allowing long-term control of bleeding in the majority of patients
Ramakanta n et al., 1996	140	no technical difficulties reported	140 PTB	greater than 300mL	No	almost complete control achieved in 102 patients patients with massive haemoptysis due to pulmonary tuberculosis should first be treated with BAE
Katoh et al., 1990	33	no technical difficulties reported	PTB inactive 14 (4 with Mycetoma)	Amount not specified	No	combination therapy of repeat BAE and or surgery as the results showed recurrent haemoptysis in 12-21 % of cases the patients with Mycetoma suffered the highest recurrence of bleeding after initial embolisation
Dasilva 1997	40	no technical difficulties reported	34 Inactive PTB	Moderate to severe, massive and profuse	No	BAE is a simple and life saving procedure and should be considered as the primary method of treatment in haemoptysis or as a preoperative method to stabilize the patient before surgery
Corr 1998	87	10 failed on technical grounds . not specified	Active PTB	Major and massive	Yes HIV positive 32	BAE is an effective treatment for major and massive haemoptysis in patients with pulmonary inflammatory disease who are not surgical candidates. Patients who are HIV . positive are able to tolerate the procedure well
Mal et al., 1999	56 46 BAE	3 failed embolisation	12 Active TB 11 inactive PTB 1 aspergilloma	life threatening	No	success rate of 77% in 56 cases with long term control achieved in only 45% of cases beyond 3 months BAE is an effective technique in the emergency treatment of life-threatening haemoptysis but shows that complications are not rare. In view of the results we continue to favor the simplest and the quickest procedure, most likely to control haemoptysis at the first embolisation rather than perform an exhaustive search for collateral circulation

		vessel 1 Rasmussen aneurysm 1 extravasation to close to great vessels		12 massive	No	82% short term effectiveness and 50% effectiveness with patients with recurrent haemoptysis BAE have been demonstrated to be useful in haemoptysis because of PTBq
Swanson KL et al (2002)	54 51 BAE	2 unable to achieve stable catheter position 1 intimal Bronchial artery damage due to catheter	Mycetoma 7 PTB 2	53/54 had haemoptysis amount not specified	No	BAE is a useful therapy to control both acute and chronic haemoptysisq
Cheng 2005	34 47 BAE	6 no bleeder identified 1 cardiac arrest during procedure	Inactive PTB 25 Active PTB 1	massive	No	our overall success rate in the control of bleeding immediately after the procedure was 97%q BAE is a safe and effective means of controlling massive haemoptysis and should be regarded as the first-line treatment for this condition.q
Kim Yong Gil et al (2006)	118	no technical difficulties reported	Active PTB 44 Inactive PTB 7 Aspergillosis 13	Massive in 94	No	72.9% immediate control BAE with appropriate medical treatment should be sufficient for most patients with massive haemoptysis. In patients with massive haemoptysis due to aspergilloma, however, elective surgery should be considered if bleeding is not controlled by repeated BAEq
Poyanli et al., 2007	140	no technical difficulties reported	136 inactive PTB	Massive (69.2%) and moderate (30.8%)	No	success rates of 98.5% immediately and 90% at 1 month BAE us a safe and effective palliative treatment alternative in moderate and massive haemoptysisq
Lee 2008	49	11 reasons not specified	Active PTB 5 Old PTB 42 Mycetoma 3	120 mL median	No	BAE was effective in a series with a sizable proportion of patients suffering from chronic recurrent haemoptysis, which is a common problem with a clinical significance akin to acute major bleeding.q
Chan 2009	251 162 BAE		Inactive PTB 62 Active PTB 13 Mycetoma 10	Life threatening	No	BAE is a safe and effective means of controlling life threatening haemoptysis.q

Number:

HRCT	
CXR	
Disease noted in:	
Right Upper zone	
Right Lower zone	
Left Upper zone	
Left Lower zone	
Disease features:	
Active disease	
Architectural distortion	
Pleural effusion	
Lymphadenopathy	
Mycetoma	
Other: (specify)	

HIV results	
Negative	
Positive	
CD4	

Bronchial Artery Embolisation	
Selected vessels:	
Right bronchial artery	
Left bronchial artery	
Common bronchial artery	
Other: (specify)	
Subselection performed	
Embolisation of pathological vessels:	
Right bronchial artery	
Left bronchial artery	
Common bronchial artery	
Other: (specify)	
Failed embolisation cause:	
Unable to select	
Unable to subselect where required	
Unable to engage securely	
Reflux noted	
Bronchial-pulmonary artery fistula	
Bronchial pulmonary vein fistula	
Bronchial-visceral fistula	
Spinal feeder identified (before or during embolisation attempt)	
Other: (specify)	

MEASURES OF UNIVERSAL PRECAUTIONS FOR THE PROTECTION IN HEALTH CARE SETTINGS

1. Body fluids should be handled with the same precautions as blood

Cerebrospinal fluid, peritoneal fluid, pleural fluid, pericardial fluid, synovial fluid, amniotic fluid, semen, vaginal secretions, breast-milk, unfixed tissues and organs (including the placenta), any bloodstained body fluid, and saliva associated with dentistry should all be handled with the same precautions as blood. Body fluids such as urine, sweat and saliva (except in the context of dentistry) do not pose any known risk.

2. Avoidance of sharp objects (sharps)

É Recognize and avoid all potentially risky objects, not only needles and knives. Examples include towel clips, suction drain introducers and bone spicules.

É Hollow needle-stick injuries account for almost all nosocomial infections recorded.

É Never allow a sharp, especially a contaminated one, near fingers. For example, do not re-sheath used needles, use instruments to load and unload scalpel blades.

É Take personal responsibility for the immediate safe disposal of all sharps used. The safe Disposal of sharps requires further specialized precautions.

É Never hand a sharp to another person. Use an agreed neutral area where the sharp is placed and then picked up. The use of magnetic pads assists with this in the operating room.

É Never pick up a sharp without looking at it.

É Never put a sharp down except in an agreed neutral area.

É Use the safest sharp that will do the job. For example, knives and needles for skin only, scissors and round-nosed needles for tissues.

É Never feel for a needle point (or other sharp object) with the fingers.

É Never put fingers in areas or wounds where a sharp is being used.

É Do not shave patients pre-operatively or pre-delivery unless it is essential for the procedure.

É Avoid the use of wire sutures if possible.

É Use heavy-duty gloves (ring link or similar) in hazardous situations (broken bones, sharp foreign bodies).

3. Avoidance of skin or mucous membrane contamination

The following three risks are identified:

- a) Contamination of hands with body fluids
- b) Spillage on the HCW's body
- c) Spray / aerosol to eyes and face

Hand protection:

É Only have direct contact with a patient and potential fomites (e.g. soiled linen) if non-intact skin on the hands (eg.cuts, eczema) can be completely isolated by impermeable adhesive tape.

É Wear appropriate quality gloves:

(i) Every HCW handling blood/body fluid must use latex gloves

(ii) Remove torn gloves immediately and wash away contamination; and

(iii) Double-gloving reduces skin contamination during operations by 80% and may reduce the risk associated with sharp injury.

Blood/body fluid spillage:

É Use plastic aprons and impermeable boots where risk of spillage exists.

É Ensure that spillage is immediately cleaned according to the guidelines in 4.5.

É All blood and other specimens must be in containers with non-leaking stoppers or lids, and be placed in sealed plastic bags.

É All unfixed tissues and organs (including placentas) must be placed in sealed plastic bags prior to incineration.

Spray / aerosol precautions:

É Use face eye protection (face-shields, eye goggles) where risk exists.

É Continuously aspirate laser and fulguration smoke by suction.

ÉSkin puncture ó allow to bleed.

5. Cleaning / disinfecting / sterilizing

a) Disinfecting / sterilizing

Moist heat (autoclaving) and dry heat (160° for 1 hour) readily destroy HIV. HIV is very sensitive and is destroyed by boiling for 5 minutes. A wide range of disinfectants may be used (see below). Thorough washing before disinfection or sterilization is essential for all equipment. Gloves and plastic aprons should be worn for this procedure.

b) Suitable disinfectants

ÉGlutaraldehyde ó 2% x 1 hour.

ÉHypochlorite solutions ó 2000 parts per million (ppm) for general cleaning. 10 000 ppm x 30 minutes soaking blood-contaminated material.

ÉEthyl alcohol ó 70% V/V x 1 hour.

ÉIsopropanol ó 70% V/V x 1 hour.

ÉIodine ó 1% x 30 minutes. Inactivation of HIV occurs after 5 minutes exposure to most of these agents. The longer exposure time given here accommodates the possible presence of other pathogens and the time required to destroy these pathogens, e.g. HBV.

c) Equipment

Wear gloves when handling equipment contaminated by blood or body fluids. Bloodstained equipment must be wiped as clean as possible with paper towels, which must be discarded after use. Wipe the item with a hypochlorite solution (if suitable) and send it for the usual sterilization. If such cleaning is not possible, place the item in a sealed and labeled clear plastic bag. Protect sharp instruments adequately.

d) Linen

Only handle bloodstained linen with gloved hands. If at all possible, contaminated linen should be placed directly in an appropriately sealed and labeled plastic bag from whence it should be tipped directly into a coldwater sluice or washing machine. If this is not possible the following steps should be taken:

ÉWipe off as much blood as possible.

ÉSoak the bloodstained area in a bucket containing 10 000 ppm available hypochlorite for at least 30 minutes.

ÉSend the linen for the usual laundering (hot water 65-70°C for 5 minutes).

e) Body fluid spillage:

Wear gloves and remove the spillage with paper towels. Immediately discard the soiled paper towels into an appropriate bag for incineration. Once the area is largely free of organic material from the spillage, pour disinfectant containing 2 000 ppm available hypochlorite over the area and allow it to stand for at least 15 minutes. Use paper towels to wipe the area clean and dry.

References

1. MASA Science and Education Committee: Universal precautions for the prevention of HIV and HBV infection in health care settings. S Afr. Med J 1995; **85**: 381-383

Sputum Sample

MEN

The NALC /NAOH solution dissolves mucus and cellular material thereby releasing mycobacteria and killing contaminating bacteria.

Equal volumes of Nalc working solution is added to each specimen. NB For stools, neat NAOH is added and CSFø and sterile fluids, half the volume of Nalc working solution is added.

This is vortexed for 15 seconds, mixed and vortexed for further 15 seconds so that the specimens appear liquefied. (For those specimens still appearing viscous, 1ml NALC powder must be added and the specimen vortexed well.)

The specimen is then left standing for 15 minutes - 20 minutes. After 20 minutes, buffer is added to neutralize the specimen. The specimen is inverted to mix. Specimens are centrifuged at 3000g for 15 minutes.

Step 2: MICROSCOPY

A slide is prepared from the sediment for Auramine smears, which is a fluorescent stain

Refer to National TB guidelines for reporting of sputum results

Positive Auramine samples will sent to molecular facility for line probe assay which will determine whether the isolate is TB & also will give a susceptibility result for INH & Rifampicin.

Step 3: CULTURE

A culture is prepared from each sediment.

15 Drops of decontaminated specimen (0.5ml) are inoculated into labeled MGIT media using a sterile glass Pasteur pipette.

The MGIT tube is mixed and then loaded onto the BACTEC 960 instrument. - Automated

MGIT=Mycobacterial growth indicator tube

Instrument will flag positive usually 7-14 days after bottle loaded into machine

Positive MGIT bottles have a Ziehl-Neelson done on them ó if ZN positive & cording present-most likely MTB.

MGIT bottle sent to molecular facility for line probe assay which will determine whether the isolate is TB & also will give a susceptibility result for INH & Rifampicin.

If AFB present but no cording on positive MGIT bottle, an MPT 64 Antigen test (immunochromatographic-like pregnancy test órapid) is done. If positive, MGIT bottle goes for line probe assay. If negative, specimen sent out as MOTT.

If line probe assay shows that it is susceptible to INH & Rifampicin, no further drug susceptibility test will be done.

If line probe assay shows that it is resistant to INH &/or Rifampicin, drug susceptibility test will be done.

MGIT bottle will be plated onto solid Middlebrook agar media for 1st& second line susceptibility testing (INH, Rifampicin, Streptomycin, and Ofloxacin & Kanamycin)

Postgraduate committee UKZN

07 December 2010

Dr J Maharajh
Department of Radiology
Nelson R Mandela School of Medicine



Dear Dr Maharajh

PROTOCOL: The impact of HIV infection when superimposed with Pulmonary Tuberculosis (either active or sequelae Tuberculosis), on the Success of Bronchial Artery Embolisation (BAE). Student: M Govind, student number 933481893. (Radiology)


The Postgraduate Education Committee ratified the approval of the abovementioned study on 07 December 2010.

Please note:

- The Postgraduate Education Committee must review any changes made to this study.
- The study may not begin without the approval of the Biomedical Research Ethics Committee.

May I take this opportunity to wish the student every success with the study.

Yours sincerely



Professor SR Thomson
Dean's Assistant: MMed Programmes
Postgraduate Education Committee

CC. Dr M Govind

Biomedical Research Ethics Committee
Westville Campus

Postgraduate Education Administration,
Medical School Campus

Postal Address: Private Bag 7, Congella, 4013, South Africa

Telephone: +27 (0)31 260 4745

Facsimile: +27 (0)31 260 4723

Email: post@ukzn.ac.za

Website: www.ukzn.ac.za

Founding Campuses:  Edgewood  Howard College  Medical School  Pietermaritzburg  Westville



RESEARCH OFFICE
Biomedical Research Ethics Administration
Westville Campus, Govan Mbeki Building
Private Bag X 54001
Durban
4000
KwaZulu-Natal, SOUTH AFRICA
Tel: 27 31 2604769 - Fax: 27 31 2604609
Email: BEREC@ukzn.ac.za
Website: <http://research.ukzn.ac.za/BiomedicalResearchEthics/BREC>

24 January 2011

Dr. M Govind
Department of Diagnostic Radiology
Nelson R. Mandela School of Medicine
University of KwaZulu- Natal

PROTOCOL: The impact of HIV infection when superimposed with Pulmonary Tuberculosis,
on the Success of Bronchial Artery Embolisation (BAE), REF: BE059/010

EXPEDITED APPLICATION - RATIFICATION

This letter serves to notify you that at a full sitting of the Biomedical Research Ethics
Committee meeting held on 14 December 2010, the Committee RATIFIED the sub-
committee's decision to approve the above study.

Yours sincerely



Mrs A Marimuthu
Senior Administrator: Biomedical Research Ethics



DEPARTMENT OF HEALTH

PROVINCE OF KWAZULU-NATAL

INKOSI ALBERT LUTHULI CENTRAL HOSPITAL

OFFICE OF THE MEDICAL MANAGER

800 Beiliev Road, Mayville, 4058

Private Bag 2003, Mayville, 4058

Tel. 031 240 1058 Fax: 031 240 1050

Email: ursalanun@ialch.co.za

Reference: HE098/010
Enquiries: Dr M E L Joshua

26 May 2019

Dr M Govind
Department of Radiology
IALCH

Dear Dr Govind

RE: PERMISSION TO CONDUCT RESEARCH AT IALCH

I have pleasure in informing you that permission has been granted to you by the Medical Manager to conduct research on the impact of HIV infection when superimposed with Pulmonary Tuberculosis, on the Success of Bronchial Artery Embolisation (BAE)

Kindly take note of the following information before you continue:

1. Please ensure that you adhere to all the policies, procedures, protocols and guidelines of the Department of Health with regards to this research.
2. This research will only commence once this office has received confirmation from the Provincial Health Research Committee in the KZN Department of Health.
3. Kindly ensure that this office is informed before you commence your research.
4. The hospital will not provide any resources for this research.
5. You will be expected to provide feedback once your research is complete to the Medical Manager.

Yours faithfully


.....
Dr M E L Joshua
Medical Manager





DEPARTMENT OF HEALTH

PROVINCE OF KWAZULU-NATAL

INKOSI ALBERT LUTHULI CENTRAL HOSPITAL

OFFICE OF THE MEDICAL MANAGER
800 Bellair Road, Mayville, 4058
Private Bag X03, Mayville, 4058
Tel: 031 240 1042 Fax: 031 240 1050
Email: Philiswemaz@alch.co.za

28 May 2010

Dr M Govind
Dept of Radiology
IALCH

Dear Dr M Govind

**Re: Ref No: BE059/010 The Impact of HIV infection when superimposed with
pulmonary Tuberculosis, on the Success of Bronchial Artery Embolisation (BAE)**

As per the policy of the Provincial Health Research Committee (PHRC), you are hereby granted permission to conduct the above mentioned research once all relevant documentation has been submitted to PHRC inclusive of Full Ethical Approval

Kindly note the following:

1. The research should adhere to all policies, procedures, protocols and guidelines of the KwaZulu-Natal Department of Health.
2. Research will only commence once the PHRC has granted approval to the researcher.
3. The researcher must ensure that the Medical Manager is informed before the commencement of the research by means of the approval letter by the chairperson of the PHRC.
4. The Medical Manager expects to be provided feedback on the findings of the research.
5. Kindly submit your research to:

The Secretariat
Health Research & Knowledge Management
330 Langaliballe Street, Pietermaritzburg, 3200
Private Bag X9501, Pietermaritzburg, 3201
Tel: 033395-3123, Fax 033394-3782

Yours faithfully



Dr M E L Joshua
Medical Manager



Data Collection Sheet
BAE Study

Patient Name: í .í í .í í í í í í í
KZ Number: í ...í í í í í í í í í í í í .
Sex: í í í í í Age: ...í í í í í í ..

Date of admission: í í í í í í í í .
Date of discharge: í í í í í í í í ..

BAE: Emergency:
 Elective:

Clinical Details

Haemoptysis:

- Minor
- Massive
- Clinically life threatening

Previous BAE:

- No
- Yes: í í í í í í í í ..

HIV Status:

- Positive
CD4: í í í í í .
- Negative
- Unknown

Pulmonary Tuberculosis:

- Referral hospital diagnosis
 - On clinical assessment
 - On microbiological assessment
 - AFB
 - Culture
 - Resistance: í í í í í í í
- On CXR or CT
- Previous PTB
Dates: í í í í í í í í í ...

Successful

- Immediate
- By discharge

Failed

- on this admission
- required surgery
- Readmission
- Death
- Complications: í í í í í í í í í í í ..

1. Lee S, Chan JWM, Chan SCH, Chan YH, Kwan TL, Chan MK, et al. Bronchial artery embolisation can be equally safe and effective in the management of chronic recurrent haemoptysis. Hong Kong Medical Journal = Xianggang Yi Xue Za Zhi / Hong Kong Academy Of Medicine. 2008;14(1):14-20.
2. Ramakantan R, Bandekar VG, Gandhi MS, Aulakh BG, Deshmukh HL. Massive hemoptysis due to pulmonary tuberculosis: control with bronchial artery embolization. Radiology. 1996 September 1, 1996;200(3):691-4.
3. Day C, Gray A. Health and Related Indicators. Health Systems Trust Department of Therapeutics and Medicines Management.
4. Marshall TJ, Flower CDR, Jackson JE. The role of radiology in the investigation and management of patients with haemoptysis. Clinical Radiology. 1996;51(6):391-400.
5. WHO. Global Tuberculosis control. Epidemiology, strategy, financing. 2008;World Health Organisation(WHO/HTM/TB/2008):393.
6. WHO. Global tuberculosis control. Epidemiology, strategy, financing. Geneva. World Health Organisation. 2009;WHO/HTM/TB/2009:411.
7. Knott-Craig C, Oostuizen J, Rossouw G, Joubert J, Barnard P. Management and prognosis of massive hemoptysis. Recent experience with 120 patients. J Thorac Cardiovasc Surg. 1993 July 1, 1993;105(3):394-7.
8. Crocco JA, Rooney JJ, Fankushen DS, DiBenedetto RJ, Lyons HA. MASSIVE HEMOPTYSIS. Arch Intern Med. 1968 June 1, 1968;121(6):495-8.
9. Marshall TJ, Jackson JE. Vascular intervention in the thorax: bronchial artery embolization for haemoptysis. European Radiology. 1997;7(8):1221-7.

- Walker S, Stavropoulos C, Rothpearl A. Active pulmonary tuberculosis in patients with AIDS: spectrum of radiographic findings (including a normal appearance). *Radiology*. 1994 October 1, 1994;193(1):115-9.
11. Rémy J, Arnaud A, Fardou H, Giraud R, Voisin C. Treatment of Hemoptysis by Embolization of Bronchial Arteries. *Radiology*. 1977 January 1, 1977;122(1):33-7.
 12. Katoh O, Kishikawa T, Yamada H, Matsumoto S, Kudo S. Recurrent bleeding after arterial embolization in patients with hemoptysis. *CHEST*. 1990 March 1, 1990;97(3):541-6.
 13. Yoon W, Kim JK, Kim YH, Chung TW, Kang HK. Bronchial and Nonbronchial Systemic Artery Embolization for Life-threatening Hemoptysis: A Comprehensive Review¹. *Radiographics*. 2002 November 1, 2002;22(6):1395-409.
 14. Leung AN, Brauner MW, Gamsu G, Mlika-Cabanne N, Ben Romdhane H, Carette MF, et al. Pulmonary tuberculosis: comparison of CT findings in HIV-seropositive and HIV-seronegative patients. *Radiology*. 1996 March 1, 1996;198(3):687-91.
 15. Jean-Baptiste E. Clinical assessment and management of massive hemoptysis. *Critical Care Medicine*. 2000;28(5):1642-7.
 16. Hudson CP, Wood R, Maartens G. Diagnosing HIV-associated tuberculosis: reducing costs and diagnostic delay. *The International Journal of Tuberculosis and Lung Disease*. 2000;4(3):240-5.
 17. Smith RL, Yew K, Berkowitz KA, Aranda CP. Factors Affecting the Yield of Acid-fast Sputum Smears in Patients With HIV and Tuberculosis. *CHEST*. 1994 September 1, 1994;106(3):684-6.
 18. Klein NC, Duncanson FP, Lenox TH, Pitta A, Cohen SC, Wormser GP. Use of mycobacterial smears in the diagnosis of pulmonary tuberculosis in AIDS/ARC patients. *CHEST*. 1989 June 1, 1989;95(6):1190-2.

- hart C, Simberkoff M, Ellner J. Accelerated course of human immunodeficiency virus infection after tuberculosis. *Am J Respir Crit Care Med*. 1995 January 1, 1995;151(1):129-35.
20. Leung AN. Pulmonary Tuberculosis: The Essentials. *Radiology*. 1999 February 1, 1999;210(2):307-22.
21. Saurborn DP, Fishman JE, Boiselle PM. The Imaging Spectrum of Pulmonary Tuberculosis in AIDS. *Journal of Thoracic Imaging*. 2002;17(1):28-33.
22. Glynn JRa, Murray Jbc, Bester Ad, Nelson Gc, Shearer Sd, Sonnenberg Pe. Effects of duration of HIV infection and secondary tuberculosis transmission on tuberculosis incidence in the South African gold mines. *AIDS*. 2008;22(14):1859-67.
23. Hirshberg B, Biran I, Glazer M, Kramer MR. Hemoptysis: Etiology, Evaluation, and Outcome in a Tertiary Referral Hospital. *CHEST*. 1997 August 1, 1997;112(2):440-4.
24. Beigelman C, Sellami D, Brauner M. CT of parenchymal and bronchial tuberculosis. *European Radiology*. 2000;10(5):699-709.
25. Chun J-Y, Belli A-M. Immediate and long-term outcomes of bronchial and non-bronchial systemic artery embolisation for the management of haemoptysis. *European Radiology*. 2010;20(3):558-65.
26. Kim YG, Yoon H-K, Ko GY, Lim C-M, Kim WD, Koh Y. Long-term effect of bronchial artery embolization in Korean patients with haemoptysis. *Respirology*. [Article]. 2006;11(6):776-81.
27. van den Heuvel MM, Els Z, Koegelenberg CF, Naidu KM, Bolliger CT, Diacon AH. Risk factors for recurrence of haemoptysis following bronchial artery embolisation for life-threatening haemoptysis. *The International Journal of Tuberculosis and Lung Disease*. 2007;11(8):909-14.
28. Kim HY, Song K-S, Goo JM, Lee JS, Lee KS, Lim T-H. Thoracic Sequelae and Complications of Tuberculosis1. *Radiographics*. 2001 July 1, 2001;21(4):839-58.

- Chan CS, Lin AWN, et al. Major haemoptysis in Hong Kong: aetiologies, angiographic findings and outcomes of bronchial artery embolisation. *The International Journal Of Tuberculosis And Lung Disease: The Official Journal Of The International Union Against Tuberculosis And Lung Disease*. 2009;13(9):1167-73.
30. Mal H, Rullon I, Mellot F, Brugière O, Sleiman C, Menu Y, et al. Immediate and Long-term Results of Bronchial Artery Embolization for Life-Threatening Hemoptysis*. *CHEST*. 1999 April 1, 1999;115(4):996-1001.
 31. Uflacker R, Kaemmerer A, Neves C, Picon PD. Management of massive hemoptysis by bronchial artery embolization. *Radiology*. 1983 March 1, 1983;146(3):627-34.
 32. Carles J, Clerc F, Dubrez J, Couraud L, Drouillard J, Videau J. The bronchial arteries: anatomic study and application to lung transplantation. *Surgical and Radiologic Anatomy*. 1995;17(4):293-9.
 33. Feigelson HH, Ravin HA. Transverse Myelitis Following Selective Bronchial Arteriography. *Radiology*. 1965 October 1, 1965;85(4):663-5.
 34. Chiro GD. Unintentional Spinal Cord Arteriography: A Warning. *Radiology*. 1974 July 1, 1974;112(1):231-4.
 35. Cohen AM, Doershuk CF, Stern RC. Bronchial artery embolization to control hemoptysis in cystic fibrosis. *Radiology*. 1990 May 1, 1990;175(2):401-5.
 36. Lee JH, Kwon SY, Yoon HI, Yoon CJ, Lee KW, Kang SG, et al. Haemoptysis due to chronic tuberculosis vs. bronchiectasis: comparison of long-term outcome of arterial embolisation. *The International Journal Of Tuberculosis And Lung Disease: The Official Journal Of The International Union Against Tuberculosis And Lung Disease*. 2007;11(7):781-7.
 37. Swanson KL, Johnson M, Prakash UBS, McKusick MA, Andrews JC, Stanson AW. Bronchial Artery Embolization. *CHEST*. [Article]. 2002;121(3):789.

- tion for Life-Threatening Hemoptysis Using Acryl
microspheres. Short-term result. Cardiovascular and Interventional Radiology. 2005;28(4):439-41.
39. Alcantara-Peraza AR, Frias-Salcedo JA, Carrillo-Largaespada OL, Reza-Trujillo C, Castañeda F. Bronchial Artery Embolization for Hemoptysis Secondary to Pulmonary Tuberculosis. Semin intervent Radiol. 2000 31.12.2000;17(02):185,92.
40. Poyanli A, Acunas B, Rozanes I, Guven K, Yilmaz S, Salmaslioglu A, et al. Endovascular therapy in the management of moderate and massive haemoptysis. The British Journal Of Radiology. 2007;80(953):331-6.
41. Burrill J, Williams CJ, Bain G, Conder G, Hine AL, Misra RR. Tuberculosis: A Radiologic Review1. Radiographics. 2007 September-October 2007;27(5):1255-73.