

**THE ANATOMICAL STUDY OF THE OSTEOCHONDRAL,
VASCULAR AND MUSCULAR RELATIONS OF THE
SUPERFICIAL AND DEEP CERVICAL PLEXUSES**

By

PATHMAVATHIE PILLAY

Submitted in fulfillment of the requirements for the degree

MASTER OF MEDICAL SCIENCE

In the Discipline of Clinical Anatomy, School of Medical Sciences,

College of Health Science

University of KwaZulu-Natal

2010

*To my grandfather, the late Mr MS Govender,
Parents, Krish & Esther Soobramoney, sister, Charlene
& husband, Vasen Pillay*

*“What lies behind us and what lies before us are tiny matters compared to what lies within us.”
Ralph Waldo Emerson*

ABSTRACT

In standard anatomical textbooks, the formation of the cervical plexus is well defined; however the accurate differentiation into superficial and deep plexuses, their emerging patterns, and gross anatomical relations are not documented as expansively.

In order to obtain detailed anatomical knowledge of the superficial and deep cervical plexuses, the investigation aimed to clarify the anatomy and variations of these plexuses, define possible anatomical landmarks, and record the relationship of the external jugular vein and muscles of the posterior triangle of neck to the branches of the superficial cervical plexus, and the relationship of the common carotid artery, internal jugular vein, sympathetic chain, cervical vertebrae, and vertebral artery to the deep cervical plexus.

The studies utilized the gross anatomical dissection, morphological and statistical analyses of forty fetal and fifteen adult cadaveric, formalinized specimens. The branches of the superficial cervical plexus emerged from the posterior border of the sternocleidomastoid muscle at the great auricular point (situated in the middle third of the muscle) and was described as ascending (lesser occipital, great auricular, transverse cervical nerves) and descending (supraclavicular nerves). Further, these branches were recorded according to their branching patterns, relations to the external jugular vein and variations. The branching patterns are described as single, duplicate and triplicate. The external jugular vein was constantly located inferior to the great auricular nerve, superior to the transverse cervical nerve and intertwined with the branches of the supraclavicular nerves. Variations of the branches of the superficial cervical plexus were observed only in fetuses and classified according to their course, branching patterns and

communications. The emerging point of the branches of the superficial cervical plexus on the sternocleidomastoid muscle, were determined according to the seven types of “emerging pattern” classification by Kim *et al.*, (2002).

In order to record the deep cervical plexus, the sternocleidomastoid muscle was reflected with the following observation: the ventral rami of the second and third cervical nerves emerged between the scalenus anterior and scalenus medius muscles, and the third and fourth cervical nerves was located at the lateral edge of scalenus medius muscle.

The deep cervical plexus was described as communicating, muscular, ansa cervicalis, and phrenic nerves. The superior cervical ganglion constantly communicated with the ventral rami of the cervical nerves; and the hypoglossal communicated with the superior root of the ansa cervicalis. The muscular branches were observed to the scalenus anterior and scalenus medius muscles with an anomalous branch to the sternocleidomastoid muscle. The ansa cervicalis demonstrated a degree of variation with regard to its origin, course and formation of the loops. The phrenic nerve arose from the ventral rami of the third, fourth and fifth cervical nerves and descended on the lateral border of the scalenus anterior muscle.

The precise understanding of the anatomy of the superficial and deep cervical plexuses together with variations may assist anesthetists and surgeons to accurately identify the vascular, neural and muscular structures and reduce the risks of complications when performing neural blocks in regional anesthesia, facial rejuvenation surgery and parotidectomies.

SUPPORTING SERVICES

In this study the foetal and adult cadaveric material was obtained from the Discipline of Clinical Anatomy, School of Medical Sciences, College of Health Sciences, University of KwaZulu-Natal (Westville and Medical School campuses).

PREFACE

This study represents original work by the author and has not been submitted in any other form to another University. Where use was made of the work of others, it has been duly acknowledged in the text.

The research described in this dissertation was supervised by Professor KS Satyapal and Professor P Partab (Discipline of Clinical Anatomy, School of Medical Science, University of KwaZulu-Natal) and was conducted in the Discipline of Clinical Anatomy, School of Medical Sciences, University of KwaZulu-Natal (Westville and Medical School campuses)

“Appreciation is a wonderful thing. It makes what is excellent in others belong to us as well”... Voltaire

ACKNOWLEDGEMENTS

The author wishes to express her sincere gratitude to the following individuals for their assistance in the preparation of this dissertation:

- First and foremost, I would like to thank my greatest teacher: God.
- My supervisors, Professors KS Satyapal and P Partab for their inspiration, assistance, supervision, support, constructive criticism and guidance. Also, for their thoughtfulness and generosity, from them I have learned much of life's philosophy.
- Ms L Lazarus for her friendship, encouragement, constructive criticism, inspiration and support.
- Mr T Lelaka, Mr A Mkhize & Mr P Mohanlall (Discipline of Clinical Anatomy, University of KwaZulu-Natal:Westville campus) for their technical support and kind assistance.
- Ms Brenda De Gama, for her friendship, advice, encouragement and support in all aspects of this work.
- Ms Leanne Govender and Ms Nokuthula Hlongwa for their continued friendship, encouragement and support.
- Ms Lindsey Naidu and Ms Tanya Maistry for their friendship.
- Mr Vasen Pillay for his love, patience, understanding, support and encouragement.
- My sister, Charlene, for her continued encouragement in all aspects of my life.
- And my parents for the life they gave me, my moral values and my education. I appreciate the efforts they have put into giving me the life I have. They are the reason I thrive to be better.

CONTENTS

PAGE

Abstract	i
Supporting services	iii
Preface	iv
Acknowledgements	v
List of figures	xii
List of tables	xix
List of plates	xvi

CHAPTER 1: INTRODUCTION

1.1 Introduction	1
------------------------	---

CHAPTER 2: LITERATURE REVIEW

2.1 Embryology	5
2.1.1 Development of the nervous system	5
2.1.2 Peripheral nervous system	6
2.1.3 Cervical somites	7
2.1.4 Spinal cord	8
2.2 A brief overview of the cervical plexus	9
2.3 Anatomy of the superficial cervical plexus	13
2.3.1 Lesser occipital nerve	16
2.3.2 Great auricular nerve	21

2.3.3	Transverse cervical nerve	26
2.3.4	Supraclavicular nerves.....	29
2.4	Anatomy of the deep cervical plexus	31
2.4.1	Medial series.....	32
2.4.2	Lateral series.....	35
2.5	Ansa cervicalis	36
2.6	Phrenic nerve	43
2.7	Communicating branches.....	46
2.8	Relations of the cervical plexus	50
2.8.1	External jugular vein	50
2.8.2	Sternocleidomastoid muscle	50
2.9	Clinical importance: regional anaesthesia	53
a)	Cervical plexus blocks	53
b)	Superficial cervical plexus block	53
c)	Deep cervical plexus block.....	54

CHAPTER 3: MATERIALS AND METHOD

3.1	Gross anatomical dissection.....	57
3.1.1	Selection criteria.....	57
3.1.2	Dissection procedure	57
3.2	Morphological & morphometric analysis	61
3.3	Statistical analysis.....	62

CHAPTER 4: RESULTS

4.1	Sample demographics	64
4.2	Gross anatomy	64
4.3	Lesser occipital nerve	66
4.3.1	Incidence.....	66
a)	Fetuses	66
4.3.1.1	Comparison of the length on the right and left sides	66c
b)	Adults	67
4.3.1.2	Comparison of the length on the right and left sides	67
4.3.2	Overall incidence of lesser occipital nerve	67
4.3.3	Course	68
4.3.4	Branching pattern.....	69
4.3.5	Variations	72
4.3.6	Relation to external jugular vein.....	75
4.4	Great auricular nerve	77
4.4.1	Incidence.....	77
a)	Fetuses	77
4.4.1.1	Comparison of the length on the right and left sides	77
b)	Adults	78
4.4.1.2	Comparison of the length on the right and left sides	78
4.4.2	Course	78
4.4.3	Branching patterns	80
4.4.4	Variation	84

4.4.5	Relation to external jugular vein.....	85
4.5	Transverse cervical nerve	87
4.5.1	Incidence.....	87
a)	Fetuses	87
4.5.1.1	Comparison of the length on the right and left sides	87
b)	Adults	88
4.5.1.2	Comparison of the length on the right and left sides	88
4.5.2	Course	88
4.5.3	Branching patterns	89
4.5.4	Variations	92
4.5.5	Relation to external jugular vein.....	95
4.6	Supraclavicular nerves	96
4.6.1	Incidence.....	96
a)	Fetuses	96
4.6.1.1	Comparison of the length on the right and left sides	96
b)	Adults	96
4.6.1.2	Comparison of the length on the right and left sides	97
4.6.2	Course	97
4.6.3	Branching patterns	98
4.6.4	Variations	100
4.6.5	Relation to external jugular vein.....	103
4.7	Emerging points of the superficial cervical plexus.....	105
4.8	Gross anatomy of deep cervical plexus	109

4.8.1 Muscular branches.....	110
4.8.2 Ansa cervicalis.....	111
4.8.2.1 Variations.....	116
4.8.3 Phrenic nerve	121
4.9. Communicating branches.....	121
4.10. Root formation of cervical plexus.....	123
4.11 Variations of the external jugular vein.....	128
4.12 Variations of the internal jugular vein	130

CHAPTER 5: DISCUSSION

5. 1 Sample	134
5. 2 Gross anatomy	134
5.3 Superficial cervical plexus.....	135
5.3.1 Lesser occipital nerve	135
5.3.2 Great auricular nerve	137
5.3.3 Transverse cervical nerve	139
5.3.4 Supraclavicular nerves.....	140
5.4 Variations of the superficial cervical plexus.....	142
5.4.1 Lesser occipital nerve	142
5.4.2 Great auricular nerve	143
5.4.3 Transverse cervical nerve	143
5.4.4 Supraclavicular nerves.....	144
5. 5 Emerging points of the superficial cervical plexus.....	146

5. 6 Deep cervical plexus	147
5. 6.1 Muscular branches.....	147
5. 6.2 Ansa cervicalis.....	147
5. 7 Variations of deep cervical plexus	149
5. 7 Landmarks.....	151
5. 8 Communications	151
5. 9 External jugular vein.....	152

CHAPTER 6: CONCLUSION

Conclusion	155
------------------	-----

REFERENCES

Journals	157
Books	169

APPENDIX

.....	174
Scientific Research to date.....	181

LIST OF FIGURES

Figure 1:	Illustration of the roots, loops and branches of the cervical plexus	1
Figure 2:	Dorsal view of the embryo, exposed by the removal of the amnion.....	5
Figure 3:	Dorsal view of embryo illustrating formation of the neural tube and detachment from the surface ectoderm.....	6
Figure 4:	Formation of a spinal nerve.....	7
Figure 5:	Dorsal view of embryo illustrating formation of somites	8
Figure 6:	Illustration of the roots, loops and branches of the cervical plexus	9
Figure 7:	Schema of the branches of the cervical plexus	11
Figure 8:	Right anterior view of the neck illustrating Erb's point and nerves piercing the cervical fascia	13
Figure 9:	The right anterior and lateral view of the superficial cervical plexus distribution.....	14
Figure 10:	The left anterior view of the superficial cervical plexus branches	15
Figure 11:	The lesser occipital nerve.....	16
Figure 12:	Illustration of the classification of lesser occipital nerve branching pattern.....	18
Figure 13:	Course of the great auricular nerve on posterior border of the sternocleidomastoid muscle	21
Figure 14:	Anterior and Posterior branches of the great auricular nerve	22
Figure 15:	Illustration of the three branches of great auricular nerve	24
Figure 16:	Illustration of the transverse cervical nerve.....	27

Figure 17:	Anastomosis between transverse cervical nerve and cervical branch of facial	28
Figure 18:	Illustration of the branches of the supraclavicular nerves	29
Figure 19:	Schematic illustration of the roots, and loops of the cervical plexus.....	31
Figure 20:	Muscular branches to Rectus capitis anterior	32
Figure 21:	Muscular branches to Rectus capitis lateralis).....	33
Figure 22:	Muscular branches to Longus capitis.....	33
Figure 23:	Muscular branches to Longus colli	34
Figure 24:	Schematic illustration of the branches of the deep cervical plexus	35
Figure 25:	Superior and inferior roots of ansa cervicalis	36
Figure 26:	Relation of the ansa cervicalis to the internal jugular vein and carotid artery	37
Figure 27:	Regional anatomy of the ansa cervicalis	38
Figure 28:	Classification of the types of ansa cervicalis	39
Figure 29:	Variations in the location of the loop of the ansa cervicalis	41
Figure 30:	Seven morphologic forms of the ansa cervicalis nerve formation.....	42
Figure 31:	Course of the Phrenic nerve in the neck	44
Figure 32:	Communications of the cervical plexus with the hypoglossal nerve.....	46
Figure 33:	Communications of the cervical plexus with Accessory nerve	47
Figure 34:	Superior cervical ganglion communication with upper four cervical nerve	48
Figure 35:	Variations in the communications between cervical nerves and superior cervical ganglion	49

Figure 36:	Left anterior view of the external jugular vein	51
Figure 37:	Relation of the internal jugular vein to ansa cervicalis	52
Figure 38:	Superficial cervical plexus block illustrating needle position.....	54
Figure 39:	Illustration of dissection procedure.....	59
Figure 40:	Illustration of the division of the sternocleidomastoid muscle	60
Figure 41:	Graphic representation of lesser occipital nerve branching patterns	69
Figure 42:	Right fetal Lesser occipital nerve relation	75
Figure 43:	Left fetal Lesser occipital nerve relation	75
Figure 44:	Right adult Lesser occipital nerve relation	75
Figure 45:	Left adult Lesser occipital nerve relation.....	75
Figure 46:	Branching pattern of the great auricular nerve	81
Figure 47:	Right fetal Great auricular nerve relation	86
Figure 48:	Left fetal Great auricular nerve relation.....	86
Figure 49:	Right adult Great auricular nerve relation	86
Figure 50:	Left adult Great auricular nerve relation.....	86
Figure 51:	Graphic illustration of the branching patterns of the transverse cervical nerve	90
Figure 52:	Right fetal transverse cervical nerve relation.....	95
Figure 53:	Left fetal transverse cervical nerve relation.....	95
Figure 54:	Right adult transverse cervical nerve relation.....	95
Figure 55:	Left adult transverse cervical nerve relation	95
Figure 56:	Right fetal supraclavicular nerve relation	104
Figure 57:	Left fetal supraclavicular nerve relation	104

Figure 58:	Right adult supraclavicular nerve relation	104
Figure 59:	Left adult supraclavicular nerve relation.....	104
Figure 60:	Graphic representation of classification of emerging points of the superficial cervical plexus	107
Figure 61:	Graphic representation of the origin of the inferior root of ansa cervicalis.....	114

LIST OF TABLES

Table 1: Classification of the Cervical Plexus.....	12
Table 2: Origin and distribution of the superficial cervical plexus	15
Table 3: Incidence and length of lesser occipital nerve in fetal specimens.....	66
Table 4: Incidence and length of the lesser occipital nerve in adult specimens	67
Table 5: Branching Patterns of the lesser occipital nerve	69
Table 6: Incidence and length of the great auricular nerve in fetal specimens.....	77
Table 7: Incidence and length of the great auricular nerve in adult specimens.....	78
Table 8: Branching Patterns of the great auricular nerve	81
Table 9: Type I and Type II duplicate branching patterns of the great auricular nerve	83
Table 10: Incidence and length of the transverse cervical nerve in fetal specimens.....	87
Table 11: Incidence and length of the transverse cervical nerve in adults	88
Table 12: Branching patterns of the transverse cervical nerve.....	90
Table 13: Incidence and length of the supraclavicular nerve in fetuses	96
Table 14: Incidence and length of the supraclavicular nerve in adults.....	97
Table 15: Average lengths of the sternocleidomastoid muscle and superficial cervical plexus branches	105
Table 16: Classification of the emerging points of superficial cervical plexus.....	106
Table 17: Origin and distribution of the superficial cervical plexus	124

LIST OF PLATES

Plate 1:	Right anterior view of the posterior triangle of neck depicting the superficial cervical plexus branches.....	65
Plate 2:	Left anterior view of the course of the lesser occipital nerve	68
Plate 3:	Left anterior view of the single branching pattern of the lesser occipital nerve	70
Plate 4:	Right anterior view of the duplication of lesser occipital nerve.....	71
Plate 5:	Right anterior view of the triplication of the lesser occipital nerve	72
Plate 6:	Left anterior view of the anomalous course of the lesser occipital nerve	73
Plate 7:	Left anterior view of the lesser occipital nerve located in “carefree part” of the neck.....	74
Plate 8:	Magnified view (X80) of the communication between the two lesser occipital nerves (indicated by dotted circle) (Left anterior view)	74
Plate 9:	Right anterior view of neck depicting the course of the great auricular nerve	79
Plate 10:	Right anterior view of neck depicting the great auricular nerve relation to the external jugular vein	80
Plate 11:	Left anterior view of the single branching pattern and distribution of the great auricular nerve	82
Plate 12:	Right anterior view of Type I branches of the great auricular nerve	83
Plate 13:	Left anterior view of Type II branches of the great auricular nerve.....	84

Plate 14: Left anterior view of the communication between great auricular nerve and the transverse cervical nerve	85
Plate 15: Right anterior view of the location and course of the transverse cervical nerve	89
Plate 16: Right anterior view of single branching pattern of the transverse cervical nerve	91
Plate 17: Right anterior view of ascending and descending branches of the transverse cervical nerve	92
Plate 18: Left anterior view of triplicate transverse cervical nerve.....	93
Plate 19: Anastomosis between the transverse cervical nerve and facial nerve (Left anterior view)	94
Plate 20: Anastomosis between ascending branch of the transverse cervical nerve and cervical branch of facial nerve (Left anterior view)	94
Plate 21: Right anterior view of the course of the supraclavicular nerve.....	98
Plate 22: Left anterior view of the medial branch of the supraclavicular nerve and its relation to the external jugular vein and the sternocleidomastoid muscle.....	99
Plate 23: Right anterior view of the lateral and intermediate branch of the supraclavicular nerve.....	100
Plate 24: Right anterior view of additional branches of the supraclavicular nerve.....	101
Plate 25: Right anterior view of the anomalous branching of supraclavicular nerve....	102
Plate 26: Left anterior view of the anomalous course medial branch of the supraclavicular nerve.....	103
Plate 27: Right anterior view of Type I emerging pattern.....	107

Plate 28: Left anterior view of Type III emerging pattern	108
Plate 29: Right anterior view of emergence of cervical nerves between scalenus anterior and scalenus medius muscles.....	109
Plate 30: Left anterior view of additional supply to the sternocleidomastoid muscle by the ventral rami of third and fourth cervical nerves	110
Plate 31: Right anterior view of muscular branches to scalenus medius and scalenus anterior muscles (indicated by arrows)	111
Plate 32: Right anterior view of the medial series ansa cervicalis	112
Plate 33: Right anterior view of superior root of ansa cervicalis located posterior to internal jugular vein.....	113
Plate 34: Right anterior view of origin of inferior root from ventral rami of second and third cervical nerves (indicated by arrow).....	114
Plate 35: Left anterior view of origin of inferior root from the ventral ramus of the second cervical nerve	115
Plate 36: Left anterior view of short ansa cervicalis and muscular branches from the loop of ansa cervicalis	116
Plate 37: Double classic form of the ansa cervicalis with two separate roots	117
Plate 38: Right anterior view of unusual loop of the ansa cervicalis	118
Plate 39: Left anterior view of dual contribution from hypoglossal nerve.....	119
Plate 40: Left anterior view of the “vago-cervical complex”	120
Plate 41: Left anterior of the view of the “vago-cervical complex”	120
Plate 43: Right superior view of the superior cervical ganglion communication with ventral rami of second cervical nerve.....	122

Plate 44: Magnified view of the right superior view of the superior cervical ganglion communication with ventral rami of second cervical nerve	122
Plate 45: Right anterior view of cervical plexus emerging between the scalene muscles	120
Plate 46: Right deep dissection depicting root value of the cervical nerve.....	122
Plate 47: Left view of a deep dissection showing the formation of loops between cervical nerves	126
Plate 48: Right view of deep dissection depicting origin of lesser occipital, great auricular, transverse cervical and supraclavicular nerves from the ventral ramus of second cervical nerve	127
Plate 49: Right anterior view of the “X” or “H” shaped appearance of the external jugular vein.....	128
Plate 50: Right anterior view of an anomalous appearance of internal jugular vein.....	129
Plate 52: Left anterior view of the “Y” shaped appearance of internal jugular vein.....	131
Plate 53: Left anterior view of the dual communication between internal jugular and external jugular veins	132

1.1 INTRODUCTION

According to standard anatomical literature, the superficial and deep cervical plexuses innervate areas of skin on the head, neck and chest, muscles of the neck and the diaphragm (Ellis and Fieldman, 1993; McMinn, 1999; Standring *et al*, 2008). The formation of the cervical plexus is well defined; however the emerging patterns and relations of the deep and superficial plexuses do not appear to be well documented.

The cervical plexus is formed by the ventral primary rami of the first four cervical nerves (Ellis and Fieldman, 1993; Standring *et al.*, 2008) and each branch receives a grey ramus communicans from the superior cervical ganglion to form three simple loops (McMinn, 1999) (Figure 1).

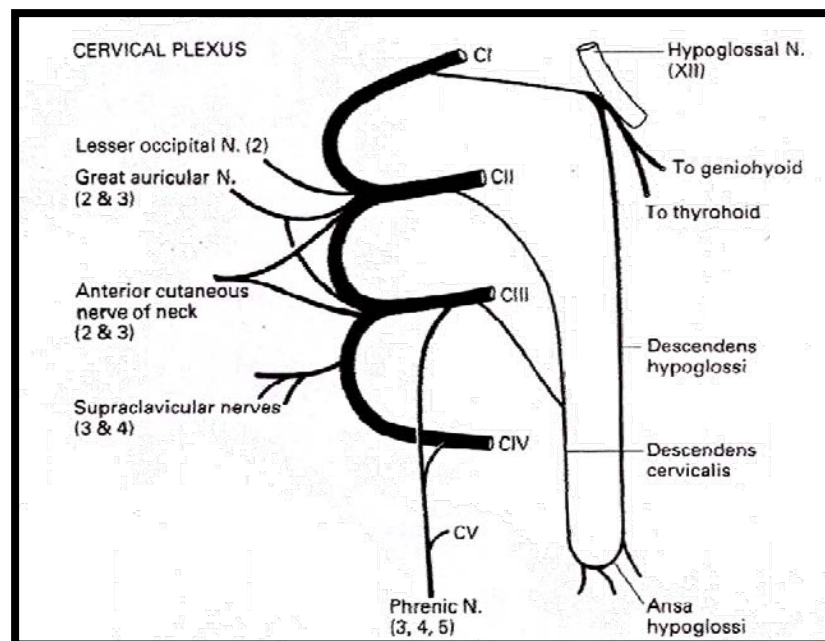


Figure 1: Illustration of the roots, loops and branches of the cervical plexus
(Adapted from Ellis and Fieldman, 1993)

The ventral rami of the second, third and fourth cervical nerves divide into ascending and descending branches which give rise to the superficial and deep cervical plexuses.

Standard anatomical literature describes the superficial cervical plexus as it emerges from beneath the posterior border of the sternocleidomastoid muscle as four distinct cutaneous branches *viz.* lesser occipital, transverse cervical, great auricular and supraclavicular nerves; and the deep cervical plexus as muscular branches, communicating branches, ansa cervicalis and the phrenic nerve (Stranding *et al.*, 2008). However, there have been controversial opinions with regard to the emergence of the superficial cervical plexus as well as its course and branching patterns (Ellis and Fieldman, 1993; Suresh and Templeton, 2004).

Regional anesthetic block of the cervical plexus is an increasingly available alternative for surgery of the neck (Santamaria *et al.*, 2004; Suresh and Templeton, 2004), eg. thyroid surgery (Aunac *et al.*, 2002); and is particularly used for carotid endarterectomy (Stoneham *et al.*, 1998; Knighton and Stoneham, 2000; Pintaric *et al.*, 2007) because of the possible overall lower incidence of morbidity and mortality. In addition, there are advancements in clinical practice whereby the use of high-resolution ultrasound imaging of these plexuses is utilized for cervical plexus blocks (Roessel and Wiessner, 2007).

Therefore, the detailed, precise anatomical understanding of these plexuses will enable anesthetists and surgeons to accurately identify the vascular, neural and muscular structures and reduce the risks of complications when performing neural blocks in regional anesthesia.

The study therefore aims to:

1. define the superficial and deep cervical plexuses and their variations
2. define the anatomical landmarks of the superficial & deep cervical plexuses
3. record the relationship of the external jugular vein and muscles of the posterior triangle of neck to the superficial cervical plexus; and the relationship of the cervical vertebrae, common carotid artery, internal jugular vein, sympathetic chain, and vertebral artery to the deep cervical plexus.

2.1 EMBRYOLOGY

2.1.1 DEVELOPMENT OF THE NERVOUS SYSTEM

The nervous system develops during the third week from the neural plate (Figure 2), which is a thickened, elongated slipper-shaped area of embryonic ectoderm. The mesoderm and notochordal process induce the overlying ectoderm to differentiate into the neural plate (Moore and Persaud, 1998).

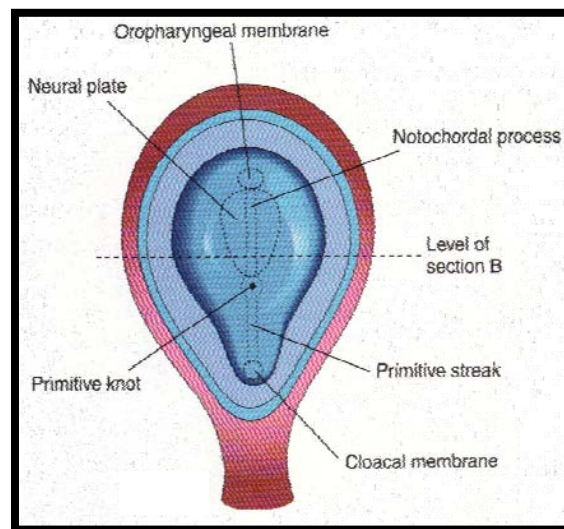


Figure 2: *Dorsal view of the embryo, exposed by the removal of the amnion*
(Adapted from Moore and Persaud, 1998)

A longitudinal neural groove develops in the neural plate, which is surrounded by neural folds. The fusion of the neural folds forms the neural tube. The neural folds fuse opposite the fourth to sixth somites and are widely spread apart at both ends (Moore and Persaud, 1998).

The neural crest is formed when the neuroectodermal cells migrate dorsolaterally between the surface ectoderm and neural tube (Figure 3). The neural crest divides into two masses that give rise to the sensory ganglia of the spinal and cranial nerves (Moore and Persaud, 1998).

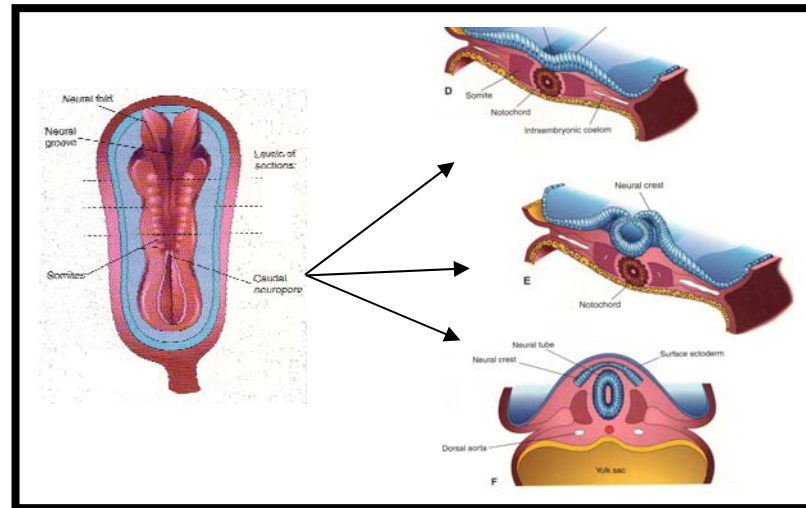


Figure 3: *Dorsal view of embryo illustrating formation of the neural tube and detachment from the surface ectoderm (Adapted from Moore and Persaud, 1998)*

2.1.2 PERIPHERAL NERVOUS SYSTEM

The peripheral nervous system (PNS) consists of cranial, spinal and visceral nerves as well as cranial, spinal and visceral ganglia. The PNS develops from various sources, mostly from neural crest cells. Sensory cells (somatic and visceral) are derived from neural crest cells and their cell bodies are located outside the central nervous system. During the fourth week, motor nerve fibres arise from the basal plates of the developing spinal cord. The fibres destined for a particular muscle group become arranged in a bundle forming the ventral nerve root and the nerve fibres of the dorsal root are derived from neural crest cells that migrate to the dorsolateral aspect of spinal cord and differentiate into cells of the spinal ganglion. The spinal ganglion forms a single bundle

that grows towards the ventral nerve root and joins it to form the spinal nerve (Figure 4). Immediately after the spinal nerve formation, a mixed spinal nerve divides into dorsal and ventral rami. The dorsal ramus (smaller division) innervates dorsal axial musculature, vertebrae, posterior intervertebral joints and part of the skin of the back. The ventral ramus is a major division of each spinal nerve which innervates the limbs, ventrolateral aspects of the body wall and forms a major nerve plexus viz. the cervical plexus (Moore and Persaud, 1998).

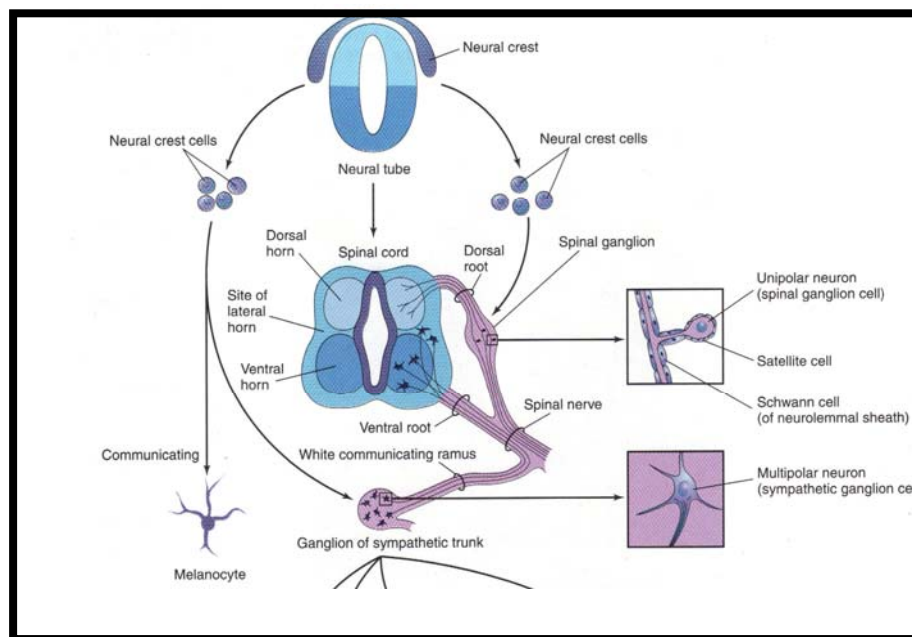


Figure 4: Formation of a spinal nerve (Adapted from Moore and Persaud, 1998)

2.1.3 CERVICAL SOMITES

During the early part of the fourth week, neuralation (formation of the neural tube) begins in the region of the fourth to sixth pairs of somites. Somites are mesodermal derivatives that develop as a series of regular, paired swellings on each side of the neural tube (Figure 5). The peripheral nerves arising from a somatic plexus may contain axons from more than one nerve trunk or spinal segment. These nerve trunks form three plexuses

along the spinal cord viz. the cervical, brachial and lumbosacral (Moore and Persaud, 1998)

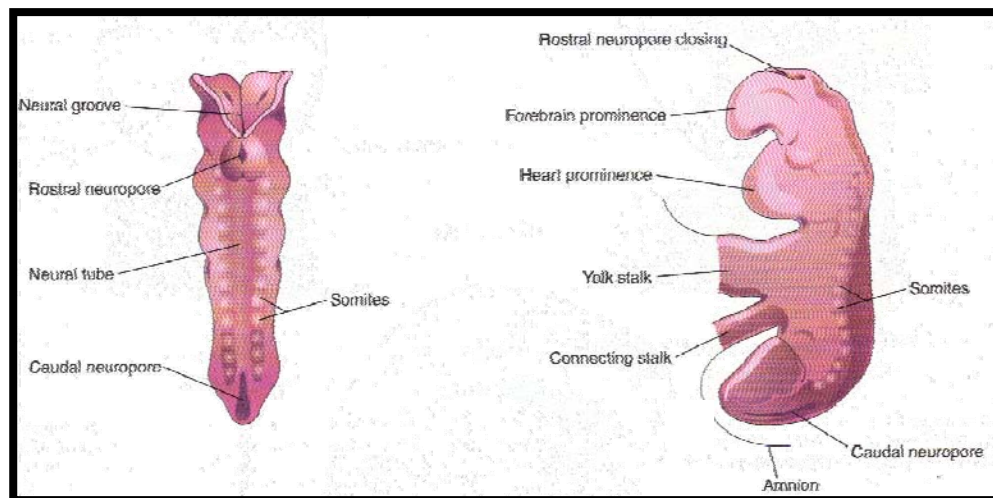


Figure 5: *Dorsal view of embryo illustrating formation of somites*
(Adapted from Moore and Persaud, 1998)

2.1.4 SPINAL CORD

Caudal to the fourth pair of somites, the neural tube develops into the spinal cord. The size of the neural canal gradually decreases (due to the thickening of the lateral walls of the neural tube) until only a minute central canal of the spinal cord is present. With proliferation and differentiation of the spinal cord there is a production of thick roof and thin wall plates. The sulcus limitans is a shallow longitudinal groove which is produced owing to the differential thickening of the lateral wall. This groove separates the dorsal (alar) plate from the ventral (basal) plate. Alar plates form the dorsal grey column and the basal plates form the ventral and lateral horns. Axons of the ventral horn cells grow out of the spinal cord and form the ventral root of the spinal nerves.

2.2 A BRIEF OVERVIEW OF THE CERVICAL PLEXUS

The cervical plexus is a complex structure formed by the ventral rami of the upper four cervical nerves and emerges through a compartment formed between the tubercles of the cervical vertebrae, and between the anterior and posterior scalene muscles (Tobias and Arnold, 1999). Moore and Dalley (1999) suggested that each cervical nerve, with the exception of the first, divides into ascending and descending branches that unite with the branches of the adjacent spinal nerves to form loops. The cervical plexus lies at the level of the first four cervical vertebrae deep to the internal jugular vein and sternocleidomastoid muscle, anterolateral to levator scapulae and the middle scalene muscles (Standring *et al.*, 2008). Tobias and Arnold (1999) stated that the branches of the plexus arise from the roots and the loops (Figure 6).

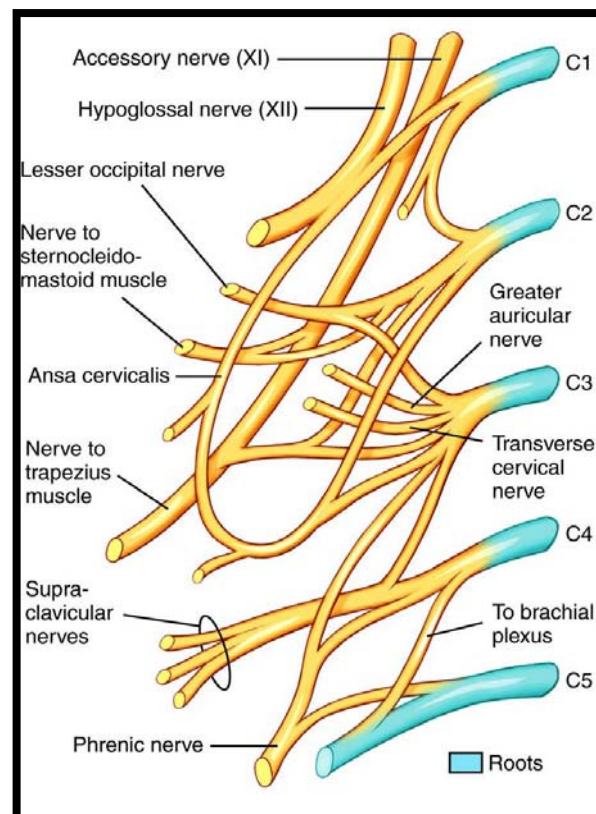


Figure 6: Illustration of the roots, loops and branches of the cervical plexus
(Adapted from Mosby, 2009)

The ventral rami of the first cervical nerve [C1] emerges from the vertebral canal in the groove on the posterior arch of the atlas behind the superior articular facet, and between the posterior arch and vertebral artery. It usually lies on the lateral side of the lateral mass of the vertebra and medial to the vertebral artery as it emerges from the transverse foramen. After supplying twigs to rectus capitus lateralis and longus capitus muscles, it descends in front of the transverse process of the atlas to form a loop with the ascending branch of the ventral ramus of the second cervical nerve [C2].

At the level of the atlas, fibres in the loop between C1 and C2 ventral rami run forward to join the hypoglossal nerve. The C2 ventral ramus emerges posterior to the superior articular process of the axis, and passes forward on the lateral side of the vertebral artery. It divides into an ascending branch which joins C1 ventral ramus and a descending branch which loops to join the ventral ramus of the third cervical nerve [C3].

The ventral ramus of the fourth cervical nerve [C4] emerges from the intervertebral foramen, anterior to the articular pillars and lateral to the vertebral artery. Each of these cervical nerve roots receives a grey ramus communicans from the superior cervical ganglion (Ellis and Fieldman, 1993). C4 lies in series with the brachial plexus beneath the prevertebral fascia (McMinn, 1999). In 1993, Ellis and Fieldman categorized the cervical plexus into four groups viz. superficial, deep, communicating and phrenic (Figure 7).

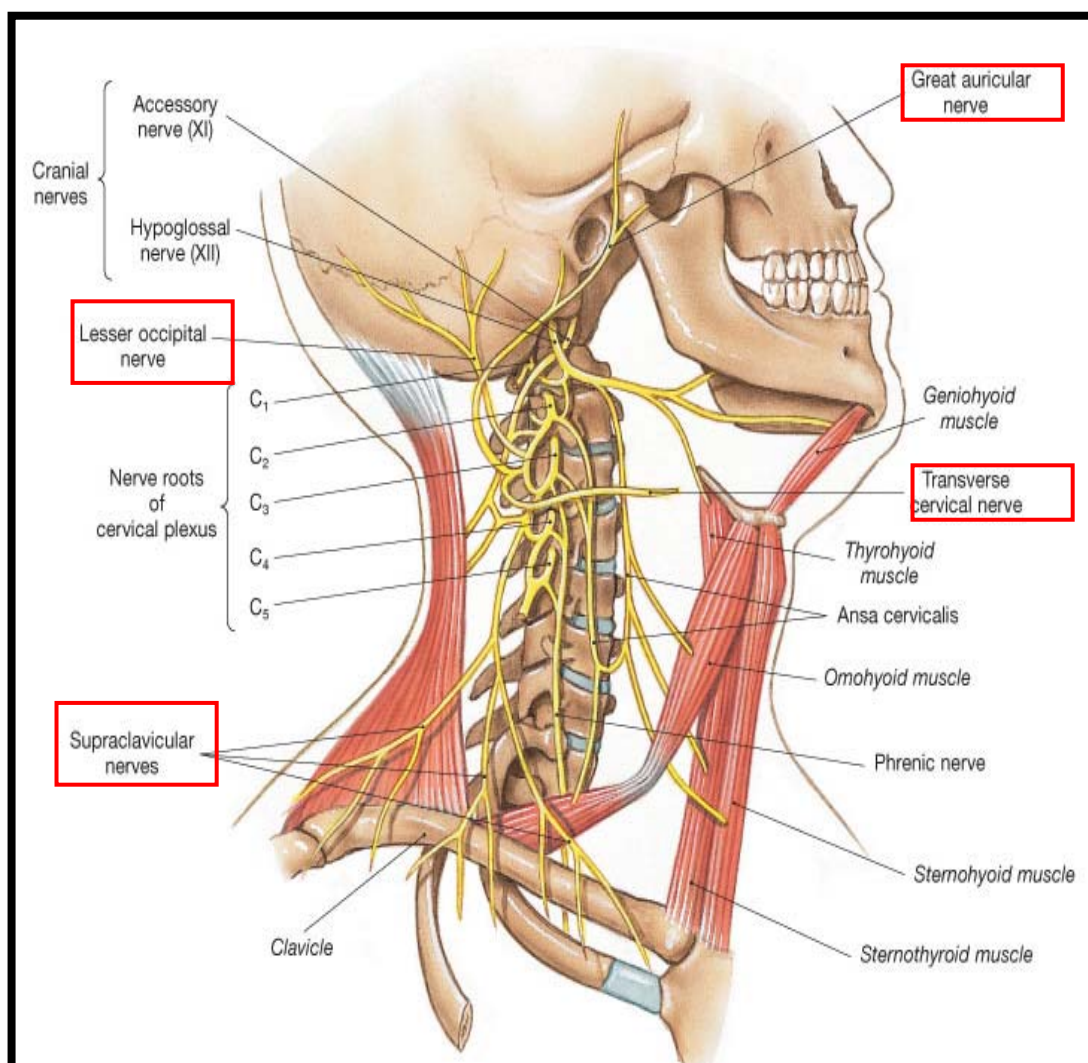


Figure 7: Schema of the branches of the cervical plexus (Adapted Cummings, 2003)

Further, Standring *et al.*, (2008) suggested the sub-division of superficial cervical plexus into ascending (lesser occipital, great auricular and transverse cervical nerves) and descending (supraclavicular) branches and the deep into medial and lateral branches. However, Ellis and Fieldman (1993) described the superficial into ascending (lesser occipital, great auricular nerves), transverse (transverse cervical nerve) and descending (supraclavicular) branches, while standard anatomical textbooks describe the branches of the deep cervical plexus as muscular, communicating, ansa cervicalis and phrenic nerves (Standring *et al.*, 2008, Tobias and Arnold, 1999; Hollinshead, 1974) (Table 1).

Table 1: *Classification of the Cervical Plexus*

AUTHOR (YEAR)	CLASSIFICATION OF CERVICAL PLEXUS	
	Superficial cervical plexus	Deep cervical plexus
Hollinshead (1974)	lesser occipital, great auricular, transverse cervical and supraclavicular nerves	Phrenic nerve
Ellis and Fieldman (1993)	ascending, transverse and descending branches	muscular, communicating, ansa cervicalis and phrenic branches
Standring <i>et al.</i>, (2008)	ascending and descending branches	medial and lateral branches

2.3 ANATOMY OF THE SUPERFICIAL CERVICAL PLEXUS

The cutaneous branches of the Superficial Cervical Plexus are located at or about the midpoint of the posterior border of the sternocleidomastoid muscle and from this point radiate like “spokes of a wheel” anteroinferiorly and posterosuperiorly (Miller, 1981). Moore and Dalley, in 1999 suggested the emergence of these nerves around the middle of the posterior border of the sternocleidomastoid muscle. This region is clinically known as the nerve point of the neck or Erb’s point (Figure 8). Authors such as Salasche *et al.*, (1988), Monsen (1992) and Nason *et al.*, (2000) describe this point as the “great auricular point”. The question was posed by Michael *et al.*, (2003) who asked: “is Erb’s point synonymous with the great auricular point?”

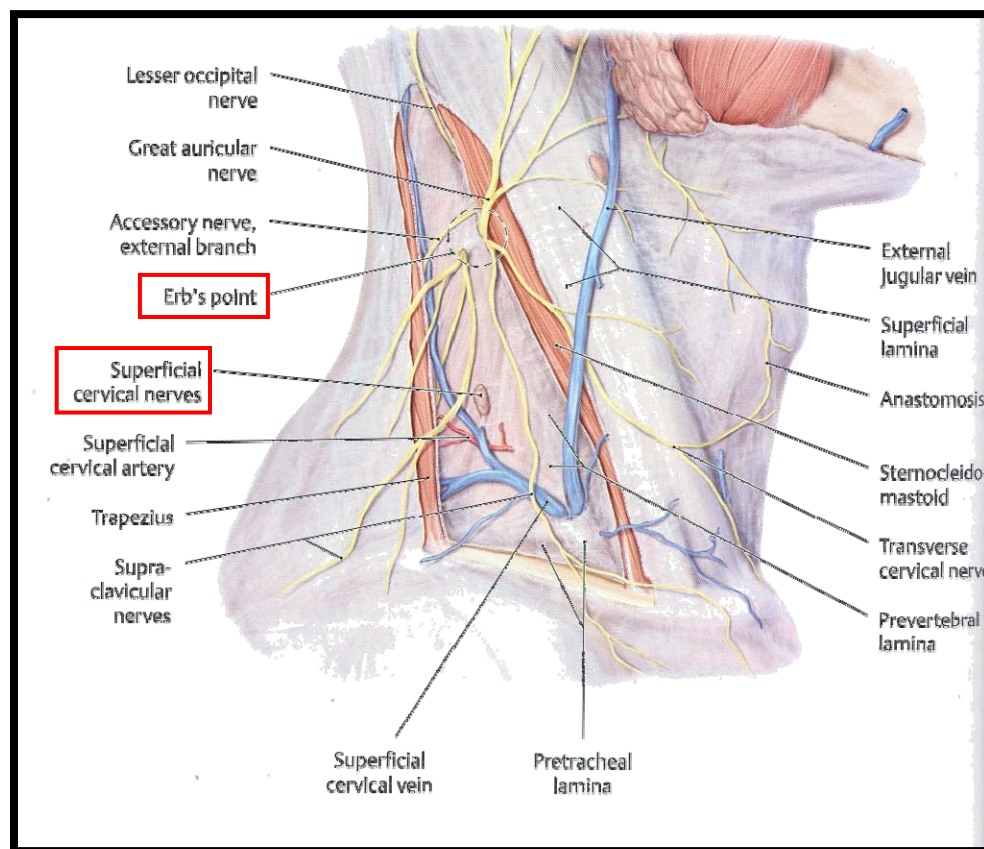


Figure 8: Right anterior view of the neck illustrating Erb’s point and nerves piercing the cervical fascia (Adapted from Clemente, 2007)

In addition, Cramer and Darby, (1995) stated that these superficial cervical plexus branches course around the posterior surface of the sternocleidomastoid muscle and pierces the cervical fascia to emerge from behind its midpoint in proximity to one another. Hollinshead (1974) suggested that the upper three branches of the superficial cervical plexus appear at the posterior edge of the sternocleidomastoid muscle and the lowest is not so intimately related to the posterior border of the sternocleidomastoid muscle.

The branches of the superficial cervical plexus are the lesser occipital nerve, great auricular nerve, transverse cervical nerve and three supraclavicular nerves which originate from the ventral rami of the upper four cervical nerves (Figure 9) and are distributed over a region extending from the superior part of the ear to the skin over the pectoralis major muscle (Standring *et al.*, 2008) (Figure 10, Table 2).

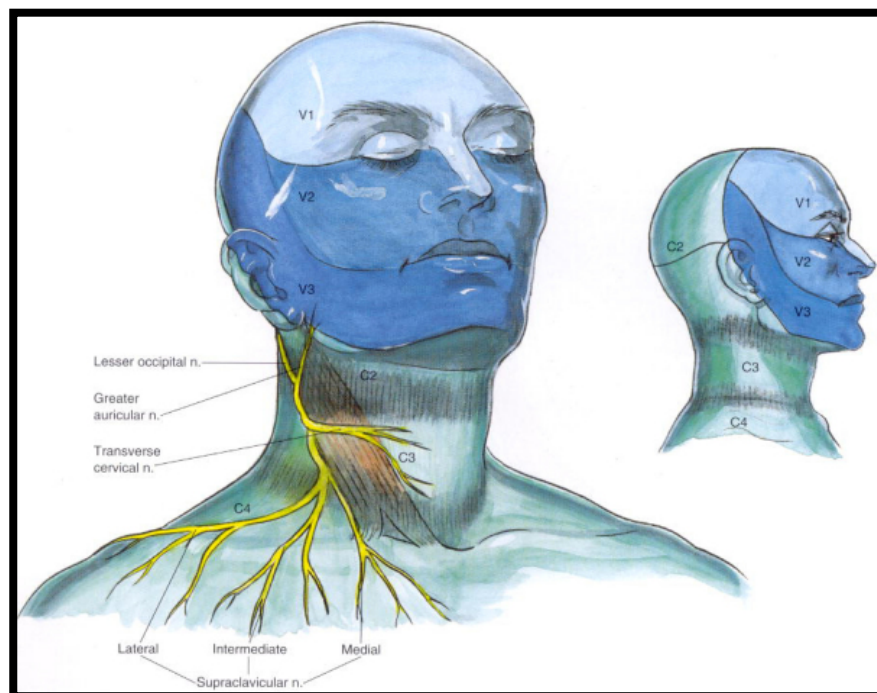


Figure 9: The right anterior and lateral view of the superficial cervical plexus distribution (Adapted from Brown, 2006)

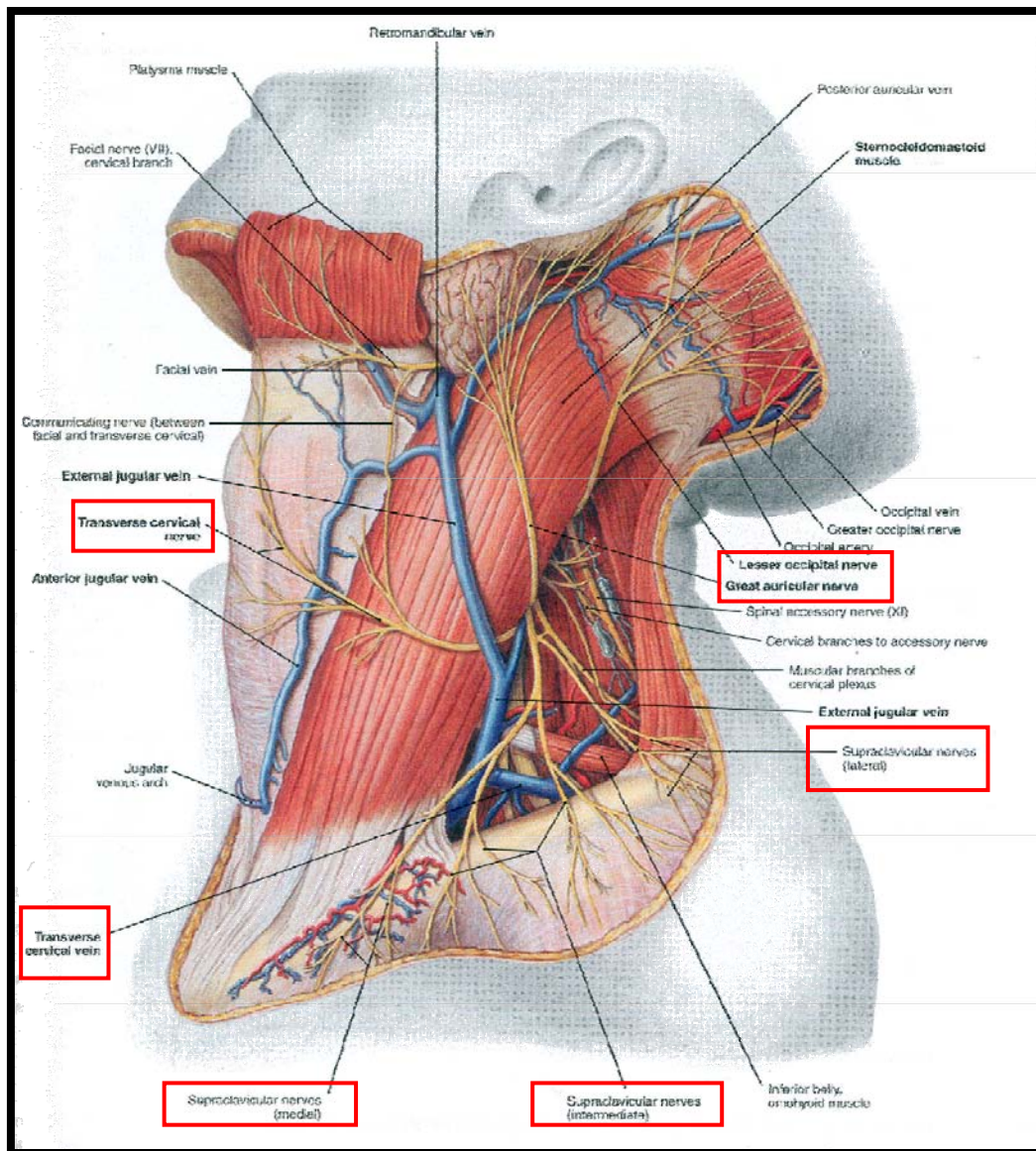


Figure 10: The left anterior view of the superficial cervical plexus branches
(Adapted from Clemente, 2007)

Table 2: Origin and distribution of the superficial cervical plexus

SCP Branches	Root value (ventral rami)	Distribution
Lesser Occipital nerve	C2	Superior part of ear and mastoid area
Great Auricular nerve	C2, C3	Ear and area overlying the angle of the mandible
Transverse cervical nerve	C2, C3	Anterior neck
Supraclavicular nerve	C3, C4	Skin over deltoid and clavicle

2.3.1 LESSER OCCIPITAL NERVE

The lesser occipital nerve is an ascending superficial branch that has a variable origin either from the ventral ramus of the second cervical nerve or second and third cervical nerves and is purely sensory (Berry *et al.*, 1995, Pantaloni and Sullivan, 2000; Madhavi and Holla, 2004). The lesser occipital nerve curves lateral to the accessory nerve, then runs vertically upward along the posterior border of the sternocleidomastoid muscle (Hollinshead, 1974; Ellis and Fieldman, 1993) (Figure 11).

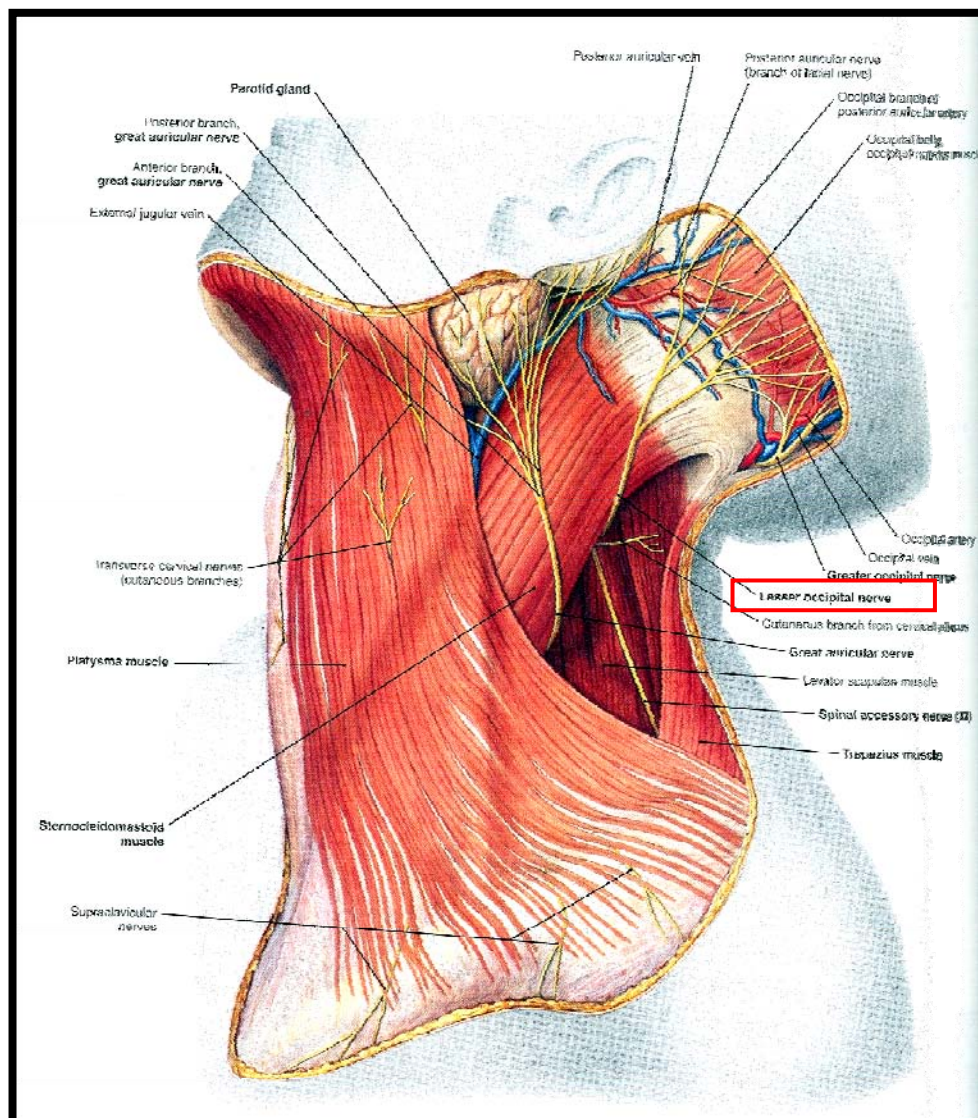


Figure 11: The lesser occipital nerve (Adapted from Clemente, 2007)

Madhavi and Holla, (2004) stated that the lesser occipital nerve ascends towards the occiput by running parallel to the posterior border of the sternocleidomastoid muscle. It perforates the deep fascia near the cranium and continues superiorly over the occiput to supply the integument and communicates with the greater occipital nerve medially (Lucas *et al.*, 1994; Tubbs *et al.*, 2007). Pantaloni and Sullivan (2000) reported that after piercing the deep cervical fascia, the lesser occipital nerve consistently emerged behind the posterior border of the sternocleidomastoid muscle superior to the great auricular nerve. It then coursed in an oblique-cephalic direction toward the ear and the mastoid process, diverging in a fan-like fashion from the great auricular nerve.

The posterior triangle of the neck is bounded anteriorly by the lateral border of the sternocleidomastoid muscle, posteriorly by the medial border of the trapezius muscle and inferiorly by the middle third of the clavicle and its content includes the accessory nerve (Standring *et al.*, 2008). The area within the posterior triangle superior to the accessory nerve is referred to as the “carefree part” since no significant structures are observed in this area; however Lucas *et al.*, (1994) observed an anomalous lesser occipital nerve ascending to the occipital area lying in the posterior triangle of the neck.

In 1987, Fredriksen reported that “trigger” points of cervicogenic headaches are found midway between the external occipital protuberance, mastoid process and the C2 area just behind and below the mastoid process and Lucas *et al.*, (1994) described these sites as being anatomically occupied by the lesser occipital nerve and thus concluded that the lesser occipital nerve may be involved in cervicogenic headaches.

Further, it has been reported by Ellis and Fieldman, in 1993 that the lesser occipital nerve divided into three branches in the upper part of the posterior triangle after piercing the deep fascia. He described these branches as (i) **auricular**: to the upper third of the medial aspect of the ear; (ii) **mastoid**: to skin over mastoid process and (iii) **occipital**: to occipital area immediately above and behind the mastoid process (Figure 12).

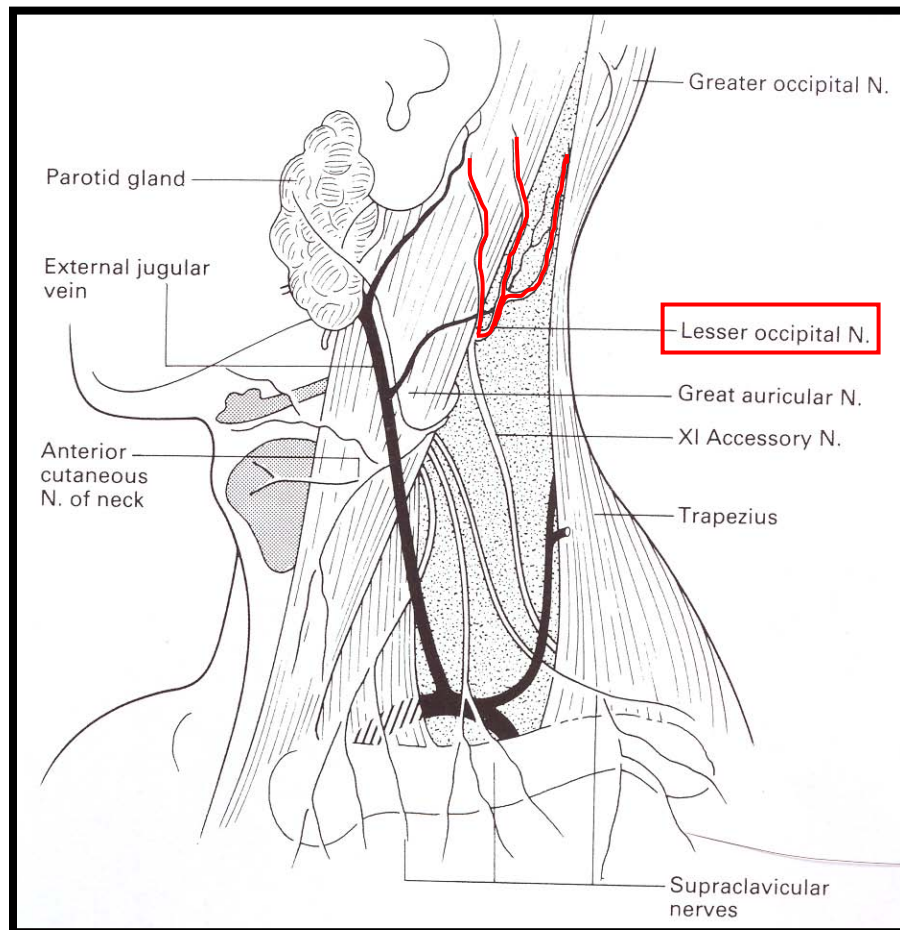


Figure 12: Illustration of the classification of lesser occipital nerve branching pattern
(Adapted from Ellis and Fieldman, 1993)

On the other hand, Berry *et al.*, (1995) classified the same branches as (i) **anterior**: to the mastoid area (ii) **posterior**: to the area of the occiput and (iii) **auricular**: to the ear.

Pantaloni and Sullivan (2000) agreed with the description by Berry *et al.*, (1995) and found that the lesser occipital nerve supplied the superior ear and the mastoid area in the majority of their dissections. In addition, the auricular branches overlap with the great auricular nerve; the posterior branches overlap with the great occipital nerve and posterior auricular branches of the facial nerve. Standring *et al.*, (2008) stated that the auricular branch is occasionally derived from the greater occipital nerve.

It was also suggested by Moore and Dalley (1999) that the lesser occipital nerve innervated the skin of the neck and scalp postero-superior to the auricle and Lucas *et al.*, (1994) noted that the area described for the dermatome of C3 comprised the region supplied by the lesser occipital, transverse cervical and great auricular nerves.

It has been reported that normally a single lesser occipital nerve supplies the postero-lateral area of the neck, scalp and the upper third of the auricle; however variations in the form of duplicate and triplicate lesser occipital nerves have also been reported (Romanes, 1987; Lucas *et al.*, 1994; Berry *et al.*, 1995; Bescer *et al.*, 1998; Madhavi and Holla, 2004).

In the presence of a duplicate lesser occipital nerve: these were described as medial and lateral branches that supplied the adjacent scalp and retro-auricular regions, respectively (Madhavi and Holla, 2004).

In addition, Madhavi and Holla, (2004) observed an anomaly of the lesser occipital nerve whereby there was triplication of the lesser occipital nerve and this was described as Type I, Type II and Type III:

- i. Type I emerged as a slender nerve between the great auricular and accessory nerve. It hooked around the posterior border of the sternocleidomastoid muscle, ascended superficial to this muscle and mastoid process, crossing the superior nuchal line.
- ii. Type II originated from a nerve to the trapezius that had a common origin from the supraclavicular nerve. Type II ascended on the sternocleidomastoid muscle, parallel to Type I.
- iii. Type III was thicker, emerged superior to the accessory nerve on the posterior border of the sternocleidomastoid muscle and ran a sinuous course across the posterior triangle of the neck, passing deep to the trapezius muscle.

Additionally, in a study conducted by Pantaloni and Sullivan (2000) it was reported that the lesser occipital nerve supplied the superior two-thirds of the ear rather than the superior one third as previously described and stressed the importance of this variation in facial rejuvenation surgery (Lucus *et al.*, 1994; Berry *et al.*, 1995).

2.3.2 GREAT AURICULAR NERVE

The great auricular nerve is the largest ascending branch arising from the loop between ventral ramus of the second and third cervical nerves or directly from the ventral ramus of the third cervical nerve (Biglioli *et al.*, 2002; Stranding *et al.*, 2008). It winds around the posterior border of the sternocleidomastoid muscle, perforates the deep fascia and ascends under the superficial musculo-aponeurotic system and platysma muscle, accompanied by the external jugular vein (Pantaloni and Sullivan, 2000; Stranding *et al.*, 2008) (Figure 13).

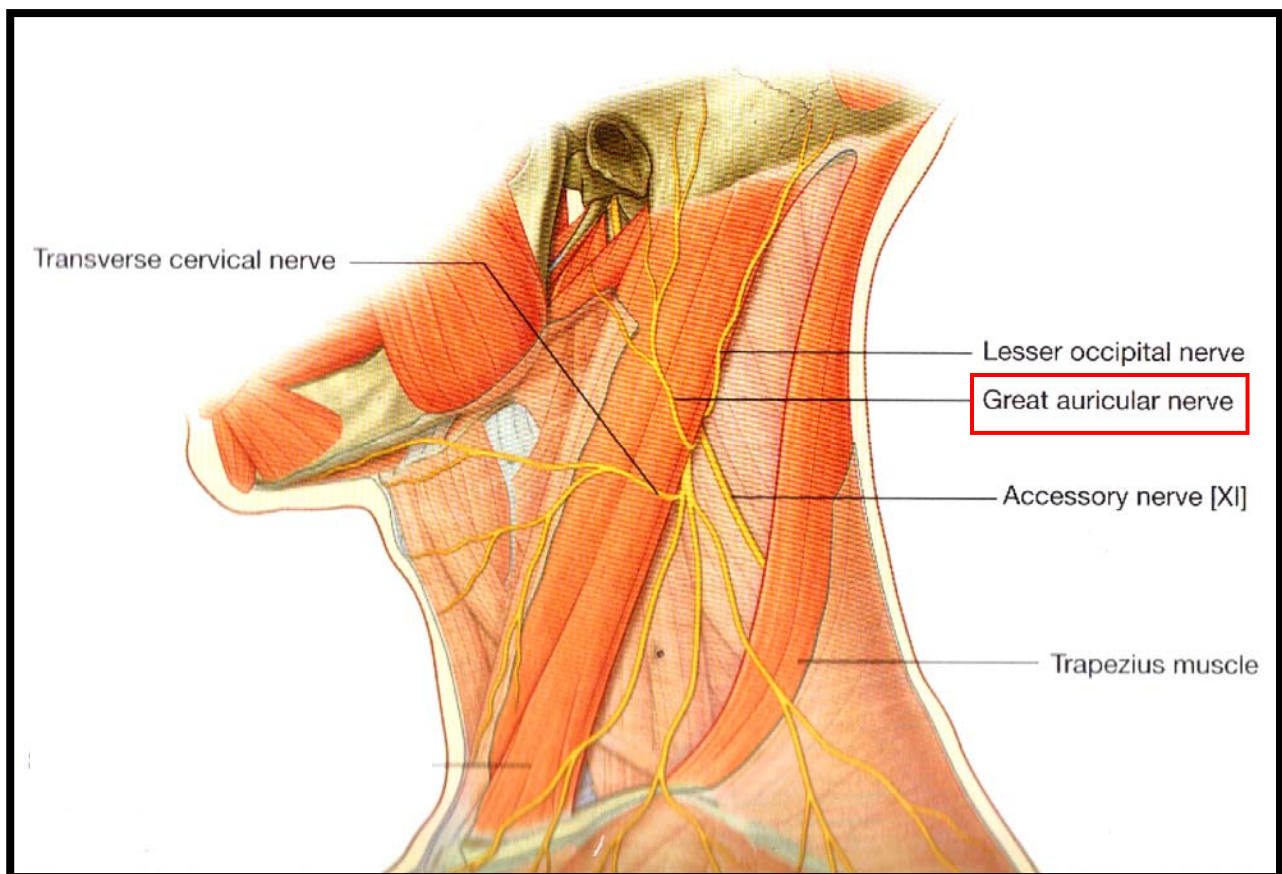


Figure 13: Course of the great auricular nerve on posterior border of the sternocleidomastoid muscle (Adapted from Stranding *et al.*, 2008)

It has been reported that the great auricular nerve divides into anterior and posterior branches as it emerges from beneath the posterior border of the sternocleidomastoid

muscle and these branches ascend diagonally across it towards the parotid gland (Standring *et al.*, 2008) (Figure 14).

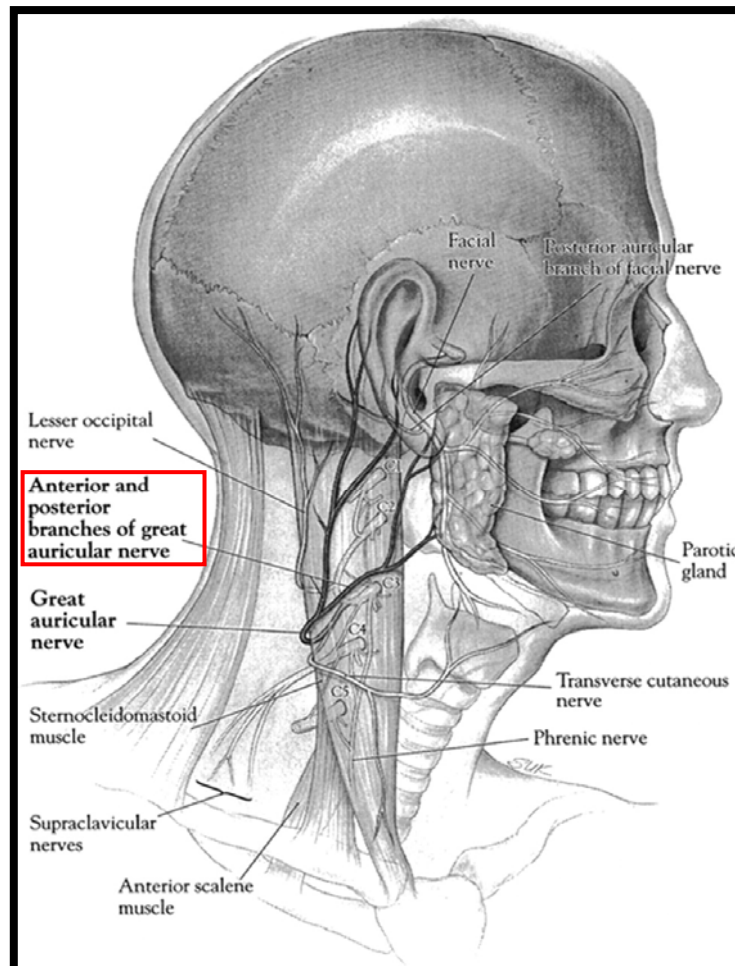


Figure 14: *Anterior and Posterior branches of the great auricular nerve*
(Adapted from Ginsberg and Eicher, 2000)

In addition, Biglioli *et al.*, (2002) suggested that the bifurcation of these two terminal branches occurs in the proximity of the inferior pole of the parotid gland and may be located within or outside the gland. Prior to this bifurcation a collateral branch arises from the great auricular nerve and runs to the skin of the mastoid region and the posterior surface of the auricle.

The anterior branch pierces the inferior pole of the parotid gland and exits anteriorly to innervate the skin overlying the parotid gland (Rouviere 1959) and the angle of the mandible (Hollinshead, 1974). The posterior branch passes to the posterior margin of the glandular parenchyma, destined for the skin over the mastoid process, the postero-inferior surface of the auricle, the lobule, and concha (Cummings, 1993; Moore and Dalley 1999; Patel *et al.*, 2001; Biglioli *et al.*, 2002).

It has been suggested by Biglioli *et al.*, (2002) that the cutaneous innervation over the region of the mastoid process and the submandibular triangle of the neck is supplied by the great auricular nerve. Rogers and Jacob (1992) reported that the great auricular nerve supplied the skin just posterior to the pinna of the ear and Moore and Dalley (1999) stated that the great auricular nerve innervates the parotid sheath.

However, Ellis and Fieldman (1993) described the nerve as having three terminal branches viz. auricular; mastoid and facial that supplies the lower two-thirds of the ear and lateral surface of the lobule; skin over the mastoid process and skin over the masseter and parotid gland, respectively (Figure 15). Zumeng *et al.*, (2006) stated that the great auricular nerve trifurcated above the mandibular angle into anterior auricular, posterior auricular and lobular branches.

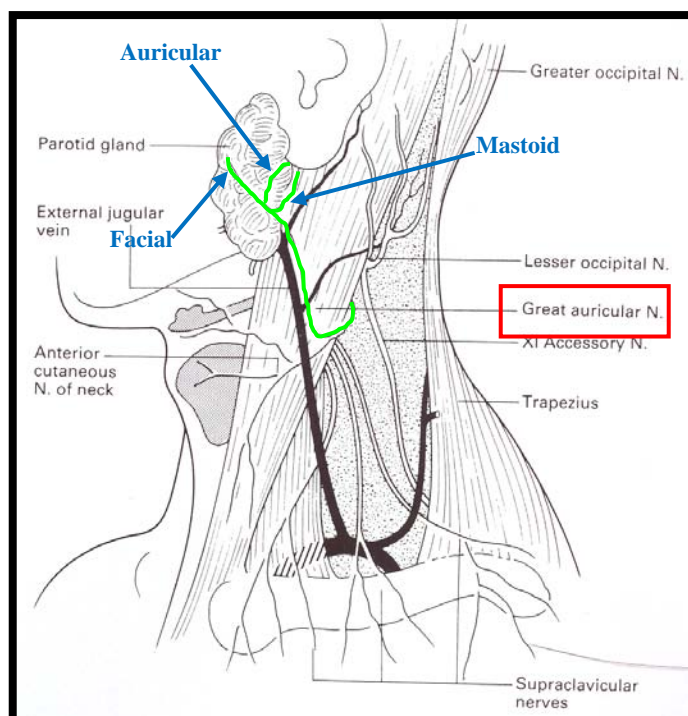


Figure 15: Illustration of the three branches of great auricular nerve
(Adapted from Ellis and Fieldman, 1993)

It has been reported that communications between great auricular nerve and the transverse cervical nerve as well as some cranial nerves exist: The anterior branch of the great auricular nerve sends small branches into the parotid gland and this connects to the facial nerve as they lie on and within the substance of the parotid gland (Ginseng and Eicher, 2000). In a recent study conducted by Brennan *et al.*, (2008), an unusual communication between the great auricular nerve and the marginal mandibular branch of the facial nerve was observed.

The posterior branch of the great auricular nerve joins the auricular branch of the vagus nerve, and posterior auricular branch of the facial nerve behind the ear (Rouviere, 1959) and communicates with the lesser occipital nerve (Wyburn-Mason, 1953; Standring *et al.*, 2008). Therefore, it appears that sensory fibres from the great auricular nerve are carried into the trigeminal area with the facial nerve (Wyburn-Mason, 1953). Biglioli *et al.*,

(2002) reported an anastomosis between the anterior branch of great auricular nerve and the transverse cervical nerve.

Ando *et al.* (1992) stated that during surgical procedures of the head and neck, the great auricular nerve is used as an important anatomical landmark. It is also often accidentally injured during various surgical procedures, such as parotidectomy, neck dissection, and excision of lateral neck masses (Patel *et al.*, 2001).

2.3.3 TRANSVERSE CERVICAL NERVE

The nomenclature of the transverse cervical nerve is variable in standard anatomical textbooks. It is referred to as transverses colli nerve (Wyburn-Mason, 1953), anterior cutaneous nerve of neck (Tobin, 1967; Hollinshead, 1974), superficial cervical nerve or cutaneous cervical nerve (Ellis and Fieldman, 1993; Standring *et al.*, 2008).

The transverse cervical nerve arises from a common stem with the great auricular nerve i.e. from the ventral rami of the second and third cervical nerves. It emerges below the great auricular nerve by turning around sharply near the midline of the posterior border of the sternocleidomastoid muscle, deep to the external jugular vein (Standring *et al.*, 2008) (Figure 16). Ellis and Fieldman (1993) suggested the nerve occasionally was located superficial to the external jugular vein.

After crossing the anterior border of the sternocleidomastoid muscle transversely, the transverse cervical nerve pierces the deep cervical fascia, subsequently dividing beneath the platysma muscle into ascending and descending branches (Standring *et al.*, 2008) that are distributed to the skin of the upper and front parts of the neck (Wyburn-Mason, 1953) and skin of the side and front of neck as far down as the sternum (Hollinshead, 1974).

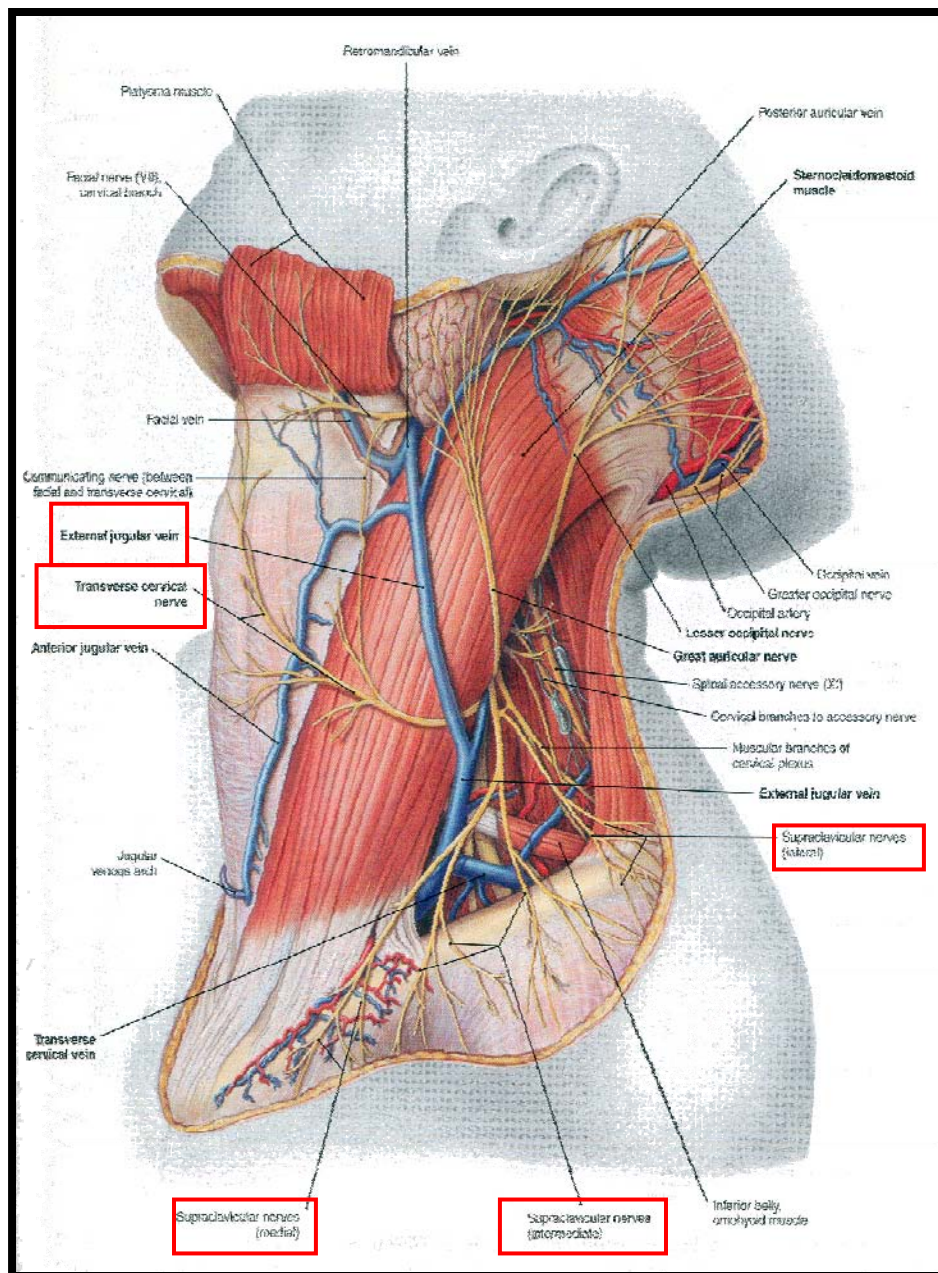


Figure 16: Illustration of the transverse cervical nerve (Adapted from Clemete, 2006)

The ascending branch of the transverse cervical nerve, pass upwards to the submandibular region and forms an anastomosis with the cervical branch of the facial nerve (Standring *et al.*, 2008) (Figure 17). This anastomosis was termed superficial ansa cervicalis by Thumfart *et al.*, (1999).

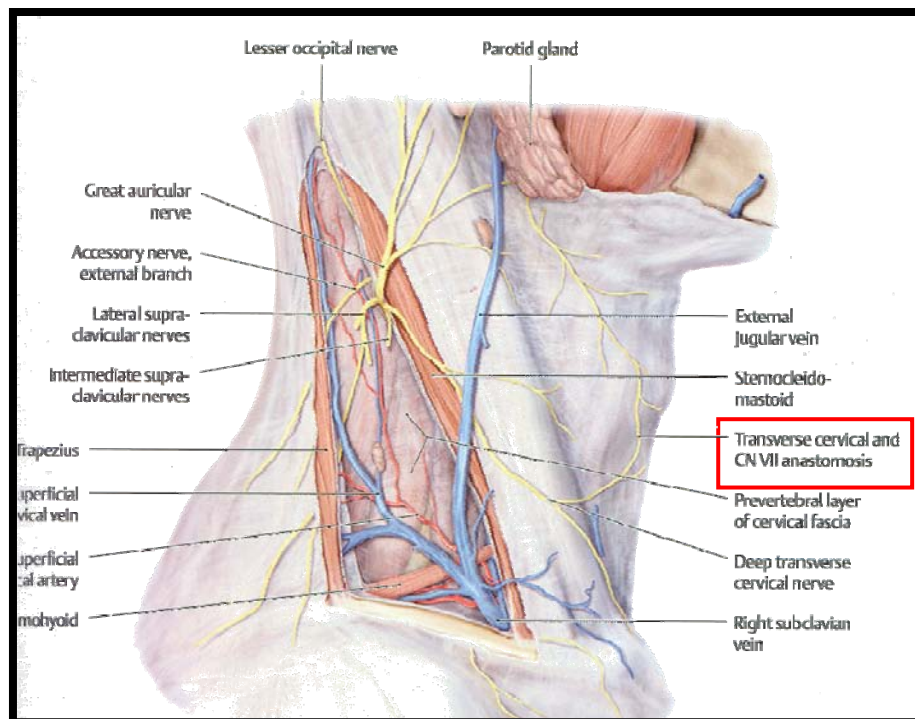


Figure 17: *Anastomosis between transverse cervical nerve and cervical branch of facial (Adapted from Clemente, 2007)*

Domet *et al.* (2005) stated that during surgical procedures of the submandibular triangle a communicating branch was found passing inferiorly on the submandibular gland: this communication is the anastomosis between the transverse cervical nerve and cervical branch of facial nerve in the vicinity of the submandibular gland.

2.3.4 SUPRACLAVICULAR NERVES

Classical anatomical textbooks described the supraclavicular nerves as the superficial descending branches that arise from a loop between the ventral rami of the third and fourth cervical nerves emerging at the posterior border of the sternocleidomastoid muscle (Hollinshead, 1974; Ellis and Fieldman, 1993; Standring *et al.*, 2008) (please see figure 16, P27).

Hovelacque (1927) reported that the supraclavicular nerve divides into three branches viz: medial or suprasternal; intermediate and; lateral or supra-acromial. Standard anatomical textbooks describe the supraclavicular nerve as it descends under the platysma muscle and deep cervical fascia, dividing into medial, intermediate and lateral branches, which diverge to perforate the deep fascia above the clavicle (Hollinshead, 1974; Standring *et al.*, 2008) (Figure 18).

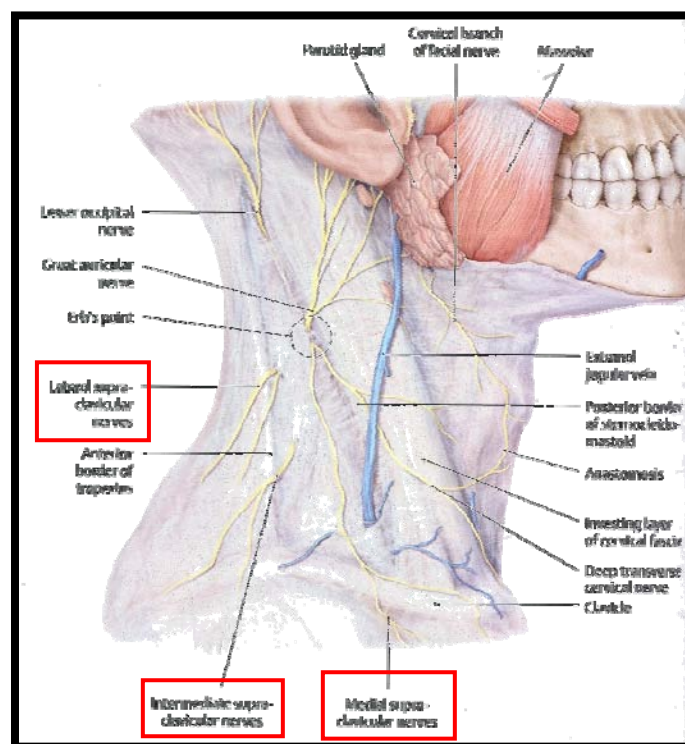


Figure 18: Illustration of the branches of the supraclavicular nerves
(Adapted from Clemente, 2007)

The medial supraclavicular nerve runs infero-medially across the external jugular vein and clavicular and sternal heads of the sternocleidomastoid muscle to innervate skin over the anterior part of the clavicle and as far down as the second rib including the sternoclavicular joint (Hollinshead, 1974; Standring *et al.*, 2008). The intermediate supraclavicular nerve emerges beneath the posterior border of the sternocleidomastoid muscle, descends antero-inferiorly crossing the clavicle innervating the skin over pectoralis major and deltoid muscles down to the level of the second rib, next to the region supplied by the second thoracic nerve; however, overlap between these nerves is minimal. The lateral supraclavicular nerve descends superficially across the acromial process, crossing the anterior border of the trapezius muscle, dividing into several smaller branches that supply the skin of the upper and posterior parts of the shoulder (Havet *et al.*, 2007; Standring *et al.*, 2008).

In a study conducted by Havet *et al.* (2007), it was found that the intermediate and lateral branches arose from a common trunk behind the sternocleidomastoid muscle and the intermediate branch divided into two or three smaller branches which concurred with the findings by Paturet (1964).

2.4 ANATOMY OF THE DEEP CERVICAL PLEXUS

The deep cervical plexus forms in the paravertebral region of the second, third and fourth cervical vertebrae, arising between the anterior scalene and middle scalene muscles (Miller, 1995). The ventral ramus of the second and third cervical nerves emerges between the longus capitus and scalenus medius muscles. At the lateral edge of scalenus medius muscle there is a strong loop connecting the ventral ramus of the third and fourth cervical nerves. The fourth cervical nerve emerges beneath the lateral edge of scalenus anterior muscle at the level of the upper border of thyroid cartilage, lying on the scalenus medius muscle (Tobias and Arnold, 1999). Standring *et al.*, (2008) classified the muscular branches of the deep cervical plexus into a medial and lateral series (Figure 19).

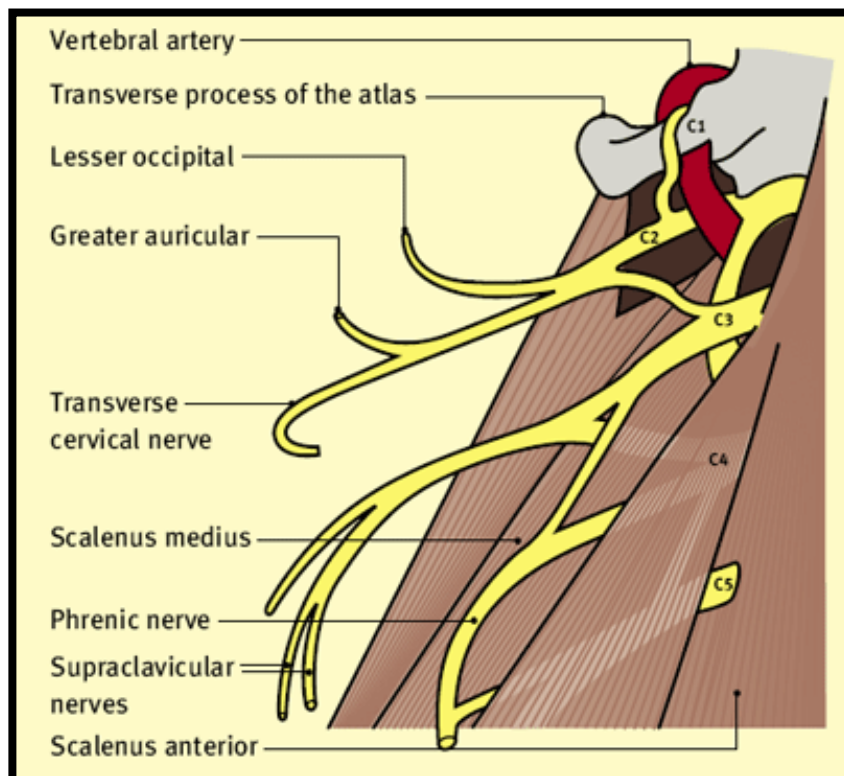


Figure 19: Schematic illustration of the roots, and loops of the cervical plexus
(Adapted from Craven, 2003)

2.4.1 MEDIAL SERIES

The muscular branches arising from the medial series innervate the anterior vertebral muscles which are rectus capitus anterior [supplied by the ventral rami of C1 and C2] (Figure 20), rectus capitis lateralis [supplied by the ventral rami of C1] (Figure 21), longus capitus [supplied by the ventral rami of C1-C3] (Figure 22) and longus colli [supplied by the ventral rami of C2-C4] (Figure 23). Additional branches include the inferior root of ansa cervicalis and the phrenic nerve (Tobias and Arnold, 1999; Standing *et al.*, 2008).

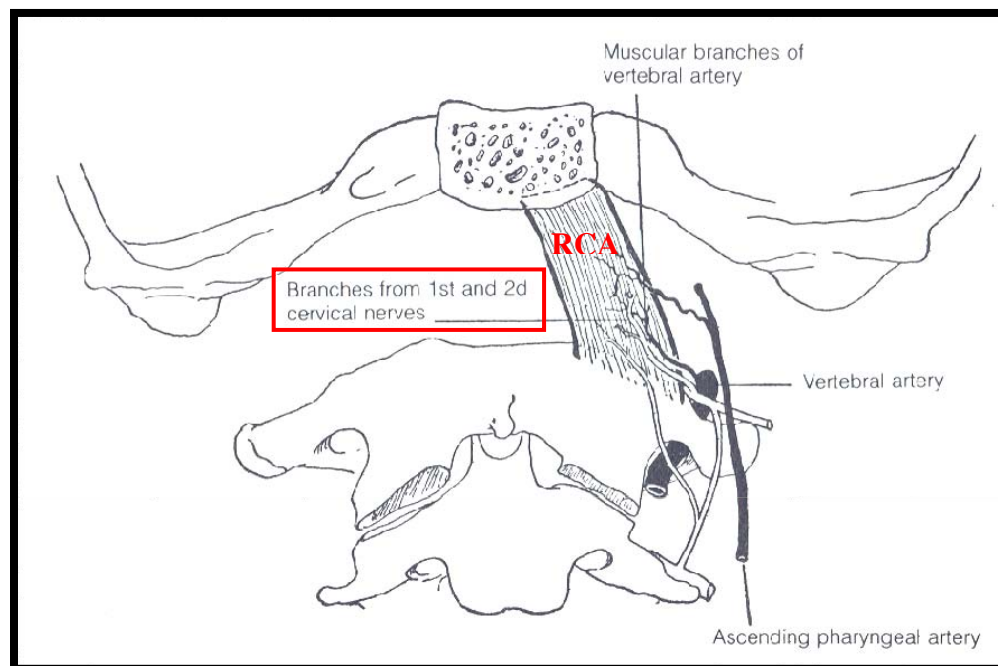


Figure 20: Muscular branches to Rectus capitis anterior (RCA) (Adapted from Warfel, 1985)

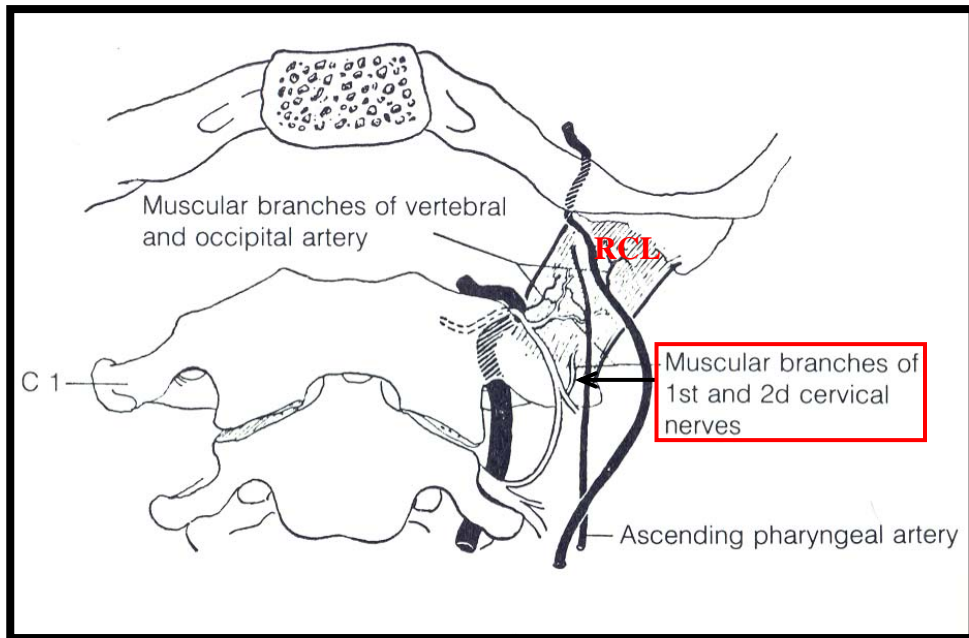


Figure 21: Muscular branches to Rectus capitis lateralis (RCL) (Adapted from Warfel, 1985)

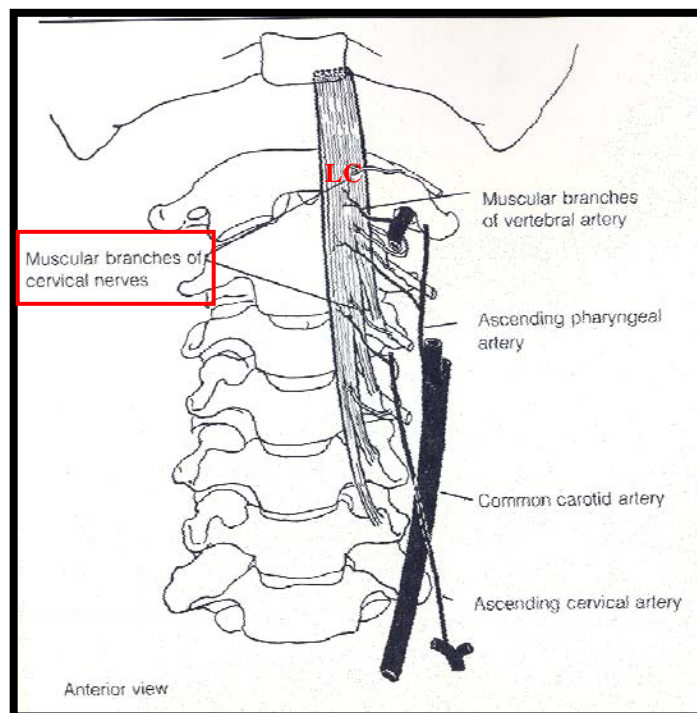


Figure 22: Muscular branches to Longus capitis (LC) (Adapted from Warfel, 1985)

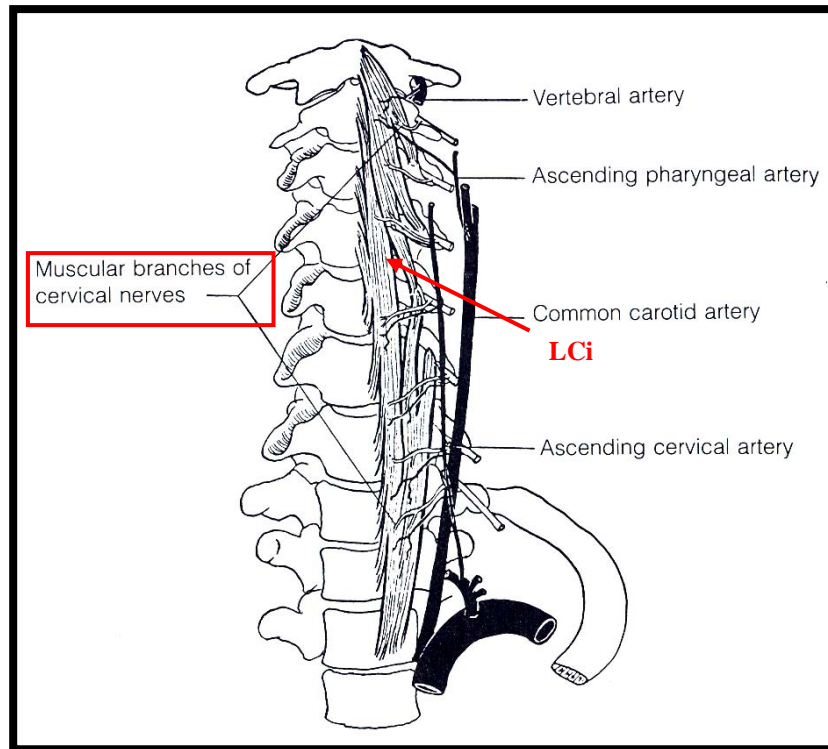


Figure 23: Muscular branches to Longus colli (LCi) (Adapted from Warfel, 1985)

2.4.2 LATERAL SERIES

The muscular branches arising from the lateral series supplies the sternocleidomastoid muscle (supplied by the ventral ramus of C2,3,4), trapezius (supplied by the ventral rami of C2 and possibly C3), levator scapulae (supplied by the ventral rami of C3 and C4) and scalenus medius (supplied by the ventral rami of C3 and C4). The branches to trapezius cross the posterior triangle obliquely below the accessory nerve (Stranding *et al.*, 2008) (Figure 24). According to Tobias and Arnold (1999) the fibres to the sternocleidomastoid muscle are “believed to be sensory only” and those to trapezius are “probably” sensory and motor to the lower end of the muscle.

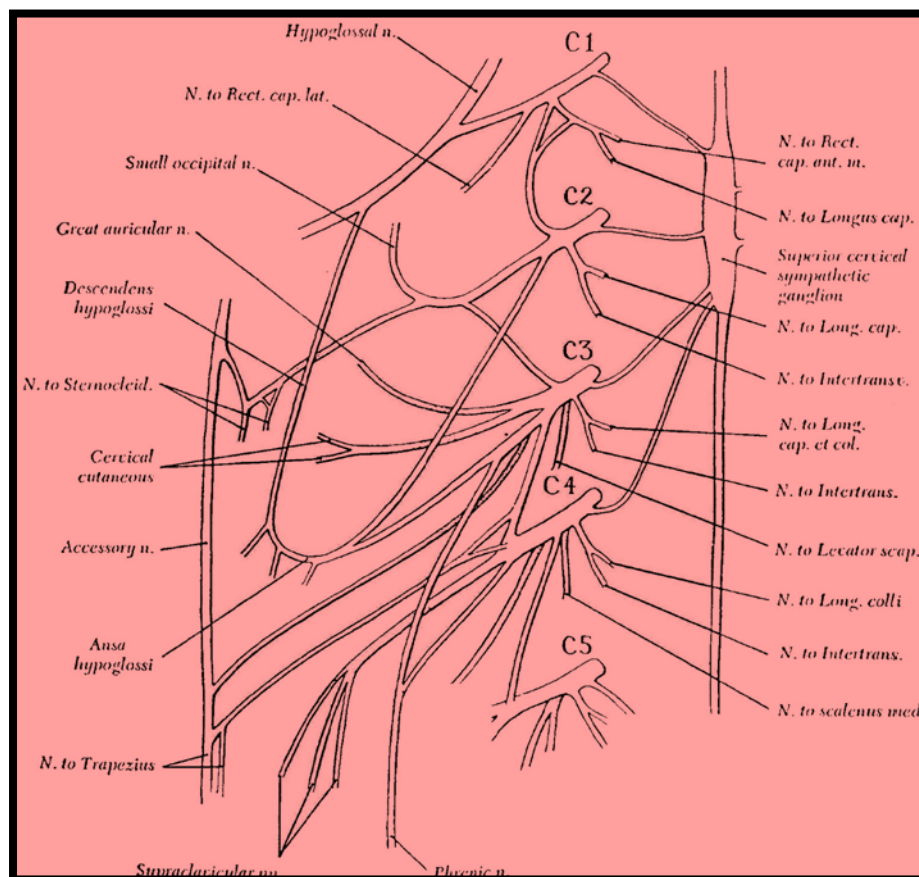


Figure 24: Schematic illustration of the branches of the deep cervical plexus
(Adapted from Stranding *et al.*, 2008)

2.5 ANSA CERVICALIS

The formation of the ansa cervicalis is relatively complex and its course and location along the common carotid artery and internal jugular vein vary (Chhetri and Berke, 1997). The superior root of the ansa cervicalis is classically described as a long slender branch. As the hypoglossal nerve curves around the occipital artery, the superior root leaves it and descends on the anterior wall of the carotid sheath, lateral to the internal jugular vein. At the midline of the neck it crosses the internal jugular vein continuing forward to join the inferior root of the ansa cervicalis, anterior to the carotid artery (Vollala *et al.*, 2005; Standring *et al.*, 2008) (Figure 25). At its origin, the superior root lies medial to the posterior belly of the digastric muscle and lateral to the internal and external carotid arteries (Kuniak and Klacansky, 1982) (Figure 26).

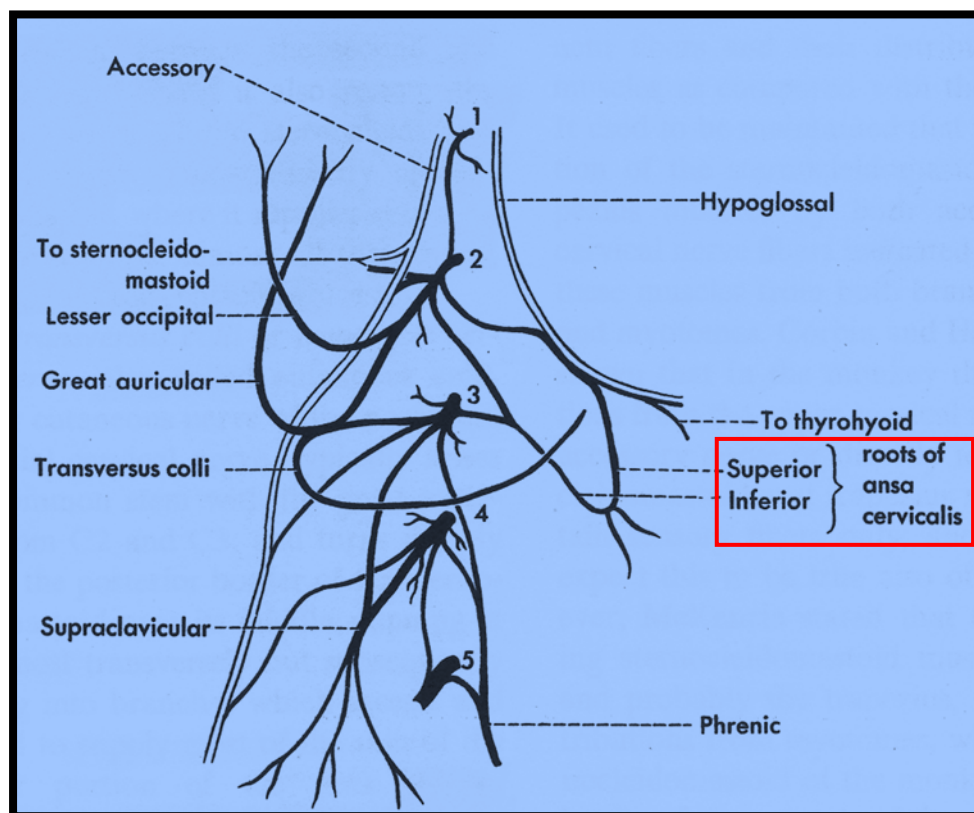


Figure 25: Superior and inferior roots of ansa cervicalis (Adapted from Standring *et al.*, 2008)

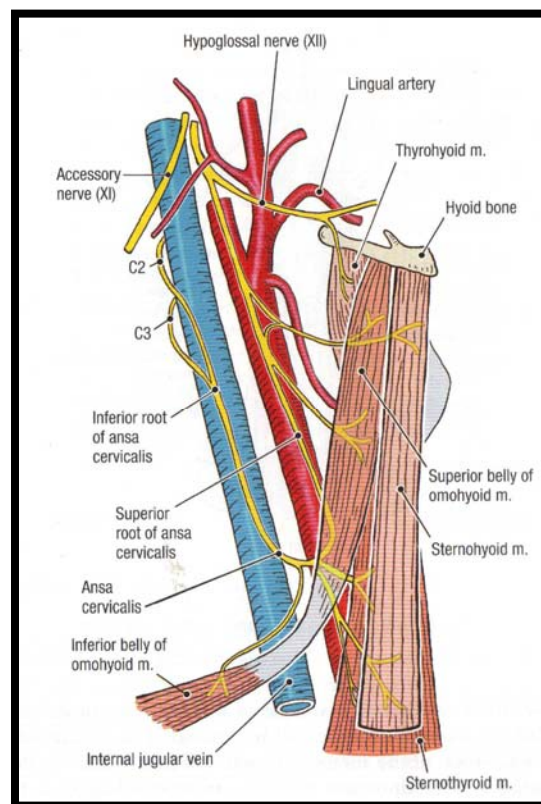


Figure 26: Relation of the ansa cervicalis to the internal jugular vein and carotid artery
(Adapted from Grants 2005)

The inferior root most frequently arises from the ventral rami of the second and third cervical nerves. In addition, the ventral rami of the first and fourth cervical nerve may also contribute to the formation of the inferior root (Poiviraev and Chernikov, 1967). According to the study conducted by Caliot and Dumont (1983), the ventral ramus of the third cervical nerve was the most frequent contributor to the inferior root. The results obtained by Loukas *et al.*, (2007) concurred with the latter finding (Figure 27).

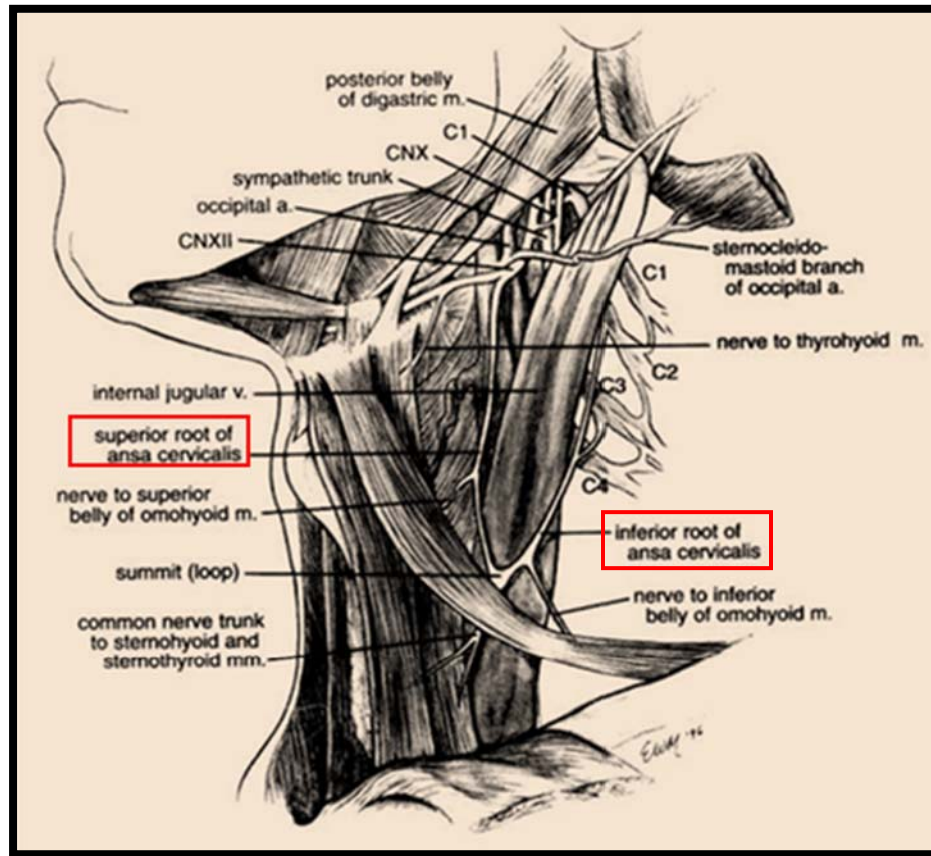


Figure 27: Regional anatomy of the ansa cervicalis (Adapted from Chhetri and Berke, 1997)

The term “ansa” was originally used to describe the looped portion of the nerve; however now it is applied to the superior and inferior roots as well as the loop (Bannehaka, 2008).

The anastomosis between the hypoglossal nerve and the cervical plexus has been described by various anatomists over the years as either ansa cervicalis or ansa hypoglossi (Ellis and Fieldman, 1993; Standring *et al.*, 2008; Banneheka, 2008). Olry and Haines (2002) described the ansa cervicalis as being formed by the ventral rami of the first and second cervical nerves only.

Standring *et al.*, (2008) states that the ansa cervicalis lies anterior to the internal jugular vein; however it has been reported by Kikuchi (1970) to lie medial to the vein. Yamada (1965) classified these relations into lateral and medial categories (Figure 28a; b). According to the study conducted by Banneheka (2008), when the inferior root had two or more branches that joined the superior root and at least one branch crossed the internal jugular vein laterally and the other medially, this arrangement is known as a mixed type of ansa cervicalis (Figure 28c).

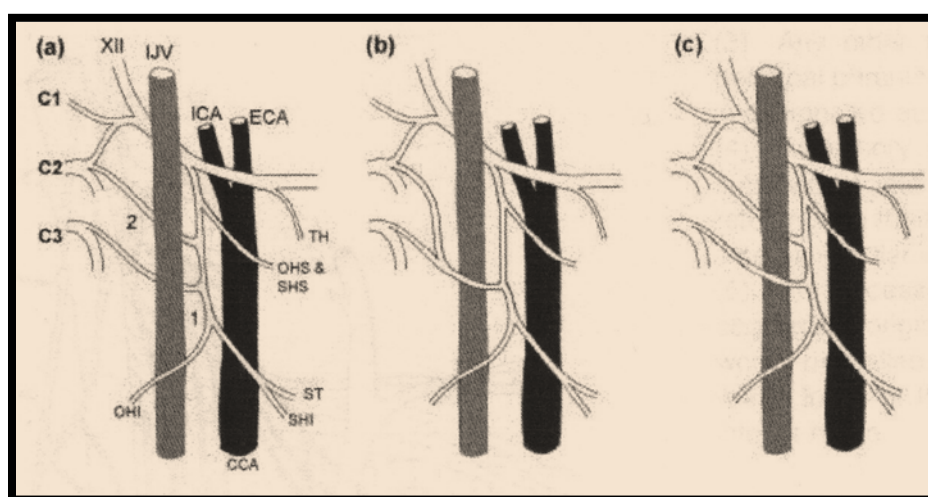


Figure 28: *Classification of the types of ansa cervicalis*
 (a) Medial type: posterior to IJV; (b) Lateral type: anterior to IJV; (c) Mixed type: upper branch of inferior root passes posterior to IJV while the lower passes below it
 (Adapted from Banneheka, 2008)

Key: XII – Hypoglossal nerve, IJV – Internal jugular vein, CCA – Common carotid artery, ICA – Internal carotid artery, ECA – External carotid artery, TH – branch to thyrohyoid muscle, OHI – branch to inferior belly of omohyoid muscle, OHS – branch to superior belly of omohyoid muscle, C1-3 – cervical ventral ramus of first, second and third nerves, SHS – branch to sternohyoid superior muscle, SHI – branch to sternohyoid inferior muscle, ST - branch to sternothyroid muscle

Previously, several authors have reported ansa-vagal communications and named this segment the vago-cervical complex (Kikuchi, 1970; Rath and Anand, 1994; Chhetri and Berke, 1997; Indrasingh and Vettivel, 2000; Verma *et al.*, 2005). Furthermore, Indrasingh and Vettivel (2000) state that if the superior and inferior roots are derived from the superior cervical ganglion and vagus nerve, a “pseudo ansa cervicalis” should be considered.

According to Chhetri and Berke (1997), the morphological variations of the ansa cervicalis that exist are as follows:

- (a) the inferior root, resulting from various cervical root combinations, although it is agreed that ventral rami of the second and third cervical nerves contribute most frequently and the ventral rami of the first and fourth cervical nerves less frequently;
- (b) the length of the loop in relation to the omohyoid muscle viz. (i) long ansa cervicalis is found when the loop is located inferior to the omohyoid muscle, and (ii) short ansa cervicalis when the loop is located superior to the omohyoid muscle (Hollinshead, 1974; Clemente, 2007) (Figure 29).
- (c) variation in the innervation pattern to the infrahyoid muscles: a report by Abu-Hijleh (2005) described the absence of ansa cervicalis, creating a potential rare third variation.

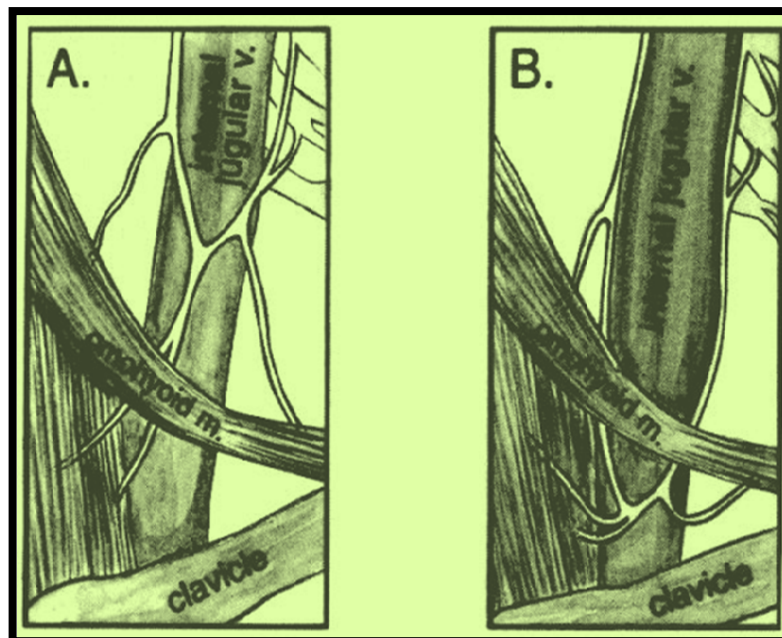


Figure 29: Variations in the location of the loop of the ansa cervicalis
(Adapted from Chhetri and Berke, 1997)

With the use of a combination of the variations that include the inferior loop and the length of the omohyoid muscle, Caliot and Dumont (1983) described the seven morphological variations (from their 80 observations) with regard to the formation of the ansa cervicalis (Figure 30) viz:

- A: Double classic form (40%);
- B: Simple classic form (27%);
- C: Double form with two separate roots (11%),
- D: Triple form (9%);
- E: Double short form (8%);
- F: Quadruple form (1%); and
- G: Single short form (1%)

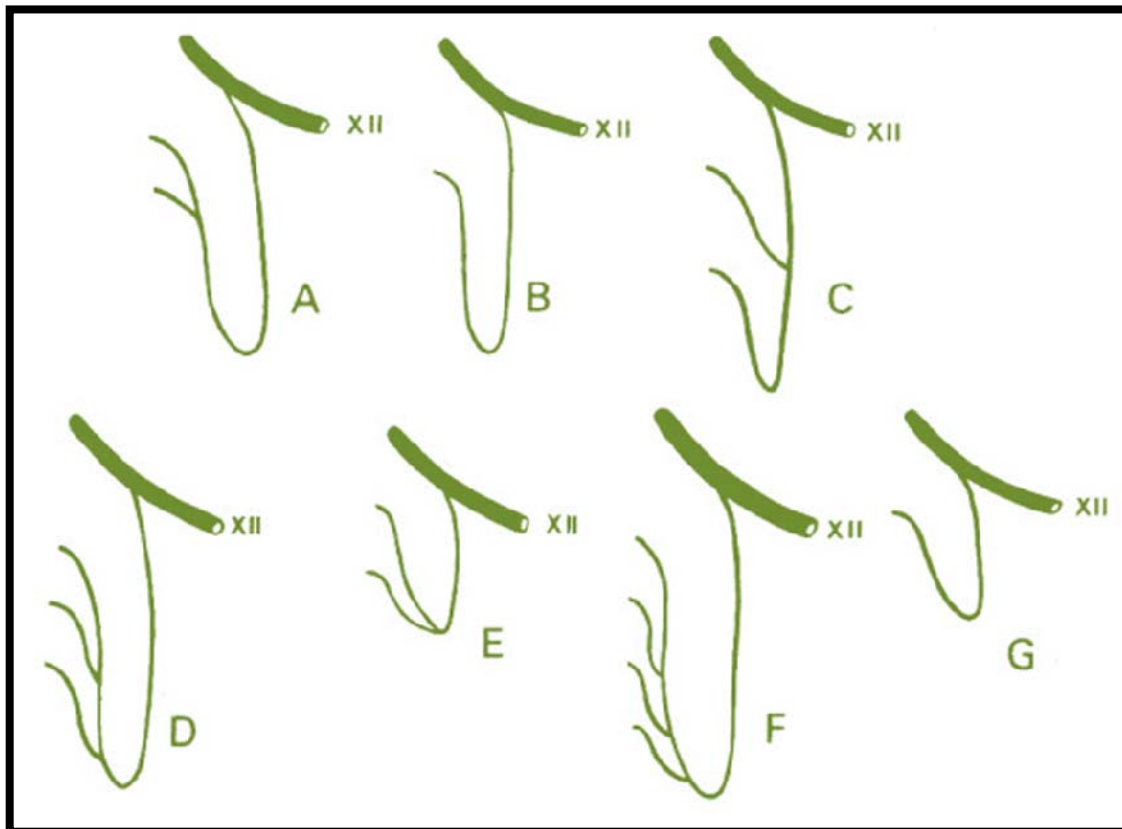


Figure 30: Seven morphologic forms of the ansa cervicalis nerve formation
(Adapted from Caliot and Dumont, 1983; cited by Chhetri and Berke, 1997)

2.6 PHRENIC NERVE

The most significant contribution to the phrenic nerve arises from the ventral ramus of the fourth cervical nerve with contributions from the ventral rami of the third and fifth cervical nerve (Standring *et al.*, 2008).

Each phrenic nerve is formed at the superior part of the lateral border of the anterior scalene muscle at the level of the superior border of the thyroid cartilage, and descends almost vertically across its anterior surface behind the prevertebral fascia.

As it descends on scalenus medius, it lies posterior to the internal jugular vein, sternocleidomastoid, and inferior belly of omohyoid muscles, transverse cervical and suprascapular arteries and on the left, the thoracic duct (Ellis and Fieldman, 1993; Standring *et al.*, 2008). At the root of the neck it passes anterior to the first part of the subclavian artery and posterior to the subclavian vein to enter the thorax (Bannekha, 2005; Standring, 2008) (Figure 31).

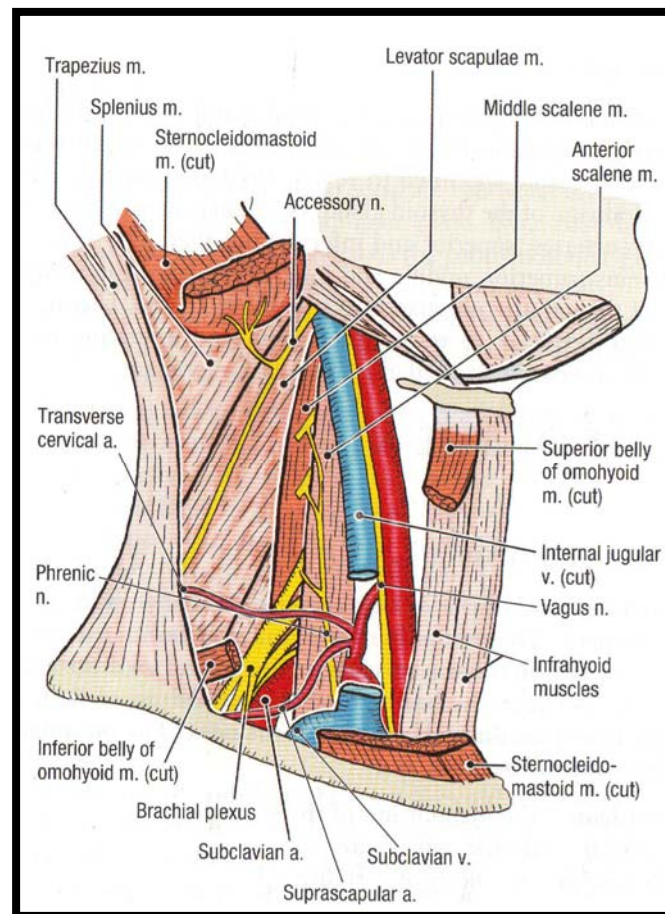


Figure 31: Course of the Phrenic nerve in the neck (Adapted from Tank, 2005)

Posteriorly, it crosses the internal thoracic artery from lateral to medial sides to enter the neck (Ellis and Fieldman, 1993). In the neck, there are connections formed between the phrenic and the cervical sympathetic ganglia and it communicates with the spinal accessory nerve. It contains motor, sensory and sympathetic fibres and provides sole motor innervation to the diaphragm and sensation to its central part. In the thorax, each phrenic nerve supplies the mediastinal pleura and pericardium (Standring *et al.*, 2008).

Madhyastha and Bhat, (2008) observed that the phrenic nerve arose from the supraclavicular nerve, deep to sternocleidomastoid, above the superior trunk of the brachial plexus. Bigeleisen (2003) stated that the phrenic nerve may arise completely

from the brachial plexus therefore blocks of the phrenic nerve may sometimes be ineffective.

Cramer and Darby, (1995) suggested the presence of an occasional phrenic nerve arising from the ventral rami of the fifth and sixth cervical nerves which they termed as the accessory phrenic nerve. The nerve to subclavius has been identified as a major contributor to the accessory phrenic nerve by many authors (Caliot and Dumont, 1983; Moore, 1992; Standring 2008). In 1970 Kikuchi, suggested that super-numerary nerves that are separated from the main trunk of the phrenic nerve by the subclavian vein may be called the “accessory phrenic nerve”.

2.7 COMMUNICATING BRANCHES

There is considerable variability between communications of the cranial nerves and the cervical plexus. Communicating branches pass from the loop between the ventral rami of the first and second cervical nerves to the hypoglossal nerve (Figure 32) and the vagus nerve.

In addition, each cervical ventral ramus receives a grey ramus communicans from the cervical sympathetic ganglion (Venkata *et al.*, 2005).

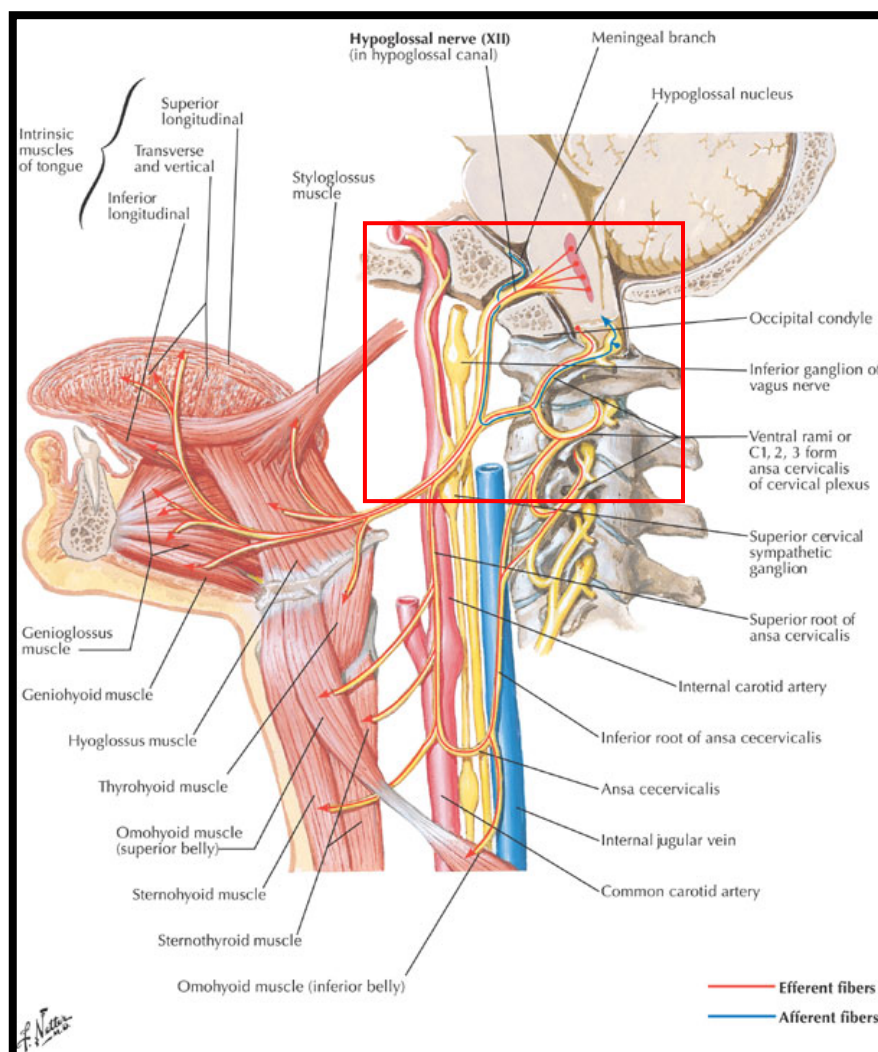


Figure 32: Communications of the cervical plexus with the hypoglossal nerve
(Adapted from Netter, 1995)

Abu-Hijleh (2005) also suggested that the cervical plexus communicates with the accessory nerve (Figure 33).

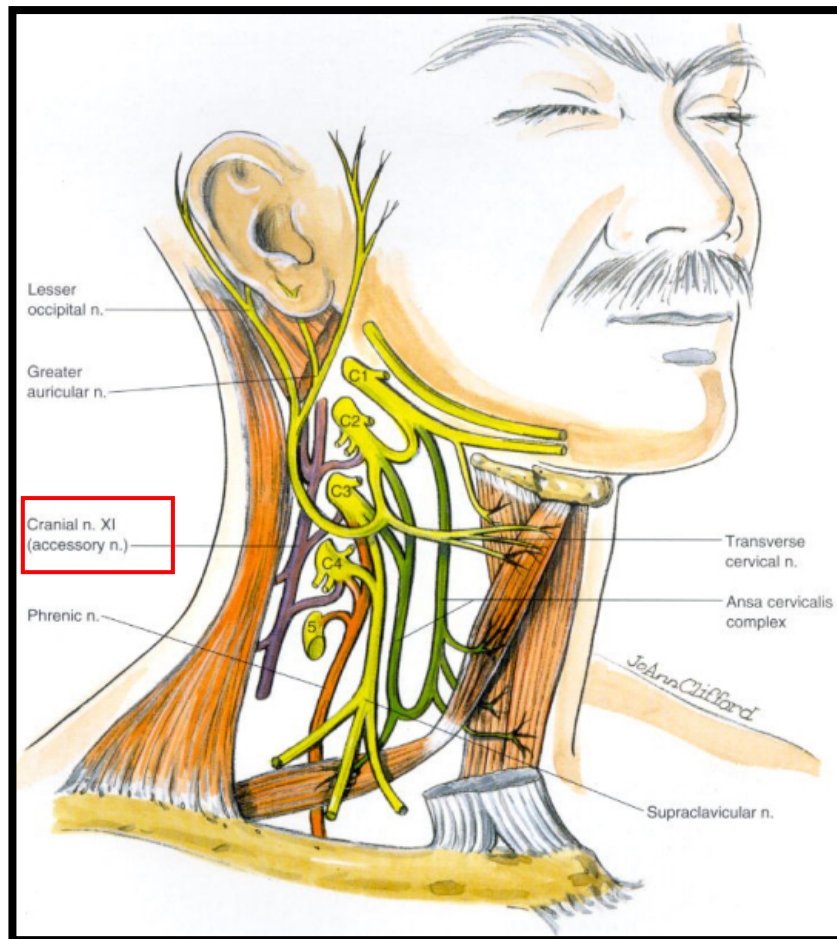


Figure 33: Communications of the cervical plexus with Accessory nerve
(Adapted from Brown , (2006)

2.7.1 Sympathetic Chain: Superior Cervical Ganglion

The superior cervical ganglion is described as a large, fusiform ganglion that usually lies at the level of the second and third cervical vertebrae, under cover of the posterior belly of the digastric muscle (Potts, 1925). In 1928, Axford presented the arrangements of the grey rami communicantes of the superior cervical ganglion to the cervical plexus (Figure 34). He reported that the grey rami to these nerves arose from the superior cervical ganglion on its lateral or anterior aspect as three branches as follows:

- 1) Uppermost ramus: joins the ventral ramus of the first cervical nerve or the loop between first and second cervical nerve;
- 2) Middle ramus: joins the ventral ramus of the second cervical nerve of the loop between second and third cervical nerves;
- 3) Lowest ramus: joins the ventral rami of the third cervical nerve or the loop between the ventral rami of the third and fourth cervical nerves.

Variations in the communications of the superior cervical ganglion and cervical plexus have been reported by Axford (1928) and Hoffman (1957) (Figure 35).

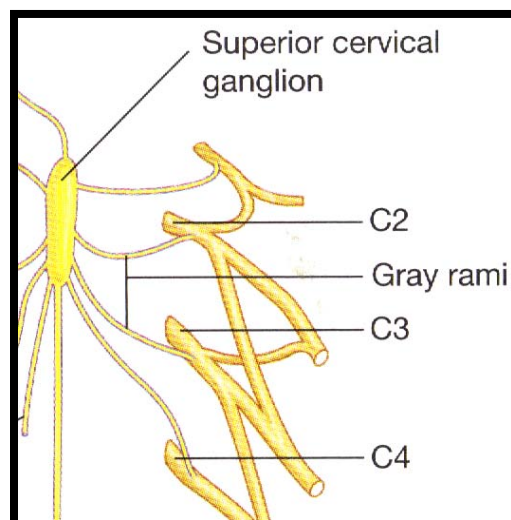


Figure 34: Superior cervical ganglion communication with upper four cervical nerves
(Adapted from Drake et al., 2010)

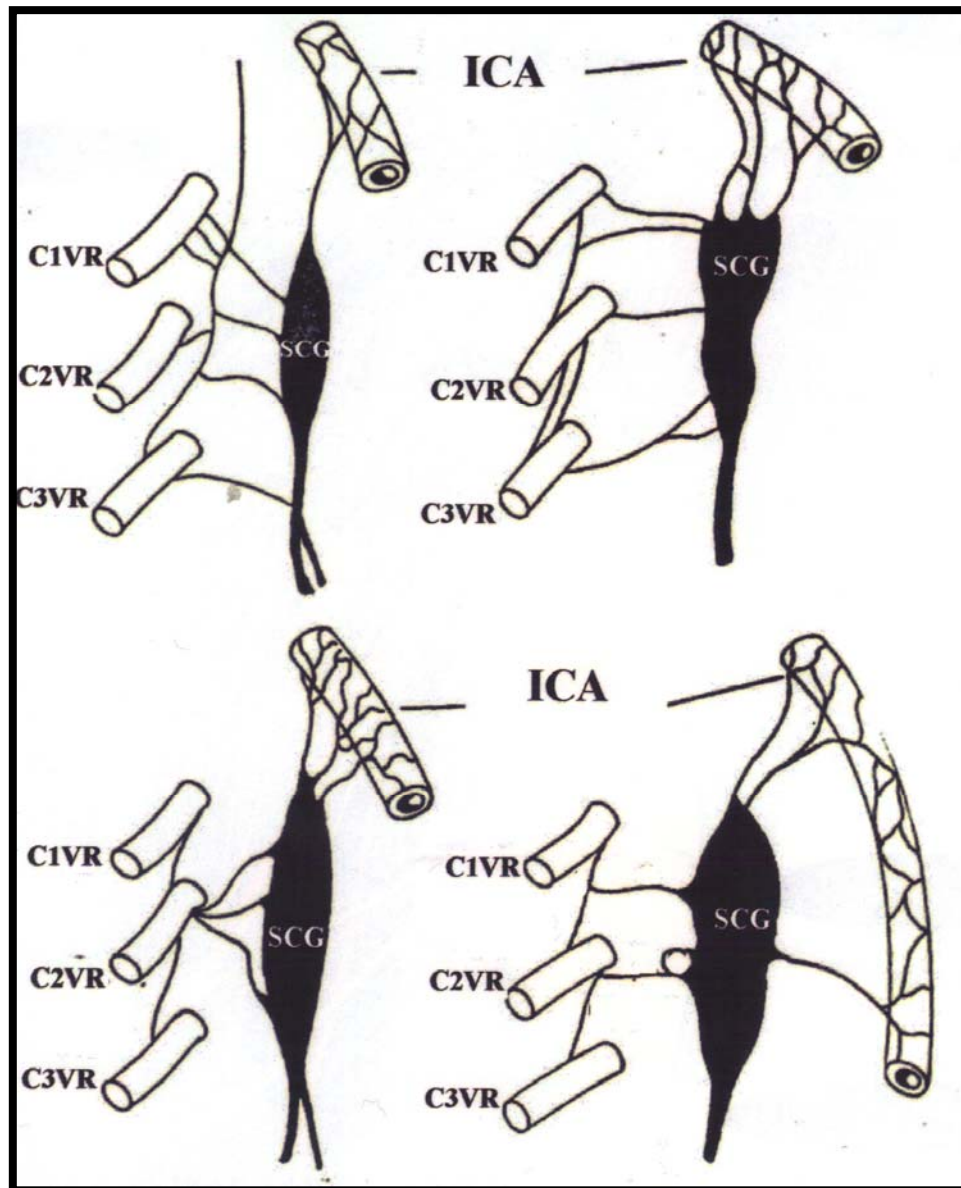


Figure 35: Variations in the communications between cervical nerves and superior cervical ganglion (Adapted from Axford, 1928)

Key: C1VR – ventral ramus of first cervical nerve, C2VR – ventral ramus of second cervical nerve, C3VR – ventral ramus of third cervical nerve, ICA – Internal carotid artery, SCG – Superior cervical ganglion

2.8 RELATIONS OF THE CERVICAL PLEXUS

2.8.1 EXTERNAL JUGULAR VEIN

The external jugular vein begins at the angle of the mandible, below the apex of the parotid gland and runs vertically down in the superficial fascia to a point just above the midpoint of the clavicle (Nayak and Soumya, 2008) (Figure 36). In its course it is closely related to the great auricular, transverse cervical and medial supraclavicular nerves: the great auricular nerve has been reported to lie parallel and posterior to the external jugular vein (McKinney and Katrana, 1980), either superior and inferior (Thumfart *et al.*, 1999) or posterior to it in the upper third (Jamieson, 2006); the transverse cervical nerve lies deep or posterior to external jugular vein (Strandring *et al.*, 2008); and the medial branch of supraclavicular nerve runs infero-medially across the external jugular vein (Hollinshead, 1974; Strandring *et al.*, 2008)

2.8.2 STERNOCLEIDOMASTOID MUSCLE

The branches of the superficial cervical plexus are closely related to the sternocleidomastoid muscle: these branches emerge from beneath the posterior border to lie either anterior, inferior or lateral (Strandring *et al.*, 2008). The great auricular and transverse cervical nerves cross the anterior border of the sternocleidomastoid muscle (Ellis and Fieldman, 1993); the lesser occipital nerve ascends along the lateral border of the muscle to reach the occiput and occipital region (Thumfart *et al.*, 1999) and the supraclavicular nerve descends inferior to the muscle towards the clavicle and deltoid region (Strandring *et al.*, 2008) (please see Figure 8 on page 13).

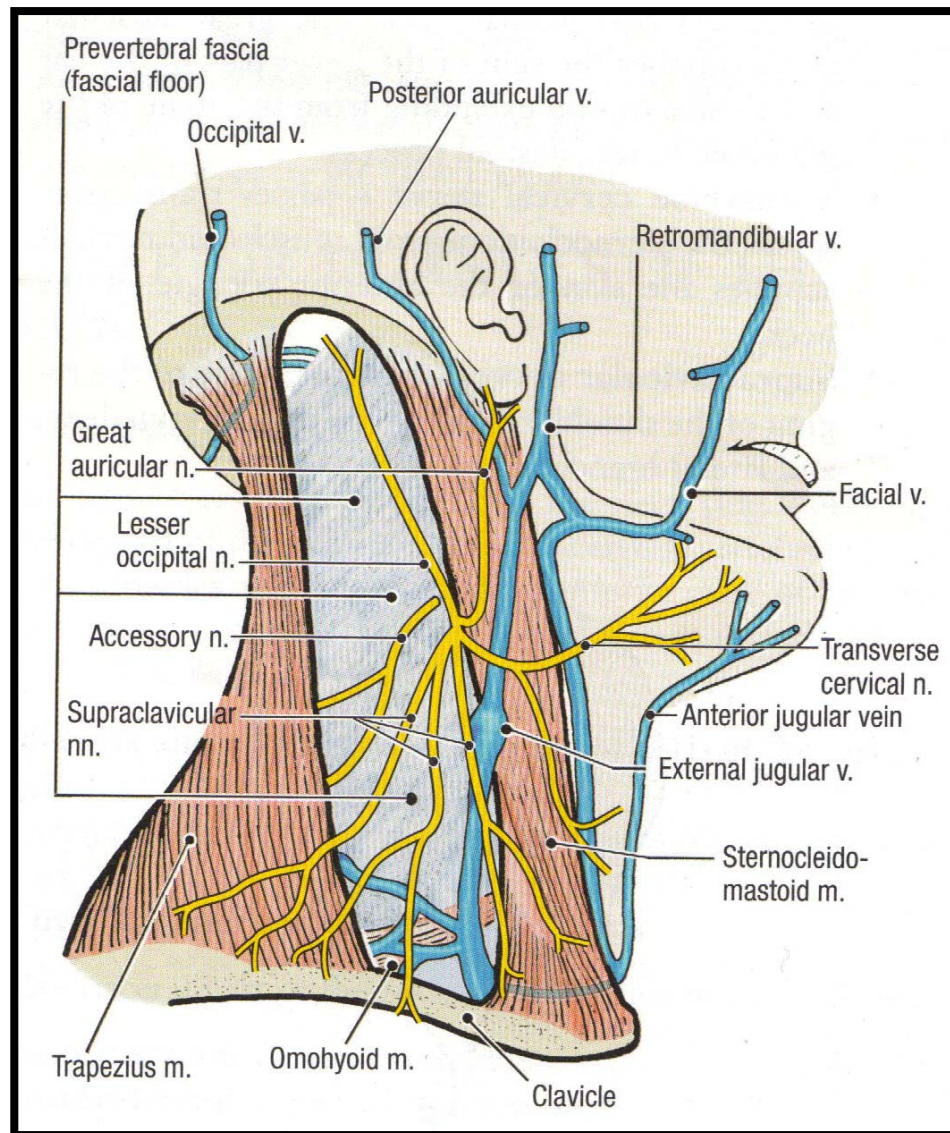


Figure 36: Left anterior view of the external jugular vein
(Adapted from Tank, 2005)

2.8.3 INTERNAL JUGULAR VEIN

The inferior root of ansa cervicalis passes at first posteriorly and then laterally to the internal jugular vein and anastomoses with the superior root anterior to the carotid sheath. Occasionally, the superior and inferior roots of the ansa cervicalis meet over the lateral side of the internal jugular vein (Bademci and Yaşargi, 2006) (Figure 37).

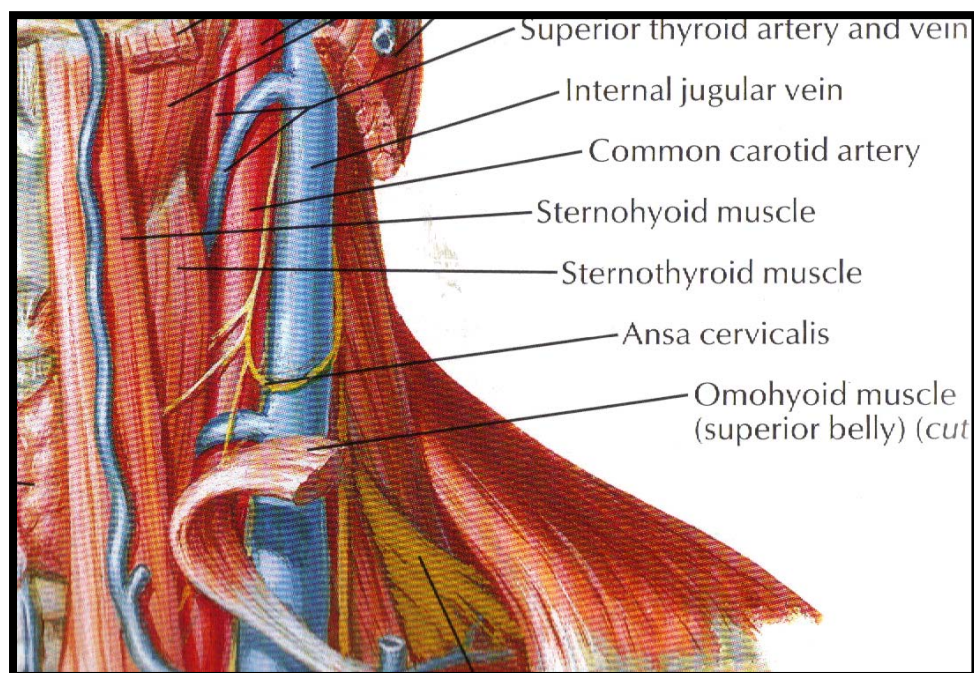


Figure 37: *Relation of the internal jugular vein to ansa cervicalis*
(Adapted from Netters, 1995)

2.8.4 COMMON CAROTID ARTERY

The bifurcation of the common carotid artery into internal and external branches occurs between third and fourth cervical vertebrae (Standring *et al.*, 1998). The superior root of ansa cervicalis is located lateral to the internal and external carotid arteries: it descends at an angle and medially on the internal carotid artery, then on the common carotid artery, either in front of or within the carotid sheath (Chhetri and Berke, 1997). There is also an important ‘cross’ between the occipital artery and the hypoglossal nerve (Bejjani *et al.*, 1998).

2.9 CLINICAL IMPORTANCE: REGIONAL ANAESTHESIA

a) CERVICAL PLEXUS BLOCKS

Regional anesthetic blockade of the cervical plexus is an increasingly available alternative for surgery of the neck, (Yerzingatsian, 1989; Davies *et al.*, 1997; Santamaria *et al.*, 2004; Suresh and Templeton, 2004), eg. thyroid surgery (Aunac *et al.*, 2002) and particularly for carotid endarterectomy (Stoneham and Wakefield, 1998; Knighton and Stoneham, 2000) because of the possible overall lower incidence of morbidity and mortality. This technique involves the anesthetic blockade of the ventral rami of second to fourth cervical nerves, performed using superficial cervical plexus block or a combination of superficial and deep cervical plexus blocks (Panditt *et al.*, 2000). It is an effective form of anaesthesia used during carotid endarterectomy (Stoneham and Wakefield, 1998 and Pandit *et al.*, 2000).

b) SUPERFICIAL CERVICAL PLEXUS BLOCK

The classic technique of superficial cervical plexus block is a local anesthetic injection in the subcutaneous plane along the posterior border of the sternocleidomastoid muscle in the cranial and caudal direction in order to block lesser occipital, transverse cervical, great auricular and supraclavicular nerves (Figure 38) (Stoneham and Wakefield, 1998; Nash *et al.*, 2005). Also, some investigators suggest placing the superficial cervical plexus block under the investing layer of cervical fascia. Previously, authors have also suggested placing the superficial cervical plexus block under the investing fascia (Stoneham and Wakefield, 1998; de Sousa *et al.*, 2005). The major structure in immediate proximity to an advancing needle in this block is the external jugular vein (Phillip, 1999)

It is suggested that the superficial cervical plexus block is easier to perform, easier to teach, and is associated with fewer potential complications, and it is as effective as the deep or combined block (Panditt *et al.*, 2000).

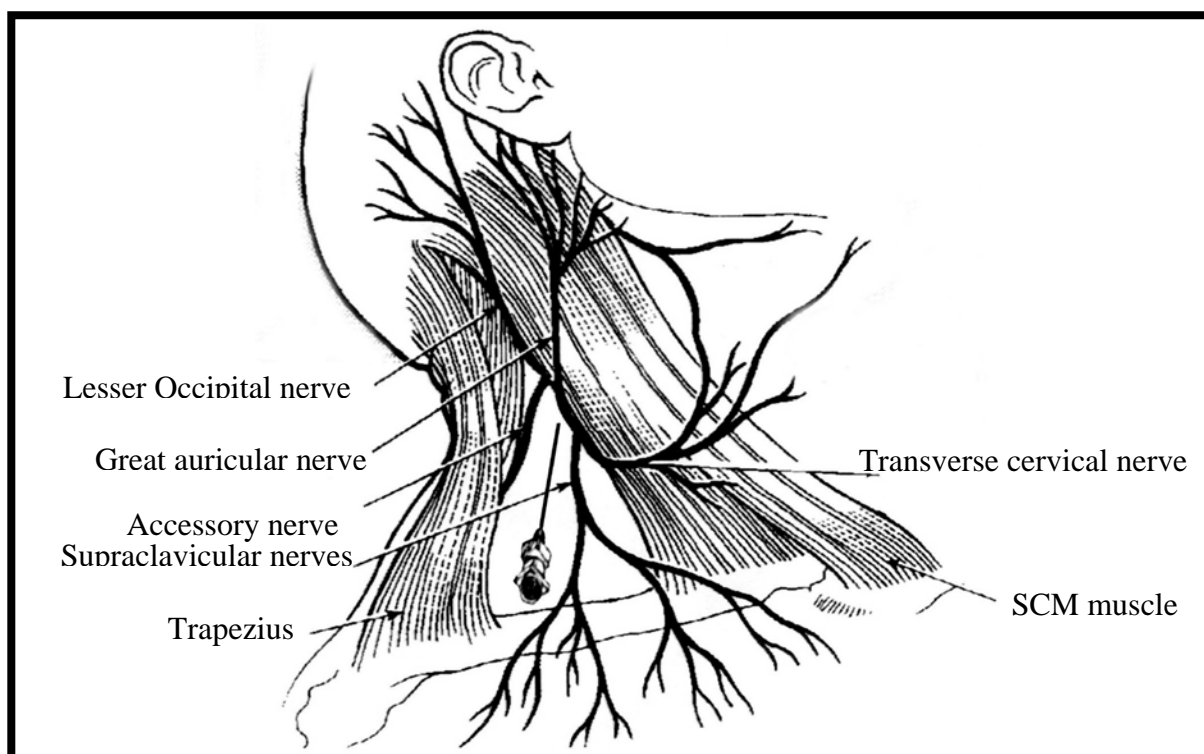


Figure 38: *Superficial cervical plexus block illustrating needle position*
(Adapted from Cousins, 1988)

c) DEEP CERVICAL PLEXUS BLOCK

Deep cervical plexus blocks require identification of the ventral rami of the second, third and fourth cervical nerve roots on the same side as the surgical field (Bonnett, 1990). This block has several major structures in its immediate proximity to an advancing needle, including the vertebral artery, dural cuffs, sympathetic chain, phrenic nerve, common carotid artery, and internal jugular vein (Phillip, 1999). Anesthesia of the deep cervical plexus is a paravertebral block: it can be accomplished by placing the needle in

the appropriate plane adjacent to the transverse processes of C₂ to C₄ vertebrae. Various techniques have been described to provide anesthesia of the deep cervical plexus, including a single injection at C₃ or three separate injections at the C₂, C₃, and C₄, vertebral levels, or a modified approach with an interscalene injection with distal pressure to encourage upward movement of the local anesthetic solution (Winnie *et al.*, 1975; Tobias, 1999). Tobias (1999) preferred a single injection at the C₃ vertebral level because the nerve roots are contained in a fascial plane, and they considered a single injection sufficient, with spread of the local anesthetic solution in the fascial plane to surround the branches of ventral rami of the second, third and fourth cervical nerves.

3.1 GROSS ANATOMICAL DISSECTION

Forty fetuses (gestational age of approximately 15 to 28 weeks) and fifteen adult cadavers were obtained from the Department of Clinical Anatomy, University of KwaZulu-Natal (Westville and Nelson Mandela School of Medicine campuses) in accordance with the National Health Act 61 of 2003. Ethical Clearance No: BF 156/07

3.1.1 SELECTION CRITERIA

Inclusion criteria: Fetuses and adult cadavers with the neck region that was normal and free of overt pathology were included in the study.

Exclusion criteria: Fetuses and adult cadavers with signs of injuries, trauma or pathology in the lateral and posterior compartments of the neck were excluded from the study.

3.1.2 DISSECTION PROCEDURE

Standard macro and micro-dissecting instruments were utilized.

Superficial Dissection: To expose the superficial cervical plexus

Anatomical dissection of the posterior triangle of the neck and deep microdissection of the prevertebral space was performed on fetal and adult cadaveric specimens. A skin incision was first made from the mastoid process to the lateral end of the clavicle. The second incision was made from the medial end of the clavicle to a point 3cm lateral to acromion of the scapula (Figure 39a). The skin was then reflected anteriorly as far as the midpoint of the mandible and detached (Figure 39b). By careful dissection, the layer of

subcutaneous fat was removed. The platysma muscle, which is in the superficial fascia and covering the lower part of the posterior triangle, was then identified. With the use of a probe, the platysma was reflected superiorly and further dissection freed the muscle from the deeper structures. The accessory nerve was identified in the superficial layer of deep cervical fascia. The fascia covering the sternocleidomastoid muscle was carefully removed, leaving the branches of the superficial cervical plexus and the external jugular vein intact. Fine dissection on the sternocleidomastoid muscle exposed the lesser occipital, great auricular, transverse cervical and supraclavicular nerves as it curved around the posterior border of the sternocleidomastoid muscle (Figure 39c). These nerves were identified and traced to the structures they innervated. Thereafter, the sternocleidomastoid muscle was measured from the mastoid process to the clavicle using a Wilson Wolpert Digital vernier caliper (0 – 150mm), and subsequently divided into 3 parts (upper, middle and lower thirds). The lesser occipital, great auricular, transverse cervical and supraclavicular nerves were measured from the mastoid process to their exit points on the sternocleidomastoid muscle. These measurements were made to determine the exit point of the nerves in relation to the sternocleidomastoid muscle (Figure 40).

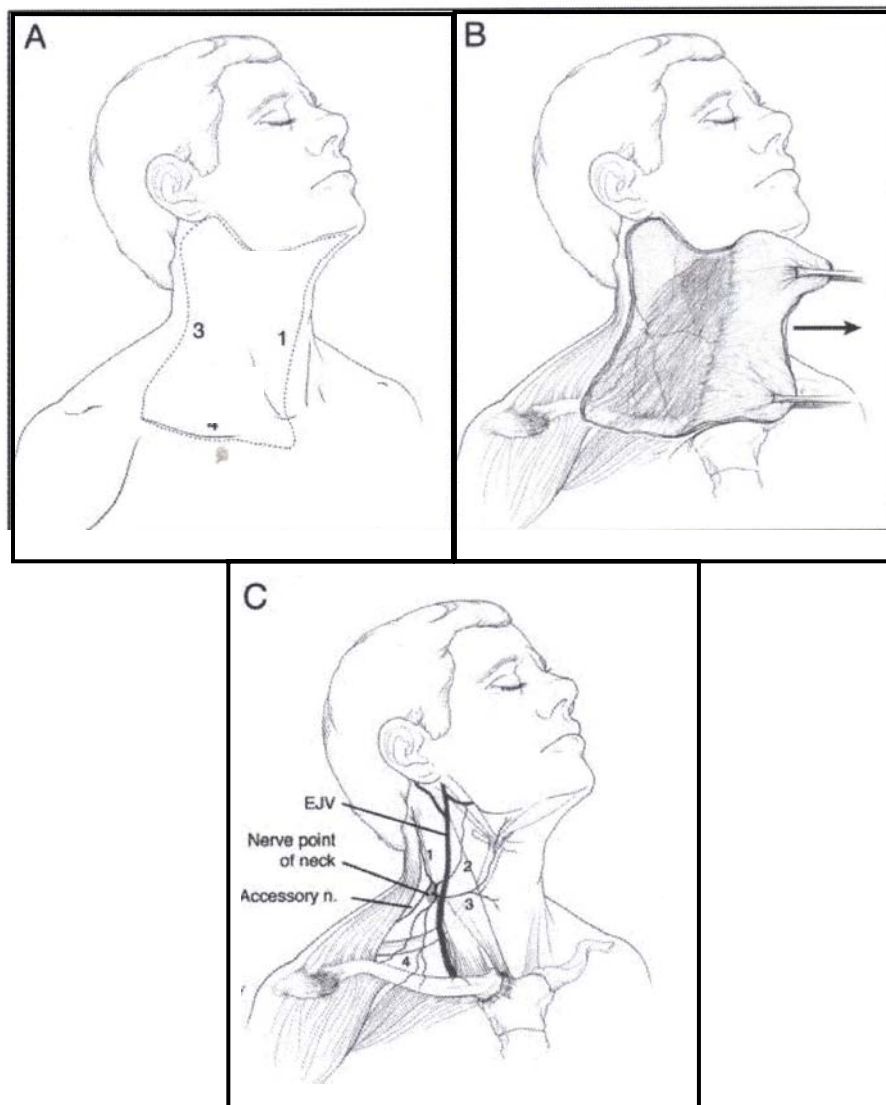


Figure 39: Illustration of dissection procedure
(Adapted from Brown, 2006)

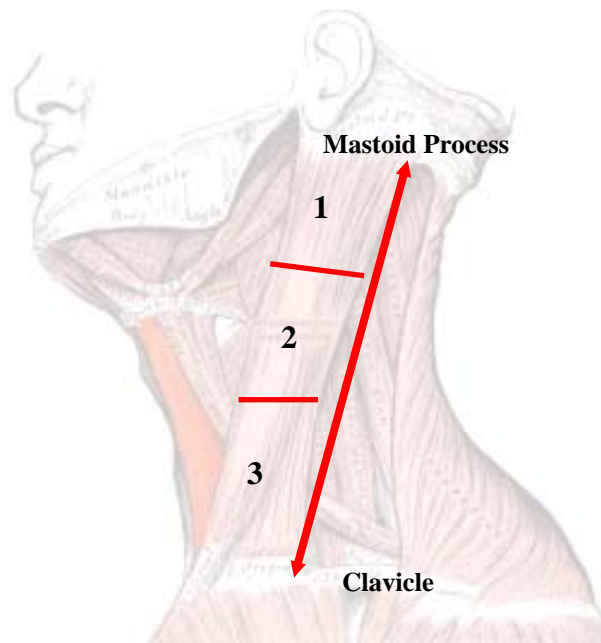


Figure 40: Illustration of the division of the sternocleidomastoid muscle
(Adapted from Standring et al., 2008)

Deep Dissection: to expose the deep cervical plexus

The sternocleidomastoid muscle was removed from its attachment to the clavicle and mastoid process. The lesser occipital, great auricular, transverse cervical and supraclavicular nerves were preserved. The fascia covering the floor of the posterior triangle was removed by fine dissection and the scalene muscles, levator scapulae muscle and splenius capitis muscle were exposed and identified. The branches of the superficial cervical plexus were then traced by fine dissection to the loops that they formed between scalenus anterior and scalenus medius muscles. The scalene and levator scapulae muscles were removed and the ansa cervicalis was traced as it formed a superior root from the hypoglossal nerve and an inferior root from the ventral ramus of the second cervical nerve. The common carotid artery, vagus nerve and internal jugular vein were dissected

to expose its relationship to the ansa cervicalis. In addition, communicating branches between the ventral ramus of the second cervical nerve and the superior cervical ganglion were exposed. Thereafter, the branches of the deep cervical plexus were traced to their origin using the loops as a guide. The dissections were recorded using a Canon digital Powershot G5 camera (4x optical zoom).

3.2 MORPHOLOGICAL & MORPHOMETRIC ANALYSIS

The following data were recorded:

- a) The incidence, anatomical course and variations of the branches of the superficial and deep cervical plexuses
- b) Length of the sternocleidomastoid muscle and subsequent division into thirds (upper, middle and lower)
- c) Distance of the lesser occipital, great auricular, transverse cervical and supraclavicular nerves from the mastoid process to their point of exit on the sternocleidomastoid muscle
- d) Relation of the lesser occipital, great auricular, transverse cervical and supraclavicular nerves to the sternocleidomastoid muscle and the external jugular vein
- e) Relation of the cervical vertebrae, common carotid artery, internal jugular vein, sympathetic chain, and vertebral artery to the deep cervical plexus
- f) Distribution of branches of the superficial cervical plexus
- g) Formation and distribution of the ansa cervicalis

3.3 STATISTICAL ANALYSIS

Statistical analysis using Microsoft Excel 2007 was utilized to calculate the averages, means, T-test Two Sampling method and R^2 (for differences in mean values). The following parameters were determined:

- Incidence of lesser occipital, great auricular, transverse cervical and supraclavicular nerves on right and left sides
- Length of the sternocleidomastoid muscle on the right and left sides
- Relation of lesser occipital, great auricular, transverse cervical and supraclavicular nerves between right and left sides
- Difference in emerging points of the lesser occipital, great auricular, transverse cervical and supraclavicular nerves between right and left sides
- Relation of external jugular vein to branches of the superficial cervical plexus

$R^2 = / > 1$ and P value > 0.05 was used to denote a statistically significant difference.

A Null Hypothesis was used to denote that the “means” are the same and an alternate hypothesis was used when the “means” are different

4.1 SAMPLE DEMOGRAPHICS

In this study, forty fetal (80 sides) and fifteen adult (30 sides) cadaveric specimens were microscopically and macroscopically dissected to document the anatomy of the superficial and deep cervical plexuses.

A total of 55 specimens were utilized (n=108). One right and one left side on two different adult specimens were excluded due to pathology of the head and neck region.

4.2 GROSS ANATOMY

In all the adult and fetal specimens dissected, the superficial cervical plexus emerged from beneath the posterior border of the sternocleidomastoid muscle as four separate and distinct branches. These branches, described after Standring *et al.*, (2008) were: ascending (lesser occipital, great auricular and transverse cervical nerves) and descending (supraclavicular nerves) branches.

The lesser occipital and great auricular nerves ascended along the posterior border of the sternocleidomastoid muscle towards the occipital region and parotid gland, respectively.

The transverse cervical nerve crossed the sternocleidomastoid muscle diagonally towards the angle of the mandible and anterior part of neck.

The supraclavicular nerves emerged from beneath the posterior border of sternocleidomastoid as a single trunk; it thereafter divided into the three main branches

that descended across the floor of the posterior triangle of the neck towards the deltoid, clavicle and pectoral regions (Plate 1).

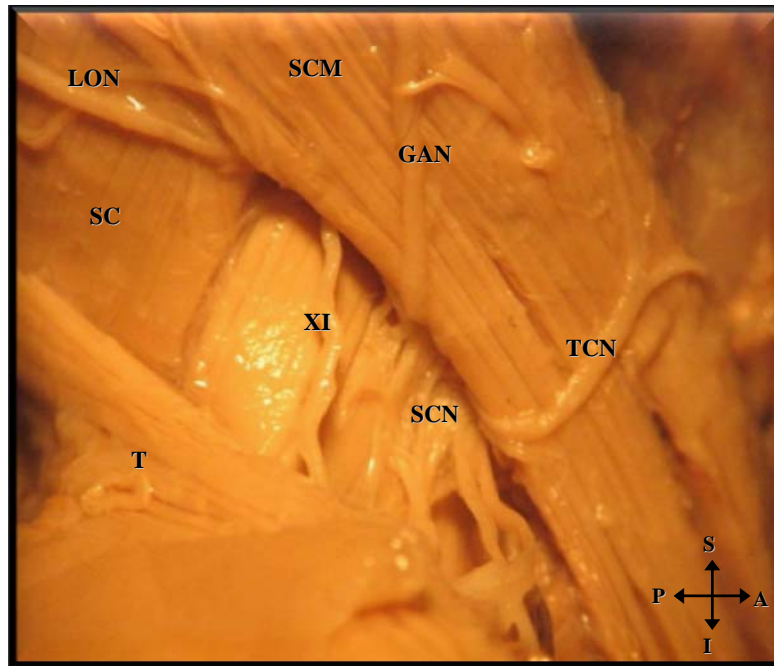


Plate 1: Right anterior view of the posterior triangle of neck depicting the superficial cervical plexus branches

For ease of orientation, the SCM and T are used as anterior and posterior landmarks, respectively

Key: LON - Lesser Occipital nerve, GAN – Great Auricular nerve, TCN – Transverse Cervical nerve, SCM – Sternocleidomastoid muscle, SCN – Supraclavicular nerve, T – Trapezius muscle, XI –Accessory nerve, SC – Splenius capitis muscle, LS – Levator scapulae muscle, A – Anterior, P – Posterior, S – Superior, I – Inferior

4.3 LESSER OCCIPITAL NERVE

4.3.1 INCIDENCE

a) FETUSES

The lesser occipital nerve was present in 100% ($^{40}/_{40}$) of the specimens on both the right and left sides. The average length of lesser occipital nerve was 11.60 ± 2.82 (1.77 - 18.33) mm and 11.61 ± 2.83 (5.36 - 18.76) mm on right and left sides, respectively (Table 3).

Table 3: Incidence and length of lesser occipital nerve in fetal specimens

	<i>Right</i>	<i>Left</i>
<i>Incidence of fetuses</i>	40	40
<i>Average length (mm)</i>	11.60	11.61
<i>Std Deviation</i>	2.82	2.83
<i>Min – Max (mm)</i>	1.77 – 18.33	5.36 -18.76

4.3.1.1 COMPARISON OF THE LENGTH ON THE RIGHT AND LEFT SIDES

When comparing the length of lesser occipital nerve on the right and left sides using the TTEST probability coefficient (P value: 0.01), the null hypothesis was rejected because $P < 0.05$; therefore no statistically significant difference was noted.

b) ADULTS

The lesser occipital nerve was observed in $^{14}/_{14}$ (100%) specimens on both sides. The average length of lesser occipital nerve was 23.59 ± 2.32 (19.55 – 26.34) mm and 23.45 ± 2.27 (19.74 -28.76) mm on the right and left sides respectively (Table 4).

Table 4: Incidence and length of the lesser occipital nerve in adult specimens

	<i>Right</i>	<i>Left</i>
<i>Incidence of adults</i>	<i>14</i>	<i>14</i>
<i>Std Deviation</i>	<i>2.32</i>	<i>2.27</i>
<i>Average length</i>	<i>23.59mm</i>	<i>23.45mm</i>
<i>Min – Max (mm)</i>	<i>19.55 – 26.34</i>	<i>19.74 - 28.76</i>

4.3.1.2 COMPARISON OF THE LENGTH ON THE RIGHT AND LEFT SIDES

With the use of the TTEST probability coefficient, it was found that no statistically significant difference was noted between the right and left sides (P=0.01).

4.3.2 OVERALL INCIDENCE OF LESSER OCCIPITAL NERVE

There were 108 lesser occipital nerves in the sample studied (right: 54; left: 54). No statistically significant differences could be identified between adults and fetuses with regard to the length of the lesser occipital nerve.

4.3.3 COURSE

The lesser occipital nerve is an ascending branch of the superficial cervical plexus. It emerged from beneath the posterior border of the sternocleidomastoid muscle by piercing the superficial cervical fascia and ascended along the lateral border of the sternocleidomastoid muscle, curving around the accessory nerve. In its ascent towards the occipital region, the lesser occipital nerve was located on the splenius capitis muscle in 100% ($^{28}/_{28}$) of the adults and in $^{68}/_{80}$ (85%) fetal specimens (Plate 2). In $^{12}/_{80}$ (15%) of the fetal specimens, it ascended vertically on the sternocleidomastoid muscle towards the ear, innervating its superior third.




Plate 2: *Left anterior view of the course of the lesser occipital nerve*

Key: LON - Lesser Occipital nerve, SC – Splenius capitis, LS – Levator scapulae, XI – Accessory nerve, SCM – Sternocleidomastoid muscle, T – Trapezius muscle

4.3.4 BRANCHING PATTERN

In its ascent, the lesser occipital nerve depicted the following branching patterns: (i) single; (ii) duplicate and (iii) triplicate (Table 5, Figure 41). The duplicate and triplicate branches were observed only in fetal specimens.

Table 5: Branching Patterns of the lesser occipital nerve

PATTERN n=108	SINGLE 84 (77%)				DUPLICATE 21 (21%)				TRIPPLICATE 3 (3%)			
SERIES	ADULT		FETUSES		ADULT		FETUSES		ADULT		FETUSES	
SIDES	R	L	R	L	R	L	R	L	R	L	R	L
SAMPLE NO.	14	14	29	27	0	0	13	8	0	0	2	1
TOTAL	28		56		0		21		0		3	

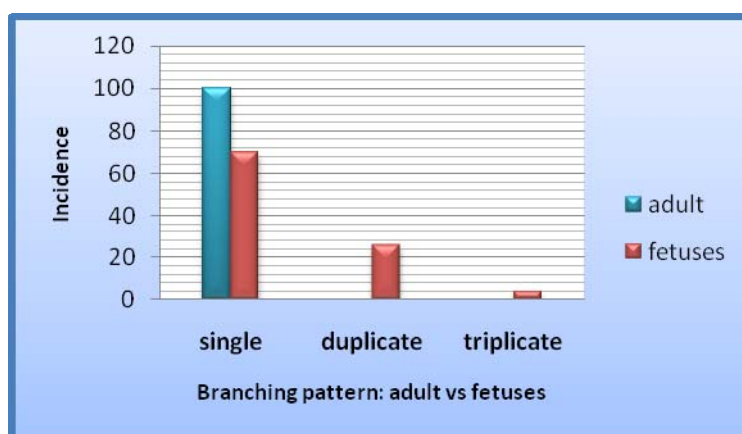


Figure 41: Graphic representation of lesser occipital nerve branching patterns

i) *Single*

The lesser occipital nerve emerged as a single trunk from beneath the posterior border of sternocleidomastoid muscle diverging from the great auricular nerve, curving lateral to the accessory nerve in $\frac{28}{28}$ (100%) adult and $\frac{56}{80}$ (70%) fetal specimens (Plate 3).




Plate 3: *Left anterior view of the single branching pattern of the lesser occipital nerve*

Key: SCM - Sternocleidomastoid muscle, LON - Lesser Occipital nerve, SC - Splenius capitis muscle, LS – Levator scapulae muscle, XI – Accessory nerve, T – Trapezius muscle

ii) Duplicate

In $\frac{21}{80}$ (26%) fetal specimens, a short distance after the lesser occipital nerve emerged, it diverged from the great auricular nerve, dividing into two distinct branches (Type I and Type II) (Plate 4).

Type I ascended on the sternocleidomastoid muscle curving towards the superior third of the ear.

Type II was visible on the lateral border of sternocleidomastoid muscle and innervated the area lateral to the ear (area over mastoid region).




Plate 4: Right anterior view of the duplication of lesser occipital nerve

Key: I – Type I Lesser Occipital nerve, II – Type II Lesser Occipital nerve, SCM – Sternocleidomastoid muscle, T – Trapezius muscle, PG – Parotid gland, EJV – External jugular vein, LON- Lesser occipital nerve

iii) Triplicate

In $\frac{3}{80}$ (4%) of the fetal specimens dissected, the lesser occipital nerve emerged from beneath the sternocleidomastoid muscle as a single trunk, thereafter dividing into three distinct branches that were based on the description by Madhavi and Holla (2004) viz.

a) Type I, b) Type II, and c) Type III.

a) Type I ascended a short distance on the sternocleidomastoid muscle before dividing into 2 branches viz. Type I^a and Type I^b. Type I^a curved towards the superior part of the ear, and Type I^b coursed towards the scalp (lateral occipital region).

b) Type II ascended towards the occiput and divided into three smaller branches.

c) Type III had a vertical ascent towards the occipital region. It ran parallel to Type II.

In addition, a communicating branch between Type II and Type III was also present (indicated by the dotted circle) (Plate 5).

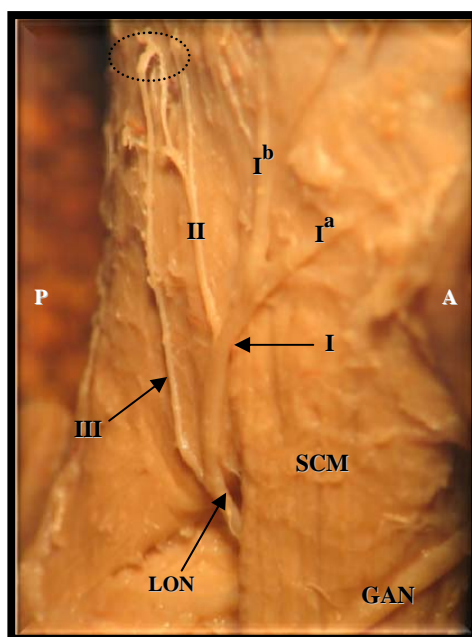


Plate 5: Right anterior view of the triplication of the lesser occipital nerve

Key: LON: Lesser occipital nerve, I – Type I Lesser Occipital nerve, II – Type II Lesser Occipital nerve, III – Type III Lesser Occipital nerve, SCM – Sternocleidomastoid muscle, GAN – Great auricular nerve, I^a and I^b – Type II Lesser occipital nerve branches, A – Anterior, P- Posterior

4.3.5 VARIATIONS

Lesser occipital nerve variations were only observed in fetal specimens on the left side.

- i) In $\frac{3}{80}$ (4%) of the fetuses dissected, the lesser occipital nerve emerged from beneath posterior border of the sternocleidomastoid muscle, hooked around the accessory nerve, crossed over the levator scapulae muscle in the direction towards the trapezius muscle. A variant trapezius muscle was observed as a thin slip which the lesser occipital nerve hooked around; thereafter the lesser occipital nerve divided into 2 branches that crossed the splenius capitis muscle and both branches coursed towards the occipital region (Plate 6). The accessory nerve crossed the levator scapulae muscle inferior to the lesser occipital nerve and pierced the trapezius muscle.

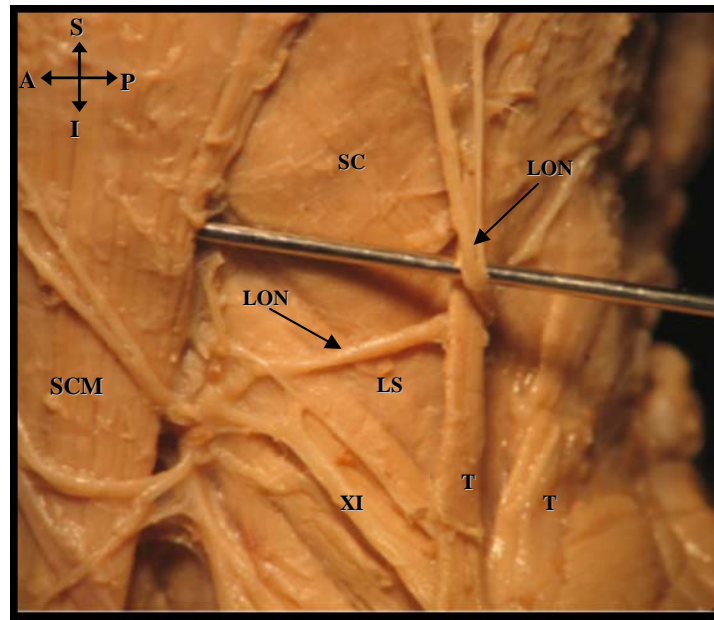


Plate 6: *Left anterior view of the anomalous course of the lesser occipital nerve*

Key: LON – Lesser Occipital nerve, SCM – Sternocleidomastoid muscle, XI – Accessory nerve, SC – Splenius capitis muscle, LS – Levator scapulae muscle, T – Trapezius muscle

- ii) In $\frac{2}{80}$ (2%) of the fetal specimens, LON was observed in the “carefree part” (*defined as the area superior to the accessory nerve*) of the neck (indicated by triangle) (Plate 7). In addition, there was a communication between 2 of these branches in one specimen (indicated by arrow) (Plate 8).

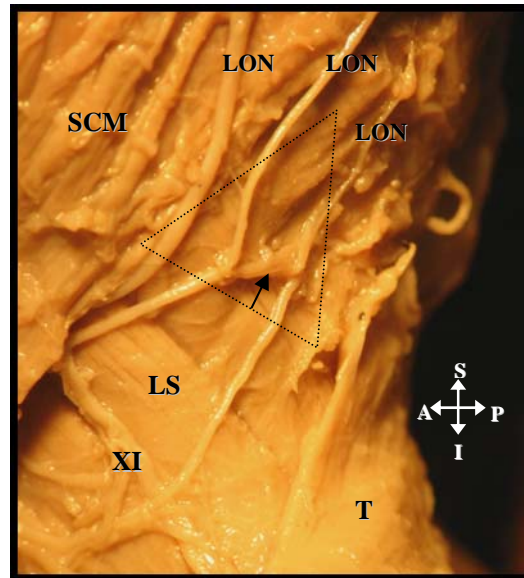


Plate 7: Left anterior view of the lesser occipital nerve located in “carefree part” of the neck

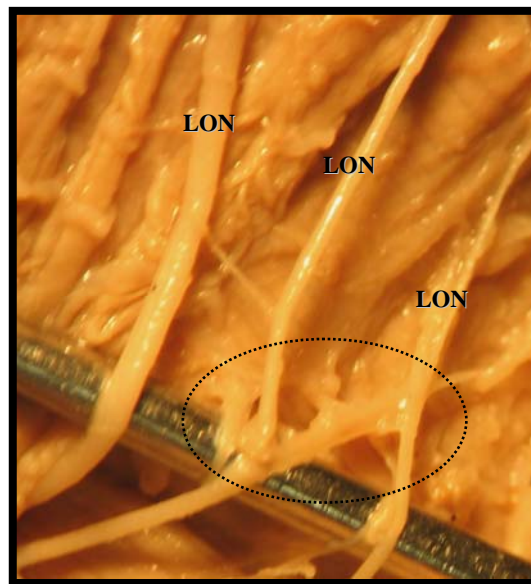


Plate 8: Magnified view (X80) of the communication between the two lesser occipital nerves (indicated by dotted circle) (Left anterior view)

Common Key: LON – Lesser Occipital nerve, SCM – Sternocleidomastoid muscle, XI – Accessory nerve, LS – Levator scapulae muscle, T – Trapezius muscle

4.3.6 RELATION TO EXTERNAL JUGULAR VEIN

In order to evaluate the relation of the lesser occipital nerve to external jugular vein, the TTEST statistical analysis for probability ($P > 0.05$) was utilized. In addition regression ($R^2 > 1$) values were also calculated.

On the left and right sides, no statistically significant differences [P value ($P=0.01$)] were noted in fetal or adult specimens and the R^2 values for fetuses it revealed that there was no correlation on the right ($R^2 = 0.019$) (Figure 42) and a correlation on the left ($R^2 = 0.465$) (Figure 43). However, no correlation was noted in the adult right (Figure 44) and left sides (Figure 45).

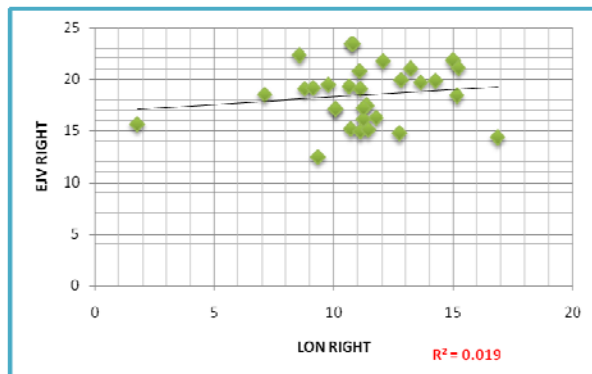


Figure 42: Right Fetal LON relation

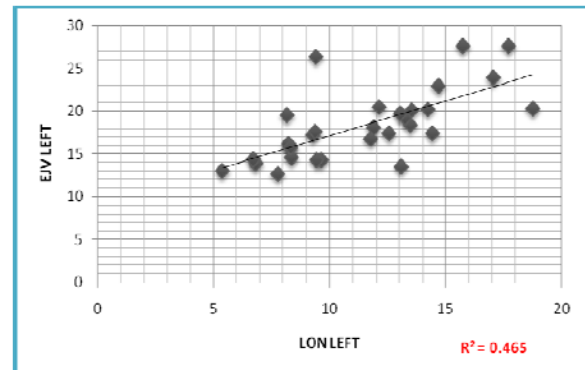


Figure 43: Left Fetal LON relation

Key: LON – Lesser Occipital nerve, EJV – External jugular vein

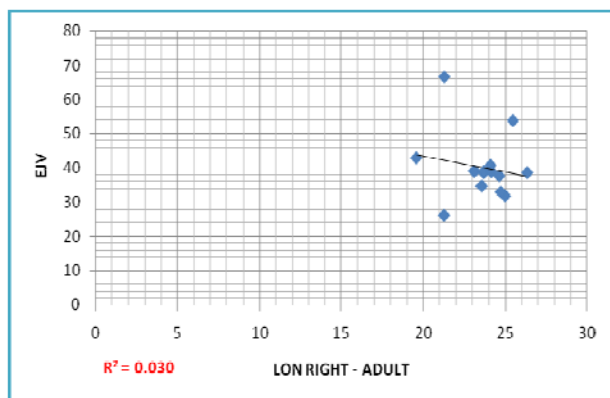


Figure 44: Right adult LON relation

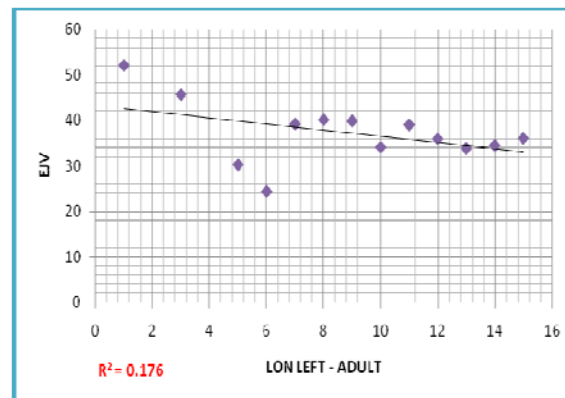


Figure 45: Left adult LON relation

Key: LON – Lesser Occipital nerve, EJV – External jugular vein

4.4 GREAT AURICULAR NERVE

4.4.1 INCIDENCE

a) FETUSES

The great auricular nerve was present in $\frac{40}{40}$ (100 %) of the specimens on the right and left sides. The average length of the great auricular nerve on the right and left sides were 12.65 ± 2.14 (7.82 – 17.16) mm and 12.55 ± 2.82 (7.60 – 18.28) mm (Table 6).

Table 6: Incidence and length of the great auricular nerve in fetal specimens

	<i>Right</i>	<i>Left</i>
<i>Incidence of Fetuses</i>	40	40
<i>Average length (mm)</i>	12.65	12.55
<i>Std Deviation</i>	2.14	2.82
<i>Min – Max (mm)</i>	7.82 - 17.16	7.60 – 18.28

4.4.1.1 COMPARISON OF THE LENGTH ON THE RIGHT AND LEFT SIDES

When comparing the length of the great auricular nerve on the right and left sides (P value: 0.00), the null hypothesis was rejected because $P < 0.05$: therefore no statistically significant difference was noted.

b) ADULTS

The great auricular nerve was observed in $^{14}/_{14}$ (100 %) of the specimens on the right and left sides. The average length of the great auricular nerve on the right and left sides were 24.71 ± 2.09 (22.15 - 29.25) mm and 25.72 ± 2.32 , (22.15 – 28.78) mm, respectively (Table 7).

Table 7: Incidence and length of the great auricular nerve in adult specimens

	<i>Right</i>	<i>Left</i>
<i>Incidence of adults</i>	<i>14</i>	<i>14</i>
<i>Average length (mm)</i>	<i>24.71</i>	<i>25.72</i>
<i>Std Deviation</i>	<i>2.09</i>	<i>2.32</i>
<i>Min – Max (mm)</i>	<i>22.15 – 29.25</i>	<i>22.15 – 28.78</i>

4.4.1.2 COMPARISON OF THE LENGTH ON THE RIGHT AND LEFT SIDES

When comparing the length of the great auricular nerve, it was found that that there was a minor difference of 1.1mm between the right and left sides, however this difference was not statistically significant (P=0.01).

4.4.2 COURSE

In the adult and fetal cadavers dissected, the great auricular nerve appeared as a large ascending branch of the superficial cervical plexus. It pierced the investing layer of cervical fascia, ascended under the superficial musculo-aponeurotic system and the

platysma muscle; thereafter it emerged from beneath the posterior border of the sternocleidomastoid muscle. The great auricular nerve has a superficial antero-superior course on the sternocleidomastoid muscle, crossing it diagonally to penetrate the parotid gland in $\frac{28}{28}$ (100%) of the adult specimens and $\frac{80}{80}$ (100%) of the fetal specimens. Furthermore, in its course, the great auricular nerve was located parallel to the transverse cervical nerve and the external jugular vein (Plate 9).

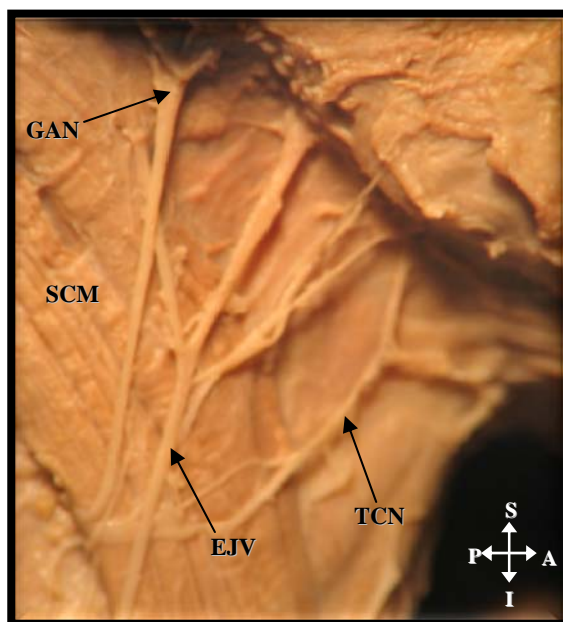


Plate 9: Right anterior view of neck depicting the course of the great auricular nerve

Key: GAN – Great Auricular nerve, SCM – Sternocleidomastoid muscle, EJV – External jugular vein, TCN – Transverse Cervical nerve

In $\frac{4}{80}$ (5%) of the fetal specimens, duplicate external jugular veins were observed; in these specimens the great auricular nerve was located anterior to one of the tributaries (indicated by dotted circle) (Plate 10). The great auricular nerve innervated the inferior $\frac{1}{3}$ rd of the ear in $\frac{28}{28}$ (100%) of the adult and $\frac{37}{80}$ (46%) of the fetal specimens; and the superior $\frac{2}{3}$ rd of the ear in $\frac{43}{80}$ (54%) of the fetal specimens.

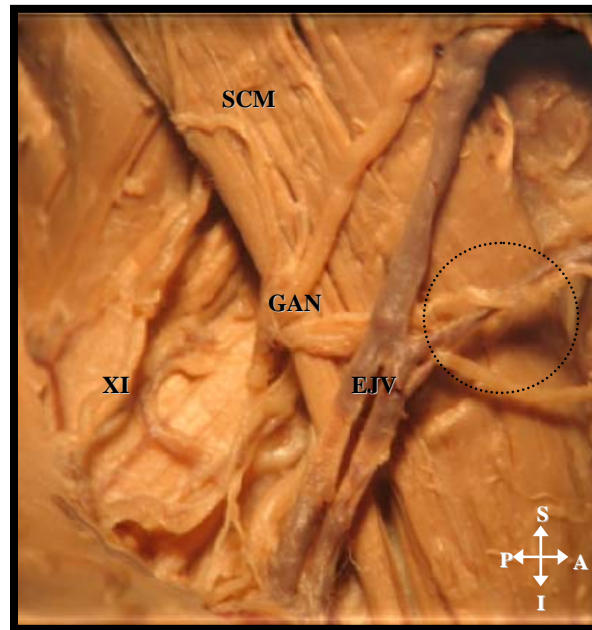


Plate 10: Right anterior view of neck depicting the great auricular nerve relation to the external jugular vein

Key: GAN – Great Auricular nerve, SCM – Sternocleidomastoid muscle, EJV – External jugular vein, XI – Accessory nerve

4.4.3 BRANCHING PATTERNS

Immediately, after emerging from beneath the posterior border of the sternocleidomastoid muscle, the great auricular nerve divided into two large and distinct branches in $\frac{18}{28}$ (64%) of the adult and $\frac{67}{80}$ (84%) of the fetal specimens. In $\frac{10}{28}$ (36%) of the adults and in $\frac{13}{80}$ (16%) of the fetal specimens the great auricular nerve remained as a single branch (Table 8, Figure 46).

Table 8: Branching Patterns of the great auricular nerve

PATTERN n=108	SINGLE 23 (21%)				DUPLICATE 85 (79%)			
SERIES	ADULT		FETUSES		ADULT		FETUSES	
SIDES	R	L	R	L	R	L	R	L
SAMPLE NO.	6	4	7	6	8	10	33	34
TOTAL	10		13		18		67	

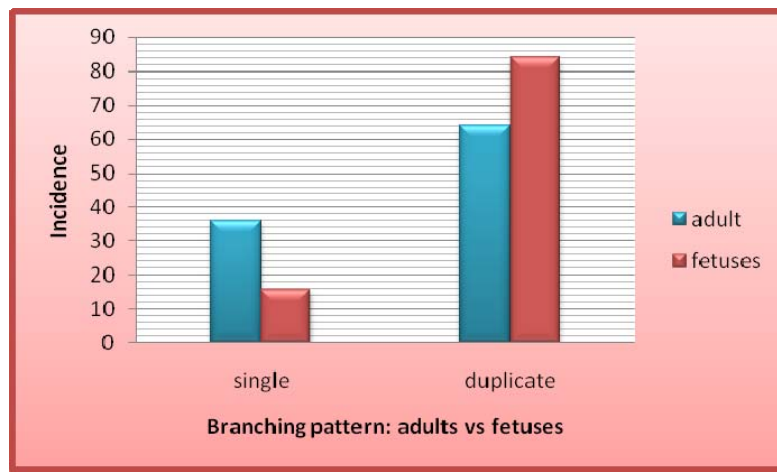


Figure 46: Branching pattern of the great auricular nerve

i) Single

As the great auricular nerve emerged on the sternocleidomastoid muscle it continued as a single branch in $\frac{10}{28}$ (36%) adults and $\frac{13}{80}$ (16%) fetal specimens; this branch divided at the inferior pole of the parotid gland into minute branches and were distributed to the parotid fascia as well as to the inferior part of the ear (Plate 11).

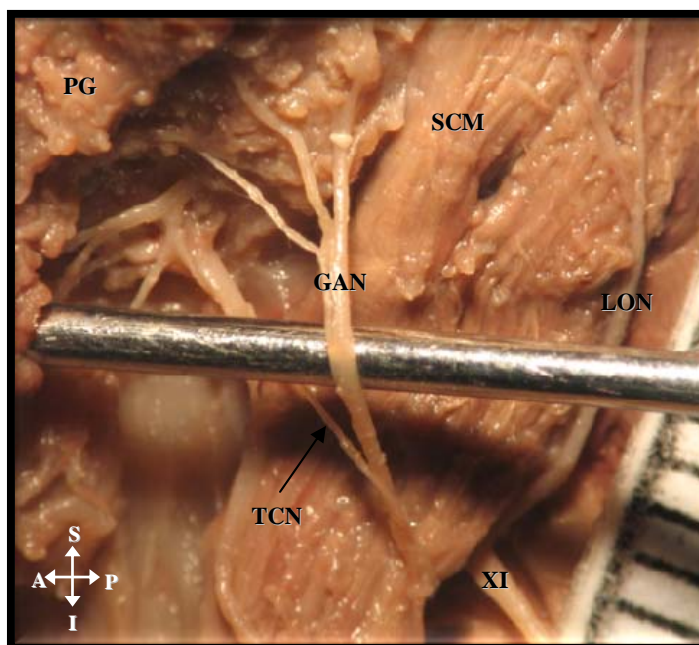


Plate 11: *Left anterior view of the single branching pattern and distribution of the great auricular nerve*

Key: GAN – Great Auricular nerve, LON – Lesser Occipital nerve, PG – Parotid gland, SCM – sternocleidomastoid muscle, XI– Accessory nerve, TCN – Transverse cervical nerve

i) Duplicate

Immediately after emerging from the posterior border of the sternocleidomastoid muscle, the great auricular nerve divided into two main branches in $^{16}/_{28}$ (57%) adults and $^{54}/_{80}$ (67%) fetuses. These branches are referred to as Type I: anterior and posterior branches (Table 9; Plate 12). The anterior branch divided into smaller branches that were distributed to the parotid fascia and the posterior branches supplied the area over the mastoid region.

In $^{12}/_{28}$ (43%) of the adults and $^{26}/_{80}$ (33%) of the fetuses the great auricular nerve bifurcated into anterior and posterior branches at about the midpoint of the

sternocleidomastoid muscle (Table 9; Plate 13); these branches are referred to as Type II: anterior and posterior branches.

Table 9: Type I and Type II duplicate branching patterns of the great auricular nerve

	ADULTS	FETUSES
TYPE I	16	54
TYPE II	12	26
TOTAL	28	80




Plate 12: Right anterior view of Type I branches of the great auricular nerve

Key: SCM – Sternocleidomastoid muscle, **GAN^a** – Anterior branch of Great Auricular nerve, **GAN^p** – Posterior branch of Great Auricular nerve, **PG** – Parotid gland, **TCN**- Transverse Cervical nerve, **EJV** – External jugular vein, **T**- Trapezius muscle




Plate 13: Left anterior view of Type II branches of the great auricular nerve

Key: SCM – Sternocleidomastoid muscle, GAN – Great auricular nerve, GAN^a – Anterior branch of Great Auricular nerve, GAN^p – Posterior branch of Great Auricular nerve, LON- Lesser occipital nerve

4.4.4 VARIATION

On the left side in $\frac{1}{80}$ (1%) of the fetal specimens, the transverse cervical nerve divided into three branches, with the uppermost branch forming a communication with the great auricular nerve, inferior to the parotid gland (indicated by circle) (Plate 14).




Plate 14: *Left anterior view of the communication between great auricular nerve and the transverse cervical nerve*

Key: TCN – Transverse Cervical nerve, GAN – Great Auricular nerve, EJV – External Jugular vein, SCM – Sternocleidomastoid muscle

4.4.5 RELATION TO EXTERNAL JUGULAR VEIN

In the adult series there were no statistically significant differences between the relations on the right and left sides (Figures 47-48). On the other hand, the fetal sample depicted a positive correlation on the left side ($R^2 = 0.482$) but no correlation was observed on the right side ($R^2 = 0.132$) (Figures 49-50).

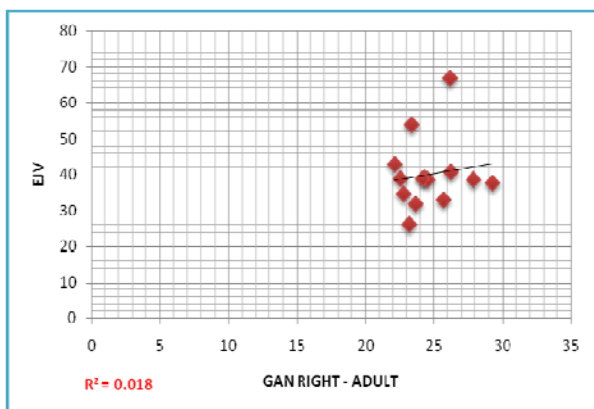


Figure 47: Right adult GAN relation

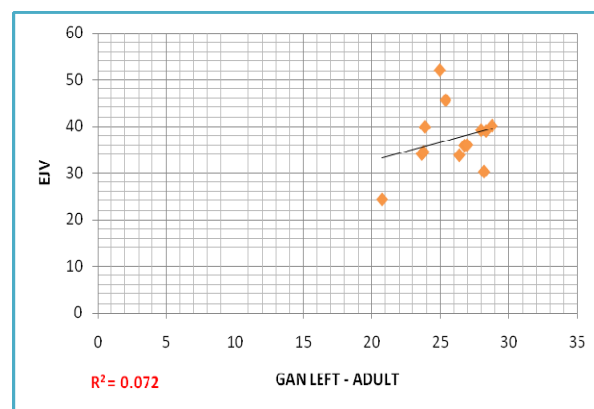


Figure 48: Left adult GAN relation

Key: GAN – Great Auricular nerve, EJV – External Jugular vein

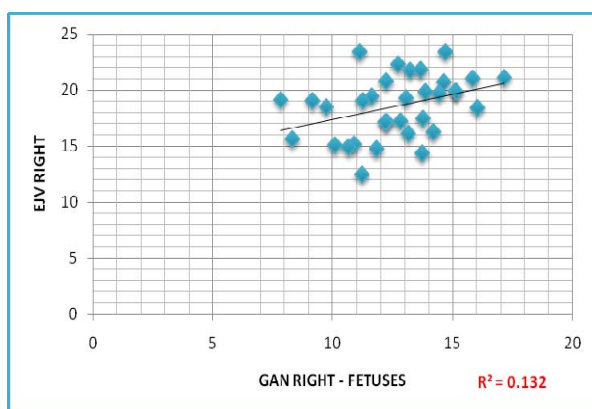


Figure 49: Right fetal GAN relation

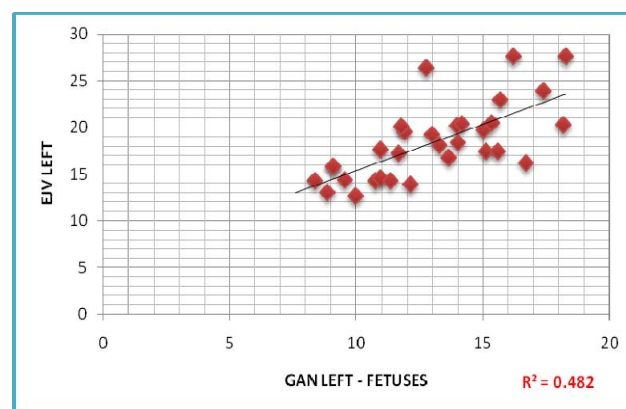


Figure 50: Left fetal GAN relation

Key: GAN – Great Auricular nerve, EJV – External Jugular vein

4.5 TRANSVERSE CERICAL NERVE

4.5.1 INCIDENCE

a) FETUSES

The transverse cervical nerve was present in 100% ($^{40}/_{40}$) of the specimens on right and left sides. The average length of the transverse cervical nerve was 14.63 ± 2.34 (9.19 - 18.97) mm and 14.61 ± 2.72 (9.36 - 21.17) mm on right and left sides, respectively (Table 10).

Table 10: Incidence and length of the transverse cervical nerve in fetal specimens

	<i>Right</i>	<i>Left</i>
<i>Incidence of Fetuses</i>	40	40
<i>Average length (mm)</i>	14.63	14.61
<i>Std Deviation</i>	2.34	2.72
<i>Min – Max (mm)</i>	9.19- 18.97	9.36 - 21.17

4.5.1.1 COMPARISON OF THE LENGTH ON THE RIGHT AND LEFT SIDES

When comparing the length of the transverse cervical nerve in fetuses, on the right and left sides (P value: 0.01) using the TTEST probability coefficient, the null hypothesis was rejected because $P < 0.05$; therefore no statistically significant difference was noted between sides.

b) ADULTS

The transverse cervical nerve was observed in $^{14}/_{14}$ (100%) specimens on the right and left sides. The average length of the transverse cervical nerve was 32.23 ± 2.07 (25.77 – 40.96) mm and 31.43 ± 2.09 (22.06 – 37.49) mm on the right and left sides respectively (Table 11).

Table 11: Incidence and length of the transverse cervical nerve in adults

	<i>Right</i>	<i>Left</i>
<i>Incidence of Adults</i>	14	14
<i>Average length (mm)</i>	32.23	31.43
<i>Std Deviation</i>	2.07	2.09
<i>Min – Max (mm)</i>	25.77 -40.96	22.06 – 37.49

4.5.1.2 COMPARISON OF THE LENGTH ON THE RIGHT AND LEFT SIDES

With the use of the TTEST probability coefficient, the length of the transverse cervical nerve in adults: revealed no statistically significant difference between the right and left sides (P=0.03).

4.5.2 COURSE

The transverse cervical nerve emerged from beneath the posterior border of the sternocleidomastoid muscle at a common emerging point with the great auricular nerve. In all specimens analyzed it crossed the sternocleidomastoid muscle at its midline and was constantly located inferior to the great auricular nerve.

The transverse cervical nerve was located either deep to the external jugular vein in [$^{17}/_{28}$, (61%) of the adults and in $^{54}/_{80}$, (68%) of the fetal specimens] or superficial [$^{11}/_{28}$, (39%) of the adults and in $^{26}/_{80}$, (32%) of the fetal specimens] (Plate 15). The transverse cervical nerve was destined to innervate the area around the angle of the mandible and anterior neck.




Plate 15: Right anterior view of the location and course of the transverse cervical nerve

Key: PG -Parotid gland, EJV -External jugular vein, TCN - Transverse Cervical nerve, GAN - Great Auricular nerve, SCM - Sternocleidomastoid muscle, T – Trapezius muscle, LON – Lesser occipital nerve, XI – Accessory nerve

4.5.3 BRANCHING PATTERNS

After the transverse cervical nerve pierced the deep cervical fascia and crossed the anterior border of the sternocleidomastoid muscle transversely, it divided into ascending and descending branches in the majority of the adult ($^{17}/_{28}$), (61%) and fetal $^{65}/_{80}$, (81%) specimens. In $^{11}/_{28}$, (39%) of the adult and $^{12}/_{80}$, (15%) of the fetal specimens, the

transverse cervical nerve was observed as a single nerve that crossed the sternocleidomastoid muscle to reach the anterior part of the neck (Table 12, Figure 51).

Table 12: Branching patterns of the transverse cervical nerve

PATTERN n=108	SINGLE 23 (21%)				DUPLICATE 82 (76%)				TRIPPLICATE 3 (4%)			
SERIES	ADULT		FETUSES		ADULT		FETUSES		ADULT		FETUSES	
SIDES	R	L	R	L	R	L	R	L	R	L	R	L
SAMPLE NO.	6	5	6	6	9	8	38	27	0	0	3	0
TOTAL	11		12		17		65		0		3	

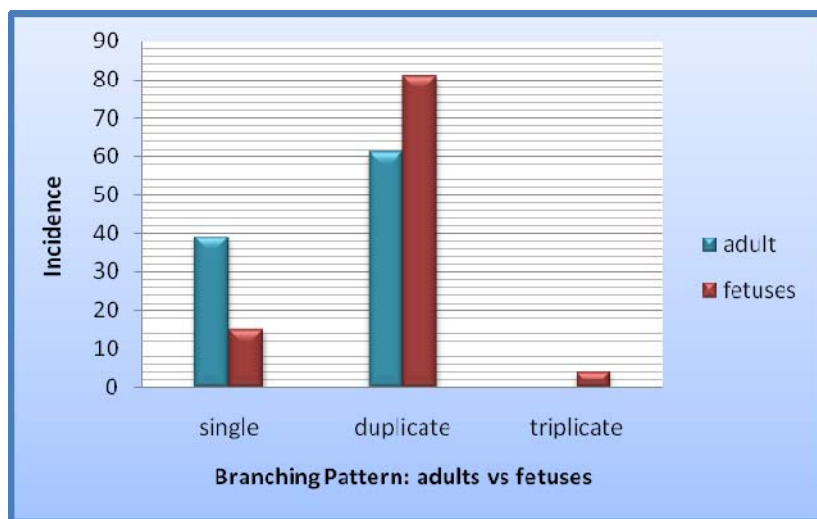


Figure 51: Graphic illustration of the branching patterns of the transverse cervical nerve

i) Single

In the adult [$^{11}/_{28}$, (39%)] and fetal [$^{12}/_{80}$, (15%)] specimens with the single branching pattern, the transverse cervical nerve crossed the anterior border of the sternocleidomastoid muscle, intertwined with the external jugular vein, to reach the angle

of the mandible and occasionally it was destined to innervate the anterior part of the neck (Plate 16).

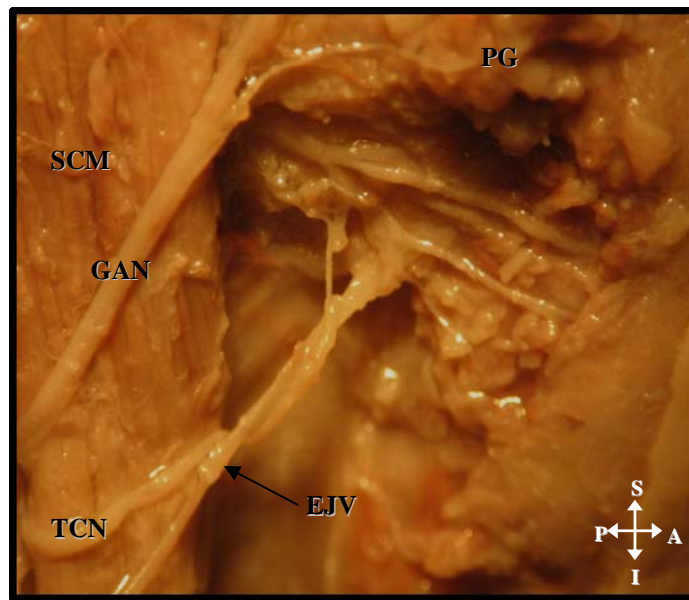


Plate 16: Right anterior view of single branching pattern of the transverse cervical nerve

Key: TCN – Transverse Cervical nerve, EJV – External jugular vein, GAN – Great Auricular nerve, SCM – Sternocleidomastoid muscle, PG – Parotid gland

ii) Duplicate

As the TCN crosses the sternocleidomastoid muscle, it divides into two major branches, viz. ascending and descending, in $\frac{17}{28}$ (61%) of the adults and $\frac{65}{80}$ (81%) of the fetuses. These branches present a “Y” shaped appearance. The ascending branch runs towards the angle of the mandible and the descending branch grooves the submandibular gland in its descent to the anterior part of the neck (Plate 17).

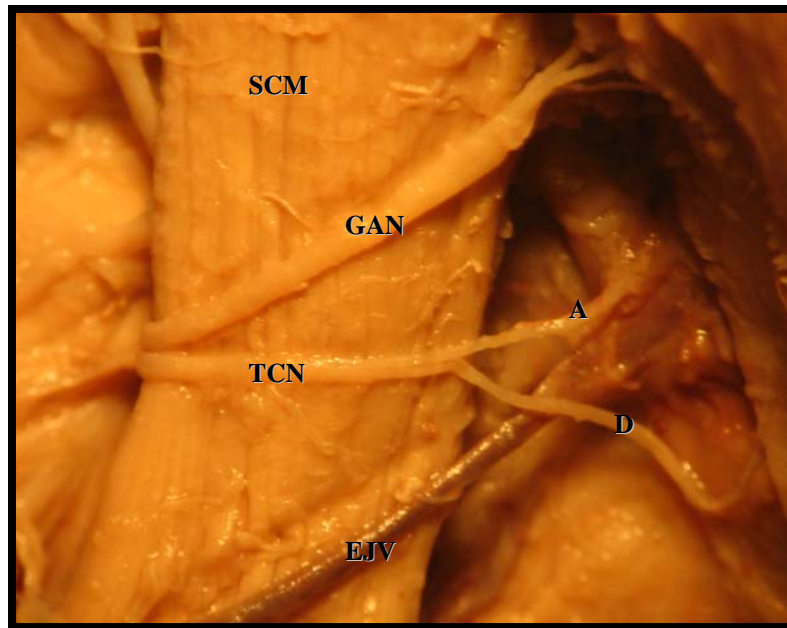


Plate 17: Right anterior view of ascending and descending branches of the transverse cervical nerve

Key: TCN - Transverse Cervical nerve, A - Ascending branch, D - Descending branch, SCM - Sternocleidomastoid muscle, EJV -External jugular vein, GAN – Great auricular nerve

4.5.4 VARIATIONS

i) Triplicate transverse cervical nerve

In $\frac{3}{80}$ (4%) fetal specimens there was a triplicate transverse cervical nerve. These branches will be referred to as (a) ascending, (b) intermediate and (c) descending and were located posterior to the external jugular vein (Plate 18).

(a) The ascending branch had a diagonal course towards the inferior pole of the parotid gland;

(b) The intermediate branch crossed the sternocleidomastoid muscle transversely to reach the angle of the mandible

(c) The descending branch coursed towards the anterior part of neck.

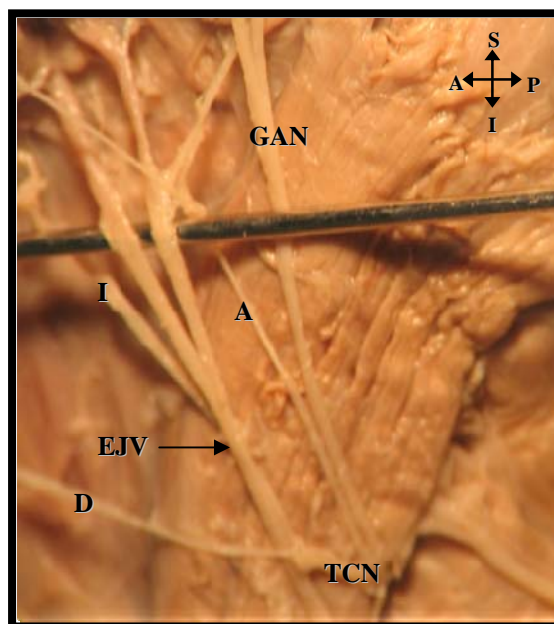


Plate 18: *Left anterior view of triplicate transverse cervical nerve*

Key: TCN - Transverse Cervical nerve, A - Ascending branch, D - Descending branch, I – Intermediate branch EJV -External jugular vein, GAN – Great Auricular nerve

ii) *Anastomosis between the transverse cervical nerve and facial Nerve*

Anastomosis between transverse cervical nerve and facial nerve were observed in:

- (a) $\frac{15}{108}$ (13%) in both fetal and adult specimens with the single branching pattern (Plate 19);
- (b) $\frac{65}{108}$ (60%) in both fetal and adult of the specimens depicted the duplicate branching pattern whereby the ascending branch of the transverse cervical nerve passed upward toward the area inferior to the parotid gland communicating with the cervical branch of the facial nerve.
- (c) $(\frac{3}{80})$ (4%) of the fetal specimens with the triplicate branching pattern where the intermediate branch formed the anastomosis with the cervical branch of the facial nerve (indicated by circle) (Plate 20).

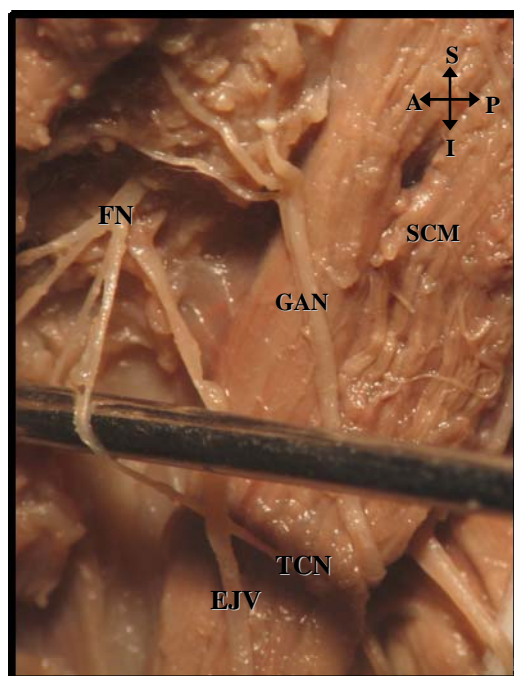


Plate 19: *Anastomosis between the transverse cervical nerve and facial nerve (Left anterior view)*

Key: FN – Facial nerve, TCN – Transverse cervical nerve, EJV – External jugular vein, SCM- Sternocleidomastoid muscle

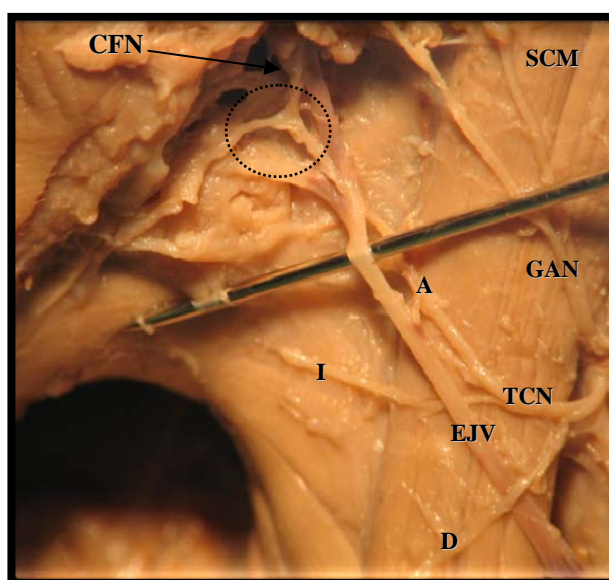


Plate 20: *Anastomosis between ascending branch of the transverse cervical nerve and cervical branch of facial nerve (Left anterior view)*

Key: CFN – Cervical branch of facial nerve, TCN – Transverse cervical nerve, GAN – Great Auricular nerve, EJV – External jugular vein, A – Ascending branch, I –Intermediate branch, D – Descending branch

4.5.5 RELATION TO EXTERNAL JUGULAR VEIN

It was noted that on the right sides of fetuses (R^2 : 0.280) and adults (R^2 : 0.232), there was no correlation between the transverse cervical nerve and external jugular vein (Figures 52-53). On the left there was a positive correlation in fetuses (R^2 : 0.499) but not in adults (R^2 : 0.275) (Figures 54-55). The P values for adults (P = 0.01) and fetuses (P = 0.00) indicate that there were no statistically significant differences between sides.

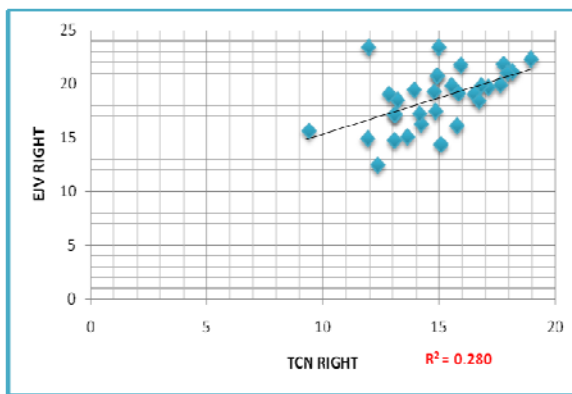


Figure 52: Right fetal TCN relation

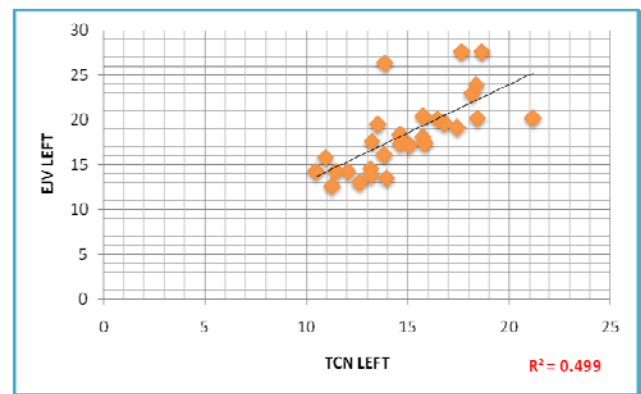


Figure 53: Left fetal TCN relation

Key: EJV – External jugular vein, TCN – Transverse cervical nerve

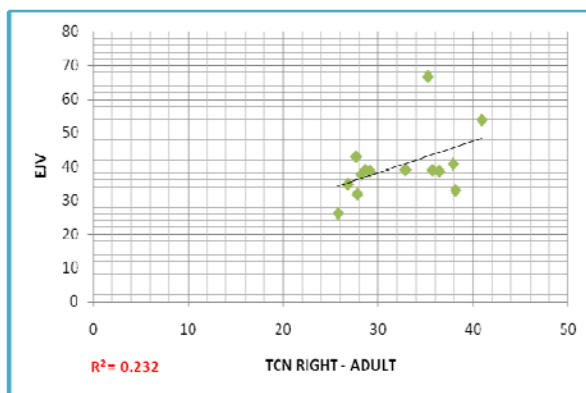


Figure 54: Right adult TCN relation

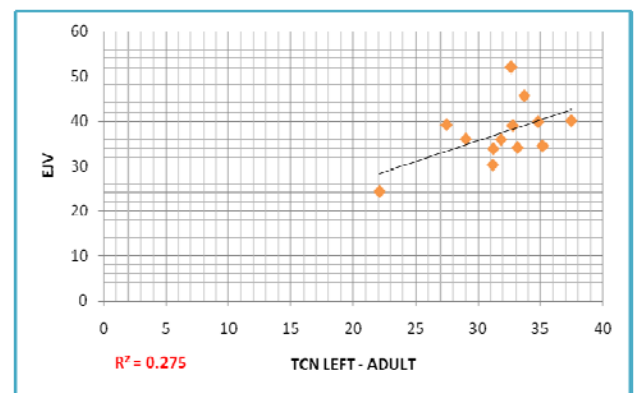


Figure 55: Left adult TCN relation

Key: EJV – External jugular vein, TCN – Transverse cervical nerve

4.6 SUPRACLAVICULAR NERVES

4.6.1 INCIDENCE

a) FETUSES

The supraclavicular nerve was observed in $^{40}/_{40}$ (100%) of the specimens on the right and left sides. The average length of the supraclavicular nerve was 16.87 ± 2.34 (12.72 - 21.86) mm and 16.85 ± 2.77 (11.54 – 23.23) mm on the right and left sides (Table 13).

Table 13: Incidence and length of the supraclavicular nerve in fetuses

	<i>Right</i>	<i>Left</i>
<i>Incidence of fetuses</i>	40	40
<i>Average length (mm)</i>	16.87	16.85
<i>Std Deviation</i>	2.34	2.77
<i>Min – Max (mm)</i>	12.72 – 21.86	11.54 – 23.23

4.6.1.1 COMPARISON OF THE LENGTH ON THE RIGHT AND LEFT SIDES

When comparing the length of the supraclavicular nerve in fetuses, using the TTEST probability coefficient, it was noted that this difference was not statistically significant (P=0.01).

b) ADULTS

The supraclavicular nerve was observed in $^{14}/_{14}$ (100%) specimens on the right and left sides. The average length of the supraclavicular nerve was 35.93 ± 2.63 (25.35 – 45.78) mm and 34.57 ± 2.85 (24.56 – 39.14) mm on the right and left sides (Table 14).

Table 14: Incidence and length of the supraclavicular nerve in adults

	<i>Right</i>	<i>Left</i>
<i>Incidence of adults</i>	14	14
<i>Average length (mm)</i>	35.93	34.57
<i>Std Deviation</i>	2.63	2.85
<i>Min – Max (mm)</i>	25.35 – 45.78	24.56 – 39.14

4.6.1.2 COMPARISON OF THE LENGTH ON THE RIGHT AND LEFT SIDES

With the use of the TTEST probability coefficient, the length of the supraclavicular nerve in adults revealed no statistically significant difference between the right and left sides (P=0.01).

4.6.2 COURSE

In all the specimens investigated the supraclavicular nerve pierced the superficial cervical fascia and emerged as a single trunk at the posterior border of the sternocleidomastoid muscle (Plate 21). It descended on the scalenus anterior and medius muscles, dividing into three distinct branches, viz. medial, lateral and intermediate. These branches appeared to intertwine with the external jugular vein.

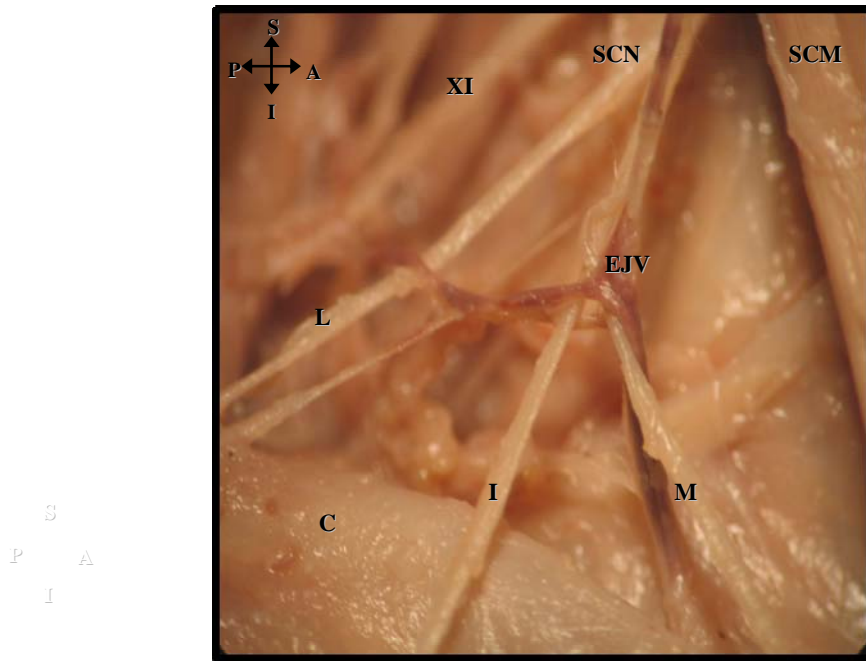


Plate 21: Right anterior view of the course of the supraclavicular nerve

Key: SCN – Supraclavicular nerve, M – Medial branch, L – Lateral branch, I – Intermediate branch, C – Clavicle, XI – Accessory nerve, EJV – External jugular vein

4.6.3 BRANCHING PATTERNS

i) Medial Branch

The medial branch of the supraclavicular nerve was observed in all adult and fetal specimens to be the most infero-medial branch: it was closely related to the external jugular vein and the sternocleidomastoid muscle (Plate 22). The medial branch innervated skin over the anterior part of the clavicle.

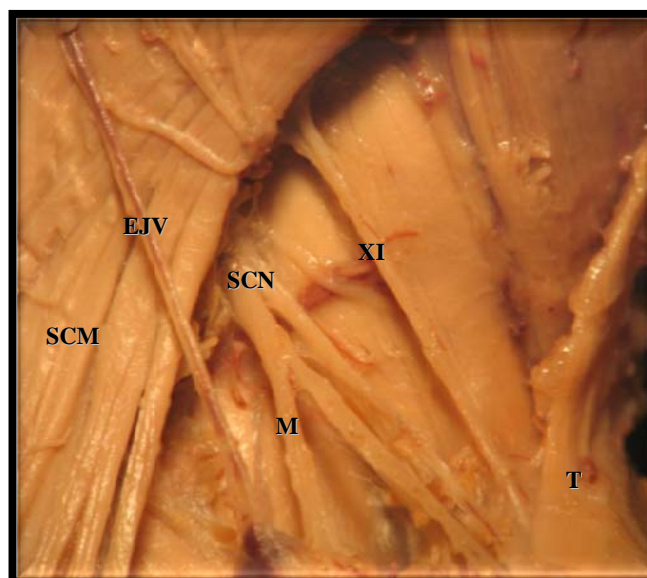


Plate 22: Left anterior view of the medial branch of the supraclavicular nerve and its relation to the external jugular vein and the sternocleidomastoid muscle

Key: EJV – External jugular vein, SCM – Sternocleidomastoid muscle, SCN – Supraclavicular nerve, M – Medial branch of supraclavicular nerve, XI – Accessory nerve, T – Trapezius muscle

ii) Intermediate Branch

The intermediate branch of the supraclavicular nerve was observed in all adult and fetal specimens: it pierced the cervical fascia and emerged along the posterior border of sternocleidomastoid muscle, descended antero-inferiorly, crossing the clavicle to innervate the skin over the deltoid muscle (Plate 23).

iii) Lateral Branch

The lateral branch of the supraclavicular nerve descended superficially, crossing the anterior border of the trapezius muscle in all adult and fetal specimens: it divided into several smaller branches and innervated the skin of the upper and posterior parts of the shoulder (please see plate 23)

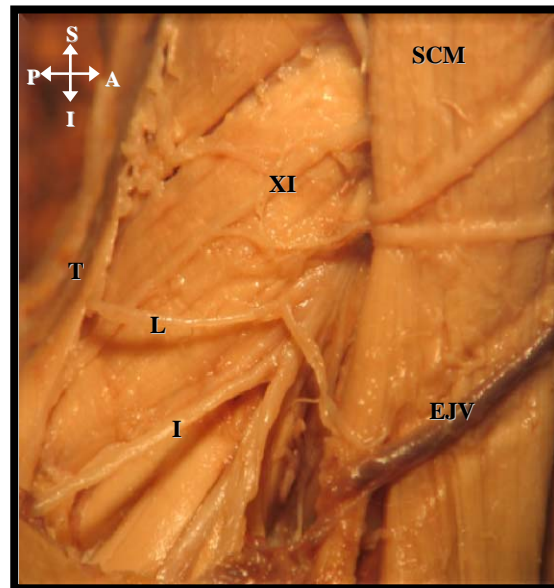


Plate 23: Right anterior view of the lateral and intermediate branch of the supraclavicular nerve

Key: SCM – Sternocleidomastoid muscle, I – Intermediate branch of supraclavicular nerve, XI – Accessory nerve, EJ – External Jugular vein

4.6.4 VARIATIONS

- i) In $\frac{2}{80}$ (3%) of the fetal specimens: the supraclavicular nerve emerged from the posterior border of the sternocleidomastoid muscle, and gave off 5 branches from the main trunk - two of its posterior most branches (referred to as Type I and Type II) were parallel to the lateral branch of the supraclavicular nerve and pierced the trapezius muscle (Plate 24).

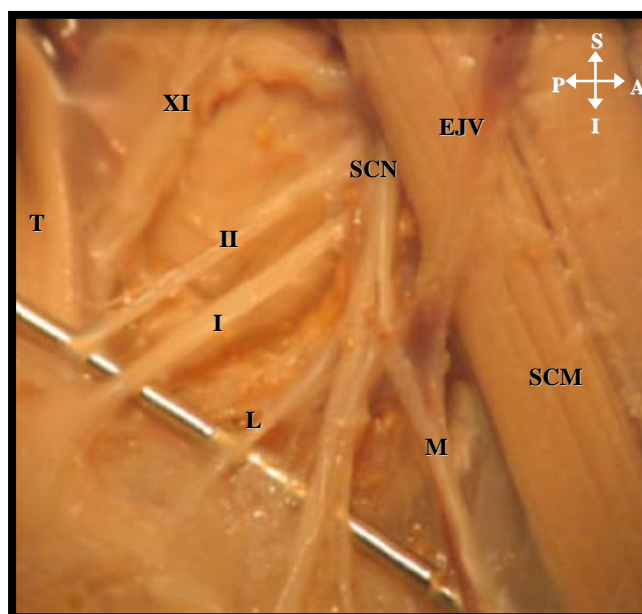


Plate 24: Right anterior view of additional branches of the supraclavicular nerve

Key: T - Trapezius muscle, M –Medial supraclavicular branch, L –Lateral supraclavicular branch
 XI - Accessory nerve, I and II – type I and type II posterior branch, SCM –Sternocleidomastoid muscle,
 SCN –Supraclavicular nerve, EJV –External jugular vein

- ii) In $\frac{6}{80}$ (8%) of the fetal specimens, an ascending branch (L^1) arose from the lateral branch of the supraclavicular nerve and supraclavicular nerve trunk: it ascended towards the scalp, parallel to the lesser occipital nerve. Upon investigation this branch appeared to mimic the course of the lesser occipital nerve.

In addition, there was a duplicate medial branch (M^1) that arose directly from the supraclavicular trunk was observed to lie beneath the external jugular vein, parallel to the sternocleidomastoid muscle (Plate 25).

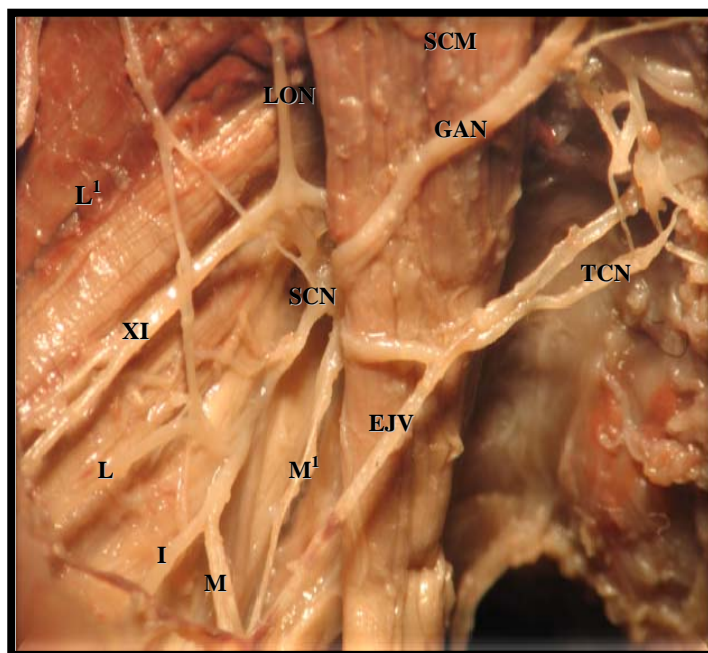


Plate 25: Right anterior view of the anomalous branching of supraclavicular nerve

Key: L - Lateral supraclavicular branch, M –Medial supraclavicular branch, XI - Accessory nerve, L¹ – anomalous lateral supraclavicular branch, M¹ –anomalous medial branch, I – Intermediate supraclavicular branch, SCN – supraclavicular nerve, LON – Lesser occipital nerve, SCM – Sternocleidomastoid muscle, TCN – Transverse cervical nerve, EJ – External jugular vein, GAN – Great auricular nerve

- iii) In $\frac{1}{80}$ (1%) of the fetal specimens, the medial branch of supraclavicular nerve divided into two branches, with one branch having an anomalous course: it passed beneath the inferior belly of omohyoid (indicated by circle) to reach the area over the clavicle (Plate 26).




Plate 26: *Left anterior view of the anomalous course medial branch of the supraclavicular nerve*

Key: **M** –Medial supraclavicular branch, **I** –Intermediate supraclavicular branch, **L** –Lateral supraclavicular branch, **XI** - Accessory nerve, **OI** – Inferior belly of omohyoid muscle, **SCM** – Sternocleidomastoid muscle, **T** – Trapezius muscle, **TCN** – Transverse cervical nerve

4.6.5 RELATION TO EXTERNAL JUGULAR VEIN

Anatomically the external jugular vein intertwines with the medial branch of the supraclavicular nerve. According to statistical analysis using the regression test there was a strong correlation with regard to the relation of the external jugular vein to the supraclavicular nerve in both adults ($R^2=0.476$ on the right and $R^2=0.453$ on the left) and fetuses ($R^2=0.533$ on the right and $R^2=0.766$ on the left) (Figures 56-59).

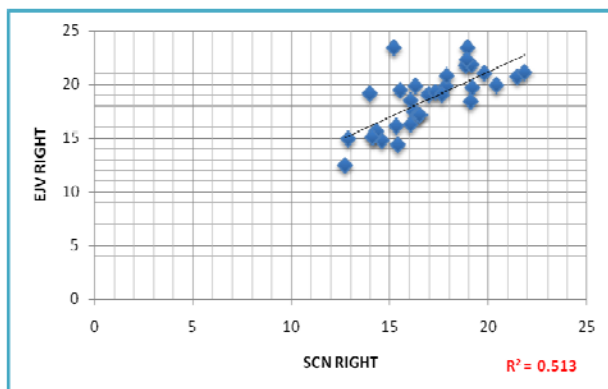


Figure 56: Right fetal SCN relation

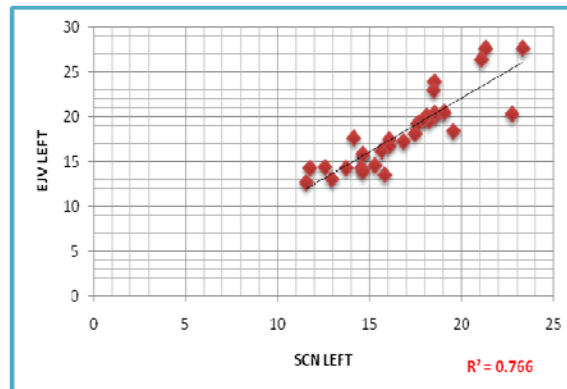


Figure 57: Left fetal SCN relation

Key: SCN - Supraclavicular nerve, EJV-External jugular vein

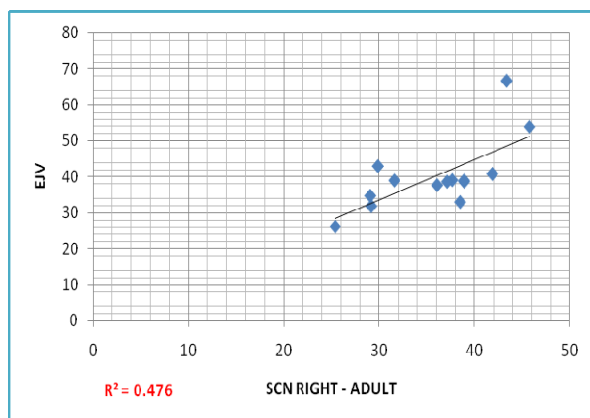


Figure 58: Right adult SCN relation

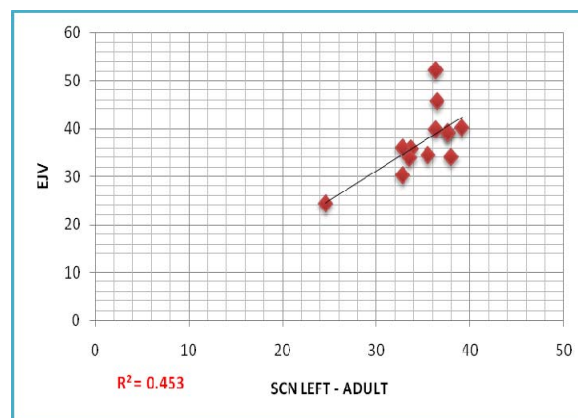


Figure 59: Left adult SCN relation

Key: SCN - Supraclavicular nerve, EJV-External jugular vein

4.7 EMERGING POINTS OF THE SUPERFICIAL CERVICAL PLEXUS

In order to classify the emerging points of the superficial cervical plexus, the sternocleidomastoid muscle was first measured from mastoid process to clavicle; subsequently each branch of the superficial cervical plexus was measured from the mastoid process to their exit points.

The average lengths of sternocleidomastoid muscle in the adult and fetal series were 75.18 ± 2.87 (54.65 – 94.25) and 77.85 ± 2.93 (56.38 – 89.92); and 28.57 ± 3.38 (19.95 – 35.42) and 27.91 ± 3.38 (22.08 – 35.51) for the right and lefts sides respectively (Table 15).

Table 15: Average lengths of the sternocleidomastoid muscle and superficial cervical plexus branches

LENGTHS (mm)	ADULT		FETUSES	
	Right	Left	Right	Left
SCM	75.18	77.85	28.57	27.91
LON	23.59	23.96	11.31	11.55
GAN	24.71	25.73	12.65	13.16
TCN	31.23	31.79	14.79	14.92
SCN	34.93	35.96	16.86	16.88

Key: **SCM** – Sternocleidomastoid muscle, **LON** - Lesser Occipital nerve, **GAN** – Great Auricular nerve, **TCN** – Transverse Cervical nerve, **SCN** – Supraclavicular nerve

The emerging points of the superficial cervical plexus branches were classified according to the seven categories by Kim *et al.*, (2002) (Table 16, Figure 60). The most frequent location was Type I (32%) (Plate 27) and Type III (35%) (Plate 28). The order in which

the superficial cervical plexus branches emerged from the posterior border of the sternocleidomastoid muscle remained constant, i.e. lesser occipital, great auricular, transverse cervical and supraclavicular nerves.

Table 16: Classification of the emerging points of superficial cervical plexus

Pattern of Emergence	Right side (n =54)	Left side (n =54)	Total (108)
TYPE I - LON, GAN, TCN, SCN emerged on middle $\frac{1}{3}$ of SCM	21 (39 %)	14 (26 %)	35 (32%)
TYPE II – LON, GAN, TCN emerged on middle $\frac{1}{3}$ and SCN on lower $\frac{1}{3}$	7 (13 %)	8 (15 %)	15 (13%)
TYPE III – LON emerged on upper $\frac{1}{3}$ and GAN, TCN and SCN on middle $\frac{1}{3}$	14 (26 %)	24 (44%)	38 (35%)
TYPE IV – LON, GAN emerged on upper $\frac{1}{3}$ and TCN and SCN on middle $\frac{1}{3}$	8 (15 %)	6 (11 %)	14 (13%)
TYPE V – LON, GAN, TCN, SCN emerged on upper $\frac{1}{3}$	1 (2 %)	1 (2 %)	2 (2%)
TYPE VI – LON, GAN, TCN emerged on upper $\frac{1}{3}$ and SCN on middle $\frac{1}{3}$	2 (4 %)	-	2 (2%)
TYPE VII – LON, GAN emerged on middle $\frac{1}{3}$ and SCN on lower $\frac{1}{3}$	1 (2 %)	1 (2 %)	2 (2%)

Key: SCM – Sternocleidomastoid muscle, **LON** - Lesser Occipital nerve, **GAN** – Great Auricular nerve, **TCN** – Transverse Cervical nerve, **SCN** – Supraclavicular nerve

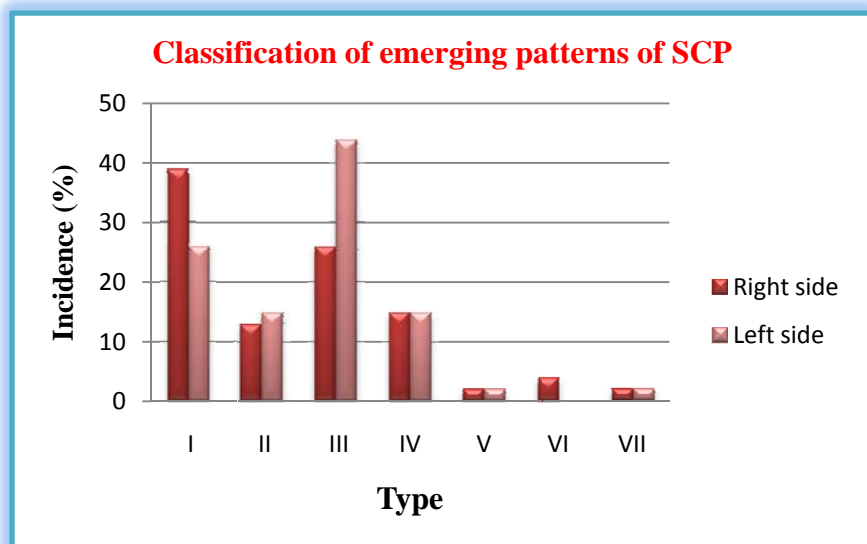


Figure 60: Graphic representation of classification of emerging points of the superficial cervical plexus

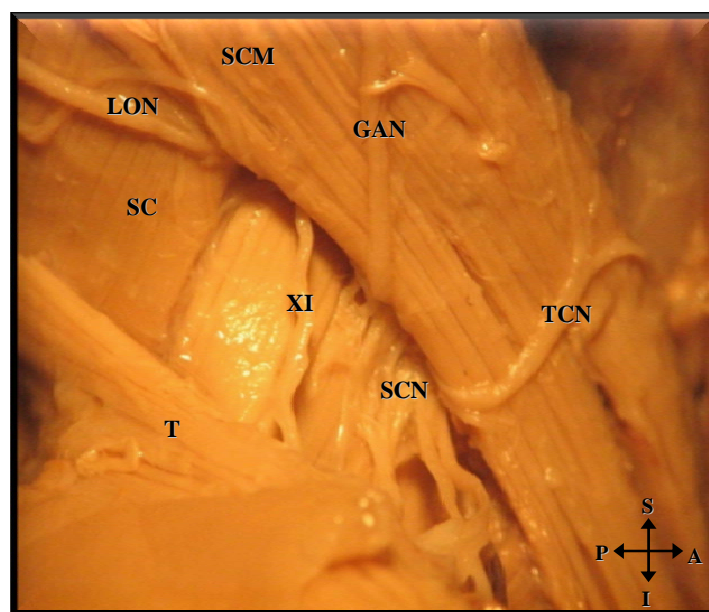


Plate 27: Right anterior view of Type I emerging pattern

Key: LON – lesser occipital nerve, SCM – Sternocleidomastoid muscle, LON - Lesser Occipital nerve, GAN – Great Auricular nerve, TCN – Transverse Cervical nerve, SCN – Supraclavicular nerve, T –Trapezius muscle

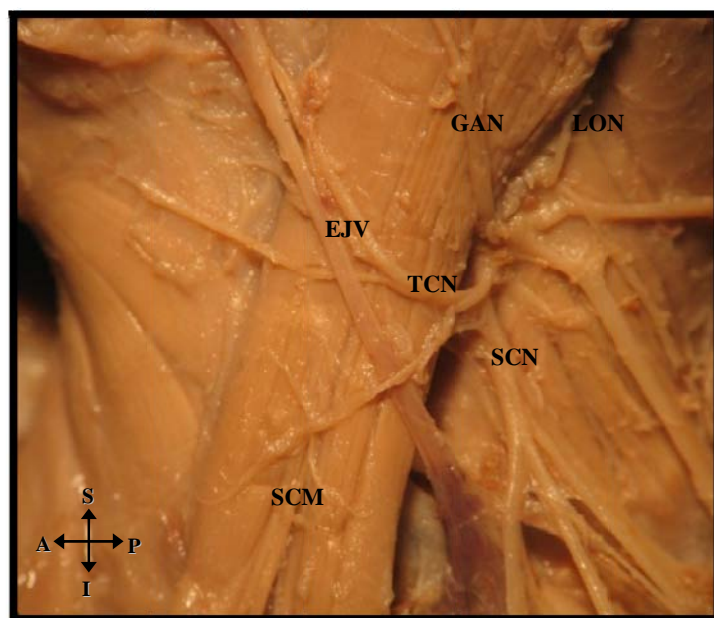


Plate 28 Left anterior view of Type III emerging pattern

Key: LON – lesser occipital nerve, SCM – Sternocleidomastoid muscle Lesser Occipital nerve, GAN – Great Auricular nerve, TCN – Transverse Cervical nerve, SCN – Supraclavicular nerve

4.8 GROSS ANATOMY OF DEEP CERVICAL PLEXUS

The sternocleidomastoid muscle was reflected in order to investigate the emergence of the cervical plexus between the scalene muscles. In all specimens, the ventral rami of the second and third cervical nerves emerged between the scalenus anterior and scalenus medius muscles, the third and fourth cervical nerves was located at the lateral edge of scalenus medius muscle. The accessory nerve crossed the levator scapulae muscle in its descent to the trapezius muscle (Plate 29).

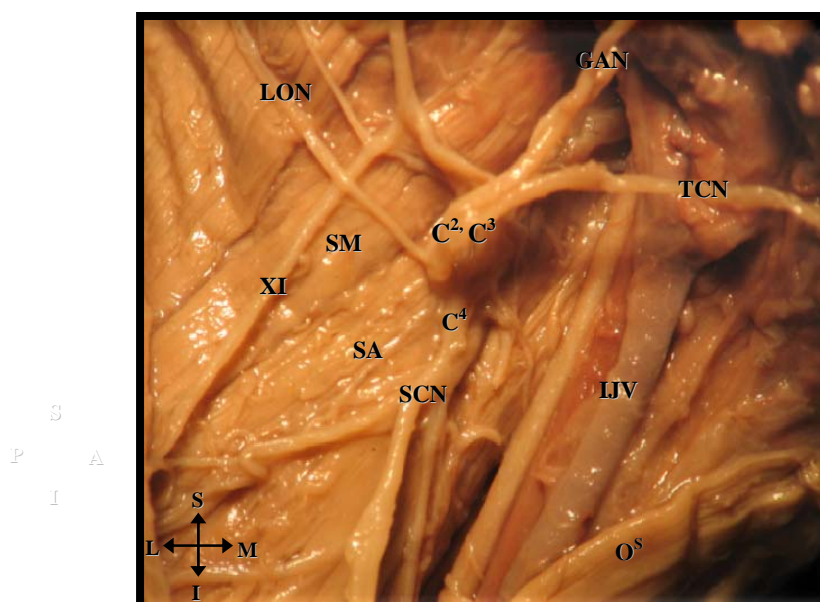


Plate 29: Right anterior view of emergence of cervical nerves between scalenus anterior and scalenus medius muscles

Key: XI – Accessory nerve, C², C³, C⁴ – ventral rami of second, third and fourth cervical nerves, SA – Scalenus anterior muscle, SM – Scalenus medius, LON - Lesser Occipital nerve, GAN – Great Auricular nerve, TCN – Transverse Cervical nerve, SCN – Supraclavicular nerve, IJV – Internal jugular vein, M – Medial, L – Lateral, S – Superior, I – Inferior

4.8.1 MUSCULAR BRANCHES

- i) In $\frac{1}{80}$ (1%) of the fetal specimens it was noted that the third and fourth cervical ventral rami of the cervical plexus together with the accessory nerve supplied the sternocleidomastoid muscle (Plate 30).

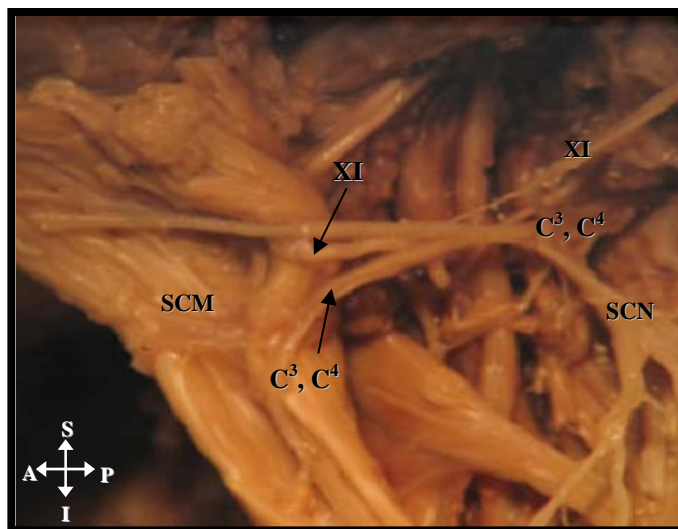


Plate 30: Left anterior view of additional supply to the sternocleidomastoid muscle by the ventral rami of third and fourth cervical nerves

The sternocleidomastoid muscle has been reflected anteriorly to depict the additional branching pattern

Key: XI – Accessory nerve, SCN – Supraclavicular nerve, C³, C⁴ – ventral rami of the third and fourth cervical nerves

- ii) In 78 % ($\frac{84}{108}$) of the specimens investigated, the cervical plexus innervated the scalenus medius and scalenus anterior muscles (Plate 31).

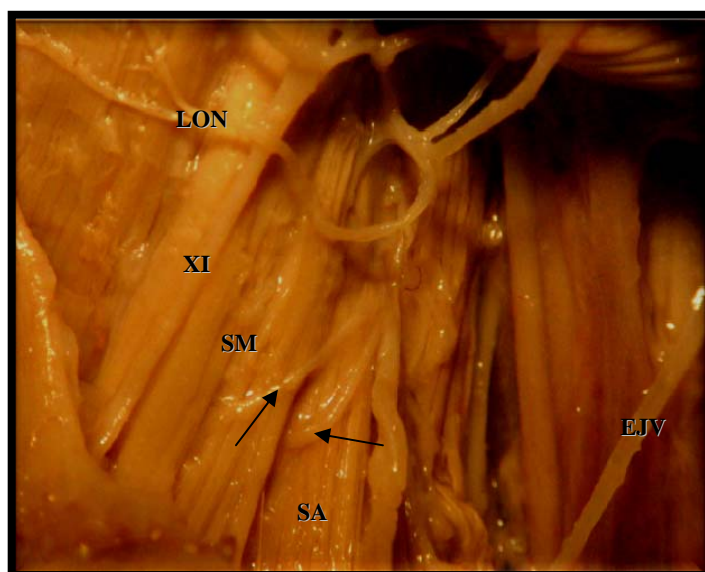


Plate 31: Right anterior view of muscular branches to scalenus medius and scalenus anterior muscles (indicated by arrows)

Key: XI -Accessory nerve, SM - Scalenus medius, LON - Lesser occipital nerve, SA – scalenus anterior, EJV – External jugular vein

4.8.2 ANSA CERVICALIS

The ansa cervicalis was identified in all specimens and demonstrated a degree of variation with regard to its origin and course. It was formed by superior and inferior roots that joined to form a loop.

i) Superior root

The superior root was identified as a long willowy nerve that branched from the hypoglossal nerve. This root descended on the carotid sheath, anterior to the common carotid artery and internal jugular vein (IJV) in 64 % ($^{69}_{108}$): this is classified according

to Yamada (1965) as the medial series (Plate 32); and posterior to IJV in 36 % ($^{39}/_{108}$), as the lateral series (Plate 33).

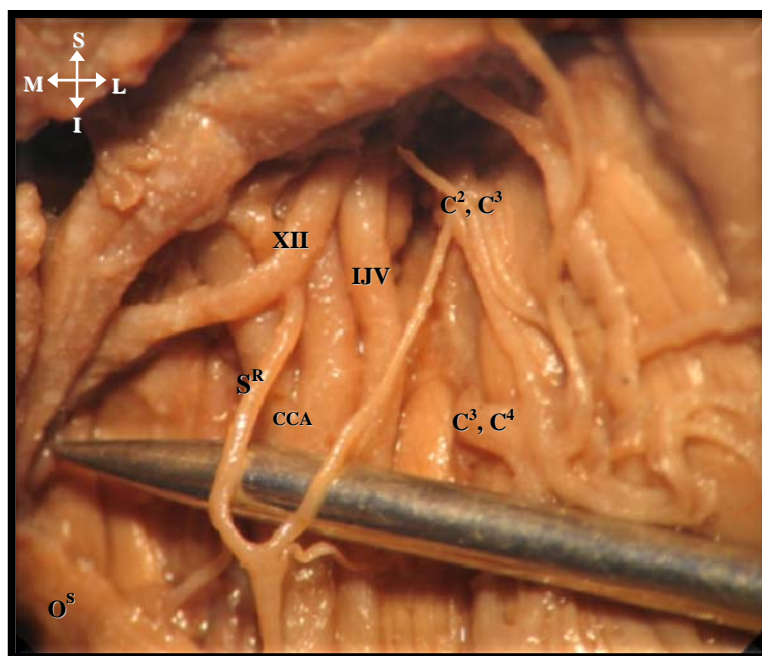


Plate 32: Right anterior view of the medial series ansa cervicalis

Key: XII - Hypoglossal nerve, S^R - Superior root of ansa cervicalis, IJV - Internal jugular vein, O^S - Superior belly of omohyoid muscle, C², C³ - ventral rami of the second and third cervical nerves, C³, C⁴ - ventral rami of the third and fourth cervical nerves, CCA - Common carotid artery

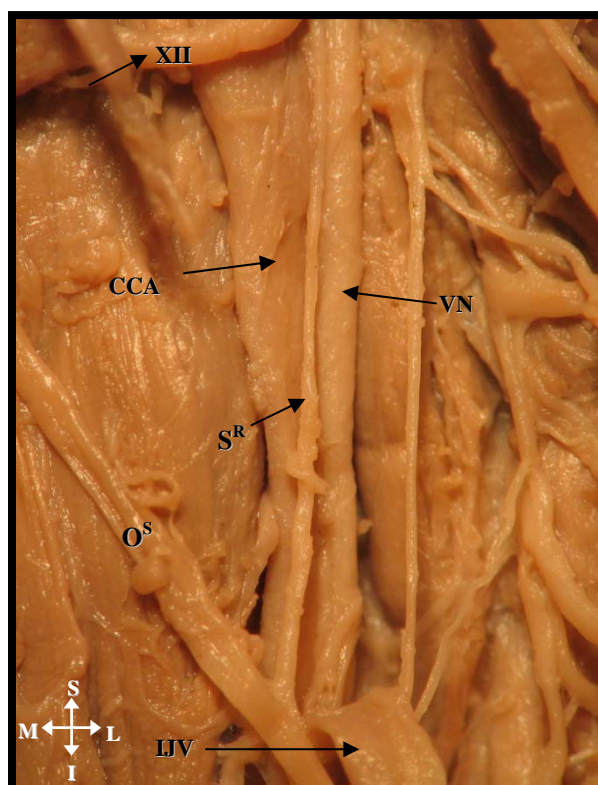


Plate 33: Right anterior view of superior root of ansa cervicalis located posterior to internal jugular vein

The internal jugular vein has been reflected anteriorly to depict the ansa cervicalis

Key: XII - Hypoglossal nerve, S^R – Superior root of AC, CCA – Common carotid artery, VN – Vagus nerve, O^S – Superior belly of omohyoid muscle, IJV – Internal jugular vein

ii) Inferior root

The inferior root of ansa cervicalis was derived from the cervical ventral rami of C2 and C3 in 26% ($^{28}/_{108}$) (Plate 34), from ventral ramus of C3 in 58% ($^{63}/_{108}$) and from the ventral ramus of C2 in 16% ($^{17}/_{108}$) (Plate 35) (Figure 61).

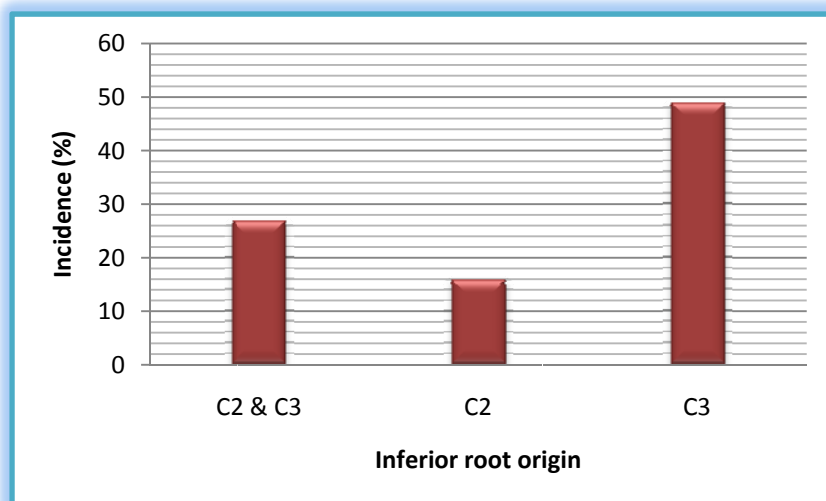


Figure 61: Graphic representation of the origin of the inferior root of ansa cervicalis

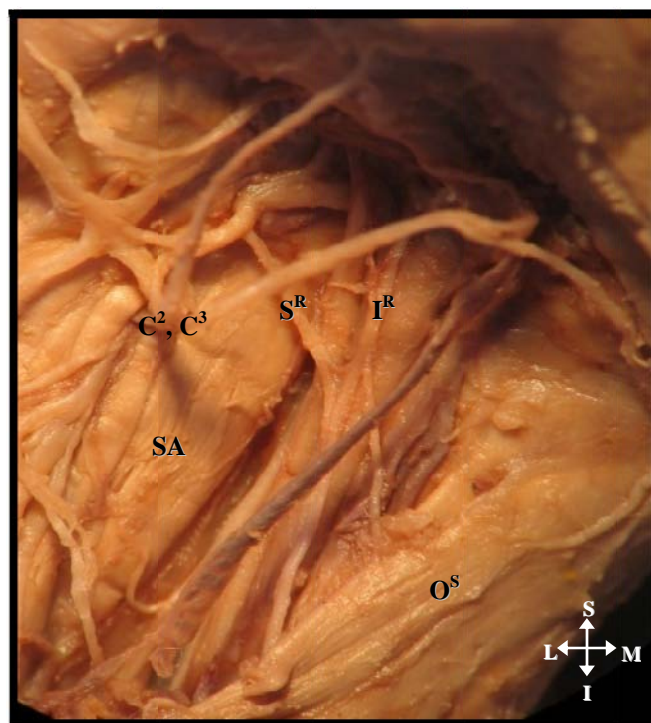


Plate 34: Right anterior view of origin of inferior root from ventral rami of second and third cervical nerves (indicated by arrow)

Key: S^R – Superior root of ansa cervicalis, I^R – Inferior root of ansa cervicalis
 C², C³ - ventral rami of second and third cervical nerve, SA –Sclenus anterior, O^S – Superior belly of omohyoid muscle

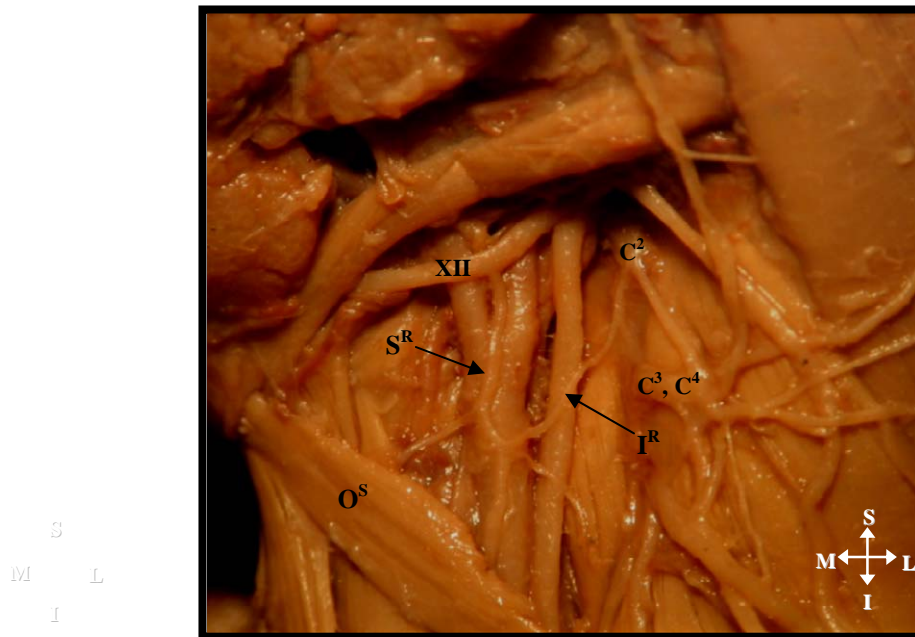


Plate 35: *Left anterior view of origin of inferior root from the ventral ramus of the second cervical nerve*

Key: XII - Hypoglossal nerve, S^R – Superior root of ansa cervicalis, I^R – Inferior root of ansa cervicalis, C² – ventral rami of second cervical nerve, C³, C⁴ - ventral rami of third and fourth cervical nerves, O^S – Superior belly of omohyoid muscle

The superior and inferior roots join to form a loop. The ansa cervicalis was classified as either long or short according to Loukas et al., (2007). In this study the majority of the specimens [adults: $\frac{17}{28}$, (61%); fetuses: $\frac{63}{80}$, (79%)] depicted the pattern of a short ansa cervicalis whereby the loop was located superior to the superior belly of omohyoid muscle (indicated by arrow). The ansa cervicalis innervated the omohyoid and sternothyroid muscles (Plate 36).

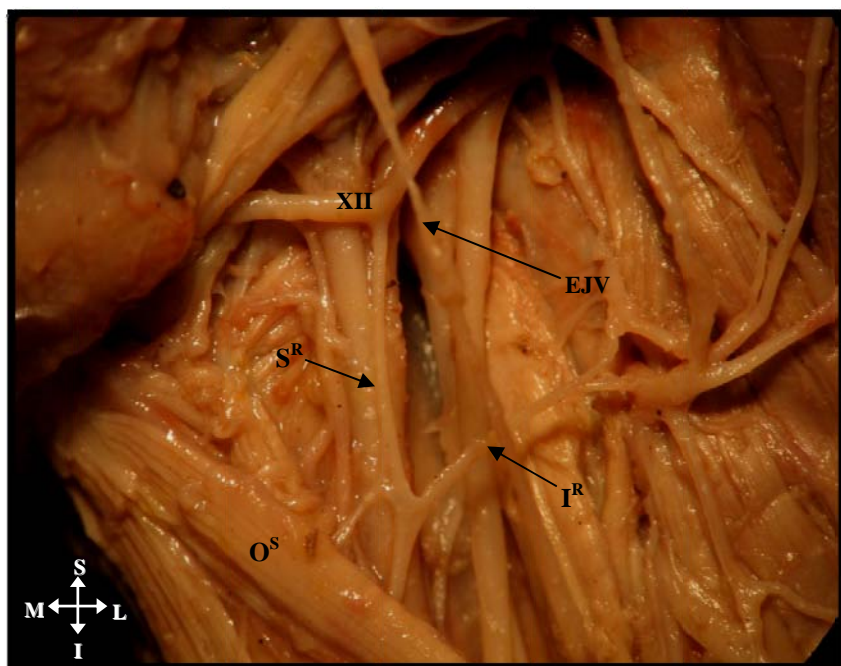


Plate 36: Left anterior view of short ansa cervicalis and muscular branches from the loop of ansa cervicalis

Key: XII - Hypoglossal nerve, S^R – Superior root of ansa cervicalis, I^R – Inferior root of ansa cervicalis, O^S – Superior belly of omohyoid, EJV – External Jugular vein

4.8.2.1 VARIATIONS

i) In $2/80$ (3%) of the fetal specimens, the ansa cervicalis had a classic double form with two separate roots (indicated by dotted square). The superior root of the first loop received the normal contribution from hypoglossal and the inferior root was formed by the ventral rami of the second cervical nerve.

The second loop was formed from a continuation of the superior root and the ventral rami of the third cervical nerve (Plate 37).

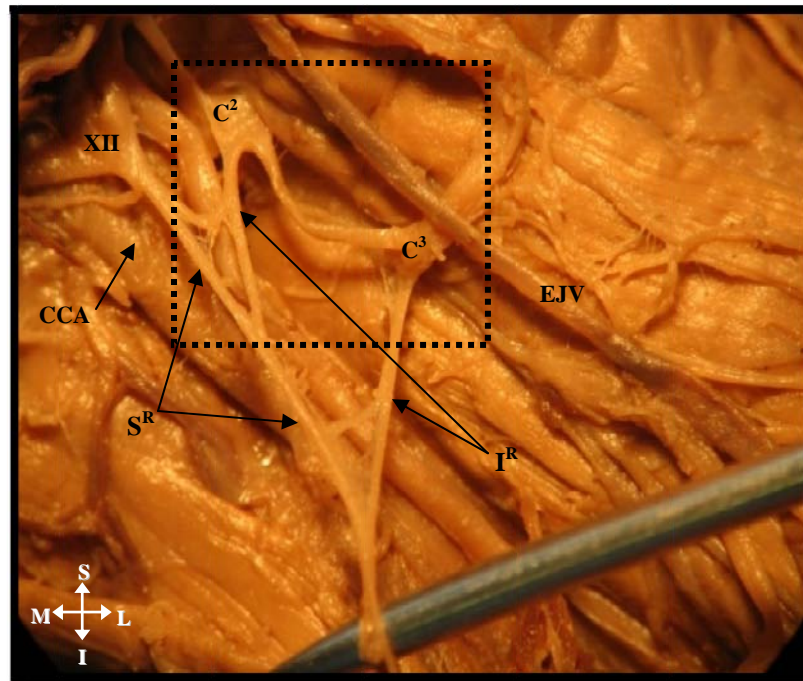


Plate 37: Double classic form of the ansa cervicalis with two separate roots

Key: XII - Hypoglossal nerve, S^R – Superior root of ansa cervicalis, I^R – Inferior root of ansa cervicalis,
 EJV – External Jugular vein, C^2 - ventral rami of second cervical nerve,
 C^3 - ventral rami of third cervical nerve

- ii) In $\frac{1}{80}$ (1%) of the fetal specimens, the superior root of the ansa cervicalis received a contribution from the hypoglossal nerve, a short distance later it formed a loop around the internal jugular vein to ascend to the ventral rami of the second cervical nerve as the inferior root (indicated by dotted square) (Plate 38).




Plate 38: *Right anterior view of unusual loop of the ansa cervicalis*

Key: XII - Hypoglossal nerve, S^R – Superior root of ansa cervicalis, SCH – Sympathetic chain, IJV – Internal Jugular vein, C², C³ - ventral rami of second and third cervical nerves, SCN – Supraclavicular nerve, LON – Lesser occipital nerve

- iii) In $\frac{1}{80}$ (1%) of the fetal specimens analysed the ansa cervicalis formed a “W” shaped appearance above the superior belly of omohyoid (indicated by arrow). This was formed by a dual contribution from the hypoglossal nerve that was located parallel to each other on the common carotid artery. The inferior root was formed by cervical ventral rami of the third cervical nerve (Plate 39).

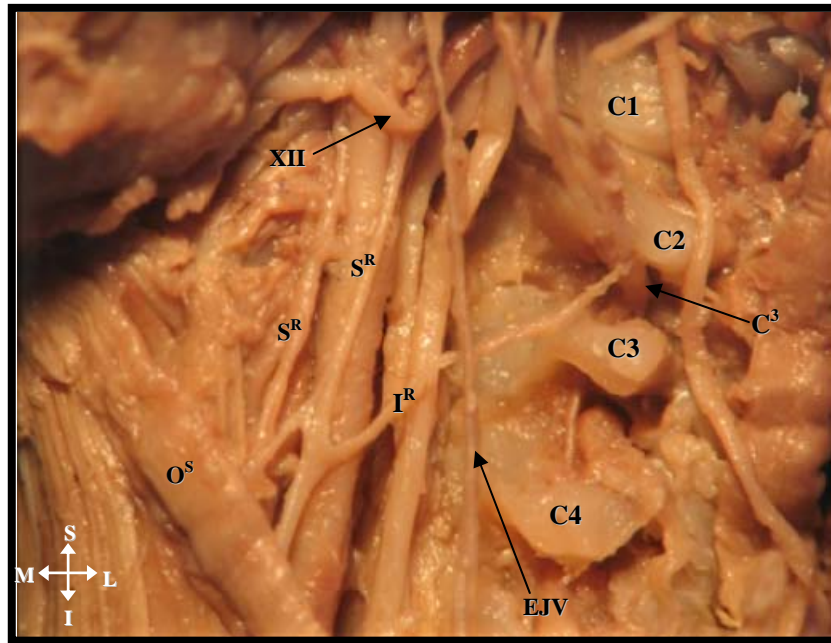


Plate 39: Left anterior view of dual contribution from hypoglossal nerve

Key: XII - Hypoglossal nerve, S^R – Superior root of ansa cervicalis, I^R – Inferior root of ansa cervicalis, C³ – ventral rami of the third cervical nerve, C1,2,3,4 – First, second, third and fourth cervical vertebrae, EJV – External jugular vein, O^S – Superior belly of omohyoid muscle

iv) According to the classification by Verma *et al.*, (2005), a “vago-cervical complex” was recorded in $\frac{2}{80}$ (3%) of the fetal specimens. This complex is formed by a contribution from the vagus nerve, as well as by a contribution from the hypoglossal nerve (indicated by square) (Plate 40 and 41) to the ventral rami of the first and second cervical nerves: from these contributions a single superior root is formed.

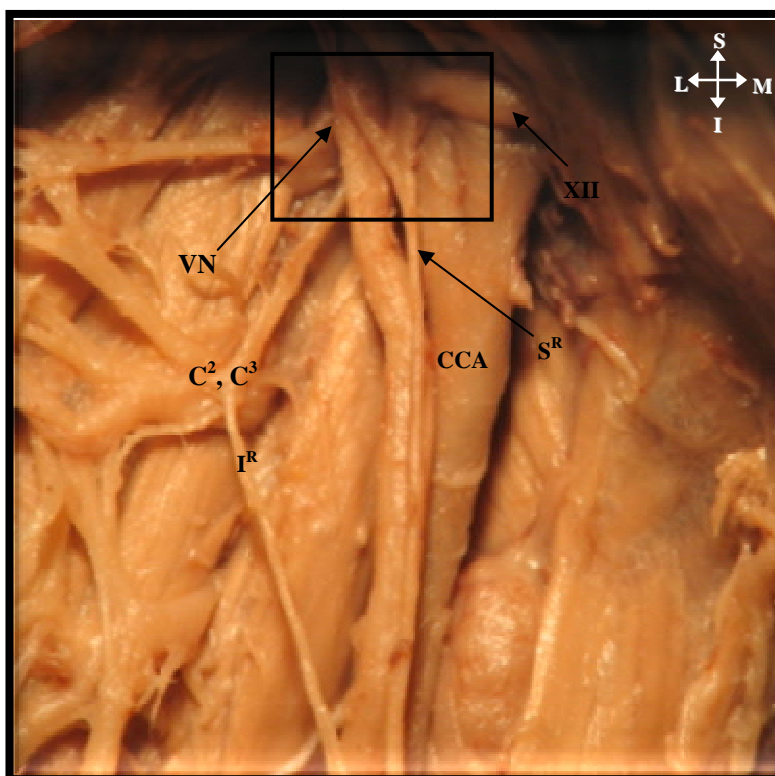


Plate 40: Left anterior view of the “vago-cervical complex”

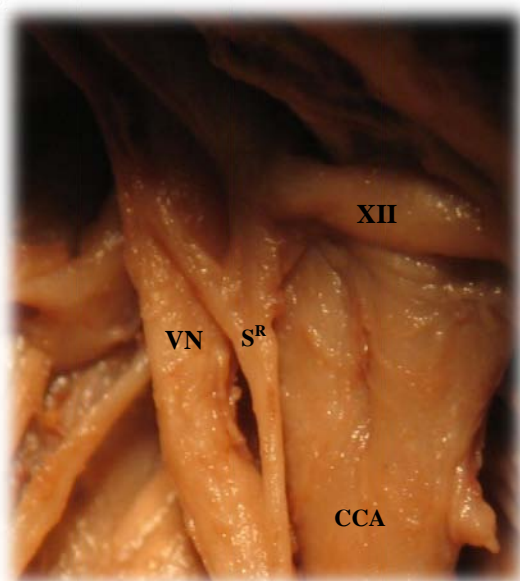


Plate 41: Left anterior view of the “vago-cervical complex”

Common Key: VN – Vagus nerve, XII – Hypoglossal nerve, S^R – Superior root of ansa cervicalis, I^R – Inferior root of ansa cervicalis, CCA – Common carotid artery, C², C³ – ventral rami of the second and third cervical nerves

4.8.3 PHRENIC NERVE

The phrenic nerve investigated in this study arose from the ventral rami of the third and fourth and fifth cervical nerves. In 100% of the adult and fetal specimens, the phrenic nerve began at the superior part of the lateral border of the anterior scalene muscle (Plate 42).

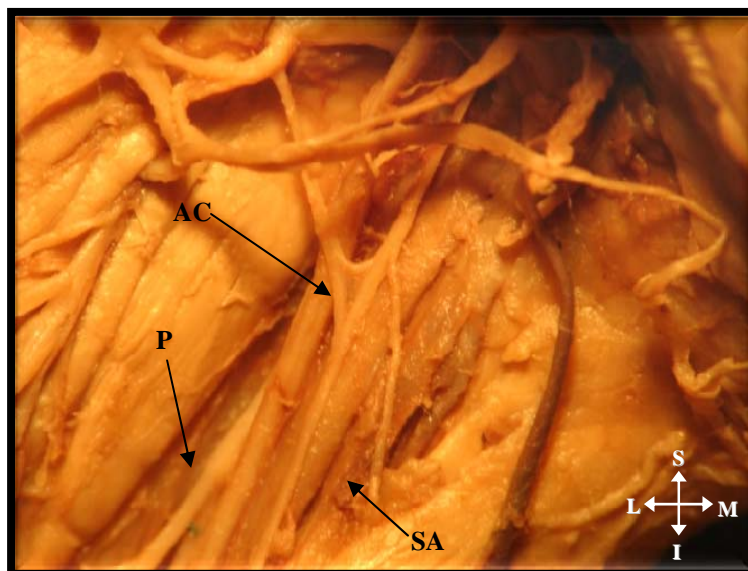


Plate 42: *Left anterior view of phrenic nerve lateral to anterior scalene muscle*

Key: P – Phrenic nerve, SA– Scalenus anterior, AC – Ansa cervicalis

4.9. COMMUNICATING BRANCHES

In all the adult and fetal specimens investigated, each cervical ventral ramus received a grey ramus communicans from the superior cervical ganglion which was consistently located opposite the second and third cervical vertebra. The number of branches from the superior cervical ganglion to the cervical nerves varied from one to a maximum of four. In the majority of the specimens, the superior cervical ganglion communicated with

the ventral ramus of the second cervical nerve (indicated by dotted square) (Plate 43 and 44).

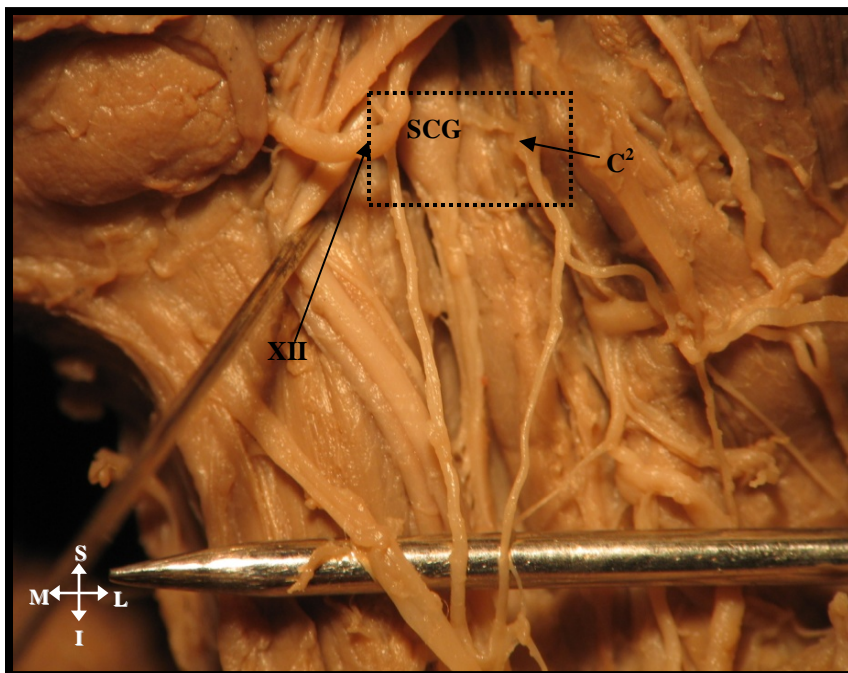


Plate 43: *Right superior view of the superior cervical ganglion communication with ventral rami of second cervical nerve*

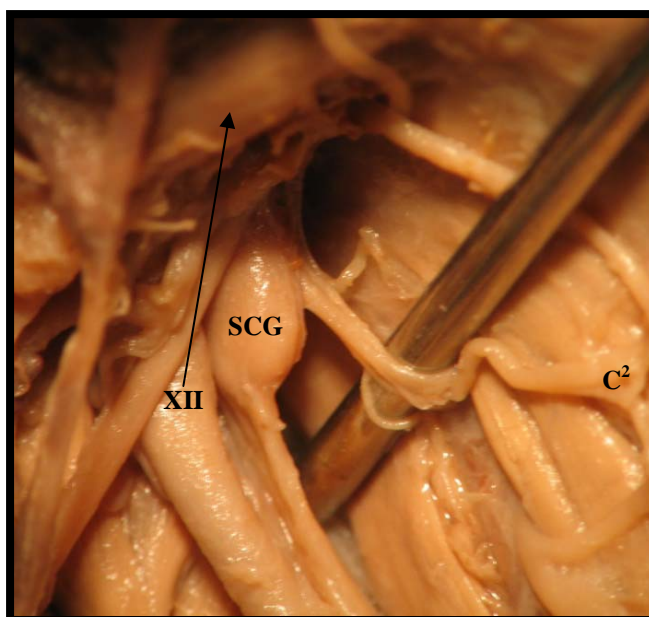


Plate 44: *Magnified view of the right superior view of the superior cervical ganglion communication with ventral rami of second cervical nerve*

Common Key: SCG – Superior cervical ganglion, C² – Second cervical nerve, XII – Hypoglossal nerve

4.10. ROOT FORMATION OF CERVICAL PLEXUS

The cervical plexus is a complex structure formed by the ventral rami of the upper four cervical nerves and emerges through a compartment formed between the tubercles of the cervical vertebrae and between the anterior and posterior scalene muscles (Plate 45).

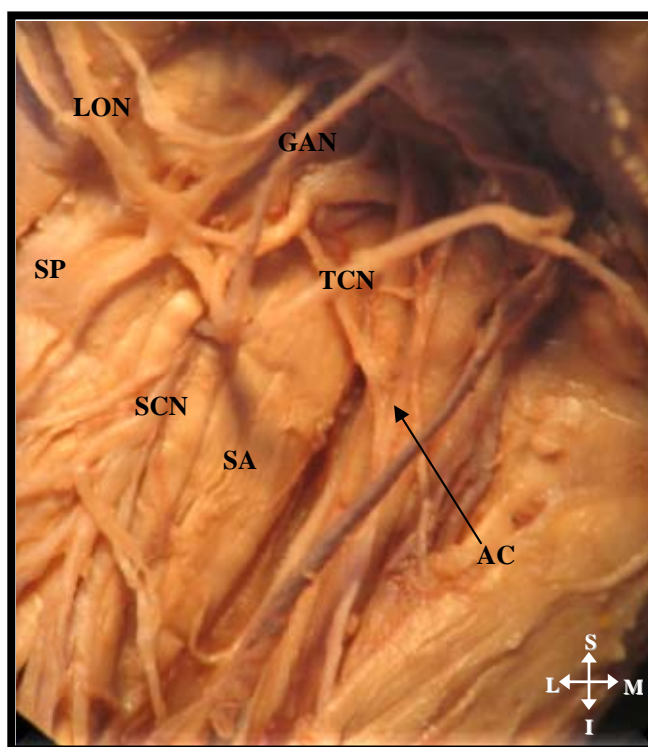


Plate 45: Right anterior view of cervical plexus emerging between the scalene muscles

Key: SP – Scalenus posterior, SA – Scalenus anterior, LON – Lesser occipital nerve, GAN – Great auricular nerve, TCN – Transverse cervical nerve, SCN – Supraclavicular nerve, AC – Ansa cervicalis

The scalene and deeper muscles of the neck were removed in order to trace the root value of the cervical plexus branches.

The lesser occipital nerve was derived from the ventral ramus of the second cervical nerve [C^2 in $\frac{9}{28}$ (32%) of the adult and $\frac{61}{80}$ (76%) fetal specimens]; and from the ventral ramus of the second and third cervical nerves [C^2 - C^3] in $\frac{21}{28}$ (75%) adult and $\frac{19}{80}$ (24%) fetal specimens.

The great auricular nerve was derived from the ventral ramus of the second and third cervical nerves [C^2 - C^3] in $^{18}/_{28}$ (64%) adults and $^{21}/_{80}$ (26%) fetuses, and from the ventral ramus of the third cervical nerve [C^3] in $^{10}/_{28}$ adults and $^{59}/_{80}$ (74%) fetuses.

The transverse cervical nerve was derived from the ventral ramus of the second and third cervical nerves [C^2 - C^3] in $^{12}/_{28}$ (43%) adults and $^{34}/_{80}$ (43%) fetuses, and from the ventral ramus of the third cervical nerve [C^3] in $^{16}/_{28}$ (57%) adults and $^{46}/_{80}$ (57%) fetuses.

The supraclavicular nerve was derived from the ventral ramus of the third and fourth cervical nerves [C^3 - C^4] in $^{28}/_{28}$ (100%) adults and $^{45}/_{80}$ (56%) fetuses, and from the ventral ramus of the fourth cervical nerve [C^4] in $^{35}/_{80}$ (44%) fetuses.

In all adult and fetal specimens the ventral rami of each cervical nerve was found lateral to the vertebral artery. Each of these cervical nerve roots received a grey ramus communicans from the superior cervical ganglion.

The accessory nerve was identified as it passed over the second cervical vertebra. The cervical nerves emerged as a common trunk from within the transverse foramen: it divided into lesser occipital, great auricular, transverse cervical and supraclavicular nerves (Plate 46). The inferior root of the ansa cervicalis arose from the ventral ramus of the third cervical nerve.

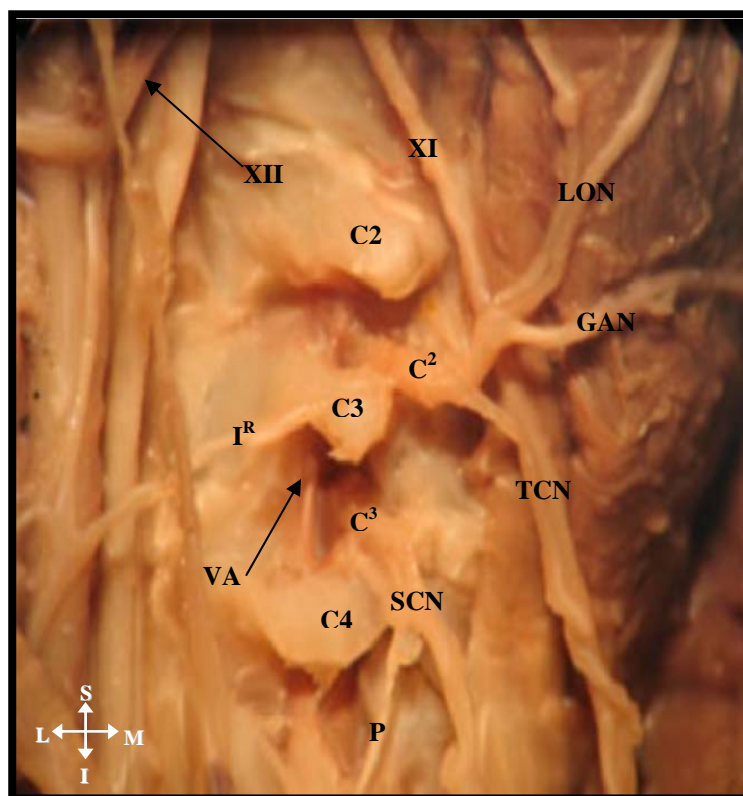


Plate 46: Right deep dissection depicting root value of the cervical nerve

Key: LON – Lesser occipital nerve, GAN – Great auricular nerve, TCN – Transverse cervical nerve, SCN – Supraclavicular nerve, C2, 3, 4 – second, third and fourth cervical vertebrae, C² – C³ – ventral rami of the second and third cervical nerves, I^R – Inferior root of AC, P – Phrenic nerve, VA – Vertebral artery, XI – Accessory nerve, XII – Hypoglossal nerve

The ventral ramus of the first cervical nerve [C1] was noted to descend in front of the transverse process of the atlas to form a loop with the ascending branch of the ventral ramus of the second cervical nerve [C2]. Subsequently, C2 formed a loop with the ventral rami of the third cervical nerve [C3] and C3 formed a loop with the ventral rami of the fourth cervical nerve [C4] (Plate 47). In addition, it was observed that fibres in the loop between C1 and C2 ran forward to join the hypoglossal nerve.

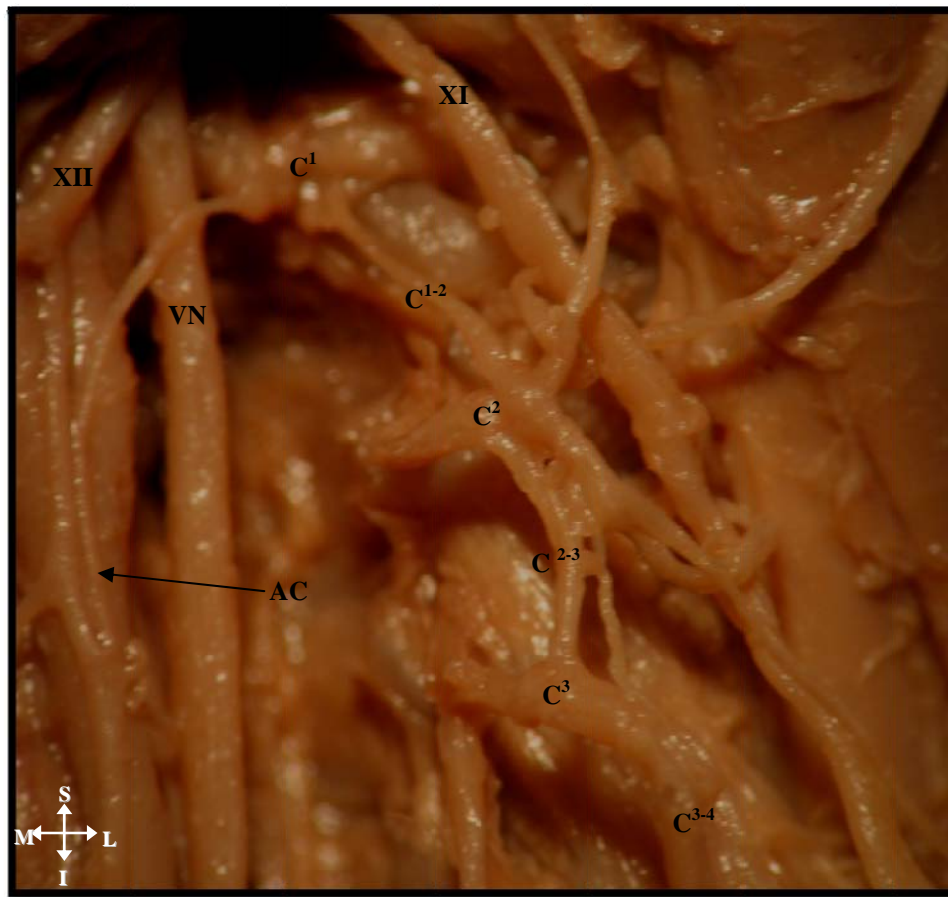


Plate 47: Left view of a deep dissection showing the formation of loops between cervical nerves

Key: C1- C2 – C³ – C⁴ – ventral rami of the first, second, third and fourth cervical nerves, C¹⁻² – loop between ventral rami of third and second cervical nerves, C²⁻³ – loop between ventral rami of second and third cervical nerves, AC – Ansa cervicalis, XII –Hypoglossal nerve, XI –Accessory nerve, VN -Vagus nerve

In $\frac{3}{80}$ (4%) of the fetal specimens lesser occipital, great auricular, transverse cervical and supraclavicular nerves emerged from the cervical ventral ramus of the second cervical nerve (Plate 48). The accessory nerve crosses the lesser occipital nerve.

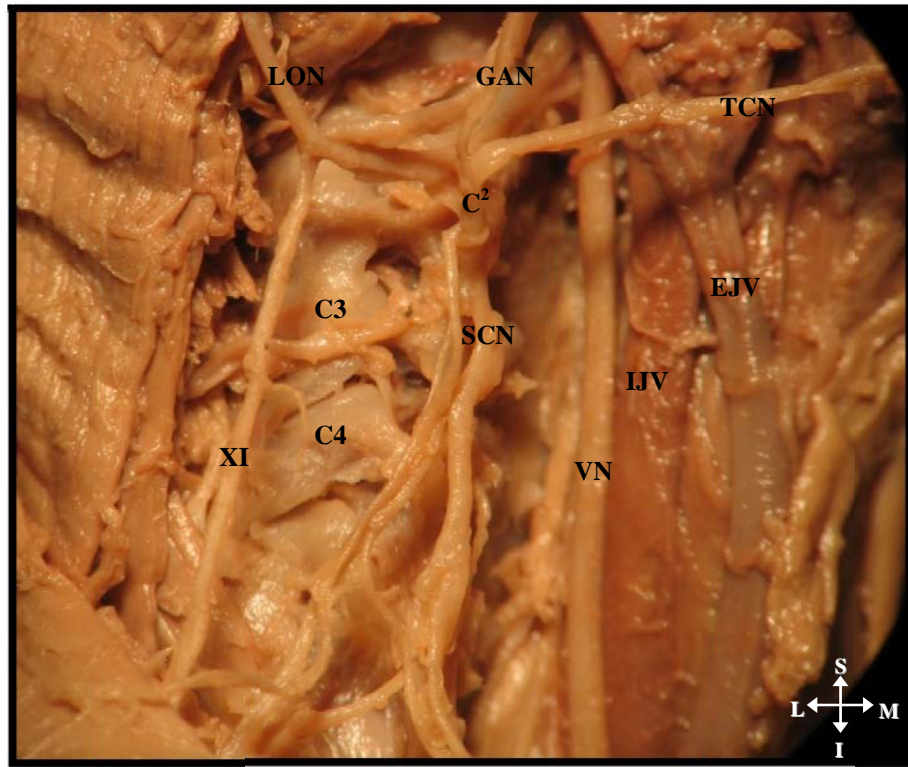


Plate 48: Right view of deep dissection depicting origin of lesser occipital, great auricular, transverse cervical and supraclavicular nerves from the ventral ramus of second cervical nerve

Key: C² – ventral ramus of the second cervical nerve, C³ – third cervical vertebra, C⁴ – Fourth cervical vertebra, XI – Accessory nerve, GAN – Great auricular nerve, TCN – Transverse cervical nerve, SCN – Supraclavicular nerve, LON – Lesser occipital nerve, VN- Vagus nerve, EJV – External jugular vein, IJV – Internal jugular vein

4.11 VARIATIONS OF THE EXTERNAL JUGULAR VEIN

i) In $\frac{3}{80}$ (4%) of the fetal specimens there was an “X” or “H” shaped formation of the external jugular vein, with 2 tributaries lying superior to the supraclavicular nerve branches and 2 tributaries lying on the sternocleidomastoid muscle. The transverse cervical nerve intertwined with the external jugular vein (Plate 49). In the specimens with the external jugular vein variations, the internal jugular had an anomalous appearance (Plate 50).

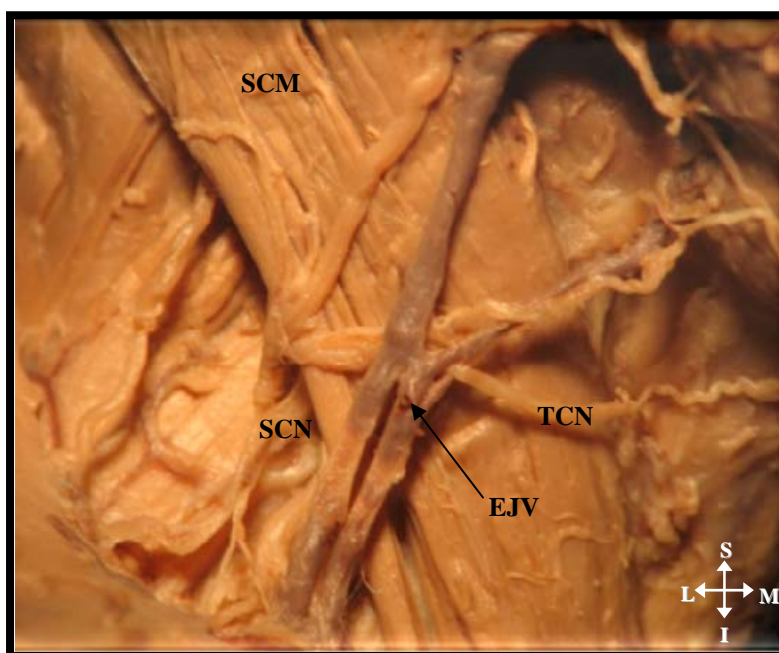


Plate 49: Right anterior view of the “X” or “H” shaped appearance of the external jugular vein

Key: TCN – Transverse cervical nerve, SCN – Supraclavicular nerve, EJV – External jugular vein, SCM – Sternocleidomastoid muscle

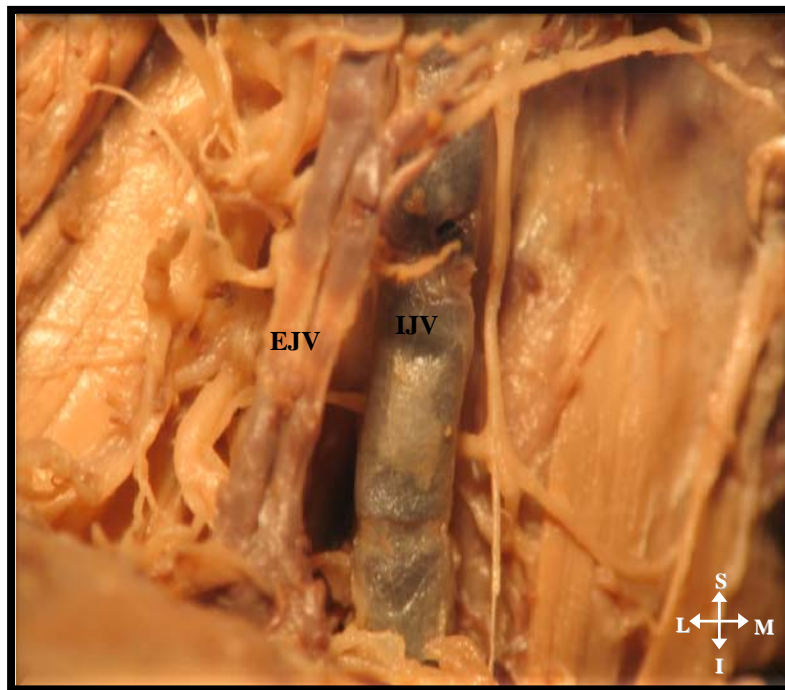


Plate 50: *Right anterior view of an anomalous appearance of internal jugular vein*

Key: IJV – Internal jugular vein, EJV – External jugular vein

- ii) In $\frac{14}{80}$ (18%) fetal specimens, duplication of the external jugular vein was observed on the anterior border of the sternocleidomastoid muscle. The transverse cervical nerve was located posterior to the external jugular vein (Plate 51).

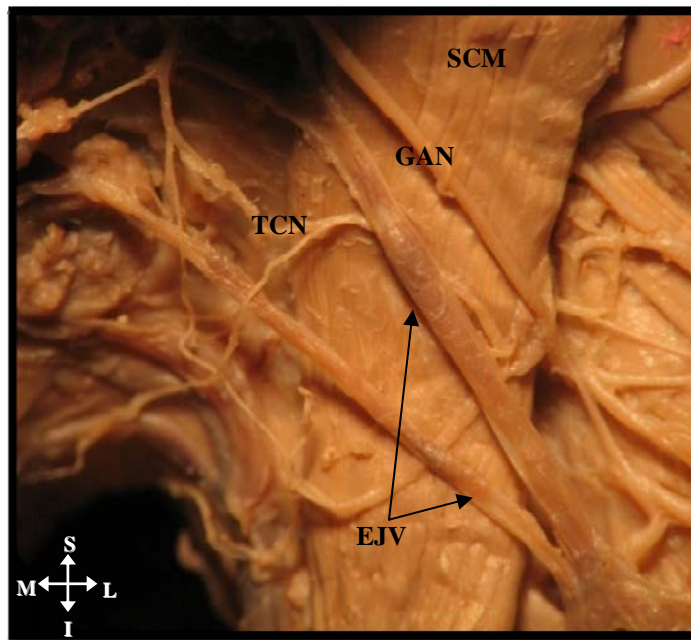


Plate 51: Left anterior view of duplication of the external jugular vein

Key: TCN – Transverse cervical nerve, EJV – External jugular vein, SCM – Sternocleidomastoid muscle, GAN- Great auricular nerve, TCN – Transverse cervical nerve

4.12 VARIATIONS OF THE INTERNAL JUGULAR VEIN

i) In $\frac{1}{80}$ (1%) of the fetal specimens the internal jugular vein had a “Y” shaped appearance. The upper part of the superior root of the ansa cervicalis was lying at the junction of the “Y” (indicated by arrow) and a lower part was located medial to the internal jugular vein (Plate 52).

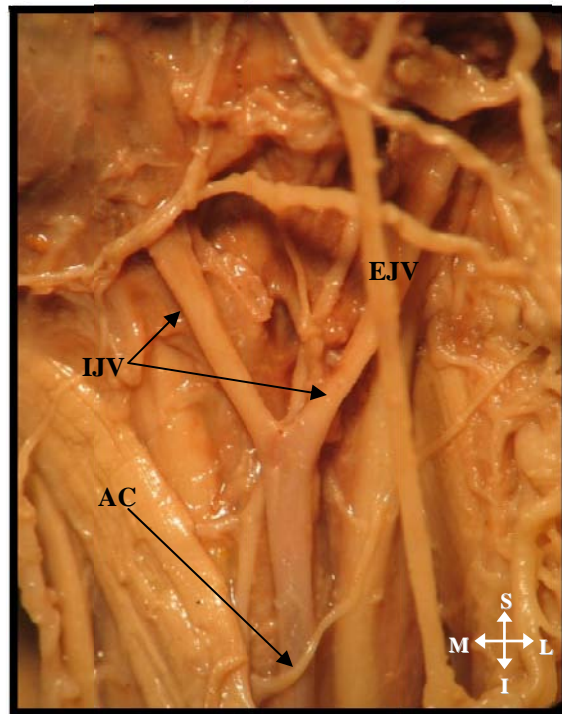


Plate 52: Left anterior view of the “Y” shaped appearance of internal jugular vein

Key: IJV – Internal jugular vein, EJV – External jugular vein, AC – Ansa cervicalis

- ii) In $\frac{2}{80}$ (3%) of the fetal specimens, the internal jugular vein divided into two and received a tributary from the external jugular vein superiorly (indicated by dotted square) and inferiorly. The ansa cervicalis looped around the lower end of the internal jugular vein (Plate 53).

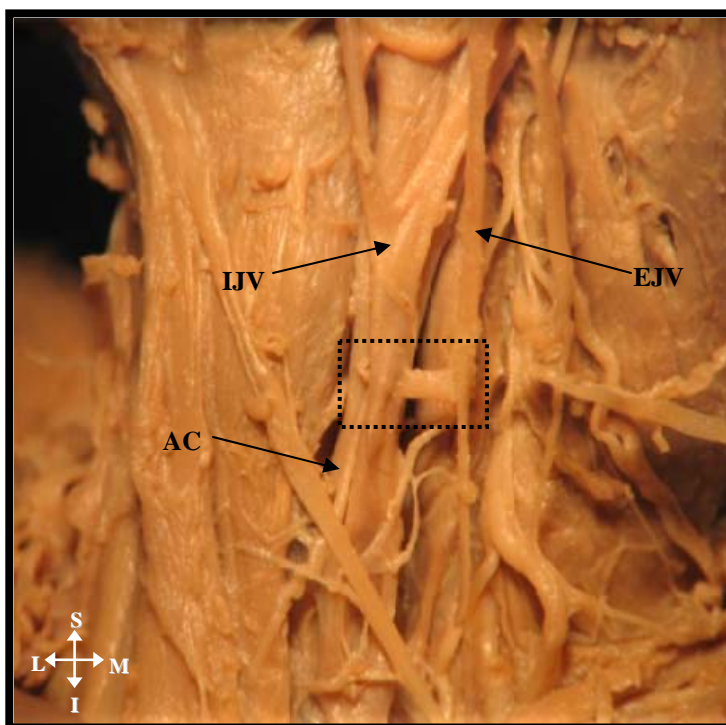


Plate 53: *Left anterior view of the dual communication between internal jugular and external jugular veins*

Key: IJV – Internal jugular vein, EJV – External jugular vein, AC – Ansa cervicalis

5.1 SAMPLE

This study utilized fifteen adult and forty fetal cadavers. This may raise the question as to why a comparatively smaller series of adults were used when compared to the fetal series. This is due to the shortage of adult cadaveric material currently made available for research. An unexpected advantage to this set of circumstances is that a detailed description of the anatomy of the cervical plexus in fetuses in the literature surveyed, is sparse. Furthermore, it is of interest to note that the anatomical variations recorded in this investigation were found only in fetal specimens.

5.2 GROSS ANATOMY

The cervical plexus is seen as an intricate formation by the upper four cervical nerves. In this study, the superficial cervical plexus was described according to that of Standring *et al.*, (2008) viz. ascending and descending branches. These branches viz. lesser occipital, great auricular, transverse cervical and supraclavicular nerves were observed as it pierced the cervical fascia to emerge like “spokes from a wheel” from the posterior border of the sternocleidomastoid muscle.

The point at which the nerves emerge is a matter of some controversy, with standard anatomical texts referring to it as the “Erb’s point” and the surgical texts referring to it as the “great auricular point”. It is proposed that in order to avoid confusion, the point where the branches of superficial cervical plexus emerge be referred to as the great auricular point. This may allow simple and reliable identification of the branches as they emerge. According to Hone *et al.*, (2001) “Erb’s point” refers to the surface marking of the upper trunk of brachial plexus and may not be as reliable.

5.3 SUPERFICIAL CERVICAL PLEXUS

5.3.1 LESSER OCCIPITAL NERVE

The lesser occipital nerve consistently emerged from beneath the posterior border of the sternocleidomastoid muscle after it pierced the deep cervical fascia. This was in accordance with the standard anatomical description (Standring *et al.*, 2008). It was located superior to the great auricular nerve in all specimens, similar to the results obtained by Pantaloni and Sullivan (2000). In its ascent towards the scalp, mastoid region and superior third of ear, the lesser occipital nerve crossed over the levator scapulae and splenius capitis muscles in 89% of the specimens (Table 17). In addition, the lesser occipital nerve was constantly located in the area around the mastoid process, which was reported to be an area that is referred to as the “trigger” point of cervicogenic headaches by Fredriksen (1987) and Lucas *et al.*, (2004). In this investigation it was found that the lesser occipital nerve was located in this anatomical area; therefore it is possible that the lesser occipital nerve may play a role in cervicogenic headaches, as described by the previous authors.

Table 17: *Origin and distribution of the superficial cervical plexus*

Author (Year)	Sample size	Lesser occipital nerve on splenius capitis muscle	Lesser occipital nerve on sternocleidomastoid muscle
Lucas <i>et al.</i> , (1994)	16	$\frac{16}{16}$ (100%)	0
Pantaloni and Sullivan (2000)	19	$\frac{3}{19}$ (16%)	$\frac{16}{19}$ (84%)
Current study	108	$\frac{96}{108}$ (89 %)	$\frac{12}{108}$ (11%)

In the majority of the fetal specimens (76%) the lesser occipital nerve arose from the ventral ramus of the second cervical nerve (C2) concurring with Berry *et al.*, (1995). In the majority of

the adults (75%), it arose from the ventral rami of the second and third cervical nerves (C2- C3) concurring with Madhavi and Holla (2004) and Standring *et al.*, (2008). Knowledge of the variable origin of the lesser occipital nerves may assist in the understanding of cervicogenic headaches caused by neck movements as described by Madhavi and Holla (2004).

The lesser occipital nerve in this investigation was depicted as single, duplicate and triplicate branching patterns; the single pattern being the most frequent in adults ($\frac{28}{28}$; 100%) and fetuses ($\frac{56}{80}$; 70%). The duplicate branching pattern ($\frac{21}{80}$; 26%) was found only in the fetal specimens. However, in the studies conducted by Lucas *et al.*, (1994) and Pantaloni and Sullivan (2000) on adult cadavers, duplication of the lesser occipital nerve was reported in ($\frac{6}{16}$; 38%) and ($\frac{13}{19}$, 68%) of their specimens respectively. In this study, $\frac{3}{80}$ (4%) fetal specimens depicted triplicate lesser occipital nerves that had a “tree like” appearance. The description of the triplicate branches vary among authors such as Ellis and Fieldman (1993) that referred to these branches as “auricular, mastoid and occipital”, Berry *et al.*, (1995) as “anterior, posterior and auricular”, and Madhavi and Holla (2004) as “LON I, LON II and LON III”. The description of Madhavi and Holla (2004) was utilized to classify the triplicate pattern.

The areas of innervation associated with the single, duplicate and triplicate branches are the posterolateral aspect of the scalp; superior third of the ear and the area over the mastoid region, and the occipital region, respectively.

Of interest, the lesser occipital nerve supplied the superior two-thirds of the ear in $\frac{12}{80}$ (15%) of the fetal specimens only which concurs with the study by Pantaloni and Sullivan in (2000) in $\frac{5}{19}$ (26%) adult specimens. It has been suggested by the latter author that knowledge of this

innervation is of importance during facial rejuvenation surgery because inadvertent injury to the lesser occipital nerve may result in sensory dysfunction of the ear.

Dash *et al.*, (2005) in a study on the lesser occipital nerve's involvement with migraine pain relief, suggested that due to the lesser occipital nerves variable location, anesthetic blockade may be difficult because of its branching patterns. Therefore they suggested that an effective location for lesser occipital nerve blockage be a “proximal” site, which according to their descriptions is the area below the external auditory canals. Their study concurred with the findings by Bescer *et al.*, (1998). In this study, it was found that the lesser occipital nerve was located in this anatomical region supporting the findings by Bescer *et al.*, (1998) and Dash *et al.*, (2005).

5.3.2 GREAT AURICULAR NERVE

The great auricular nerve is an ascending branch of the superficial cervical plexus that pierces the investing layer of cervical fascia, to emerge from beneath the posterior border of the sternocleidomastoid muscle. It then had a superficial antero-superior course on the sternocleidomastoid muscle, crossing it diagonally to penetrate the parotid gland. This anatomical description concurs with that of Standring *et al.*, (2008). In addition, in its course the great auricular nerve was constantly parallel to the transverse cervical nerve and the external jugular vein. It has been reported by Zohar *et al.*, (2002) that the anatomical descriptions of the great auricular nerve vary: it has been described as a sensory nerve by Zohar (2002), “a superficial nerve supplying the skin” by Hollingshead (1982) and as a nerve “terminating in the external fascia of the parotid gland” by Moore and Dally (1992). The results obtained in this study concur with Moore and Dally (1999).

In addition, Yokoshima *et al.*, (2004), stated that the great auricular nerve is considered a significant anatomical landmark to identify structures such as the accessory nerve. This allows for easy identification of the accessory nerve in the posterior triangle of the neck and may be a useful to reduce the risk of surgical injury.

In this investigation the great auricular nerve arose predominantly from a common trunk with the lesser occipital nerve which arose from the second and third cervical ventral rami in adults [$^{18}/_{28}$ (64%)]; and from the third cervical ventral ramus in fetuses [$^{59}/_{80}$ (74%)] which correlates with standard anatomical (Standring *et al.*, 2008) and some surgical (Biglioli *et al.*, 2002) texts.

In the presence of the single branching pattern, the great auricular nerve emerged from beneath the posterior border of the sternocleidomastoid muscle, crossed the anterior border as a single branch; thereafter dividing into minute branches at the inferior pole of the parotid gland that innervated the parotid fascia and the inferior third of ear.

Additionally, in this study, the great auricular nerve bifurcated into two main branches *viz*, anterior and posterior as it crossed the anterior border of the sternocleidomastoid muscle [$^{18}/_{28}$ (64%) adult and $^{67}/_{80}$ (84%) fetal specimens]. Occasionally, the great auricular nerve divided into anterior and posterior branches at the inferior border of the parotid gland [$^{12}/_{28}$ (43%) adults and $^{26}/_{80}$ (33%) fetuses] which concurs with the findings by Biglioli *et al.*, (2002).

The anterior branch of the great auricular nerve pierces the inferior pole of the parotid gland innervating the skin overlying the parotid gland; and the posterior branch passed along the posterior margin of the gland, destined for the skin over the mastoid process, the posteroinferior surface of the auricle, and the lobule of the ear.

It has been suggested by numerous authors (Patel *et al.*, 2001; Yokoshima *et al.*, 2004; Zumeng *et al.*, 2006) that the great auricular nerve is usually damaged at the inferior border of the parotid gland during parotidectomy: therefore anatomical knowledge of the course and bifurcation pattern may prevent surgical complications such as Frey's syndrome.

5.3.3 TRANSVERSE CERVICAL NERVE

The nomenclature regarding this nerve has been controversial (Wyburn-Mason, 1953, Tobin, 1967; Hollinshead, 1974; Ellis and Fieldman, 1993; Standring *et al.*, 2008); therefore this study employs the term transverse cervical nerve for ease of reference. The transverse cervical nerve emerged from beneath the posterior border of the sternocleidomastoid muscle at a common point with the great auricular nerve. In all specimens analysed the nerve crossed the sternocleidomastoid muscle at its midline. It was constantly located inferior to the great auricular nerve in close relation to the external jugular vein. It was located either deep to the external jugular vein [$^{17}/_{28}$ (61%) of the adults and in $^{54}/_{80}$ (68%) of the fetal specimens] which supports the description of Standring *et al.*, (2008) or superficial to the external jugular vein [$^{11}/_{28}$ (39%) of the adults and in $^{26}/_{80}$ (32%) of the fetal specimens] in accord with Ellis and Fieldman (1993). Taylor and McHanwell (2009) suggested that knowledge of the relationship of the transverse cervical nerve and external jugular vein is of significance during facial rejuvenation surgery and venipuncture as this may cause erroneous damage to the nerve.

The transverse cervical nerve arose from the second and third cervical ventral rami in $^{12}/_{28}$ (43%) adults and $^{34}/_{80}$ (43%) fetuses concurring with the description by Standring *et al.*, (2008). In

addition, it arose from the third cervical ventral rami in $^{16}/_{28}$ (57%) adults and $^{46}/_{80}$ (57%) fetuses which supports the findings by Hollinshead (1974).

The transverse cervical nerve bifurcated into “Y” shaped ascending and descending branches [in adults: ($^{17}/_{28}$) (61%) and in fetuses: $^{65}/_{80}$ (81%)] as it crossed the anterior border of the sternocleidomastoid muscle or it remained as a single branch [$^{11}/_{28}$ (39%) of the adult and $^{12}/_{80}$ (15%) of the fetal specimens]. The single branch was destined to supply the skin over the angle of the mandible. Due to this “Y” shaped branching pattern, the transverse cervical nerve may sometimes be located at a higher level than usual and mistaken for the great auricular nerve as pointed out by Taylor and McHanwell (2009). An understanding of this concept may avoid inadvertent injury to this nerve during surgical procedures eg. Facial rejuvenation surgery.

According to the description from standard anatomical texts (Standring *et al.*, 2008), the transverse cervical nerve in this study was distributed to the skin of the side and front of neck.

5.3.4 SUPRACLAVICULAR NERVES

In all the specimens investigated the supraclavicular nerve pierced the cervical fascia as it emerged as a single trunk at the posterior border of the sternocleidomastoid muscle. It descended on the anterior and middle scalene muscles dividing into three distinct branches, viz. medial, lateral and intermediate. The supraclavicular nerves are intertwined intimately with the external jugular concurring with the description by Rao *et al.*, (2009). The course of the supraclavicular nerve and branches compares favorably with standard anatomical literature (Ellis and Fieldman, 1993; Berry *et al.*, 1995; Standring *et al.*, 2008).

The supraclavicular nerve arose from the cervical ventral rami of the third and fourth cervical nerves in $^{28}/_{28}$ (100%) of the adults and $^{45}/_{80}$ (56%) of the fetuses; and from the ventral ramus of the fourth cervical nerve in $^{35}/_{80}$ (44%) fetuses. In their course, the cervical ventral rami of the third and fourth nerves emerged constantly from the transverse foramen, lateral to the vertebral artery. This description concurred with Havet *et al.*, (2007) and Standring *et al.*, (2008). Rao *et al.*, (2009) reported that the supraclavicular nerves arose from three cervical rami viz. third, fourth and fifth cervical nerves; however this was not found in the current study.

The medial supraclavicular nerve is the most infero-medial branch of the supraclavicular nerve and is closely related to the external jugular vein and clavicular and sternal heads of the sternocleidomastoid muscle and innervated the skin over the anterior part of the clavicle. Knowledge of the close relationship of the medial branch to the external jugular vein is important because during venipuncture this nerve may be inadvertently injured, resulting in sensory loss to its area of distribution as suggested by Rao *et al.*, (2009). The intermediate supraclavicular nerve pierced the cervical fascia and emerged along the posterior border of the sternocleidomastoid muscle, descending antero-inferiorly, crossing the clavicle to supply the skin over the deltoid region and the lateral supraclavicular nerve descended superficially crossing the anterior border of the trapezius muscle dividing into several smaller branches that innervated the skin of the upper and posterior parts of the shoulder. Mehta and Birch (1997) suggested that the anatomical location of the supraclavicular nerves make them “vulnerable” to injury during surgical procedures within the posterior triangle of neck.

.

5.4 VARIATIONS OF THE SUPERFICIAL CERVICAL PLEXUS

“Anatomical variation is defined as the normal range in topography and morphology of the body structures.” (Khaki et al., 2006)

5.4.1 LESSER OCCIPITAL NERVE

A previously unreported finding which was observed in $\frac{3}{80}$ (4%) of the fetal specimens related to the course of the lesser occipital nerve. It emerged from beneath posterior border of the sternocleidomastoid muscle, hooked around the accessory nerve, and crossed over the levator scapulae muscle in the direction towards the trapezius muscle. A trapezius variant muscle was observed as a thin slip around which the lesser occipital nerve hooked. This variant lesser occipital may become compressed by the trapezius muscle resulting in “entrapment neuropathy” that may cause cervicogenic headaches as suggested by Madhavi and Holla (2004).

Basmajian and Slonecker (1989) described the area superior to accessory nerve within the posterior triangle of neck, where there are no important structures located to as the “carefree part”. In $\frac{2}{80}$ (2%) of the fetal specimens, the lesser occipital nerve was observed in the “carefree part” of the neck which corroborated the findings in $\frac{6}{16}$ (38 %) adult specimens by Lucas *et al.*, (1994). It was reported by Lucas *et al.*, (1994) that the presence of the lesser occipital nerve in the “carefree part” may be a cause of pain in the neck region as well as it playing a vital role in understanding the contribution of this nerve to cervicogenic headaches. In support of Lucas *et al.*, (1994), Madhavi and Holla, (2004) suggested that this location may make the nerve vulnerable to compression and stretching leading to cervicogenic headaches.

In addition, triplication of the lesser occipital nerve was observed confirming the findings by Madhavi and Holla (2004). It has been suggested that knowledge of this variation may assist in prevention of unintentional injury to the lesser occipital nerve during surgical and anesthetic practice.

5.4.2 GREAT AURICULAR NERVE

In $\frac{1}{80}$ (1%) of the fetal specimens depicting a single branching pattern, the great auricular nerve divided at the inferior pole of parotid gland into minute branches; one of these branches formed a connection with the transverse cervical nerve. This finding has been previously reported by Biglioli *et al.*, (2002). It has been recommended by Biglioli *et al.*, (2002) that in order to possibly avoid injury to the great auricular nerve during facial rejuvenation surgery and parotidectomy, knowledge of these communications may be crucial.

5.4.3 TRANSVERSE CERVICAL NERVE

An unreported finding observed in $\frac{3}{80}$ (4%) of fetal specimens was the presence of a triplicate branching pattern of the transverse cervical nerve which was located posterior to the external jugular vein. It has been reported by Rao *et al.*, (2009) that procedures such as venipuncture or regional anesthesia require understanding of anatomical variations; therefore knowledge of the triplicate branching pattern as well as its location to the external jugular vein may assist in preventing damage to this nerve during surgical procedures such as facial nerve rejuvenation surgery.

The results of the present study demonstrated a communication between the cervical branch of the facial nerve and the transverse cervical nerve which was observed in $^{83}_{/108}$ (77%) of the specimens. These results concur with the findings of Domet *et al.*, (2005) and Taylor and McHanwell (2009). Domet *et al.*, (2005) further stated that this communication may be a valuable aid in assisting surgeons to identify the facial nerve.

Awareness of the communications between the transverse cervical nerve and facial nerve may prevent the erroneous sacrifice of these nerves during surgical neck procedures.

In terms of the variable nomenclature regarding this communication, with Thumfart (1999) referring to it as the superficial ansa cervicalis and Domet *et al.*, (2005) as an anastomosis. The current research study proposes the use of the term “communication” rather than “anastomosis” considering the definition of an anastomosis is “the area of communication between end branches of adjacent blood vessels”.

5.4.4 SUPRACLAVICULAR NERVES

An anomalous finding in $^{6}_{/80}$ (8%) of the fetal specimens of a so called “ascending branch” arose from the main trunk and lateral branch of supraclavicular nerve. It ascended parallel to the lesser occipital nerve in its course towards the scalp. Lucas *et al.*, (1994), it was reported that variations such as the present one exist and may explain shoulder and arm pain encountered during cervicogenic headaches because of the common course of the supraclavicular and lesser occipital nerves. Lucas *et al.*, (1994) considered the ascending branch as a lesser occipital nerve anomaly rather than supraclavicular nerve anomaly because of the common origin of lesser occipital and supraclavicular nerves. However in the current study, it arose from the lateral

branch of the supraclavicular nerve and the main trunk with lesser occipital and supraclavicular nerves having separate origins.

Furthermore, there was a duplicate medial branch observed that arose directly from the supraclavicular trunk and was located beneath the external jugular vein, parallel to the sternocleidomastoid muscle.

In $\frac{1}{80}$ (1%) of the fetal specimens, the medial branch of supraclavicular nerve divided into two branches, with one branch having an anomalous course: it passed beneath the inferior belly of omohyoid muscle to reach the area over the middle third of the clavicle. Although this anomaly was previously unreported, anomalies regarding entrapment of the supraclavicular nerve beneath the trapezius muscle and clavicle have been widely studied and the term supraclavicular nerve entrapment has been employed (Gelberman *et al.*, 1975; Tubbs *et al.*, 2007; Jelev and Surchev, 2007). Tubbs *et al.*, (2007) stated that clinicians should consider such entrapment in patients with extreme shoulder pain.

5.5 EMERGING POINTS OF THE SUPERFICIAL CERVICAL PLEXUS

Bescer *et al.*, (1998) reported wide variability in the location of the branches of the superficial cervical plexus. This study attempts to classify the emerging points of the branches of the superficial cervical plexus in relation to their location on the sternocleidomastoid muscle. This study adopted the classification pattern by Kim *et al.*, (2002).

The most frequent classification type encountered in this research was the lesser occipital nerve emerging on the upper third and the great auricular, transverse cervical and supraclavicular nerves emerging on the middle third of the sternocleidomastoid muscle (35%). Kim *et al.*, (2002) reported their frequent pattern as the separated type (50%). The findings in the current study differed from that of Kim *et al.*, (2002). A possible explanation for this discrepancy may be influenced by the difference in sample size (current study: 108 sides; Kim *et al.*, (2002): 64 sides) as well as the different population groups (current study: South African; Kim *et al.*, (2002): Korean)

Kim *et al.*, (2002) suggested that the knowledge of emerging points may assist in the effective anaesthesia to all branches of the superficial cervical plexus during surgical procedures of the neck, eg. carotid endarterectomies and thyroid surgery.

5.6 DEEP CERVICAL PLEXUS

The deep cervical plexus was classified according to muscular, communicating, ansa cervicalis and phrenic branches which is the standard classification used among authors such as Hollinshead (1974), and Standring *et al.*, (2008). It formed in the paravertebral region of the second, third and fourth cervical vertebrae, arising between the anterior and middle scalene muscles in 100% of the adult and fetal specimens.

5.6.1 MUSCULAR BRANCHES

The muscular branches were classified according to Standring *et al.*, (2008) into medial and lateral series. The medial series innervated the longus colli muscle and the lateral series innervated the levator scapulae, scalenus medius and sternocleidomastoid muscles. In this study, the deep cervical plexus supplied the muscles of both the medial and lateral series concurring with standard anatomical textbooks (Standring *et al.*, 2008).

5.6.2 ANSA CERVICALIS

Ansa is a Latin term meaning "handle of a cup" or "haft." (Clemente, 1986)

The ansa cervicalis is formed by superior and inferior roots that are located in the vicinity of the common carotid artery and internal jugular vein. In the research conducted the hypoglossal nerve was observed superior to the bifurcation of the common carotid artery. The superior root of the ansa cervicalis was recognized as a long willowy nerve that branched from the hypoglossal nerve and descended on the carotid sheath, predominantly anterior to the internal jugular vein [in 64 % (⁶⁹/₁₀₈)] in support of Calliot and Dumont (1983) who recorded the descent of the superior root

anterior to the carotid sheath and internal jugular vein in majority of their dissections. However Standring *et al.*, (2008) described the descent predominantly lateral to the internal jugular vein.

The inferior root of the ansa cervicalis was derived from the junction between the ventral rami of the second cervical nerve in 16%, second and third cervical nerves in 26%, and from the third cervical nerve in 58%. In the specimens dissected by Calliot and Dumont (1983) the most frequent contributor to the inferior root was the ventral ramus of the third cervical nerve (80%). This study concurs with these findings. In addition, it was noted that standard anatomical texts report the inferior root derivation from the junction between the ventral rami of the second and third cervical nerve (Standring *et al.*, 2008).

The superior and inferior roots join to form a loop which determines the classification into long and short ansa cervicalis. Loukas *et al.*, (2007) reported that if the loop was located low in the neck it was classified as a long ansa and if it was high in the neck it was termed short ansa. It was also suggested that the superior belly of omohyoid be used as a landmark to determine the long and short ansa, with the loop above termed “short” and below termed “long” ansa (Chhetri and Berke, 1997). In the present series utilizing Chhetri and Berke (1997) definition, the majority of the ansa cervicalis dissected were as short ansa cervicalis [adults: $\frac{17}{28}$, (61%); fetuses: $\frac{63}{80}$, (79%)].

Chhetri and Berke (1997) and Loukas *et al.*, (2007), recommended the use of the ansa cervicalis in laryngeal reinnervation surgery since resection of this nerve causes no serious “functional or

cosmetic” damage. Therefore the anatomic course and relation to the vessels in the neck may be of importance to surgeons.

5.7 VARIATIONS OF DEEP CERVICAL PLEXUS

In $\frac{1}{80}$ (1%) fetal specimens it was noted that the ventral rami of the third and fourth cervical nerves together with the accessory nerve supplied the sternocleidomastoid muscle. This finding was previously reported by Tobias and Arnold (1999). Interestingly, they reported this branch to the sternocleidomastoid muscle as being sensory.

Calliot and Dumont (1983) described seven morphological forms for the classification of the formation of the loops. In addition, morphological variations of the ansa cervicalis were classified into three types according to Chhetri and Berke (1997). In $\frac{2}{80}$ (3%) fetal specimens, the ansa cervicalis had a classic double form with two separate roots. The superior root of the first loop received the normal contribution from hypoglossal nerve and the inferior root was formed by the ventral ramus of the second cervical nerve. The second loop was formed from a continuation of the superior root and the ventral ramus of the third cervical nerve. This variation was previously described by Calliot and Dumont (1983) in 40% of their dissections.

A previously unreported variation existed in $\frac{1}{80}$ (1%) of the fetal specimens: the superior root of ansa cervicalis received a contribution from the hypoglossal nerve, a short distance later it formed a loop around the internal jugular vein and the inferior root was derived from the ventral ramus of the second cervical nerve. Additionally, in $\frac{1}{80}$ (1%) specimens the ansa cervicalis formed a “W” shaped appearance above the superior belly of omohyoid muscle. This was

formed by a dual contribution from the hypoglossal nerve and the inferior root was formed by ventral ramus of the third cervical nerve

A “vago-cervical complex formed by a contribution from the vagus nerve, as well as a contribution from the hypoglossal nerve to the superior root was recorded in $\frac{2}{80}$ (3%) of the fetal specimens. This was previously reported in a study conducted in adults by Bannekha *et al.*, (2008).

During laryngeal re-innervation surgery, understanding the intimate anatomical relationship of the ansa cervicalis with the common carotid artery and internal jugular vein as well as variations in its formation may play a role in preservation of the nerve as well as avoiding inadvertent damage to the common carotid artery and the internal jugular vein.

5.7 LANDMARKS

Anteriorly, the branches of the superficial cervical plexus originate from the “great auricular point” that was located at the junction of the upper two-thirds and middle thirds of the sternocleidomastoid muscle. This is at the level of the hyoid bone at the third cervical vertebra. This point may be utilized for the effective administration of anaesthesia during surgical procedures such as carotid endarterectomy and thyroid surgery.

The great auricular nerve was suggested to be a useful landmark in identifying the spinal accessory nerve within the posterior triangle of the neck.

The transverse process below the mastoid process is the second cervical vertebra that is located opposite the hyoid bone. The fourth cervical vertebra lies approximately at the level of the mandible and the sixth cervical vertebra is the point at which the external jugular vein crosses the posterior border of the sternocleidomastoid muscle. These second, third and fourth vertebral levels may be utilized when performing a deep cervical plexus block during carotid endarterectomy.

5.8 COMMUNICATIONS

The hypoglossal nerve contributed to the superior root of the ansa cervicalis. In this study the superior cervical ganglion received a grey ramus communication from the cervical plexus supporting the description from standard anatomical texts (Standring *et al.*, 2008). In all specimens in this study the superior cervical ganglion was located opposite the second and third cervical vertebrae. The number of branches from the superior cervical ganglion to the cervical

nerves varied from one to a maximum of four and in the majority of the specimens. In addition, the superior cervical ganglion communicated with the first cervical nerve. Variations in the contribution of the superior cervical ganglion to the cervical plexus were recorded by Axford (1928) and Hoffman (1957). However this was not observed in the current study. Dash *et al.*, (2005) conducted a study on the lesser occipital nerve and its relation to migraine headaches and concluded that pain in the face or head region may be caused by its communication with the superior cervical ganglion.

5.9 EXTERNAL JUGULAR VEIN

Anatomically, the great auricular nerve has been described as lying parallel and posterior to the external jugular vein by McKinney and Katrana, (1980) and superior or inferior by Thumfart *et al.*, (1999). This concurs with the results obtained in this study. The transverse cervical nerve was observed as it lies deep to the external jugular and the medial supraclavicular nerves passes infero-medially across the external jugular vein or intertwining with it. This study was the first to measure the distance between the external jugular vein and each branch of the superficial cervical plexus to determine its relationship. It was recorded statistically that the transverse cervical and supraclavicular nerves produced positive correlations and this may be due to the close anatomical relationship of supraclavicular and transverse cervical nerves.

In addition, variations in external jugular and internal jugular vein formation were observed viz. duplication of the external jugular vein and a “Y” shaped appearance of the internal jugular vein. Aboudib and de Castro (1997) suggested that knowledge of the variations of the veins may play

a role in preventing hematoma formation and injury to the branches of the superficial cervical plexus during venipuncture.

The gross anatomy of the cervical plexus recorded in this study conformed to that described in standard anatomical textbooks (Standring *et al.*, 2008, McMinn, 1994).

In this study, clarification was sought on the gross anatomical course, branching pattern and relations of the superficial cervical plexus which comprised the lesser occipital, great auricular, transverse cervical and supraclavicular nerves. Even though the gross anatomy conformed to standard anatomical textbooks, variations were encountered in the branching patterns, formation and communication with nerves of the superficial cervical plexus and the facial nerve. The emerging points in this study were classified according to a study on the Asian population by Kim *et al.*, (2002) and differences were observed. The external jugular vein relation to the branches of the superficial cervical plexus investigated by means of statistically analysis and gross anatomical descriptions.

In addition, the deep cervical plexus was classified according to muscular, ansa cervicalis, phrenic and communicating branches and their relations were investigated. The ventral rami of the second and third cervical nerves emerged between the scalenus anterior and scalenus medius muscles, and the third and fourth cervical nerves was located at the lateral edge of scalenus medius muscle. The superior cervical ganglion constantly communicated with the ventral rami of the cervical nerves; and the hypoglossal communicated with the superior root of the ansa cervicalis. The muscular branches were observed to the scalenus anterior and scalenus medius muscles with an anomalous branch to the sternocleidomastoid muscle. The ansa cervicalis demonstrated a degree of variation with regard to its origin, course and formation of the loops.

The phrenic nerve arose from the ventral rami of the third, fourth and fifth cervical nerves and descended on the lateral border of the scalenus anterior muscle.

While there is abundant information that exists on the clinical aspects of the superficial and deep cervical plexus, however there is limited information save for textbooks on the detailed gross anatomy of the plexuses.

The precise understanding of the anatomy of the superficial and deep cervical plexuses together with variations may assist anesthetists and surgeons to accurately identify the vascular, neural and muscular structures and reduce the risks of complications when performing neural blocks in regional anesthesia, facial rejuvenation surgery and parotidectomies.

JOURNALS

Aboudib JHC and de Castro CC (1997) Anatomical Variations Analysis of the External Jugular Vein, Great Auricular Nerve, and Posterosuperior Border of the Platysma Muscle *Aesthetic Plastic Surgery* **21(2)**: 75-78

Abu-Hijleh MF (2005) Bilateral absence of ansa cervicalis replaced by vagocervical plexus: case report and literature review. *Ann Anat* **187**: 121—125

Ando M, Beppu M, Nagao M, Myoshi K, Kohda M (1992) Anatomy of the accessory nerve and its innervations of the trapezius. *J Jpn Soc Surg Hand* **9**: 288 – 291

Aunac S, Carlier S, Singelyn F, De Kock M (2002) The Analgesic Efficacy of Bilateral Combined Superficial and Deep Cervical Plexus Block Administered Before Thyroid Surgery Under General Anesthesia. *Anesth Analg* **95**:746-750

Axford M (1927) Some Observations of Cervical Sympathetics in Man *J Anat* **62**: 301

Bademci G, Yaşargil MG (2006) Microsurgical anatomy of the hypoglossal nerve *Journal of Clinical Neuroscience* **13(8)**: 841 -847

Banneheka S (2008) Morphological study of the ansa cervicalis and the phrenic nerve. *Anatomical Science International* **83**: 31–44

Becser N, Bovim G, Sjaastad O (1998) Extracranial nerves in the posterior part of the head: anatomic variations and their possible clinical significance. *Spine*. **23**:1435–1441

Bejjani G, Sullivan B, Lopez ES (1998) Surgical anatomy of the infratemporal fossa: the styloid diaphragm revisited, *Neurosurgery* **43**: 842–853

Bigeleisen PE, (2003) Anatomical variations of the phrenic nerve and its clinical implication for supraclavicular block. *British Journal of Anaesthesia* **91** (6): 916-17

Biglioli F, D’Orto O, Bozzetti A, Brusati R (2002) Function of the great auricular nerve following surgery for benign parotid disorders. *Journal of Cranio-Maxillofacial Surgery* **30**: 308–317

Bonnet F, Derosier JP, Pluskwa F, Abhay K and Gaillard A (1990) Cervical epidural anaesthesia for carotid artery surgery. *Canadian Journal of Anesthesia* **37** (3) 353 – 358

Brennan PA, Webb R, Kemidi F, Spratt J, Standring S (2008) Great auricular communication with the marginal mandibular nerve – a previously unreported anatomical variant. *British Journal of Oral and Maxillofacial Surgery* **46(6)**: 492-493

Caliot P, Dumont D (1983) A contribution to the morphological study of the ansa cervicalis. *Rev Laryngol Otol Rhinol (Bord)* **104**: 441-4

Castrasena MR, Masters RD, Castasena EJ (1994) Incidence and clinical significance of hemidiaphragmatic paresis in patients undergoing carotid endarterectomy during cervical plexus block anesthesia. *J Neurosurg Anesthesiol* **6**:21–3

Chhetri DK, Berke GS (1997) Ansa Cervicalis Nerve: Review of the Topographic Anatomy and Morphology. *Laryngoscope* **107(10)**: 1366-1372

Christensen NR, Jacobsen SD (1997) Parotidectomy. Preserving the posterior branch of the great auricular nerve. *Journal of Laryngology and Otology* **3**: 556-559

Craven J, (2007) The cervical plexus. *Anesthesia and intensive care medicine* **8(6)**: 266-267

Dash KS, Janis JE, Guyuron B (2005) The lesser and third occipital nerves and migraine headaches. *American Society of Plastic Surgeons* **115(6)**: 1752-1758

Davies MJ, Dysart RH, Silbert BS (1992) Prevention of tachycardia with atenolol pretreatment for carotid endarterectomy under cervical plexus blockade. *Anaesth Intensive Care* **20**:161–4

Davies MJ, Murrell GC, Cronin KD (1990) Carotid endarterectomy under cervical plexus block, a prospective clinical audit. *Anaesth Intensive Care* **18**:219–23

Davies MJ, Silbert BS, Scott DA, Cook RJ, Mooney PH, Blyth C (1997) Superficial and deep cervical plexus block for carotid artery surgery: A prospective study of 1000 blocks. *Reg Anesth* **22**:442–6

de Sousa AA, Filho MAD, Faglione W, Carvalho GTC (2005) Superficial vs combined cervical plexus block for carotid endarterectomy: A prospective, randomized study. *Surg Neurol* **63** (1) 22-25

Domet MA, Connor NP, Heisey DM, Hartiq GK (2005) Anastomoses between the cervical branch of the facial nerve and the transverse cervical cutaneous nerve. *Am J Otolaryngol* **26**:168–171

Fredriksen TA, Hovdal H, Sjaastad O (1987) Cervicogenic headache: clinical manifestations. *Cephalalgia* **7**:147-160

Ginsberg LE, Eicher SA (2000) Great Auricular Nerve: Anatomy and Imaging in a Case of Perineural Tumor Spread *Am J Neuroradiol* **21**:568–571

Havet E, Duparc F, Tobenas-Dujardin AC, Muller JM and Frége P (2007) Morphometric study of the shoulder and subclavicular innervation by the intermediate and lateral branches of supraclavicular nerves. *Surgical and Radiologic Anatomy* **29** (8): 605-610

Hoffman H (1957) An Analysis of the Sympathetic Trunk and Rami in the Cervical and Upper Thoracic Regions in Man. *Annals of Surgery* 145 (1): 94-103

Hone SW, Ridha H, Rowley H, Timon CI (2001) Surgical landmarks of the spinal accessory nerve in modified radical neck dissection *Clin Otolaryngol Allied Sci* **26**: 16–8

Hovelacque A (1927) Anatomie des nerfs crâniens et rachidiens et du. *Doin, Paris*, **6**: 248–258

Indrasingh I, Vettivel S (2000) A Rare Pseudo Ansa Cervicalis: A Case Report *J Anat. Soc. India* **49(2)**: 178-179

Jelev L, Surchev L (2007) Study of variant anatomical structures (bony canals, fibrous bands, and muscles) in relation to potential supraclavicular nerve entrapment. *Clin Anat.* **20**:278–285

Khaki AA, Shokouhi G, Shoja MM, Farahani RMZ, Zarrintan S, Khaki A, Montazam H, Tanoomand A, Tubbs RS (2006) Ansa cervicalis as a variant of spinal accessory nerve plexus: A case report. *Clinical Anatomy* **19**:540–543

Kikuchi T (1970) A contribution to the morphology of the ansa cervicalis and the phrenic nerve. *Acta Anat Nipon* **45**: 242–81

Kim HJ, Koh KS, Oh CS, Hu KS, Kang JW, Chung IH (2002) Emerging patterns of the cervical cutaneous nerves in Asians. *Int J Oral Maxillofac Surg* **31**:53–56

Knighton JD, Stoneham MD (2000) Carotid endarterectomy: A survey of UK anaesthetic practice. *Anaesthesia* **55**:481–5

Kuniak B, Klacansky J (1982) A contribution to topographic anatomy of ansa cervicalis with reference to reinnervation of the larynx. *Cesk Otolarynogl* **31**: 170–175

Loukas M, Thorsell A, Tubbs RS, Kapos T, Louis Jr. RG, Vulis M, Hage R, Jordan R (2007) The ansa cervicalis revisited. *Folia Morphol.* **66 (2)**: 120–125

Madhavi C and Holla SJ (2004) Triplication of the lesser occipital nerve. *Clin Anat* **17**: 667 – 671

Madhyastha S, Bhat SM (2008) Anomalous phrenic nerve – A case report. *Neuroanatomy* **5**: 47-49

McKinney P, Katrana DJ (1980) Prevention of injury to the great auricular nerve during rhytidectomy. *Plast Reconstr Surg* **66**:675

Mehta A, Birch R (1997) Supraclavicular nerve injury: The neglected nerve? *Injury* **28**:491-492

Michael K, Lueng S, Dieu T, Cleland H (2003) Surgical approach to the accessory nerve in the posterior triangle of the neck. *Plastic and Reconstructive Surgery*: 2067-2070

Nash L, Nicholson H, Zhang M (2005) Does the investing layer of deep cervical fascia exist? *Anesthesiology* **5**:962-968

Nason RW, Abdulrauf BM, Stranc MF (2000) The anatomy of the accessory nerve and cervical node biopsy. *Am J. Surg* **180**:214

Nayak SB, Soumya KV (2008) Abnormal formation and communication of external jugular vein. *International Journal of Anatomical Variations* **1**: 15–16

Olry R, Haines DE (2002) Ansa hypoglossi or Ansa cervicalis? That is the question. *J Hist Neurosci* **11**: 302–4

Pandit JJ, Bree S, Dillon P (2000) A Comparison of Superficial Versus Combined (Superficial and Deep) Cervical Plexus Block for Carotid Endarterectomy: A Prospective, Randomized Study. *Anesth Analg* **91**:781–6

Pantaloni M, Sullivan P (2000) Relevance of the lesser occipital nerve in facial rejuvenation surgery. Discussion paper by E Austad. *Plastic and Reconstructive Surgery* **105** (7): 2600 – 2603

Patel N, Har-El G, Rosenfeld R (2001) Quality of life after great auricular nerve sacrifice during parotidectomy. *Arch Otolaryngol Head Neck Surg* **127**:884–8

Philip C (1999) Applied Anatomy of Cervical Plexus Blockade. *Anesthesiology* **90**(6): 1790 -1791

Pintaric TS, Hocevar M, Jereb S, Casati A, Jankovic VN (2007) A Prospective, Randomized Comparison Between Combined (Deep and Superficial) and Superficial Cervical Plexus Block with Levobupivacaine for Minimally Invasive Parathyroidectomy. *Anesth Analg* **105**:1160-1163

Poviraev NP, Chernikov YF (1967) Anatomy of the ansa cervicalis. *Excerpta Medica* **21** (1): 219

Potts TK., (1925) The main peripheral connections of the human sympathetic nervous system. *J. Anat.*, 59: 129

Rao TR, Shetty P, Rao S (2009) A rare case of looping of supraclavicular nerve branches around external jugular vein and transverse cervical artery. *International Journal of Anatomical Variations* **2**:48–50

Rath G, Anand C (1994) Vagocervical complex replacing an absent ansa cervicalis. *Surg Radiol Anat* **16**: 441–3

Roessel T, Wiessner D, Heller AR, Zimmermann T, Koch T, Litz RJ. (2007) High-resolution ultrasound-guided high interscalene plexus block for carotid endarterectomy. *Reg Anesth Pain Med* **32**:247-53

Santamaria G, Britti RD, Tescione M, Moschella A, Bellinvia C (2004) Comparison between local and general anaesthesia for carotid endarterectomy: A retrospective analysis. *Minerva Anesthesiol* **70**:771–8

Stoneham MD, Doyle AR, Knighton JD, Dorje P, Stanley JC (1998) Prospective, randomized comparison of deep or superficial cervical plexus block for carotid endarterectomy surgery. *Anesthesiology* **89**:907–12

Stoneham MD, Wakefield TW (1998) Acute respiratory distress following deep cervical plexus block. *J Cardiothorac Vasc Anesth* **12**:197– 8

Suresh S, Templeton L (2004) Superficial cervical plexus block for vocal cord surgery in an awake pediatric patient. *Anesth Analg* **98**:1656–7

Takolander R, Bergqvist D, Hulthen UL (1990) Carotid artery surgery: local versus general anaesthesia as related to sympathetic activity and cardiovascular effects. *Eur J Vasc Surg* **4**:265–70

Taylor R, McHanwell S (2008) Re: Brennan PA, Webb R, Kemidi F, Spratt J, Standring S. Great auricular communication with the marginal mandibular nerve—A previously unreported anatomical variant. *Br. J. Oral. Maxillofac. Surg.* **47(6)**:492–493

Tobias JD (1999) Cervical plexus block in adolescents. *Journal of Clinical Anesthesia* **11(7)**: 606-608

Tubbs RS, Salter EG, Wellons JC (IIIrd), Blount JP, Oakes WJ (2007) Landmarks for the identification of the cutaneous nerves of the occipital and nuchal regions. *Clin Anat* **20**: 235-238

Verma R, Das S, Suri R (2005) Unusual organization of the ansa cervicalis: a case report. *Braz. J. morphol. Sci.* **22(3)**: 175-177

Vollala VR, Bhat SM, Nayak S (2005) A rare origin of upper root of ansa cervicalis from vagus nerve: A case report. *Neuroanatomy* **4**: 8–9

Winnie AP, Ramamurthy S, Durrani Z, Radonjic R (1975) Interscalene cervical plexus block: a single injection technique. *Anesth Analg* **54** 370–375

Wyburn-Mason R (1953) The nature of tic douloureux: Treatment by alcohol block or section of the great auricular nerve. *British medical journal* 119-122

Yamada S, Peterson GW, Soloniuk DS, Will AD (1965) Coaptation of the anterior rami of C-3 and C-4 to the upper trunk of the brachial plexus for cervical nerve root avulsion. *Journal of Neurosurgery* **74** (2) 643-451

Yerzingatsian KL (1989) Thyroidectomy under local analgesia: The anatomical basis of cervical blocks. *Ann Roy Coll Surg Engl* **71**:207–10

Yokoshima K, Nakamizo M, Ozu C (2004) Significance of preserving the posterior branch of the great auricular nerve in parotidectomy *J Nippon Med Sch* **71**: 323–327

Zohar Y, Siegal A, Siegal G, Halpern M, Levy B, Gal R (2002) The great auricular nerve; does it penetrate the parotid gland? An anatomical and microscopical study *Journal of Cranio-Maxillofacial Surgery* **30** (5): 318-321

Zumeng Y, Zhi G, Gang Z, Jianhua W, Yinghui T (2006) Modified superficial parotidectomy: Preserving both the great auricular nerve and the parotid gland fascia. *Otolaryngology–Head and Neck Surgery* **135**: 458-462

BOOKS

Basmajian JV, Slonecker CE (1989) Posterior triangle of the neck. In: *Grant's method of anatomy. A clinical problem-solving approach*. 11th ed. Baltimore: Lippincott Williams and Wilkins. p491

Berry M, Bannister HL, Standring S (1995) Nervous System In L. P. William (Ed.), *Gray's Anatomy*, 8th Ed. Edinburgh: Churchill Livingstone pp 1238–1264

Brown DL (2006) *Atlas of Regional Anesthesia*, 3rd ed., Elsevier Saunders

Clemente CD (2007) *Anatomy: The regional atlas of the human body*, 5th ed., Lippincott Williams and Wilkins pp 1023

Cousins MJ, Bridenbaugh PO eds. (1988) Back pain: Zygapophysial blocks and epidural steroids: Neural blockade. Philadelphia, Lippincott pp 935-954

Cramer GD and Darby SA (1995) Basic and clinical anatomy of the spinal cord, and ANS. Mosby pp 140 – 149

Cummings B (2003) *Otolaryngology: Head & Neck Surgery*, 4th ed. Mosby pp 532

Drake RL, Vogl AW, Mitchell AWM (2010) In, *Gray's anatomy for students* (2nd ed.), Churchill Livingstone, Edinburgh pp. 971-974

Ellis H and Fieldman S (1993) *Anatomy for Anaesthetists* Blackwell science publishers

Grant JCB (1995) *A Method of Anatomy, Descriptive and Deductive* ed. Baltimore, Williams and Wilkins

Hollingshead WH (1974) *Anatomy for Surgeons, Vol. 1*, 3rd edition, Philadelphia: Harper and Row pp 479

Jamieson GG (2006) *The Anatomy of General Surgical Operations*, E-book Elsevier Publishers, pp 143

McMinn RMH (1999) *Last's Anatomy: Regional and Applied*. Singapore Churchill Livingstone Ltd. Pp 306

Miller RD (eds) (1995) *Anesthesia: Nerve blocks Vol 1*. pp 624 -625

Monsen, H (1992) *Anatomy of the anterior and lateral triangles of the neck*. In L. M. Nyhus and R. J. Baker (Eds.), *Mastery of Surgery*, 2nd Ed. Boston: Little, Brown

Moore KL and Dalley AF (1999) *Clinically Orientated Anatomy* 4th ed. Lippincott Williams and Wilkins pp 1010 – 1012

Moore KL and Persaud R (1998) The developing human. WB Saunders. Philadelphia
pp 368

Mosby (2009) Mosby's Medical Dictionary 8th ed. Elsevier pp 1056

Netter F (1995) Atlas of human anatomy 3rd ed. Ciba-Geigy Corporation. Summit, New
Jersey pp 122

Paturet (1964) Traite d'anatomie humaine. Vol. 1. Masson et Cie edit. Paris

Rogers AW, Jacob S (1992) Textbook of Anatomy, Edinburgh: Churchill-Livingstone
pp 314–420

Romanes GJ (1987), Editor, *Cunningham's textbook of anatomy* (12th ed.), Oxford
University Press, Oxford pp. 770–772

Rouviere H (1959) Anatomie Humaine, 8th edition. Nerfs de la tete et du cou, Paris:
Masson et Cie, pp 231–288

Salasche, S. J., Bernstein, G., and Senkarik, M (1988) Surgical Anatomy of the Skin.
Norwalk, Conn.: Appleton & Lange, Pp. 12, 116–117, 263–265

Sinnatamby CS (2006) Head and neck and spine. In: C.S. Sinnatamby, Editor, *Last's
anatomy* (12th ed.), Churchill Livingstone, Edinburgh pp. 345–347

Standring S (2008) Neck. In: S. Standring, Editor, *Gray's anatomy* (40th ed.), Churchill Livingstone, Edinburgh pp. 435–436.

Tank PW (2005) In: *Grant's dissector* 13th ed. Baltimore: Lippincott Williams and Wilkins. Pp 176, 178

Thumfart WF, Platzer W, Gunkel AR, Maurer H, Brenner E (1999) Surgical Approaches in Otorhinolaryngology Thieme Publishers, pp 24

Tobias and Arnold (1999) Man's Anatomy Vol 2 pp 130 -133

Tobin CE (1967) Basic Human Anatomy New York, McGraw-Hill - Blakiston publication pp 382

Yamada M, Mannen H (1985) *Anatomy for Dissectors*. Nankodo, Tokyo pp 188

Table I: Emerging Points in Adult

NO. / SIDE	SCM	GAN	LON	TCN	SCN	EJV
1 R	94.21	26.19	21.28	35.27	43.38	66.75
L	89.63	24.95	23.81	32.63	36.35	52.13
2 R	54.65	29.25	24.62	28.17	36.07	37.65
L						
3 R	88.34	23.38	25.46	40.96	45.78	53.89
L	88.39	25.38	22.52	33.7	36.47	45.7
4 R	67.36	22.15	19.55	27.64	29.83	42.97
L	69.54	24.27	21.56	25.56	33.15	33.47
5 R	61.46	23.67	24.98	27.77	29.14	31.82
L	89.17	28.19	28.76	31.17	32.76	30.26
6 R	85.18	23.16	21.26	25.77	25.35	26.12
L	81.36	20.74	20.58	22.06	24.56	24.32
7 R	71.71	26.23	24.08	37.93	41.87	40.79
L	70.13	27.98	23.24	27.44	37.65	39.23
8 R	80.11	24.25	23.11	32.87	37.65	39.06
L	89.15	28.78	25.58	37.49	39.14	40.15
9 R	74.13	24.58	23.66	36.44	38.91	38.63
L	73.87	23.88	21.26	34.83	36.33	39.89
10 R	73.48	25.68	24.71	38.18	38.48	32.96
L	89.92	23.65	22.87	33.14	37.96	34.11
11 R	89.36	22.56	23.67	28.63	31.56	38.96
L	74.73	28.34	24.17	32.76	37.62	39.04
12 R	79.55	27.9	26.34	29.14	37.12	38.62
L	68.01	26.78	22.22	31.85	33.67	35.91
13 R						
L	73.88	26.41	24.8	31.21	33.56	33.84
14 R	58.76	22.78	23.54	26.79	29.03	34.71
L	56.38	23.77	26.89	35.18	35.47	34.49
15 R	74.34	24.18	24.13	35.74	38.9	38.94
L	75.87	26.97	21.15	29.02	32.78	36.03

Table II: Emerging Points in Fetuses

NO. / SIDE	AGE	SCM	GAN	LON	TCN	SCN	EJV
1 R	14 WKS	25.5	11.84	12.77	13.07	14.61	14.78
L		22.83	8.35	9.64	10.47	11.74	14.3
2 R	13 WKS	22.25	10.89	10.71	15.32	14.18	15.18
L		23.75	14.63	12.61	15.86	17.05	14.98
3 R	15 WKS	34.38	12.37	10.65	16.66	18.76	25.33
L		27.11	12.77	9.42	13.87	21.08	26.41
4 R	19 WKS	29.92	11.11	10.74	11.97	18.95	23.42
L		29.36	11.89	8.16	13.52	18.24	19.57
5 R	15 WKS	34.73	15.11	12.81	17.64	20.44	19.95
L		29.55	14.01	13.48	14.63	19.55	18.41
6 R	13 WKS	19.95	10.09	11.43	10.88	14.09	16.02
L		24.15	9.09	8.32	10.95	14.64	15.85
7 R	19 WKS	33.71	13.23	12.08	15.93	18.87	21.79
L		31.13	13.98	14.24	18.44	18.65	20.23
8 R	19 WKS	31.46	13.67	14.98	17.77	19.14	21.82
L		29.17	18.19	18.76	21.17	22.76	20.26
9 R	15 WKS	25.18	13.16	11.26	15.77	15.35	16.12
L		25.36	10.74	11.2	12.06	14.56	14.32
10 R	15 WKS	25.48	14.2	11.76	14.22	16.05	16.27
L		23.36	8.86	5.36	12.63	12.94	13.08
11 R	17 WKS	28.38	9.13	8.77	16.53	16.98	19.03
L		24.75	15.13	12.56	15.85	16.05	17.43
12 R	15 WKS	29.46	12.73	12.67	14.48	18.42	16.12
L		29.14	13.65	14.05	15.77	16.64	14.32
13 R	17 WKS	27.84	14.44	13.64	17.12	19.18	19.73
L		24.93	12.13	6.82	13.19	14.62	13.89
14 R	17 WKS	27.73	16.04	15.14	16.73	19.1	18.42
L		28.82	11.12	13.07	13.96	15.84	13.58
15 R	15 WKS	26.43	11.06	11.63	9.19	14.15	13.32
L		23.82	13.65	11.77	9.36	16.06	16.82
16 R	13 WKS	23.3	13.79	11.37	14.86	16.22	17.44
L		22.08	9.96	7.78	11.26	11.54	12.66
17 R	17 WKS	33.85	14.62	14.19	14.93	21.5	20.75
L		28.7	14.18	14.13	14.87	18.55	20.44
18 R	17 WKS	31.06	13	10.9	12.82	14.26	14.52
L		26.33	14.53	12.41	16.04	16.84	14.32
19 R	15 WKS	23.31	8.33	1.77	9.42	14.31	15.62
L		23.16	9.55	6.71	9.53	12.57	14.35
20 R	15 WKS	29.6	13.06	10.64	14.81	17.29	19.27
L		28.14	10.94	8.36	13.18	15.29	14.58
21 R	17 WKS	26.52	9.72	7.12	13.21	16.08	18.53

APPENDIX

L		31.1	17.69	14.25	13.01	18.84	14.35
22 R	16 WKS	28.14	12.25	10.05	13.11	16.53	17.17
L		34.14	14.53	13.66	16.42	18.92	17.31
23 R	17 WKS	30.18	17.16	15.23	18.19	21.86	21.12
L		30.26	11.69	9.28	15.08	16.86	17.27
24 R	17 WKS	30.83	11.65	9.78	13.93	15.52	19.49
L		30.16	11.24	9.64	15.19	15.75	19.51
25 R	16 WKS	31.35	15.15	18.33	15.55	17.83	19.86
L		35.51	18.28	17.73	18.67	23.33	27.63
26 R	17 WKS	34.26	14.71	10.83	14.98	15.2	23.45
L		30.51	16.21	15.75	17.66	21.31	27.63
27 R	15 WKS	25.91	7.82	9.14	15.83	13.96	19.13
L		23.65	7.6	6.22	12.19	13.95	19.16
28 R	19 WKS	29.06	12.72	8.56	18.97	18.92	22.34
L		28.43	15.34	12.13	15.77	19.08	20.46
29 R	15 WKS	26.53	12.83	11.26	14.16	16.44	17.26
L		25.55	16.69	8.24	13.84	15.64	16.19
30 R	24 WKS	31.71	12.23	11.08	14.93	17.87	20.79
L		30.13	12.98	13.24	17.44	17.65	19.23
31 R	16 WKS	35.42	15.83	13.23	17.95	19.79	21.03
L		27.01	13.29	11.9	15.75	17.45	18.15
32 R	24 WKS	30.11	11.25	11.11	12.87	17.65	19.06
L		29.15	11.78	13.56	16.48	18.14	20.15
33 R	16 WKS	31.85	15.69	15.51	16.85	19.27	19.73
L		29.49	15.04	13.05	16.8	17.93	19.74
34 R	13 WKS	24.55	10.64	11.11	11.95	12.86	14.94
L		26.9	10.96	9.36	13.25	14.13	17.62
35 R	13 WKS	26.43	11.22	9.34	12.35	12.72	12.51
L		28.35	17.4	17.07	18.39	18.55	23.92
36 R	13 WKS	26.38	13.74	16.87	15.08	15.43	14.39
L		29.82	15.59	14.44	14.64	15.05	17.42
37 R	14 WKS	28.08	13.32	9.65	11.53	17.94	14.6
L		28.83	11.35	9.44	11.47	13.74	14.3
38 R	16 WKS	28.12	12.21	10.07	13.1	16.51	17.14
L		34.13	14.58	13.66	16.44	18.91	17.32
39 R	17 WKS	33.87	13.88	14.26	16.83	16.33	19.89
L		33.48	15.68	14.71	18.18	18.48	22.96
40 R	13 WKS	19.95	10.09	11.43	13.65	14.09	15.07
L		24.15	9.09	8.32	10.95	14.64	15.85

Table III: Emerging Patterns: Upper, middle or lower thirds - ADULTS

NO. / SIDE	UPPER 13	MIDDLE 1/3	LOWER 1/3
1 R	GAN, LON	TCN, SCN	EJV
L	GAN, LON	TCN, SCN	EJV
2 R	GAN, LON, TCN	SCN, EJV	
L			
3 R	GAN, LON	TCN, SCN, EJV	
L	GAN, LON	TCN, SCN, EJV	
4 R	GAN, LON	TCN, SCN, EJV	
L	GAN, LON	TCN, SCN, EJV	
5 R		GAN, LON, TCN, SCN, EJV	
L	GAN, LON	TCN, SCN, EJV	
6 R	GAN, LON, TCN, SCN, EJV		
L	GAN, TCN, SCN, EJV		
7 R		GAN, LON, TCN, SCN, EJV	
L	LON	GAN, TCN, SCN, EJV	
8 R	GAN, LON	TCN, SCN, EJV	
L	GAN, LON	TCN, SCN, EJV	
9 R	GAN, LON	TCN, SCN, EJV	
L	GAN, LON	TCN, SCN, EJV	
10 R		GAN, LON, TCN, SCN, EJV	
L	GAN, LON	TCN, SCN, EJV	
11 R	GAN, LON, TCN	SCN, EJV	
L	LON	GAN, TCN, SCN, EJV	
12 R		GAN, LON, TCN, SCN, EJV	
L	LON	GAN, TCN, SCN, EJV	
13 R			
L	LON	GAN, TCN, SCN, EJV	
14 R		GAN, LON, TCN, SCN, EJV	
L		GAN, LON, TCN, SCN, EJV	
15 R	GAN, LON	TCN, SCN, EJV	
L	LON	GAN, TCN, SCN, EJV	

Table IV : Emerging Patterns in Fetuses

NO. / SIDE	UPPER 13	MIDDLE 1/3	LOWER 1/3
1 R		GAN; LON; TCN; SCN; EJV	
L		GAN; LON; TCN; SCN; EJV	
2 R		GAN; LON, TCN	SCN; EJV
L		GAN; LON, TCN	SCN; EJV
3 R	LON	GAN; TCN; SCN; EJV	
L		GAN; LON; TCN	SCN; EJV
4 R		GAN; LON; TCN; SCN	EJV
L	LON	GAN; TCN; SCN; EJV	
5 R		GAN; LON; TCN; SCN; EJV	
L		GAN; LON; TCN; SCN; EJV	
6 R		GAN; LON	SCN
L	LON	GAN; TCN; SCN; EJV	
7 R		GAN; LON; TCN; SCN; EJV	
L		GAN; LON; TCN; SCN; EJV	
8 R		GAN; LON; TCN; SCN	EJV
L		GAN; LON	TCN; SCN; EJV
9 R		GAN; LON; TCN; SCN; EJV	
L		GAN; TCN; SCN; EJV	
10 R		GAN; LON; TCN; SCN; EJV	
L	LON	GAN; TCN; SCN; EJV	
11 R	LON; GAN	TCN; SCN	EJV
L		GAN; LON; TCN; SCN	EJV
12 R		GAN; TCN; SCN	
L		GAN; LON; TCN; SCN	
13 R		GAN; LON; TCN	SCN; EJV
L	LON	GAN; TCN; SCN; EJV	
14 R		GAN; LON; TCN	SCN; EJV
L		LON; TCN; SCN; EJV	
15 R		GAN; TCN; SCN	
L		GAN; LON, TCN	SCN; EJV
16 R		GAN; LON; TCN	SCN; EJV
L	LON	GAN; TCN; SCN; EJV	

APPENDIX

17 R	LON	GAN; TCN; SCN; EJV	
L		LON, GAN; TCN; SCN	EJV
18 R	LON	GAN; TCN; SCN	
L		GAN; LON; TCN; SCN	
19 R	LON	GAN; TCN; SCN	EJV
L	LON	GAN; SCN; EJV	
20 R		GAN; LON; TCN; SCN; EJV	
L	LON	GAN; TCN; SCN; EJV	
21 R	LON	GAN; TCN; SCN	EJV
L		GAN; LON; SCN	
22 R		GAN; LON; TCN; SCN; EJV	
L		GAN; LON; TCN; SCN	
23 R		GAN; LON; TCN	SCN; EJV
L	LON	GAN; TCN; SCN; EJV	
24 R	LON	GAN; TCN; SCN; EJV	
L	LON	GAN; TCN; SCN, EJV	
25 R		GAN; TCN; SCN; EJV	
L		GAN; LON; TCN	SCN; EJV
26 R	LON	GAN; TCN; SCN	EJV
L		GAN; LON; TCN	SCN; EJV
27 R	LON; GAN	TCN; SCN	EJV
L	LON; GAN	TCN; SCN	EJV
28 R	LON	GAN; TCN; SCN	EJV
L		GAN; LON; TCN	SCN; EJV
29 R		GAN; LON; TCN; SCN; EJV	
L	LON	GAN; TCN; SCN; EJV	
30 R		GAN; LON; TCN; SCN; EJV	
L		GAN; LON; TCN; SCN; EJV	
31 R		GAN; LON; TCN; SCN; EJV	
L		GAN; LON; TCN; SCN; EJV	
32 R		GAN; LON; TCN; SCN; EJV	
L		GAN; LON; TCN; SCN	EJV
33 R		GAN; LON; TCN; SCN	
L		GAN; LON; TCN	SCN; EJV
34 R		GAN; LON; TCN; SCN;	

APPENDIX

		EJV	
L	LON	GAN; TCN; SCN; EJV	
35 R	LON	GAN; TCN; SCN; EJV	
L		GAN; LON; TCN; SCN	EJV
36 R		GAN; TCN; SCN; EJV	
L		GAN; LON; TCN; EJV	
37 R	LON	GAN; TCN, SCN, EJV	
L	LON	GAN; TCN; SCN; EJV	
38 R		GAN; LON; TCN; SCN; EJV	
L		GAN; LON; TCN; SCN; EJV	
39 R		GAN; LON; TCN; SCN; EJV	
L		GAN; LON; TCN; SCN; EJV	
40 R		LON; GAN	TCN; SCN; EJV
L	LON	GAN; TCN; SCN; EJV	

SCIENTIFIC RESEARCH BASED ON THIS RESEARCH TO DATE

PAPERS DELIVERED AT SCIENTIFIC CONFERENCES

NATIONAL CONFERENCES

Fetal study of the superficial cervical plexus: relevance for local anaesthesia

P Soobramoney, P Partab, KS Satyapal

University of Kwa-Zulu Natal, College of Health Science Astra Zeneca Research Symposium, 12-13 August 2008

Superficial Cervical Plexus: variations in a fetal study

P Soobramoney, P Partab, L Lazarus, KS Satyapal

College of Health Science Research Symposium, Nelson R Mandela School of Medicine, UKZN, September 2009

INTERNATIONAL CONFERENCES

Superficial Cervical Plexus: variations in a fetal study

P Soobramoney, P Partab, L Lazarus, KS Satyapal

17th Congress of the International Federation of Association of Anatomists (IFAA), Cape Town, 16-19 August 2009

Superficial cervical plexus: Emerging points in a fetal study

P Soobramoney, P Partab, L Lazarus, KS Satyapal

17th Congress of the International Federation of Association of Anatomists (IFAA), Cape Town, 16-19 August 2009

CHAPTER 1

INTRODUCTION

CHAPTER 2

REVIEW OF LITERATURE

CHAPTER 3

MATERIALS AND METHODS

CHAPTER 4

RESULTS

CHAPTER 5

DISCUSSION

CHAPTER 6

CONCLUSION

REFERENCES

APPENDIX
